THE LIBRARY OF CONGRESS

THE LIBRARY OF CONGRESS

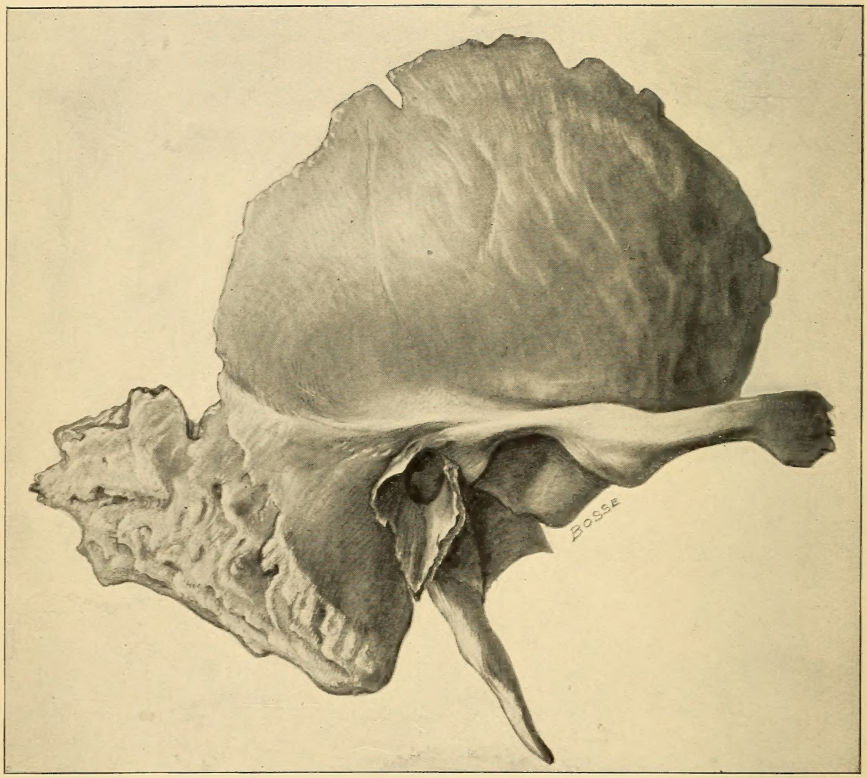

Fig. 1.—External surface of the adult temporal bone. Landmarks indicated upon key plate.

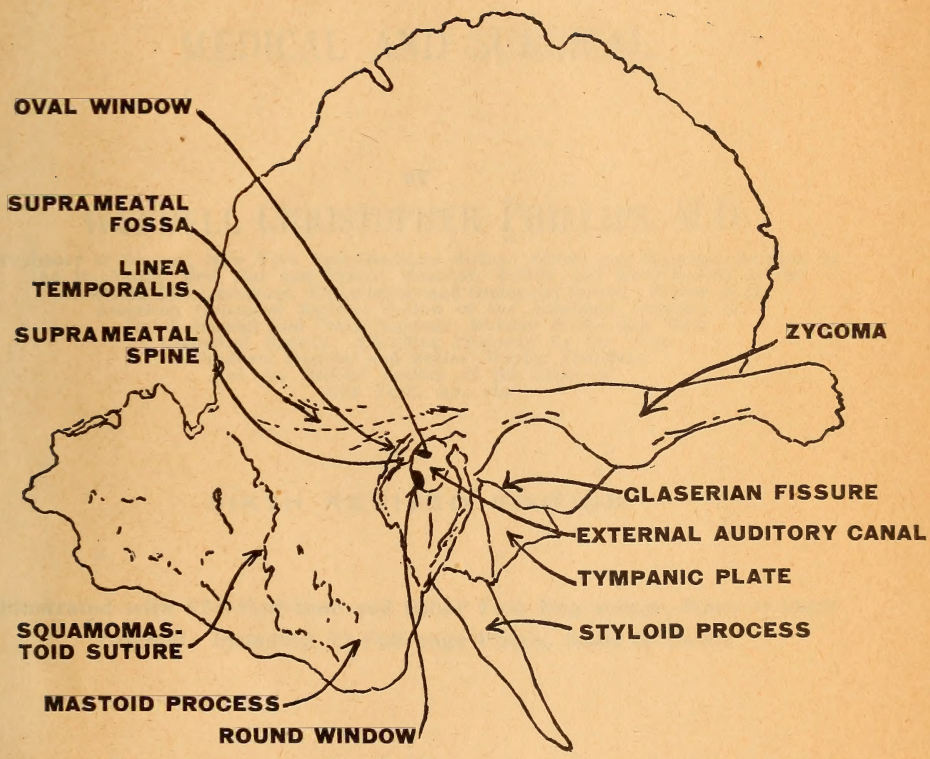

Key plate for Fig. 1.

DISEASES

OF THE

EAR, NOSE AND THROAT

MEDICAL AND SURGICAL

BY

WENDELL CHRISTOPHER PHILLIPS, M.D.

Professor of Otology, New York Post-Graduate Medical School and Hospital; Surgeon to the Manhattan Eye, Ear and Throat Hospital; Fellow and Ex-President of the American Laryngological, Rhinological and Otological Society; Fellow of the American Otological Society; Fellow of the American Academy of Ophthalmology and Otolaryngology; Member of the New York Otological Society; Attending Otologist to the Post-Graduate Hospital and Babies' Wards; President of the Medical Society of the State of New York, etc., etc.

SIXTH REVISED EDITION

Illustrated with 578 Half-tone and Other Text Engravings, Many of them Original; Including 37 Full-page Plates, Some in Colors

PHILADELPHIA
F. A. DAVIS COMPANY, PUBLISHERS
1922

RF46
.P5
1922

COPYRIGHT, 1911
COPYRIGHT, 1913
COPYRIGHT, 1915
COPYRIGHT, 1917
COPYRIGHT, 1919
COPYRIGHT, November, 1922
BY
F. A. DAVIS COMPANY

Copyright, Great Britain. All Rights Reserved

©CIA666686

PRINTED IN U. S. A.
PRESS OF
F. A. DAVIS COMPANY
PHILADELPHIA, PA.

NOV -3 1922

PREFACE TO SIXTH EDITION.

In presenting the Sixth Edition of this text-book, I desire to express grateful appreciation of the generous support accorded by my *confrères,* especially the teachers of oto-laryngology, by medical students, and the medical profession in general.

Its adoption as the standard text-book by the majority of the Medical Schools of the country, and as a reference book by many Medical Institutions of foreign countries, together with the rapid exhaustion of the Fifth Edition, has encouraged me to make an extensive revision of the subject matter, to eliminate methods and procedures which have become obsolete and to add many items of new and up-to-date material. For instance, it has demanded considerable courage, mingled with some misgivings, to eliminate the descriptions and illustrations of such operations as the Asch, Roe and Gleason operations upon the nasal septum, which now must be considered obsolete.

In the Nose and Throat section I have revised the operative treatment for chronic ethmoiditis, including the necessary illustrations.

Important additions have been made regarding the adult tonsil.

The operative treatment for intrinsic cancer of the larynx has been extensively elaborated and illustrated.

The chapters on Suspension Laryngoscopy, Bronchoscopy and Esophagoscopy have been revised under the supervision of Drs. Lynch and Jackson.

A brief description and illustration of the audiometer test for hearing has been introduced.

There has also been a revision of the methods of examination of the pus and blood in purulent otitis media and its complications.

In the department of general diseases I have thoroughly revised the subject matter of diphtheria, syphilis, asthma, and allergy and pollen therapy in hay fever.

The details of the Schick test and the New York City Health Department plan for its application are fully defined.

There is also a reference to social and community service work for the deafened.

Finally, cuts pertaining to improved methods and new instruments, numbering about fifty, have been introduced.

It has been my continued desire to thoroughly Americanize this volume, by giving preference to the achievements of American otologists, rhinologists and laryngologists, in the belief that wherever it may be read it should stand for American ideals.

W. C. P.

40 West Forty-seventh Street,
New York City.

PREFACE.

In the preparation of this volume it has been my conscientious endeavor to define the essential features of the principal diseases of the ear, nose and throat, and to outline the modern and approved methods of treatment for these affections.

The work was attempted, in part, in response to repeated requests from many students and practitioners of medicine whom I have been privileged to instruct in the New York Post-Graduate Medical School and at the Manhattan Eye, Ear and Throat Hospital during the past twenty years. Hence, it has been prepared to meet the needs of the general practitioner and surgeon as well as the otologist and laryngologist.

I have purposely refrained from perpetuating discarded theories, or descriptions of operations which are either obsolete or have been superseded by more modern methods, simply for the purpose of completing the record or to conform to the older text-books. Nor have I introduced modern theories or operations unless they possess a reasonable measure of scientific value. In short my purpose has been to write a practical, accurate and concise treatise bearing the approval of personal experience.

In the chapters devoted to general considerations I have grouped various symptoms and measures of treatment which are common to two or more affections, in order to avoid needless repetition. A section devoted to the influence of general diseases and conditions upon the ear, nose and throat has permitted the grouping of a variety of affections (numbering about thirty-seven), which exhibit symptoms or lesions referable to these organs, and to depict the necessary local and general measures of treatment for the same. It is believed that this section will appeal to the general practitioner and be valuable for reference. I have purposely placed the section on the ear first in order to give emphasis to the fact that in this book the space devoted to the ear is not a mere addendum, but a complete work on otology. The section on the nose and throat is at the same time equally comprehensive and complete.

The subject-matter is presented in the general form of a text-book, but in the preparation of the text as well as the illustrations I have aimed to make it a practical, comprehensive operative surgery

of the ear, nose and throat. To this end the illustrations of operations or steps of operations, whether schematic or actual, are accurate and may safely serve as guides to the surgeon.

It is a pleasure to acknowledge the aid received from the publications of my numerous confrères. The standard American and foreign text-books, monographs and published articles have been freely consulted, and many of these have been referred to in the text. Parker's excellent classification of the diseases of the pharynx and larynx has been adopted in part.

I desire also to express my sincere thanks for the encouragement and many courtesies extended by my colleagues in New York and elsewhere, many of whom have been personally consulted regarding numerous phases of this work. The members of my staff at the Manhattan Eye, Ear and Throat Hospital have responded cheerfully to all requests for assistance in various details. I am specially indebted to Drs. S. J. Kopetzky, J. J. Thomson, L. M. Hubby, E. P. Fowler, J. H. Guntzer and L. J. Denchfield for outlining or compiling various items of descriptive matter, and for abstracting valuable material from foreign and American literature. Mr. K. K. Bosse has devoted his best energies and skill to the preparation of the numerous drawings. The valuable assistance rendered by Miss B. Arnaud in attending to the various minor details is gratefully acknowledged.

My thanks are due to the publishers for their valuable suggestions and for the care bestowed upon the numerous details pertaining to the mechanical preparation of this work.

W. C. P.

40 West Forty-seventh Street,
New York City.

CONTENTS.

Part I. The Ear.

Section I.—General Considerations.

CHAPTER.		PAGE.
I.	The Office Equipment	1
II.	The Examination of Patients	9
III.	The Physiology of Hearing	26
IV.	Functional Examination. The Tests for Hearing	36
V.	General Etiology of Ear Diseases	45
VI.	General Symptomatology of Ear Diseases	54
VII.	General Diagnosis of Ear Diseases	65
VIII.	General Therapy of Ear Diseases	84

Section II.—The External Ear.

IX.	Surgical Anatomy of the External Ear	104
X.	Diseases of the External Ear	109
XI.	Diseases of the External Ear (*Continued*)	125
XII.	Diseases of the External Ear (*Continued*). Malformations and Anomalies	143
XIII.	Diseases of the External Ear (*Continued*). Neoplasms	152

Section III.—The Middle Ear.

XIV.	Diseases of the Middle Ear. Diseases and Injuries of the Membrana Tympani	168
XV.	Diseases of the Middle Ear (*Continued*). Surgical Anatomy of the Middle Ear and Eustachian Tube	174
XVI.	Diseases of the Middle Ear (*Continued*). Classification. Acute Middle-ear Catarrhs	182
XVII.	Diseases of the Middle Ear (*Continued*). Chronic Middle-ear Catarrhs	187
XVIII.	Diseases of the Middle Ear (*Continued*). Acute Inflammation of the Middle Ear and Mastoid Process	198
XIX.	Diseases of the Middle Ear (*Continued*). Acute Diseases of the Mastoid Process	212
XX.	Diseases of the Middle Ear (*Continued*). The Simple Mastoid Operation	228
XXI.	Diseases of the Middle Ear (*Continued*). Chronic Purulent Otitis Media	255
XXII.	Diseases of the Middle Ear (*Continued*). The Radical Mastoid Operation	281
XXIII.	Complicating Lesions of Purulent Otitis Media. Purulent Labyrinthitis	314

CHAPTER. PAGE.

XXIV. Complicating Lesions of Purulent Otitis Media (*Continued*). The Intracranial Complications of Purulent Otitis Media Lateral Sinus Thrombosis 346
XXV. Complicating Lesions of Purulent Otitis Media (*Continued*). Intracranial Complications. Otitic Diseases of the Meninges. 365
XXVI. Complicating Lesions of Purulent Otitis Media (*Continued*). Otitic Brain Abscess 375

SECTION IV.—DISEASES OF THE PERCEPTIVE APPARATUS AND MISCELLANEOUS DISEASES AND CONDITIONS OF THE EAR.

XXVII. Diseases of the Perceptive Apparatus. Otosclerosis 386
XXVIII. Miscellaneous Otitic Conditions 394

PART II. THE INFLUENCE OF GENERAL DISEASES UPON THE EAR, NOSE AND THROAT.

XXIX. The Influence of General Diseases upon the Ear, Nose and Throat. Introduction. Tuberculosis. Lupus 407
XXX. The Influence of General Diseases upon the Ear, Nose and Throat (*Continued*). Syphilis 433
XXXI. The Influence of General Diseases upon the Ear, Nose and Throat (*Continued*). Diphtheria. Scarlatina. Measles .. 449
XXXII. The Influence of General Diseases upon the Ear, Nose and Throat (*Continued*). Typhoid Fever, Typhus Fever, etc. .. 474

PART III. THE NOSE AND ACCESSORY SINUSES.—THE PHARYNX AND FAUCES.—THE LARYNX.

SECTION I.—THE NOSE AND THE NASAL ACCESSORY SINUSES.

XXXIII. Acute Inflammatory Affections of the Nasal Mucosa 494
XXXIV. Chronic Inflammatory Affections of the Nasal Mucosa 505
XXXV. The Nasal Septum and its Pathological Conditions 522
XXXVI. The Turbinate Bones and their Diseases 546
XXXVII. The Diseases of the Nasal Accessory Sinuses. Anatomical Classification. The Maxillary Antrum 566
XXXVIII. The Diseases of the Nasal Accessory Sinuses (*Continued*). The Frontal Sinuses 587
XXXIX. The Diseases of the Nasal Accessory Sinuses (*Continued*). The Ethmoidal Sinuses and the Sphenoidal Sinuses 609
XL. The Correction of External Nasal Deformities, Epistaxis, Foreign Bodies in the Nose, Parasites (Maggots, Screw-worms, Fungi, etc.), Rhinoliths, Nasal Furunculosis 633
XLI. Nasal Neuroses 648
XLII. Neoplasms of the Nose 655

SECTION II.—THE PHARYNX AND FAUCES.

CHAPTER. PAGE.

XLIII. Diseases of the Nasopharynx. Surgical Anatomy. Acute Nasopharyngitis. Simple Chronic Nasopharyngitis. Atrophic Nasopharyngitis. Adenoids. Neoplasms. Foreign Bodies. 665

XLIV. Diseases of the Oropharynx. Surgical Anatomy. Malformation and Deformities of the Oropharynx. Malformation and Deformities of the Uvula. Retropharyngeal Abscess. Ulcerations and Adhesions of the Uvula and Soft Palate 690

XLV. Diseases of the Oropharynx (*Continued*). Simple Acute Inflammations. Acute Infective Inflammations. Traumatic Pharyngitis. Toxic Pharyngitis 699

XLVI. Diseases of the Oropharynx (*Continued*). Chronic Hyperplastic Pharyngitis. Chronic Atrophic Pharyngitis. Chronic Tonsillitis. Lingual Varix 718

XLVII. Diseases of the Pharynx. Neoplasms. Neuroses of the Pharynx. Unclassified Affections of the Pharynx 742

SECTION III.—THE LARYNX.

XLVIII. Acute Inflammatory Diseases of the Larynx. Acute Infectious Epiglottitis. Simple Acute Laryngitis. Acute Infectious Laryngitis. Acute Laryngitis due to Traumatism 751

XLIX. Chronic Inflammatory Affections of the Larynx. Chronic Hyperplastic Laryngitis. Chronic Atrophic Laryngitis. Chronic Perichondritis and Chronic Chondritis. Chronic Ankylosis of the Cricoarytenoid Joint. Chronic Arthritis. Laryngeal Stenosis. Foreign Bodies in the Larynx. Prolapse of the Ventricle 768

L. Neoplasms of the Larynx 780

LI. Neuroses of the Larynx 801

LII. Suspension Laryngoscopy 819

LIII. Direct Laryngoscopy, Bronchoscopy, and Esophagoscopy 832

LIV. Esophagoscopy 844

Formulary 850

Index 855

ILLUSTRATIONS.

FIG. PAGE

1 External surface of the adult temporal bone. Landmarks indicated upon key plate ..... Frontispiece
2 Section of the right temporal bone, the two segments of which show important anatomical landmarks. See key plate. (Author's specimen.) ..... Facing 1
3 Main section of the author's treatment room 2
4 Author's enameled waste pail with funnel-shaped cover 3
5 Justrite metal receptacle for mastoid and other dressings 3
6 "Erickson" sterilizing outfit 3
7 Author's electric headlight with focusing device 4
8 Compressed air apparatus 5
9 Bib for patients 6
10 Author's cotton box 7
11 Introducing the aural speculum 10
12 Author's history card 11
13 Reverse side of Author's history card 12
14 Sharp's modification of Bosworth's nasal speculum 13
15 Author's modification of Bosworth's speculum with solid flaring blades 13
16 Ingalls's nasal speculum 14
17 Flat wide platinum applicator 14
18 Posterior rhinoscopy 15
19 White's palate retractor 16
20 Michael's postnasal mirror 16
21 Anatomical conformation of the mouth and pharynx 17
22 The laryngeal picture—cords widely separated 18
23 The laryngeal picture—cords in apposition 19
24 Proper position of surgeon and patient during catheterization of the Eustachian tube 20
25 Catheter properly introduced along the inferior meatal floor 21
26 Faulty introduction of the Eustachian catheter 22
27 Catheter tip in position within the Eustachian orifice 23
28 Eustachian bougie passed through a catheter 24
29 Siegel pneumatic speculum 24
30 Fowler's middle-ear inflation apparatus 31
31 Showing thick membrana basilaris near the lower end of the basal coil (*Shambaugh*) 32
32 Membrana tectoria about one-half turn from the lower end of the basal coil (*Shambaugh*) 33
33 Membrana tectoria near the apex of the cochlea (*Shambaugh*) 34
34 Politzer's acoumeter 38
35 Set of Hartman's tuning forks 39
36 Galton whistle 40
37 Fowler's resonator apparatus 42
38 Fowler audiometer 43
38*a* Audiograph illustrating the shortening of hearing capacity 44
39 Fracture of the temporal bone through the labyrinth 50
40 Lateral view of the tympanic cavity and drum membrane, with key plate 67
41 Marked retraction of the drum membrane 68
42 Lateral view of the tympanic cavity, drum membrane and bony meatus, with key plate 69
43 Large perforation of the membrana tympani 70
44 Position of patient for the operation of lumbar puncture (*Louis Fischer*) 76
45 Lumbar puncture needle and syringe 77
46 Anatomical illustration showing the place best adapted for lumbar puncture (*Louis Fischer*) 77
47 The piston syringe in use 84
48 The Fowler suction bell douche 85
49 The suction douche applied to the ear, showing the indrawing of the auricle resulting from the partial vacuum within the glass bell 86
50 The suction douche apparatus complete, showing the supply bag, rubber tubing, etc. 87
51 Electric air heater 91
52 Points for the subperiosteal injection of cocaine to induce local anesthesia of the mastoid process 95
53 Electric ear speculum 96
53*a* Pocket electric ear speculum 96
54 Paracentesis bistoury 97
55 Incision commonly required for opening the drum membrane 97
56 A lateral view of the inner portion of the external auditory canal and tympanic cavity 98
57 Incision of the drum membrane 99
58 Incisions of the membrana tympani 99
59 The Bier treatment by constriction band about the neck (*Kopetzky*) 100
60 Suction apparatus for inducing local hyperemia (*Fowler*) 101

FIG. PAGE
61 The normal auricle, with landmarks 105
62 Outer aspect of the right side of the cranium of a fetus at birth, showing entire absence of the osseous meatus, mastoid tip, the drum membrane and ossicles *in situ* (*Dunning*) 106
63 Eczema of the auricle 110
64 Facial nerve, geniculate ganglion and relations with the otic (*Testut*) 115
65 Herpes oticus. (Partly schematic) 117
66 Othematoma of the auricle 123
67 Furuncle of the external meatus viewed through the speculum 126
68 Lateral view of the external meatus, showing furuncle in posterior wall 128
69 Syringing the ear for the removal of cerumen 134
70 A method to be employed for removing buttons from the external meatus whenever the eye or eyelet can be seen by the surgeon 137
71 Removal of oval object (bean) from the auditory meatus with forceps 138
72 Quires's foreign-body extractor 139
73 Carious mastoid process. Removed from a child 14 years old (Author's case) 141
74 Projecting ear, with abnormal droop or lop. There is also redundant cartilage and deformity of the helix 143
75 Diminutive auricle, with absence of external meatus 144
76 Diagrammatic representation of the normal measurements of the auricle (*Goldstein*) 145
77 The satyr ear 145
78 Redundancy and deformity of the helix (*Goldstein*) 146
79 Bifid lobule. Showing line for incision to be followed in performing a plastic operation to overcome the deformity 147
80 Large horny excrescence projecting from lobule (Author's case) 148
81 Supernumerary tragus 149
82 Fistula congenita auris 149
83, 84, 85 Usual technique for reducing macrotia (*Goldstein*) 149
86 Usual incisions for correcting deformities of "lop ear" 150
87, 88, 89, 90 Serve to illustrate the steps of operation for projecting auricle (*Goldstein*) 151
91 Postauricular sebaceous cyst (Author's case) 153
92 Extensive congenital angioma of the auricle, the side of the face and the head (side view) 154
93 Same as Figure 92 (front view) 155
94 Epithelioma of the auricle (Author's case) 158
95 Same as Figure 94. Later stage of the disease 159
96 Postauricular osteosarcoma. (Patient of Dr. E. Terry Smith) 161
97 Exostosis of the external auditory canal. (Partly schematic) 162
98 Rupture of the drum membrane due to concussion from "boxing the ear" 172
99 Vertical section through left temporal bone in the plane of the axis of the petrous portion. (*Bardeleben.*) (Colored.) ..... Facing 174
100 Partly schematic drawing from specimen (enlarged) after Siebenmann (*Kopetzky*) 175
101 The normal membrana tympani. (Colored.) ..... Facing 176
102 The landmarks of the membrana tympani 176
103 Lateral view, showing the normal relations of the external auditory canal, drum membrane, ossicles and tympanic cavity 177
104 Showing early stage of serous transudate into the tympanic cavity as a result of an attack of acute catarrhal otitis media. (Partly schematic.) 183
105 Congested blood-vessels along the line of the malleus handle. The drum membrane is retracted 183
106 Hyperemia of the blood-vessels of the drum membrane during the early stage of acute catarrhal otitis media 183
107 Showing upper level of tympanic transudate. Drum membrane retracted 184
108 Air bubbles in the tympanic transudate, following inflation. (Partly schematic) 184
109 Change in the level of the fluid induced by tipping the patient's head backward. (Partly schematic) 184
110 Lateral view of the tympanum, showing air bubbles in the transudate. (Partly schematic) 185
111 Drum membrane retracted 190
112 Malleus handle foreshortened 190
113 Retraction of the drum membrane with calcareous plaques 191
114 Large perforation healed over with a thin layer of tissue 191
115 Lateral view of the tympanic cavity, with key plate. (Partly schematic) 192
116 Holmes nasopharyngoscope 193
116*a* Pharyngeal opening of the normal Eustachian tube 193
116*b* Anatomically constructed tube (chronic epipharyngitis and salpingitis) 193
116*c* Papilloma attached to the posterior superior wall and about one-third inch from the orifice of the tube 193
116*d* Two adenomatous polypi arising within the tube. Both turbinals, much hypertrophied, resting upon the anterior lip of the tube and in contact with the growths within the lumen of the tube 193
117 Inflammatory engorgement of the blood-vessels of the membrana tympani 204
118 Bulging of the drum membrane 204
119 Lateral view of the tympanum, with key plate, partly schematic, showing bulging of the drumhead (1), pus in the tympanum (2), and absence of the usual prominence of the processus brevis (3) 205
120 Lateral view of the tympanum, with key plate, partly schematic, showing (1) bulging of drumhead. The tympanum is nearly filled with pus (2), the long process of the malleus (3) is forced outward with the bulging drum and the usual prominence of the short process (4) is partially obliterated... 206

FIG. PAGE
121 Lateral view of the tympanum, partly schematic, showing perforation in the lower segment of the drum membrane ... 207
122 Lateral view of the tympanic cavity and drum membrane, partly schematic, showing extravasation of exudate between the layers of the membrana tympani ... 208
123 Marked bulging of the posterosuperior quadrant of the drum membrane ... 209
124 External periostitis of the mastoid process due to furunculosis of the external auditory meatus and simulating advanced acute mastoiditis ... 213
125 Subperiosteal mastoid abscess ... 216
126 Lateral view of the external auditory canal and tympanic cavity ... 220
127 Localizing points of tenderness upon pressure over the mastoid process ... 221
128 Radiograph of a normal mastoid process (pneumatic type) ... Facing 222
129 Radiograph of a normal mastoid for the purpose of comparison with its fellow (*c*) the diseased mastoid ... Facing 222
130 A diseased mastoid process with broken-down cell walls ... Facing 222
131 Wooden block, grooved for head rest during operation upon mastoid process (*S. Richardson*) ... 228
132 The head in position upon grooved block ... 228
133 Photograph showing the arrangements completed for performing a mastoid operation ... 229
134 A complete set of instruments for the mastoid operation, including the emergency instruments required for complications ... 230
135 Temporal bone, external surface, showing landmarks ... 231
136 The primary incision through the soft tissues of the mastoid process ... 232
137 Langenbeck's hoe periosteal elevator ... 232
138 The Douglas periosteal elevator ... 232
139 Cutting the outer portion of the attachment of the sternomastoid muscle to the tip of the mastoid process ... 233
140 Jansen's mastoid wound retractor ... 234
141 Showing the cortex of the mastoid process with the soft tissues retracted by self-retaining retractors ... 234
142 The posterior mastoid incision ... 235
143 Chiseling the antrum cortex ... 236
144 The mastoid antrum opened and a curved probe inserted through the aditus ... 237
145 Set of mastoid chisels and gouges ... 238
146 Removing the cortex with rongeur forceps ... 239
147 Excavating cells and granulations with curet, and the technique of biting the overhanging cortex with the rongeur forceps ... 240
148 The specimen shows a continuation of the mastoid cells into the basilar process of the occipital bone (*Dunning*) ... 241
149 A set of rongeur forceps comprising those in common use ... 242
150 A completed simple mastoid operation ... 243
151 Exposure of the dura in the region of the antrum and attic tegment, and exposure of the lateral sinus ... 243
152 Extensive excavation of the mastoid process and the zygomatic cells (*Dunning*) . 244
153 Author's portable operating table ... 245
154 Author's complete sterilized outfit ... 246
155 The mastoid wound packed with gauze and nearly closed with sutures ... 247
156 First step in applying the mastoid bandage ... 248
157 The completed mastoid bandage ... 249
158 The double mastoid bandage ... 250
159 Postoperative temperature curve, showing continuous flat temperature ... 251
160 Temperature chart, illustrating postoperative elevation of temperature ... 253
161 Temperature chart, showing the usual postoperative rise in temperature on the day following the operation ... 253
162 Large granulations involving the intratympanic mucosa ... 257
163 Showing an aural polypus projecting through a perforation in the drum membrane ... 257
164 Polypus protruding from a perforation in Shrapnell's membrane ... 257
165, 166 Lateral view of the tympanic cavity, partly schematic, with key plate ..262, 263
167 Perforation in the drum membrane, which has healed over ... 264
168 Lateral view of tympanic cavity, with key plate, partly schematic ... 265
169 Perforation of drum membrane which does not impinge upon bony structures of middle ear ... 266
170 Small perforation at umbo ... 266
171 Perforation of large size in central portion of drumhead ... 266
172 Loss of entire central portion of drum membrane and small portion of membrana flaccida ... 267
173 Almost entire absence of drumhead proper and membrana flaccida ... 267
174, 175 Multiple perforations in drumhead ... 268
176 Large perforation in Shrapnell's membrane, through which the carious malleus and incus are visible ... 269
177 Perforation of upper posterior quadrant at junction of drum membrane proper with Shrapnell's membrane ... 269
178 An attic cannula in position ... 271
179 Snare passed along the polypus, the mass meanwhile being engaged within the wire loop ... 272
180 A hypodermic needle, introduced along upper portion of osseous canal wall to inject local anesthetic ... 275
181 A schematic drawing representing field of intratympanic operation ... 276

FIG. PAGE
182 Circle *A*, outer extremity of aural speculum, introduced into external auditory canal. Dotted circle *B*, drumhead to be incised. Inner circle *C*, portion of drum membrane visible to eye of operator at one time 276
183 Primary incision to sever drumhead from its peripheral attachments 277
184 Tenotomy knife introduced into tympanic cavity at a point above level and behind short process of malleus to sever tendon of tensor tympani muscle 277
185 Position of tenotomy knife after tendon of tensor tympani has been severed 277
186 Angular extracting forceps introduced into tympanic cavity, firmly grasping malleus preparatory to its removal 278
187 Position of incus hook when introduced to rotate incus downward and forward preparatory to its removal 278
188 *A*, sharp ring curets. *B*, angular sharp curets 279
189 Kerrison chisel forceps in position for removing outer wall of aditus (attic) ... 280
190 Jansen's fibrocartilaginous wall retractor 283
191 A completed tympanomastoid excavation 284
192 The Stacke protector 285
193 The Richards curet 285
194 Eustachian curet (*Neumann*) 286
195 Set of Allport's mastoid drills 286
196 Anomalous position of the facial nerve, with plate (*Dr. T. P. Berens*) 288
197 Complete facial paralysis 290
198 Same patient. Taken while attempting to close the eyes 290
199 The Stacke meatal flap 293
200 The Panze meatal flap 294
201 The dotted line indicates the location of the primary incision to be followed in constructing the Stacke, the Panze and other modifications of the Stacke skin-flap 295
202 A posterior view of the primary incision. (Diagrammatic) 296
203 The final incision in the modified Stacke meatal flap. (Diagrammatic) 297
204 Meatal skin-flap stitched to temporal fascia above. (Diagrammatic) 298
205 The Körner meatal skin-flap. (Diagrammatic) 299
206 Primary incision in construction of the Neumann modification of the Siebenmann meatal flap 300
207 Completing incision for the Neumann modification of the Siebenmann meatal flap with scissors 301
208 The Neumann modified flap completed. (Diagrammatic) 302
209 The Ballance meatal skin-flap 303
210 A razor, with one flat surface, especially applicable for removing Thiersch's skin grafts 303
211 Mattress suture employed for closure of postauricular mastoid wound 304
212 A mastoid wound closed by mattress sutures and reinforced by interrupted sutures 304
213 The Michel metal clamp suture outfit 304
214 The technique of applying the Michel clamp suture to the postauricular mastoid wound 305
215 The first step in the closure of a postauricular fistula. (Passow-Trautmann method) 305
216 Second step in the Passow-Trautmann operation for closure of a postauricular fistula 306
217 The first row of sutures have been tied, the knots being still visible 306
218 Incision shows U-shaped skin-flap cut from inferior margin of postauricular opening. (Mosetig-Moorhof method) 307
219 Second incision, which releases skin around border of postauricular opening. (Mosetig-Moorhof method) 307
220 The third step. (Mosetig-Moorhof method) 308
221 The final step in the Mosetig-Moorhof operation 308
222 Methods of suturing to be followed in end-to-end anastomosis of nerve trunks. (Schematic) 310
223 Schematic illustration of lateral implantation of anastomosis of nerves 311
224 Schematic illustration of dissection for anastomosis of facial nerve with hypoglossal nerve 312
225 Schematic representation of anastomosis of severed end of facial nerve with hypoglossal nerve by lateral implantation 313
226 The Phillips-Friesner rotation chair 318
227-239 Rotation tests for nystagmus 319-330
240 Mnemonic diagram of the canalicular system of the right side 331
241 Dissection of the temporal bone, with key plate 332
242 Deep dissection of the temporal bone, with key plate 334
243 Author's noise producer 339
244 Bárány's noise producer 340
245, 246, 247, 248, 249 Operation upon the labyrinth. (*Richards.*) (Colored.) Facing 342
250 The modiolus 344
251, 252 Sinus bone specimens 348, 349
253 Radiograph showing purulent invasion of a sigmoid sinus ..... Facing 350
254 *b, c, d, e* Sections from temperature chart of a case of O. M. P. C., complicated with sinus-thrombosis with symptoms of typhoid fever 353, 354, 355
255 Osseous covering (inner cranial table) of lateral sinus excavated from level of jugular bulb upward and backward toward the torcular 359
256 Resection of the jugular vein 361
257 Method advised for incising the dura for purpose of drainage 372
258 Trephine operation upon the temporosphenoidal lobe 373
259 Circular flap over the squama for purpose of trephining the skull 374

FIG. PAGE
260 Section of temporal bone in which thinness of inner (cranial) table and region of tegmen is depicted (Author's specimen) 375
261 Retouched photograph of encapsulated brain abscess. Natural size (*H. P. Mosher*). 376
262 Brain, showing lesion produced by an abscess in the temporosphenoidal lobe (*H. P. Mosher*) 377
263 Exposure of dura of middle cranial fossa by removal of the attic and antrum tegmen 382
264 Spongification of the labyrinthine capsule (*Katz*) 387
265 Spongification of the labyrinthine capsule (*Siebenmann*) 387
266 Tubercle bacillus. (Human type) 409
267 Tubercle bacillus. (Bovine type) 410
268 Extensive lupus vulgaris of the face, nose, mouth, ears and neck. (From collection of *Dr. John A. Fordyce*) 412
269 Lupus vulgaris. (From collection of *Dr. John A. Fordyce*) 416
270 Tuberculous ulceration of the gums. (*Robert Levy.*) (Colored.) ..... Facing 420
271 Tuberculous ulceration of the hard palate, soft palate, uvula and posterior wall of the pharynx. (*Robert Levy.*) (Colored.) ..... Facing 420
272 Tuberculous ulceration of the tongue. (*Dr. J. C. Sharp.*) (Colored.) .. Facing 420
273 Tuberculous ulceration of the tonsils. (*Robert Levy..*) (Colored.) ..... Facing 420
274 Tuberculous infiltration of the epiglottis 424
275 Tuberculous ulceration of the vocal cords 425
276 Krause-Heryng laryngeal cutting forceps 428
277 Killian laryngeal cutting forceps 429
278 Yankauer laryngeal medicine dropper 430
279 Leduc's autoinsufflator 431
280 Primary chancre of the nose. (From collection of *Dr. John A. Fordyce*) 437
281 Gumma of the tongue healing. (*Dr. John A. Fordyce.*) (Colored.) ..... Facing 440
282 Interstitial glossitis. Syphilis 6 years old. (*Dr. John A. Fordyce.*) (Colored.) Facing 440
283 Nasal deformity (saddle-back) resulting from syphilitic necrosis of the nasal and turbinate bones 440
284 Collapse of anterior portion of nose 441
285 Cicatricial adhesion of the soft palate to the posterior pharyngeal wall 442
286 Cicatricial web-formation between the vocal cords 443
287 Diphtheria or Klebs-Loeffler bacilli (*Lenhartz-Brooks*) 450
288 Common, follicular, hemorrhagic, and septic types of diphtheria. (*Fischer*) (Colored.) ..... Facing 452
289 Antitoxin syringe 458
290 Nasal syringing in contagious cases of Riverside Hospital (*Fischer*) 459
291 O'Dwyer's set of intubation instruments 460
292 Mummy bandage, showing child in proper position for dorsal method of intubation (*Fischer*) 461
293 Intubation. First step in operation (*Fischer*) 462
294 Intubation. The tube passing the epiglottis (*Fischer*) 463
295 Casselberry method of feeding (*Fischer*) 464
296 Extubation. First step in operation (*Fischer*) 465
297 Extubation. Second step in operation (*Fischer*) 466
298 A tracheotomy tube 467
299 Lateral view of the tracheotomy tube in position 468
300 Leprosy. (Photograph loaned by *Dr. E. Echeverria*, of Costa Rica) 483
301 The Faught blood-pressure apparatus applied to a patient's arm 489
302 Radiograph illustrating status lymphaticus ..... Facing 492
303 The De Vilbiss hand atomizer 500
304 Fowler's nasal douche 516
305 Postnasal syringe 517
306 The anatomical formation of the nasal septum. (*Deaver.*) ..... Facing 518
307 Septal spur parallel with floor of nasal cavity 523
308 The cone-shaped septal spur situated upon the vomer 523
309 A deflected septum of normal thickness throughout and without spurs or crests .. 524
310 A deflected and thickened septum with a ridge upon each side 524
311 The vertical deflection of the nasal septum 525
312 A diagrammatic representation of the sigmoid or S-shaped deflection 526
313 The Adams forceps for overcoming the resiliency (crushing) of a deflected septum. 528
314 Ballenger's mucosa knife 528
315 Showing the line of incision employed by Hajek, Killian, and Yankauer 528
316 Freer's L-shaped incision for the submucous resection operation 529
317 Perichondrium elevators. *a*, Ballenger's. *b*, Freer's 530
318 Dunning's periosteal elevator 530
319 Small oval curet for penetrating the septal cartilage 530
320 Specimen of septal cartilage removed with the swivel knife 530
321 Mucochondrium separated from both sides of cartilage in accordance with description in text 531
322 The Ballenger swivel knife 531
323 McCoy's straight cutting septal forceps 532
324 Foster-Ballenger's bone-cutting forceps for removing portions of the vomer 532
325 Carter's fenestrated nasal speculum 533
326 Dann's self-retaining nasal speculum 533
327 Killian's submucous speculum 534
328 Submucous hand retractor 534
329 Allen-Heffermann's submucous speculum 534
330 Yankauer's periosteum elevator 535
331 Bone-cutting forceps 535

FIG. PAGE
332 Yankauer's suture needle 536
333 Pierce's submucous dissector 536
334 The crotch-chisel applied to the maxillary ridge 537
335 The Hajek septal chisel 537
336 The Douglas douche bag 538
337 Submucous resection set, containing the models devised by Yankauer and others .. 539
338 Removal of the projecting free border of the septal cartilage 540
339 Septal spur which impinges upon the inferior turbinal 541
340 The Bosworth nasal saw 541
341 The Payne nasal saw 542
342 Simpson's (Berney's) sponge tampon 542
343 Knight's angular scissors 543
344 A perforation of the cartilaginous septum 544
345 Vertical coronal section of the skull, with key plate 547
346 Cystic middle turbinal with a large edematous polypus 549
347 Angular flat applicator 551
548 Grünwald's punch forceps 551
349 The primary incision for the middle turbinotomy 552
350 The Holmes middle turbinal scissors 553
351 The Krause nasal snare 553
352 The snare in position for severing the anterior portion of the middle turbinal ... 554
353 The partial middle turbinal operation, with key plate 555
354 A large sessile hyperplasia (polypoid) removed from the posterior extremity of the inferior turbinal of an asthmatic 557
355 Bilateral posterior hyperplasia (cauliflower) of the inferior turbinals 558
356 The Jackson turbinotomy scissors 559
357 The snare in position for removing a posterior hyperplasia of the inferior turbinal. 560
358 The Mial-turbinal snare 561
359 Partial (anterior) inferior turbinotomy by means of punch forceps 561
360 Partial (anterior) turbinotomy by the combined employment of the punch or scissors and the snare 562
361 The Berens spokeshave 563
362 Various synechiæ (adhesions) observed in nasal cavities 564
363 Front view of a vertical coronal section of the skull on the plane of the second molar teeth, with key plate 567
364 Dissection showing the antral surface of the nasoantral wall and ostium maxillare, with key plate 569
365 The outer or temporal wall of the maxillary antrum, with key plate 571
366 The location of ostium maxillare and exploratory puncture of maxillary antrum .. 574
367 Transillumination of the maxillary antra (antra of Highmore). (Colored.) Facing 574
368 The Coakley transillumination lamp 575
369 Coffin's suction pump apparatus 578
370 Myles's antrum irrigation tube 579
371 Weiner's antrum rasp 579
372 Radical operation for chronic empyema of antrum (*Harmon Smith*) 580
373 Wagener's forward-cutting antrum forceps 581
374 Ostrum's forward-cutting forceps 582
375 First step in the Jansen antrum operation 584
376 Second step (resection of bone) in the Jansen antrum operation 585
377 Orifices of the nasal accessory sinuses. (*Deaver*) ..... Facing 586
378 The abnormally large right frontal sinus. (*Dunning*) ..... Facing 586
379 Same specimen viewed with head tilted slightly backward. (*Dunning*) ... Facing 586
380 Killian's frontal sinus cannula 591
381 Intranasal drainage of the frontal sinus (*Ingals*) 592
382 Transillumination of the right frontal sinus. (Colored.) ..... Facing 592
383 Two photographs of a model constructed to show the effects of changing the position of the tube with reference to the skull (*Caldwell*) 593
384-390 Skiagraphs of frontal sinuses ..... Facing 594
384 Skiagraph shows cloudy appearance in right frontal sinus, ethmoidal cells and maxillary antrum, indicating empyema of these cavities ..... Facing 594
385 Skiagraph shows the nearly symmetrical frontal sinuses containing numerous septa ..... Facing 594
386 Skiagraph shows a very large right and small left frontal sinus, both containing septa ..... Facing 594
387 Skiagraph shows lateral projection and depth of the frontal sinuses ..... Facing 594
388 Skiagraph shows small symmetrical frontal sinuses ..... Facing 594
389 Skiagraph shows total absence of the frontal sinus ..... Facing 594
390 Skiagraph shows slightly asymmetrical sinuses ..... Facing 594
391 Halle's frontal sinus burrs and handle 597
392 Ingals's pilot burr 598
393 Ingals's frontal sinus drainage tube 599
394 Killian's packing forceps 599
395 Killian's operation. First step (*Harmon Smith*) 600
396 Killian's operation. Second step (*Harmon Smith*) 601
397 The Killian protector 602
398 Killian's V-shaped chisel 602
399 Killian's operation. Third step (*Harmon Smith*) ..... Facing 602
400 Killian's operation. Lateral appearance after dividing the head (*Harmon Smith*). 603
401 Brüning's forceps 604
402 Grünwald's sphenoidal forceps 604
403 A complete set of instruments for operating upon the nasal accessory sinuses .. 605

FIG. PAGE
404 Cosmetic results of a Killian frontal sinus and antrum operation upon the left side (Author's case) ... 606
405 Cosmetic results of a Killian frontal sinus operation upon the left side (Author's case) ... 607
406 Left and right sphenoids, chiasm, posterior ethmoid cells, frontal sinuses, internal carotid (*Loeb*) ... 610
407 Left labyrinth, sphenoids, posterior ethmoid cells, optic nerve, trifacial nerve (*Loeb*) ... 617
408 Coffin's right and left ethmoidal forceps. (*a*) ethmoidal chisel ... 618
409 The ethmoid chisel entering the ethmoid labyrinth ... 619
410 The dotted line indicates the position of the chisel within the labyrinth ... 620
411 The forceps engaged in the ethmoidal mass ... 621
412 The completed ethmoidal operation ... 622
413 Mosher's ethmoidal curet ... 622
414 Front view of a slightly slanting coronal section of the skull, with key plate ... 626
415 Probe in sphenoidal sinus ... 628
416 Myles's sphenoidal cannula ... 630
417 Sphenoidal punch forceps ... 631
418 A twisted nose ... 633
419 Dislocation of both nasal bones and transverse deflection of the cartilaginous septum caused by external violence ... 634
420 Smith's paraffin syringe ... 636
421 The paraffin cup ... 637
422 Photograph of a saddle-back nose, the result of external violence ... 638
423 The saddle-back deformity, shown in Fig. 422, corrected by an injection of paraffin ... 639
424 Bridge and intranasal splint for correcting depressed deformities of the nose (*Carter*) ... 640
425 Sectional view of splint and bridge in place (*Carter*) ... 640
426 Mechanics of the intranasal splint and bridge (*Carter*) ... 641
427 Primary incision for dissecting a flap from the floor and septal side of the meatus (*MacKenty*) ... 641
428 Backward dissection across along the floor at the mucocutaneous junction (*MacKenty*) ... 642
429 Flap dissected from the floor of the nostril (*MacKenty*) ... 643
430 Flap sutured to the line of the original incision (*MacKenty*) ... 643
431 A false nose ... 644
432 The Belocq sound ... 645
433 Benefit to be gained by traction rather than by severing the polypoid mass ... 658
434 Large mucous polypus, exact size ... 659
435 Ollier's incision to obtain a wide opening of the nasal cavities ... 663
436 The choanæ ... 666
437 Lateral view of the anatomical conformation of the nose, nasopharynx, pharynx, and larynx (*Deaver*) ... 667
438 The author's flexible cotton carrier ... 669
439 Sessile masses of adenoids in the vault of the pharynx ... 671
440 Group of public school boys who had adenoids and hypertrophied tonsils ... 673
441 Same boys as Nos. 1, 2, 3, of Fig. 440, after operation ... 674
442 The typical adenoid facial expression ... 675
443 Same boy as in Fig. 442, after the removal of adenoids ... 675
444 Group of "mentally defective children with adenoids" ... 676
445 Denhart's mouth-gag with ether tube ... 678
446 Jenning's mouth gag ... 678
447 The Chapin tongue depressor ... 679
448 The Brandegee adenoid forceps ... 679
449 The Stubbs adenoid curet ... 680
450 The Coffin small curved adenoid ring curet ... 680
451 Position of patient, operator, and assistants for removal of adenoids and tonsils under general anesthesia ... 681
452 The Thompson protector for the adenoid curet ... 682
453 Schematic representation of the removal of adenoids by means of the curet ... 682
454 La Force's adenotome ... 682
455 Large adenoid, actual size, showing linear folds and deep depressions ... 683
456 The Hunter sponge holder ... 684
457 Adhesive bands from adenoid mass in connection with Eustachian tubes ... 685
458 The Author's galvanocautery knife for dividing adhesions in the nasopharynx ... 686
459 The Hooper adenoid forceps ... 689
460 Bifid uvula ... 693
461 The McKenzie uvulotome ... 694
462 Edema of the uvula, with small punctures for the removal of serum ... 695
463 Carmine granules passing the epithelium of the tonsil from without, bacteria remaining on the surface. (*Jonathan Wright.*) (Colored.) ... Facing 704
464 The exudate of Vincent's angina upon the tonsil (*Arrowsmith*) ... 709
465 Suitable history for incising peritonsillar abscesses ... 712
466 The general appearancee of a peritonsillar abscess, and the line of incision for its evacuation ... 713
467 Extensive involvement of the pharyngeal walls with Vincent's angina (*Arrowsmith*) ... 714
468 Exudate of Vincent's angina extending over the tonsil, velum, and a portion of the buccal cavities (*Arrowsmith*) ... 715
469 Glandular enlargement and dilated veins which accompany chronic granular pharyngitis ... 721

FIG. PAGE
470 Mayer's pharyngeal curet 722
471 Points for injecting cocaine to induce local anesthesia of the tonsii 727
472 Thomson's tongue depressor 727
473 The Author's tongue depressor devised for the tonsil operation 728
474 Thomson's tenaculum tonsil forceps 728
475 Leland's tonsil separator 729
476 Douglas's tonsil knife 729
477 Wagner's adaptation of the Michel clamp suture for the control of tonsillar hemorrhage 730
478 Primary incision for separating the hypertrophied tonsil from its attachments .. 731
479 The Hurd tonsil separator 732
480 The Moseley tonsil snare 732
481 Hurd's tonsil suction tube 732
482 The tonsil snare applied to the loosened and evulsed tonsil 733
483 Tonsils removed by dissection and snare 734
484 Hartmann's tonsil punch 734
485 Sluder's method for the removal of the faucial tonsils 735
486 Ingersoll's tonsil hemorrhage needle 735
487 Spiral tonsil suture needle 736
488 Rosenheim's tonsil ligature-carrying hemostat 736
489 Hurd's tonsil hemostat 737
490 The Miculicz-Stoerck tonsil hemostat 738
491 Cavity from which tonsil has been removed 739
492 The lingual tonsil and lingual varix 740
493 The Myles lingual tonsillotome 741
494 Large angioma of the uvula removed by the galvanocautery snare 744
495 Unilateral paralysis of the velum palati 748
496 Superior aperture of the larynx (*Deaver*) 752
497 Anterior external structures of the larynx (*Deaver*) 754
498 Posterior external structures of the larynx (*Deaver*) 755
499 View of the internal lateral structures of the larynx (*Deaver*) 756
500 The intratracheal cannula and syringe 757
501 The Hays pharyngoscope and laryngoscope (*Hays*) 760
502 The Tobold concealed laryngeal scarifier 761
503 Edema of the epiglottis and arytenoids relieved by incisions 762
504 Croup kettle or steam inhaler 766
505 Inflamed and thickened vocal cords 771
506 Singer's nodules upon the vocal cords 774
507 Various laryngeal forceps from the models of Fränkel, Scheinmann, Krause, etc. 775
508 Dundas Grant's laryngeal forceps 776
509 Laryngeal forceps in position for severing a papilloma from the vocal cord 782
510 Tuberculous ulceration of the larynx 785
511 The primary T-incision (*MacKenty*) 787
512 The skeletonized larynx (*MacKenty*) 788
513 The divided trachea (*MacKenty*) 789
514 The divided trachea with large rubber tube inserted (*MacKenty*) 790
515 Cadaver representation of larynx divided both below and above and ready to be taken out (*MacKenty*) 791
516 Sutured hypopharynx (*MacKenty*) 792
517 Closed external wound, etc. (*MacKenty.*) 793
518 Trachael cannula and feeding tube adjusted and anchored (*MacKenty*) 794
519 Neck dressings protected by rubber drain (*MacKenty*) 795
520 Device for breathing warm air from around the body (*MacKenty*) 796
521 Dietary chart (*MacKenty*) 797
522 Dietary chart (*MacKenty*) 798
523 Tracheal wound after discarding cannula (*MacKenty*) 799
524 Position of the vocal cords during forced inspiration 804
525 Position of the vocal cords during ordinary inspiration 804
526 Diagrammatic representation of the centers of respiration and phonation in the brain and medulla oblongata and their tracts (*Rethi*) 805
527 Bilateral abductor paralysis during inspiration 807
528 Bilateral abductor paralysis during expiration 807
529 Paralysis of the left abductor as seen during forced inspiration 807
530 Paralysis of the right recurrent laryngeal nerve during inspiration 809
531, 532 Paralysis of the right recurrent laryngeal nerve during phonation 809
533 Cadaveric position of cords in bilateral paralysis of recurrent laryngeal nerve .. 810
534 Bilateral paralysis of recurrent laryngeal nerve during extreme effort to phonate 810
535 Bilateral adductor paralysis of the larynx 810
536 Paralysis of the artenoideus muscle 812
537 Bilateral paralysis of the internal tensors during respiration 812
538 Bilateral paralysis of the internal tensors during phonation 812
539 Bilateral paralysis of the external tensors (cricothyroids) 813
540 Complete bilateral paralysis of the supralaryngeal nerve 813
541 Lynch's suspension apparatus 819
542 New position of head and position of spatula as related to epiglottis and larynx 820
543 Demonstrating hook, tilted to patient's right to remove left tooth plate 822
544 Hook tilted to left to remove right tooth plate 823
545 Elevation of ring, out of way of bronchoscope 824
546 Removal of spatula 825
547 Interior of larynx, showing vocal cords in direct view 826
548 *a*, Papilloma of the vocal cord; *b*, complete removal by dissection 827
549 *a*, Technique of dissection; *b*, nodule forceps in place for vocal nodule removal 828

FIG. PAGE
550 Angiofibroma of vocal cord as seen through suspension laryngoscopy 829
551 *a*, Section of vocal cord showing papilloma; *b*, showing papilloma dissected from under side of cord 830
552 Suspension laryngoscopy instruments 830
553 Chevalier Jackson's laryngoscopes, esophagoscopes and bronchoscopes. This illustration includes the essentials for an ordinary working set of endoscopic instruments. Made by Charles Pilling and Sons 833
554 Jackson's secretion aspirator with plus pressure for cleansing clogged aspirating canals. When portability is not required the Robertson motor aspirator is better 834
555 Jackson's foreign body forceps and other instruments for the removal of foreign bodies 834
556 Chevalier Jackson's laryngeal operating instruments. The illustrations are enlarged about 4 diameters 835
557 Gabriel Tucker's tack and pin forceps. The lower illustration shows the Tucker staple forceps 836
558 Mosher's foreign body forceps 836
559 Mosher's safety-pin closer 837
560 Coolidge's sponge holder. (Modified by *Jackson*) 837
561 Sajous's cotton-holding forceps for preliminary cocainization of the pharynx and larynx 838
562 Direct laryngoscopy, recumbent patient 839
563 Insertion of the bronchoscope. Note direction of the trachea as indicated by the bronchoscope. In the correct position the bite-block is held on the assistant's right index finger, as shown in Fig. 568 840
564 Schema illustrating oral bronchoscopy 841
565 Tracheobronchial tree. (*Jackson* with permission.) 842
566 Skiagraph of a safety-pin embedded in the larynx. (Author's collection.) 842
567 Photoprocess reproduction of a painting by Chevalier Jackson for Saunders' Clinics of North America (Colored) ..... Facing 844
568 Esophagoscopy, "high-low" method, recumbent patient 845
569 Schema for finding the pyriform sinus in the author's method of esophagoscopy. (From Jackson's "Bronchoscopy and Esophagoscopy." W. B. Saunders Co.) 846
570 Esophagoscopy by the Jackson's "high-low" method 847
571 Schematic illustration of Jackson's "high-low" method of esophagoscopy. (From Jackson's "Bronchoscopy and Esophagoscopy," W. B. Saunders Co.) 848
572 Schematic illustration of Jackson's "high-low" method of esophagoscopy, fourth stage. (From Jackson's "Bronchoscopy and Esophagoscopy," W. B. Saunders Co.) 849

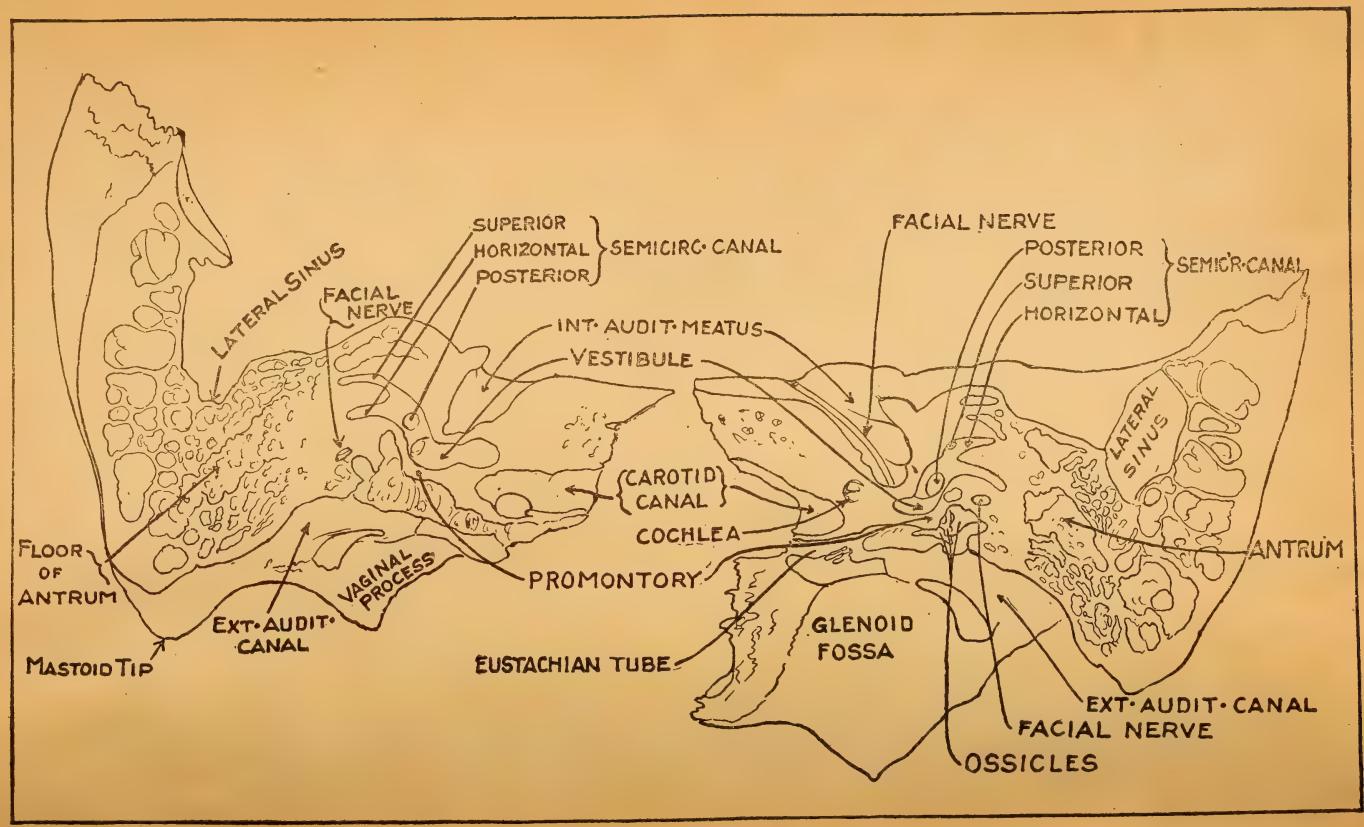

Key plate for Fig. 2.

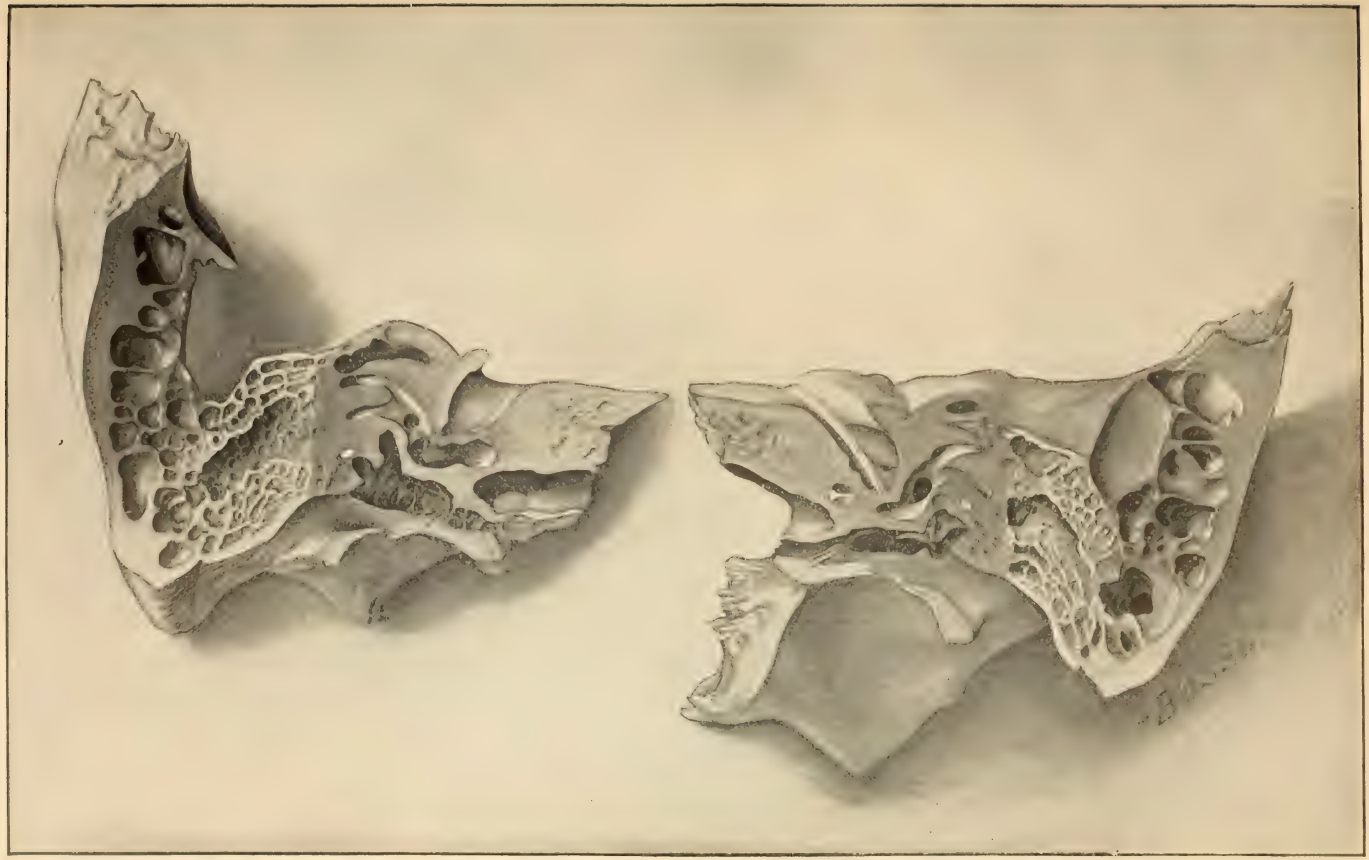

Fig. 2.—Section of the right temporal bone, the two segments of which show important anatomical landmarks. See key plate. (Author's specimen.)

PART I.
The Ear.

SECTION I.
General Considerations.

CHAPTER I.

THE OFFICE EQUIPMENT.

To facilitate the examination and the treatment of patients suffering from diseases of the ear, nose and throat, in harmony with our more modern ideas, a special office equipment is essential. In devising the necessary office paraphernalia the chief considerations are efficiency, simplicity, convenience and cleanliness.

Various general forms of office equipment are in vogue, depending largely upon the individual peculiarities of the surgeon. For the actual treatment of patients most operators employ a corner of the general consulting room; others set apart a special small room known as the "treatment" room. The author prefers the latter arrangement, inasmuch as within a space comparatively small, when this is well utilized, it becomes possible to concentrate all necessary working utensils in a space which can be kept clean.

For those who do not employ office nurses, the treatment room affords additional facilities.

The author's treatment room, one end of which is shown in Fig. 3, measures 5 x 7 feet, and has a side entrance. The floor may be of cement or tile, and the walls of tile at least to the height of five or six feet. For the upper portion of the walls and the ceiling, enamel paint is sufficient. A room of this kind, when equipped with enameled furniture, and scrubbed every morning before the work of the day begins, does not easily become contaminated, hence it is safe for both physician and patient.

It is furthermore possible in such a room to dispense entirely with wooden furnishings, inasmuch as all forms of office paraphernalia are now manufactured in enameled metal, and the danger of infection connected with the more absorbable wood and leather-covered furniture is eliminated. Such a room may be darkened, and thus become valuable for applying the transillumination tests.

The treatment room should contain the following articles of enameled furniture:—

A revolving chair (Fig. 3) with stationary attachment to the wall, if possible, in order to economize floor space; otherwise it may

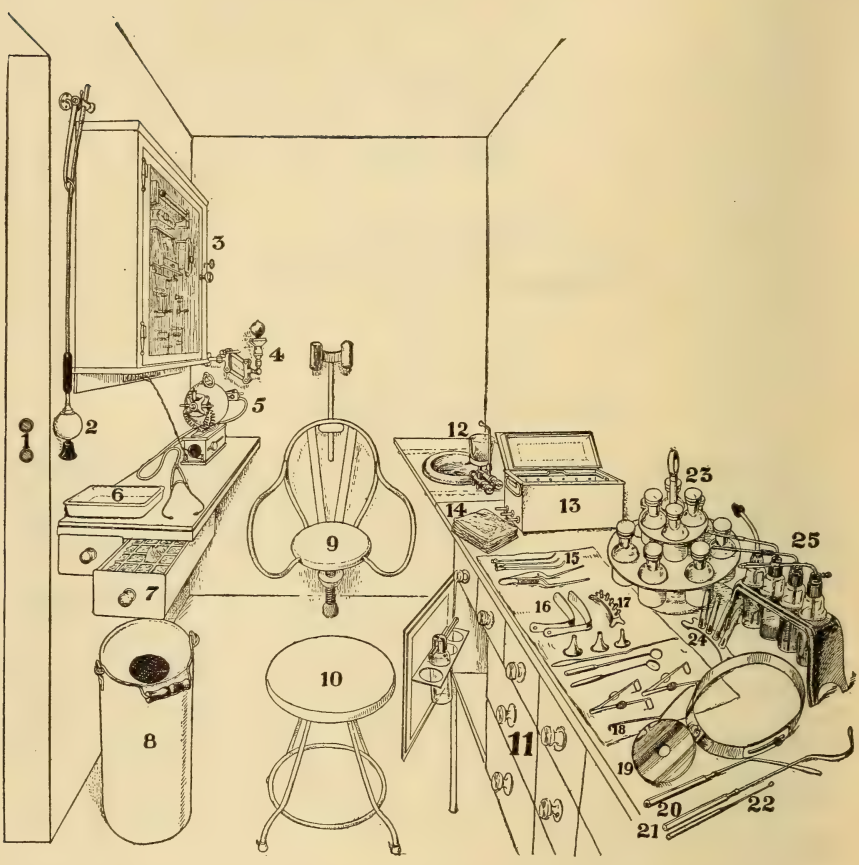

Fig. 3.—Main section of the author's treatment room. 1, Push buttons in jamb of treatment room door. 2, Vibratory massage applicator. 3, Wall electric switchboard. 4, Electric light. 5, Electric motor for galvano-cautery, pump massage and vibratory massage. 6, Enameled receptacle for soiled instruments. 7, Drawer for absorbent cotton. 8, Enameled waste pail. 9, Revolving arm chair with head rest for the patient. 10, Revolving stool for the surgeon. 11, Treatment room cabinet with glass top and drawers. 12, Running water cuspidor. 13, Electric sterilizer. 14, Stack of cheese cloth wipes. 15, Soft silver catheters. 16, Tongue depressors. 17, Sterilized ear tips for otoscope. 18, Hartman's ear probe. 19, Head mirror. 20, Flat-tipped angular applicator. 21, Flexible post-nasal and laryngeal applicator. 22, Sharp ring curet. 23, Medicine bottles and holder. 24, Sterilized glass spray tip covers. 25, De Vilbis atomizers.

rest upon the floor. The preference for the stationary base of attachment is founded upon the patient's tendency to move a chair before seating himself, thus disarranging the relative position of the light to the chair.

The advantages of a chair which revolves are, first, that its height may be changed to conform to the height of the patient,

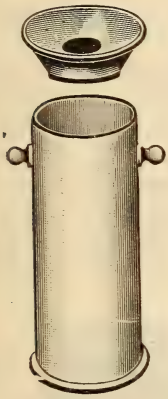

Fig. 4.—Author's enameled waste pail with funnel-shaped cover.

Fig. 5.—Justrite metal receptacle for mastoid and other dressings, with a foot lever attachment.

and, second, that the patient may be easily and quickly turned from side to side for otologic examinations.



Fig. 6.—"Erickson" sterilizing outfit, especially designed for surgeon's office, first aid stations, industrial plants, and emergency and other hospitals.

For the physician a simple revolving stool (Fig. 3) is to be preferred, inasmuch as the revolving motion adds materially to the ease and deftness of his motions. The author claims priority in the use of the revolving seats for both patient and physician.

Cabinet.—Along the side of the room at the operator's right there is a cabinet (Fig. 3) equipped with drawers of various sizes and covered with glass upon which instruments, bottles containing the various solutions for routine treatment, and if necessary a sterilizer may be placed.

It is necessary to have the top of the cabinet about 31 inches from the floor, its width 14 inches and length about 40 inches.

Fountain Cuspidor.—At some point convenient for the use of the patient a running water cuspidor of glass (Fig. 3) should be located and thus all secretions immediately removed from sight.

The waste pail (Figs. 3 and 4) is 19 inches high and 6 inches in diameter, with a funnel-shaped cover into the large opening of which cotton swabs, soiled gauze napkins and other refuse are

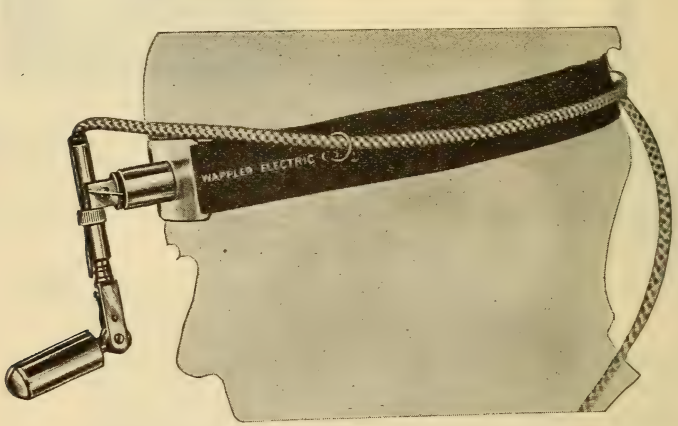

Fig. 7.—Author's electric headlight with focusing device. The light is arranged for use with portable storage batteries or with the street current, the latter requiring the interposition of a suitable rheostat. The focus is adjusted by rotating the metal cylinder.

thrown and thereby removed from sight. This pail is emptied at intervals and scalded with boiling water. Mastoid and other dressings should be deposited in a larger waste pail with a foot attachment for opening and closing (Fig. 5). It is desirable and convenient either in the larger treatment rooms or in a small adjoining toilet room, to have a wash basin with hot and cold running water, and supplied with stiff handbrushes and green soap to be utilized for scrubbing of hands and cleaning of instruments.

Personal cleanliness in its minutest details is an absolute essential in all work upon the ear, the nose and the throat.

It is a wise procedure to lay all sterilized instruments upon the operator's right side and after use upon a patient to deposit them upon a shelf or receptacle (Fig. 3) located at the left side to be resterilized. In this manner the danger of mixing soiled instruments with those that are clean is avoided.

Sterilizers.—A medium-sized sterilizer operated by gas for boiling instruments is reliable, therefore commendable. When an office nurse is employed the main sterilizer may be located in an adjoining room in order to dispense with the considerable heat which it generates. A more complete outfit including arrangements for the sterilization of surgical dressings, gowns, etc., is recommended. Such a sterilizer is shown in Fig. 6, which operates on the same principle as the standard hospital sterilizers. A small electric sterilizer (Fig. 3) located upon the surgeon's cabinet is useful for dipping spray tips, examining mirrors and washing the tongue depressors, nasal specula or other instruments during the treatment of an individual patient. It should in no wise supersede the larger sterilizer.

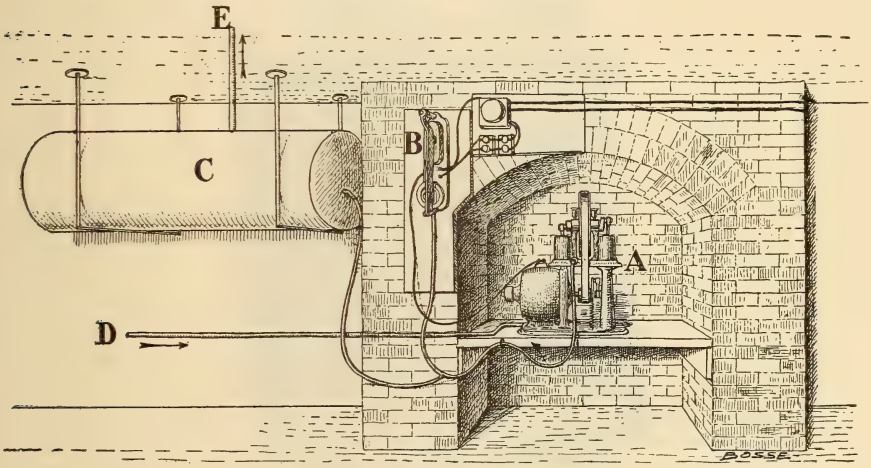

Fig. 8.—Compressed air apparatus. *A,* Electric air pump. *B,* Automatic cut-off. *C,* Galvanized iron air tank. *D,* Piping so arranged that the air used in tank is drawn from out-of-doors. *E,* Outlet to office apparatus.

Illumination.—The examination is conducted by the aid of reflected light controlled by the ordinary head mirror (Fig. 3) or directly by the means of an electric lamp attached to the surgeon's forehead, the former being more convenient and reliable for routine office practice. For reflected light, the source may be a kerosene or gas apparatus equipped with an Argand burner and a condensing lens, or an electric light (Fig. 3) of at least 32 candle power, the globe of which should be of ground glass with the exception of an oval space in direct line with the surgeon's head mirror. The light should be fixed on a movable bracket, so that it may be changed to any position demanded by the height of the patient and the focal distance of the head mirror used by the operator.

The author's headlight with focusing device (Fig. 7) may be used with portable storage batteries or attached to the street current by the interposition of a suitable rheostat. For minor opera-

tions at the patient's house and for major operations upon the ear, the nose and the throat, this form of illumination is invaluable.

Sprays.—Sprays and douches are useful adjuncts to the office equipment and are to be utilized for the proper cleansing of the nasal passages, the accessory sinuses, the ear and the fauces, and for the application of remedial agents to the mucosa and to wounded surfaces.

In the light of our modern knowledge of the etiology of the inflammations of the mucosa of the upper air passages, spray medication holds a minor position as a curative measure; nevertheless it has its value.

The metal spray apparatus of De Vilbiss (Fig. 3) or hard-

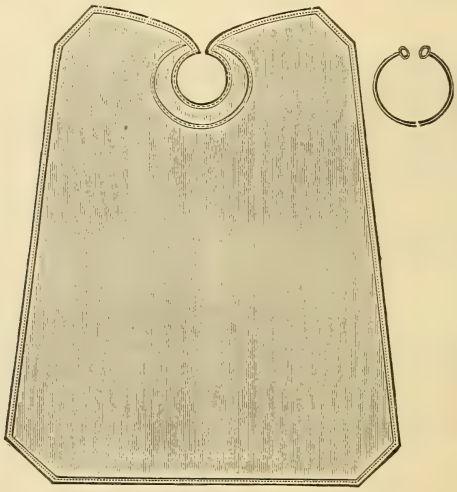

Fig. 9.—Bib for patients. Large cotton protector arranged with a fold which contains a curved wire spring to fit about the patient's neck.

rubber spray outfits of other manufacture are recommended. The tips of these sprays may be sterilized by boiling or the perforated glass spray tip cover devised by Dr. J. J. Thomson may be slipped over the spray while in use (Fig. 3).

Spray solutions are of the following general varieties, viz., cleansing, local anesthesia, hemostatic, medicinal and protective or emollient.

For cleansing purposes the physiological normal salt solution or alkalol and sterile water in equal parts are recommended. They are non-irritating to the mucosa, therefore there is no subsequent prolonged watery discharge like that observed following the employment of sprays containing glycerin or remedies which produce local irritation.

Whenever local anesthesia and ischemia are desired, a solution containing cocaine 2 per cent. and adrenalin chlorid 1:5000, or one of alypin 2 per cent. and adrenalin chlorid 1:5000, may be care-

fully sprayed over the mucous surface, the proportions to be varied according to the requirements.

Of the numerous oil spray solutions two are recommended: first, Dr. O. B. Douglas's formula of benzoinol (see Chapter XXXIII); second, a solution of camphor, 2 per cent., menthol, 2 per cent., in benzoinol. The latter is most efficacious as a remedy for intratracheal injections.

Compressed-air Apparatus (Fig. 8).—This apparatus consists essentially of an electric or a water-compression pump, and some form of tank into which the air is compressed. When much in use a large tank is to be preferred. If desired a smaller auxiliary tank with gauge may be connected with the main reservoir. When the apparatus is located in the cellar the air should be drawn from without, through piping.

Fig. 10.—Author's cotton box. The cylinder is detachable from the base, the latter containing a strong spring which forces the mass of absorbent cotton upward into the wire network at the top.

Instruments.—The routine examination of ear, nose and throat patients requires a liberal armamentarium of instruments with a sufficient number of duplicates to eliminate the delays incident to sterilizing. For convenience it is desirable to have at least a dozen complete sets of those most commonly employed. If fewer are provided it becomes necessary to continuously resterilize during the progress of the day's work. Briefly enumerated the instruments for examination include a cluster of aural specula, two or three types of nasal specula, tongue depressors, nasal and laryngeal applicators, cotton carriers, thumb or angular forceps, laryngeal and postnasal mirrors, small ring curets, Eustachian catheters (Fig. 3), a piston and fountain syringe, a Fowler suction douche (Figs. 48, 49 and 50), pus basins, Dench inflation apparatus (Fig. 24), Politzer bag, auscultation tube (Fig. 24), Seigel pneumatic speculum (Fig. 29), Eustachian bougies (Fig. 28), tuning forks (Fig. 35), acoumeter (Fig. 34), and Galton's whistle (Fig. 36).

A wall cabinet (Fig. 3) equipped with an electric switchboard, current transformers, controllers, etc., supplying currents suitable

for transillumination, electric bougie, galvanic and faradic purposes, etc., is indispensable.

An electric motor (Fig. 3) is useful when equipped with an aural massage pump, a vibrator, a galvanocautery attachment, a drill and a superheated air device. The fact that this motor may be put to so many uses, while it occupies comparatively small space, renders it a most valuable addition to the office armamentarium.

A stack of small gauze or cheesecloth wipes (Fig. 3) folded into a convenient size are well adapted as a substitute for handkerchiefs which are not sterile. The expense involved is small and is well repaid by the endorsement and approval of the patient.

To protect the patient's clothing a bib constructed from a large square of cotton (Fig. 9) hollowed along one edge and folded so as to contain a curved wire-holding device is worthy of notice.

A proper-constructed cotton holder is both a time- and labor-saving device. The author's cotton box (Fig. 10) or his wire-covered drawer (Fig. 3), which is preferable, holds the cotton in such a manner that a small or large piece may be conveniently removed with one hand, whereas small, loose, absorbent cotton requires handling with both hands and several additional manœuvres in order to detach the required segment.

Sterilization and Care of Instruments.—All metal and glass instruments are made sterile by boiling fifteen to twenty minutes in a solution of sodium bicarbonate, about one dram to a pint. Before sterilizing they should be washed in running water in order that all portions of tissue or blood may be removed. Some rubber implements, bougies, etc., which might be injured by boiling, are sterilized by immersion for a considerable time in a 1:20 solution of carbolic acid or a 1:4000 solution of bichlorid of mercury.

Knives may be sterilized by immersing in a tray containing alcohol.

Knives that have become infected by use in pus cases should be sterilized by boiling, notwithstanding the probable deterioration in the temper of the steel.

CHAPTER II.

THE EXAMINATION OF PATIENTS.

History of the Patient.—The permanent history record should be one to which reference can be made at any time with but little difficulty. A card index system carefully maintained is preferable, inasmuch as a 5 x 8 inch history card is convenient and can easily be taken into the treatment room for reference or for recording progress. It should contain a full statement of all essential facts relating to the patient's general condition, date and character of illness and a full outline of the attack for which he seeks relief. The history cards should be filed in numerical order, and cross indexed alphabetically by means of small index cards.

In order to obtain these facts in a concise and comprehensive form it is advisable that a set routine be followed in each case. This is best accomplished by having a printed history card such as is shown in Figs. 12 and 13, which the author has used with satisfaction for many years. Having obtained the name, address, age and occupation of the patient, we pass to his general history, which often proves of considerable value in relation to the specific ailment.

THE EAR.—First inquire about the family history, including hereditary deafness, syphilis, tuberculosis and congenital deafness. The personal history should include a note relating to the diseases of childhood, such as measles, diphtheria, scarlet fever and any attacks of otitic disease. Next we ascertain the history of the present attack, its nature, mode of onset and whether or not the ear is primarily involved. Duration is especially important in chronic purulent infection; likewise the persistency, color and odor of the discharge. Other symptoms to be noted are pain, deafness, tinnitus and vertigo. These may be noted upon the record card by a check sign. If the trouble is non-suppurative in nature or involves the inner ear, we go more fully into the character of the tinnitus or vertigo; whether or not there is paracusis, and ascertain the patient's habits with regard to alcohol and drugs.

NOSE, THROAT AND LARYNX.—What has been said of the general history relating to the ear pertains, in like manner, to the nose, throat and larynx. With regard to the special symptoms, inquiry should be made whether or not there is obstructed nasal breathing through one or both nostrils, whether there is pain referable to the regions of the accessory sinuses, and the character and quality of the nasal discharge, its persistence, color, odor, consistency and the time of the day when it is most profuse. If the history points to an affection of the larynx or throat, the symptoms should be noted, *e.g.,* cough, hoarseness, aphonia, dysphagia and dyspnea.

Physical Examination.—Having learned as much as possible from the statements of the patient, we next come to the physical examination.

Ear.—This includes thorough inspection of the pinna (Fig. 61), noting its general formation, its color, its sensitiveness to touch, and the presence or absence of swelling or cutaneous affections. In examining the external auditory canal and fundus of the ear, the relative positions of the patient and examiner are of importance. If reflected light is used, the source of light should be at least six inches farther back than the patient's head and upon the same level as his ear. The patient's gaze should be directly at right angles to that of the operator, which brings his ear broadside to his view. The introduction of the speculum requires considerable practice before the proper degree of skill is acquired. The upper portion

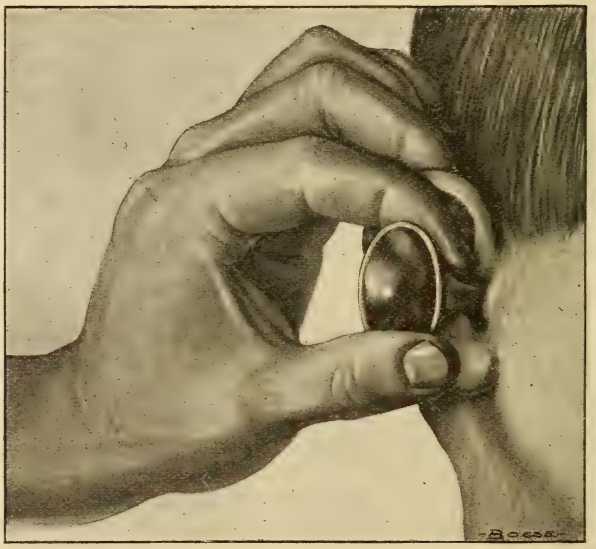

Fig. 11.—Introducing the aural speculum. Showing method of grasping the patient's ear, how to hold the speculum *in situ* and the angle of the patient's head.

of the pinna should be grasped between the second and third fingers and the ear drawn backward and upward, a procedure which tends to straighten the canal and to permit a better view of the fundus, while the speculum is held between the index finger and thumb of the left hand (Fig. 11). The right hand thus remains free for adjusting the head mirror and for the instrumentation incident to the examination and the treatment. The introduction of the speculum never evokes pain unless it is clumsily handled, or when there is some disease of the canal walls. Upon its introduction the canal should be searched for evidences of inflammation, swelling, cutaneous disease, impacted cerumen, exostoses or foreign bodies. The fundus is next observed. It is rarely possible to obtain a complete view of the entire drum at one time except by moving the

CASE NO. | DATE | OCCU.

NAME | ADDRESS | AGE

HISTORY

RIGHT		LEFT
AURICLE	DURATION	AURICLE
MASTOID	IMPAIRED HEARING	MASTOID
CANAL	PAIN	CANAL
RETRACTION	DISCHARGE	RETRACTION
PERFORATION	TINNITUS	PERFORATION
SCLEROSIS	VERTIGO	SCLEROSIS
CONGESTED	PARACUSIS	CONGESTED

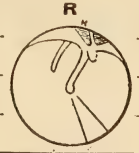

AFTER INFL.	BEFORE INFL.	FUNCTIONAL TESTS	BEFORE INFL.	AFTER INFL.
		VOICE		
		WHISPER		
		WATCH		
		ACOUMETER		
CONDENSATION M.T.	SUCTION M T.	GELLÉ	SUCTION M. T.	CONDENSATION M.T
GALTON	SIEGLE R	WEBER	L SIEGLE	GALTON
A.C. / B.C.		RINNÉ		A.C. / B.C.
O.H. C. C.′ / V.S 128 256	C.″ C.‴ C.⁗ / 512 1024 2048	TUNING FORKS	C. C.′ C.″ / 128 256 512	C.‴ C.⁗ O.H. / 1024 2048 V S.
A.C. 36 18	60 30 20	SCHWABACH	36 18 60	30 20 A.C.
B.C. 18 9	25 14 10		18 9 25	14 10 B.C.

RIGHT		LEFT
	ANT. NARES	
	SEPTUM	
	TURBINATES	
	PHARYNX	
	TONSILS	
	ADENOIDS	
	ANT. PILLAR	
	POST PILLAR	
	NASOPHARYNX	
	EUST. TUBES	
	POST TURBINATES	
	EPIGLOTTIS	
	VOCAL CORDS	
	ARYTENOIDS	

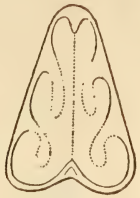

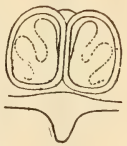

RIGHT | DIAGNOSIS | LEFT

PHILLIPS-NERES

History continued,

Temperature Pulse Resp.

Headache.

Vertigo.

Nausea.

Vomiting.

VESTIBULAR EXAMINATIONS.

Spontaneous Nystagmus. Right Left.

Rotation "

Caloric "

Past Pointing " "

Equilibrium.

Fistula Test

Blood Examination.

Bacteriological Examination.

Ophthalmological Findings.

Pathological Findings.

Diagnosis.

Treatment?

Fig. 13.—Reverse side of Author's history card.

speculum in different directions in order to inspect all the segments, and it is essential that the view be obtained by directing the eye directly through the central opening in the head mirror. Note upon the history chart, and if possible make a rough drawing of the appearance of the drum and ossicles; record the relative position and color of the surrounding structures, whether or not there is secretion, the size, location and general appearance of perforations, and the size and location of polypi and granulations when observed.



Fig. 14.—Sharp's modification of Bosworth's nasal speculum.

In acute purulent otitis media a smear or culture from the pus may be prepared for bacteriological examination.

It is possible to observe the condition of the lining membrane of the tympanum, and also to use a probe for the purpose of detecting uncovered bone through large perforations.

In purulent cases the mastoid process should be inspected for swelling, redness and tenderness to pressure. If the mastoid symp-



Fig. 15.—Author's modification of Bosworth's speculum with solid flaring blades.

toms are positive, the temperature and pulse rate must be ascertained.

Nose, Throat and Larynx.—The first step in the inspection of the nose is anterior rhinoscopy, by which is meant the inspection of the anterior portion of the nasal chambers, by means of reflected light. For the purpose of distending the nasal orifices numerous specula have been devised. Habit has much to do with each individual surgeon as to his favorite type. The author varies the form of speculum to meet the requirements of the nose to be inspected or upon which he intends to operate.

The steel-wire speculum of Bosworth (Fig. 3), made in differ-

ent sizes, is an admirable one for examining both adults and children.

When the vestibule is hairy, it may be necessary to employ a speculum with solid blades. Sharp's modification of Bosworth's (Fig. 14) fulfills the requirement. For operations the author makes use of his large-size modification of Bosworth's nasal speculum (Fig. 15), which flares at the end of the blade, or the one devised by Ingalls (Fig. 16).

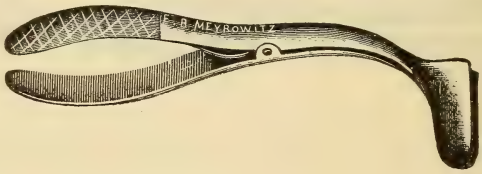

Fig. 16.—Ingalls's nasal speculum.

While making the examination a note should be made of the size of the nasal apertures and the character and location of the secretions. If pus is found, its origin should be sought.

A deeper view will determine the size of the turbinals and the color of the membrane covering them, the presence of septal deflections, spurs, ridges, lesions of the septum or perforations. The view may be interfered with by the presence of mucus or scabs, which may be blown or wiped away. Swellings, polypi or new growths should now be observed. At this point the fuller examination is facilitated by holding aside any soft tissue with a flat



Fig. 17.—Flat wide platinum applicator.

platinum applicator (Fig. 17), or it may become advisable to make an application of a weak solution of adrenalin chloride in order that the behavior of the tissue under its action may be observed. It may be necessary to make an effort to pass a probe into the opening of the maxillary, sphenoid or frontal sinus, a procedure which cannot always be accomplished until after the removal of the major portion of the middle turbinate bone.

Posterior Rhinoscopy.—By this is meant the inspection of the posterior portion of the nasal cavities and of the epi- or rhinopharynx. This is accomplished by reflecting the light on to a small

mirror passed through the mouth, beyond the soft palate (Fig. 18). The tongue of the patient is depressed by a tongue depressor held in the surgeon's left hand, while the mirror is manipulated by his right hand, the patient being instructed to relax the soft palate by attempting to breathe through the nose. Considerable practice is often necessary before a patient is able to submit to posterior rhinoscopy without gagging. In examining nervous patients or those with unusually sensitive throats, it may become necessary to anesthetize the pharynx and soft palate with a 4 per cent. cocaine solution, or draw the soft palate forward by means of a palate

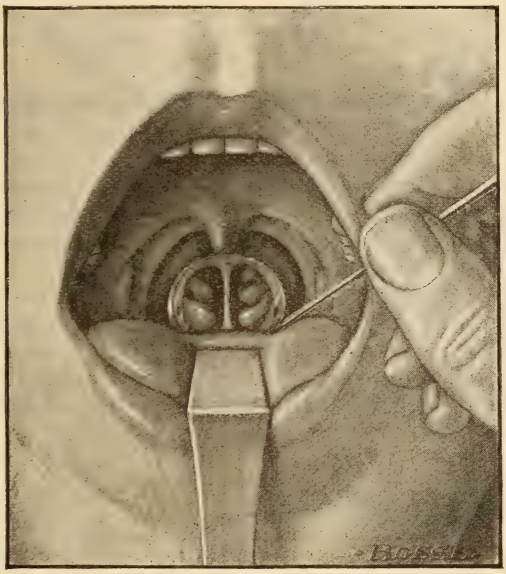

Fig. 18.—Posterior rhinoscopy.

retractor (Fig. 19). Small laryngeal mirrors or Michael's post-nasal mirror (Fig. 20) should be employed.

The office armamentarium should contain tongue depressors of various shapes. The Chapin tongue depressor (Fig. 3) is light, convenient and answers many needs. Glass and wood depressors, the former boilable and the latter to be destroyed after use upon one patient, have their advocates. To properly depress the tongue the mouth should be fully opened, the tongue to lie in its natural position (not protruded) and the depressor when laid firmly upon the dorsum in the median line forces it downward between the rami of the inferior maxillary bone. A good rhinoscopic view of the nasopharynx and postnasal chambers reveals the size of the posterior ends of the turbinals, projecting polypi, or discharges when present and the presence of adenoids or new growths in the nasopharynx.

Fauces and Pharynx.—In examining the oropharynx (Fig. 21), the surgeon should take a bird's-eye view of the gross appearance of the entire area, then observe the condition of the various parts, meanwhile recording abnormalities and diseases when found.

To fully inspect the tonsils it is often necessary to employ a ring curette to search the crypts, or a tenaculum to pull the tonsil well out between the pillars. Any visible tonsil is pathologic, but in some the hypertrophy is extensive and the crypts contain cheesy ephithelial detritus.

The color and thickness of the pharyngeal membrane are mat-

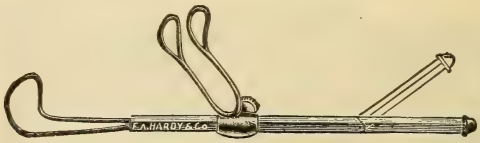

Fig. 19.—White's palate retractor.

ters of importance. Hypertrophied glands upon the postpharyngeal wall (Fig. 469) commonly indicate general lymphatic enlargement of tonsils and adenoids, while atrophic conditions indicate chronic inflammation of the nasopharyngeal mucosa.

The Larynx.—In examining the larynx either direct or indirect laryngoscopy may be employed. By direct laryngoscopy is meant the observation of the larynx through a straight tube inserted beyond the epiglottis, obtaining the illumination either by means of a small electric light situated at the distal end of the

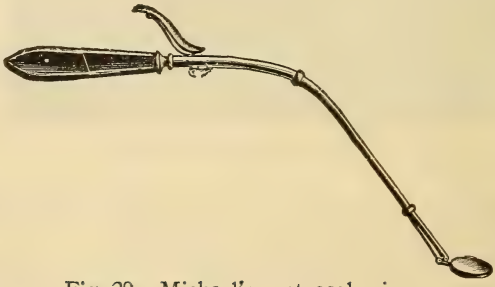

Fig. 20.—Michael's postnasal mirror.

spatula after the manner of Jackson's invention, or by the Killian method, the light being reflected through the tube by means of a Kirstein headlight. By both of these means a direct view not only of the larynx is obtainable, but also of a large portion of the trachea.

The indirect method of examination of the larynx is accomplished by inserting the laryngeal mirror under the soft palate and pressing the entire soft palate upward, the tongue meanwhile being drawn well out of the mouth with a napkin held between the thumb and index finger of the surgeon's left hand (Fig. 22). The

light is now thrown upon the face of the mirror and thus the interior of the larynx may be observed during respiration and phonation. It will be found that during inspiration the cords open widely, but when the patient phonates "A" as in "HA" or "E" as in "HE" the cords approximate in the median line (Fig. 23.) The laryngeal image must be quickly observed, as most patients are intolerant of prolonged manipulation of the larynx. Before introducing a throat mirror it should be warmed over a flame or immersed in hot water. In making laryngeal examinations it is necessary to note the appearance of the epiglottis with regard to its color, position, ulceration or swelling; likewise the arytenoids, aryepiglottidean and glosso-epiglottic folds. Attention is then directed to the laryngeal

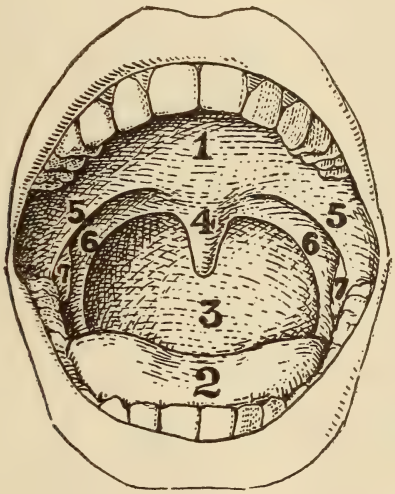

Fig. 21.—Anatomical conformation of the mouth and pharynx. 1, Palate. 2, Tongue. 3, Posterior wall of pharynx. 4, Uvula. 5, Anterior pillars. 6, Posterior pillars. 7, Tonsils.

ventricles and the true and false cords; meanwhile the motility, color and elasticity of the cords are noted, and the presence or absence of nodes, crusts, foreign bodies and new growths is observed. Looking beyond the cords, it is sometimes possible to observe several rings of the trachea and even its bifurcation.

Throat mirrors which admit of boiling are now manufactured, hence they may be kept sterile. A variety of sizes are requisite and numerous angles and bends in the shaft or mirror attachment will be found applicable to the great variety of throats. About five variations in diameter of mirrors (Fig. 3) from half to one inch will suffice.

Recently an instrument has been devised by Hays (Fig. 501), which permits of direct inspection of the entire rhinopharynx and also the larynx, with the patient's mouth closed. The instrument is a cystoscope modified for use in this region and is known as

Hays's pharyngoscope. The light is furnished by two small electric bulbs, and the surgeon's eye placed to the telescope views the inspected field. The invention is quite recent and as yet the instrument has only a value as a diagnostic aid, but is especially useful in examining bedridden persons.

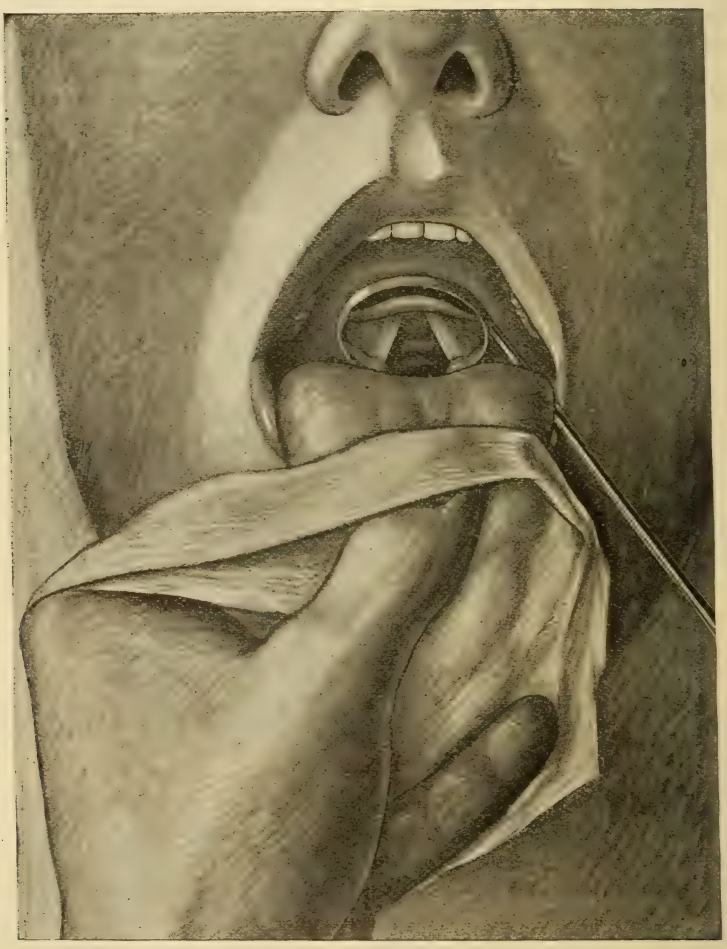

Fig. 22.—The laryngeal picture—cords widely separated.

Additional Information.—In addition to the information thus far obtained by means of inspection, there are other procedures necessary to the complete examination of the ear, nose and throat.

Ear.—Among these may be mentioned inflation of the ears through the Eustachian tube. The chief methods employed for this purpose are Valsalva's, Politzer's and direct inflation by means of the Eustachian catheter.

In Valsalva's method the patient is instructed to firmly grasp the nose between the thumb and forefinger to prevent the escape of air; then with the mouth closed the air is forced from the lungs into the nasal chambers and pharynx. Its normal avenue of escape being shut off, and the Eustachian tubes offering the least resistance, they open and the air rushes into the tympanic cavity.

This method may be conveniently used while the ear is under inspection, and the presence of a perforation can occasionally be detected when otherwise it would escape observation.

In Politzer's method a cone-shaped nose-piece connected to a compressible rubber bag by rubber tubing is fitted snugly into one nostril and the other nostril is closed by the index finger of the physician. The patient is then instructed to freely puff air into his cheeks without allowing it to escape, or he is instructed to perform the act of swallowing either with or without water, or he is told to



Fig. 23.—The laryngeal picture—cords in apposition.

repeat rapidly the letter "K," and while so engaged the surgeon compresses the rubber bag and forces air through the Eustachian tube into the tympanic cavity.

The most efficacious and exact method is Eustachian catheterization. The Eustachian catheter (Fig. 3) should be constructed from pure silver, and be about eight inches in length and the distal end curved sufficiently to rotate snugly into the Eustachian orifice. Opinions vary as to whether the curve should be long and gradual or sharp. The advantage of pure silver in its construction is found in the flexibility of the instrument to meet the variations made necessary by intranasal irregularities and digressions in faucial conformation.

For purposes of diagnosis in the routine treatment of chronic and of some acute affections of the middle ear, catheterization secures the most favorable results (Fig. 24). It is applicable mostly to adults, but even young children often submit to catheterization with good grace. Under favorable circumstances, with wide-open nares, the introduction of the catheter is unpleasant. Furthermore it is a painful procedure in patients whose membranes are hyper-

sensitive, or in those with lesions which obstruct the nose. This should be remembered by the surgeon while manipulating the catheter. A reputation for gentle and painless catheterization brings many loyal allies. When catheterizing for the first time the

Fig. 24.—Proper position of surgeon and patient during catheterization of the Eustachian tube. 1, Catheter in position. 2, Otoscope. (Diagnostic tube.) 3, The Dench middle-ear vaporizer with air douche in surgeon's right hand.

patient's confidence may be gained by making a preliminary application of a mild solution of cocaine and adrenalin chloride along the inferior nasal meatus and the Eustachian orifice. By doing this the tissues are both shrunken and anesthetized, and thus catheterization is made easy. It is not advisable to cocanize all cases as

a routine method. In introducing the catheter the nostril may be dilated with a speculum under reflected illumination, or the tip of the nose elevated with the surgeon's finger. The catheter tip is now slid along the floor of the inferior meatus (Figs. 24, 25, 26, 27), and its shank held in a horizontal position until it passes through the choana and dips toward the nasopharynx. At exactly this point the author ignores the usual rules, rotates the tip outward and upward with slight and gentle manipulation until it engages in the Eustachian orifice; or following the same method of introduction the catheter may be first carried well over into the epipharynx and then drawn forward until it is firmly in contact with

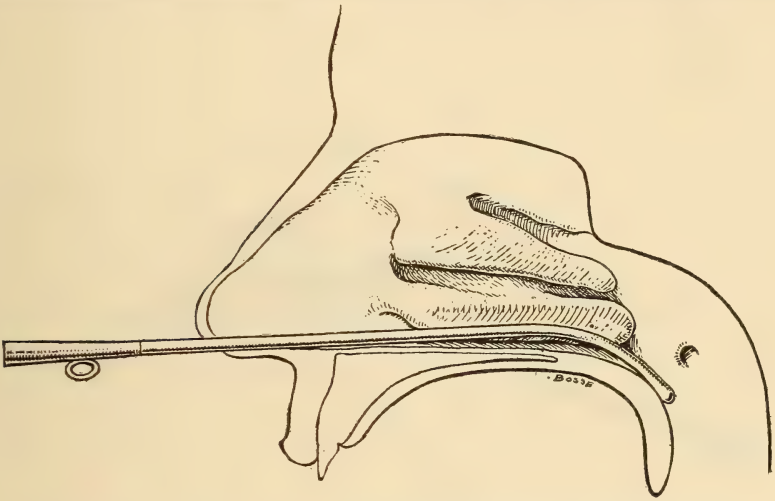

Fig. 25.—Catheter properly introduced along the inferior meatal floor. The catheter is shown as it emerges into the epipharynx and is about to be rotated into the Eustachian orifice.

the posterior aspect of the soft palate, from which point it is rotated outward to little more than a right angle and its point enters the Eustachian orifice.

A favorite method of catheterization with many operators is to rotate the tip of the catheter toward the median line after its point falls into the nasopharynx, then draw it firmly against the posterior border of the septum itself, after which it is rotated outward slightly more than 180°; this usually brings its point in apposition with the pharyngeal orifice of the tube. The catheter having been properly inserted many operators insert the tip of a Politzer air-douche bag directly into the funnel of the catheter and drive a blast of air into the middle ear. The direct contact of the hard-rubber tip of the air-douche bag with the catheter, in spite of the greatest care, usually gives rise to more or less pain, owing to the movement which is imparted to the catheter while squeezing the air douche. In order to avoid this a length of soft-rubber tubing may be interposed between the air bag and the tip which fits into the

catheter, and thus no shock is occasioned when the air douche is squeezed.

The Dench middle-ear vaporizer (Fig. 24) is an admirable apparatus for tubal and tympanic inflation. It consists of a hard-rubber reservoir fitted with a stopcock, the turning of which changes the current of air so that it passes directly to the catheter or is diverted and made to carry medicated vapor from the solution in the reservoir.

In order to determine the patency of the Eustachian tube the diagnostic tube (otoscope) is employed. This is a section of small, soft-rubber tubing about 30 inches long, into each end of which is

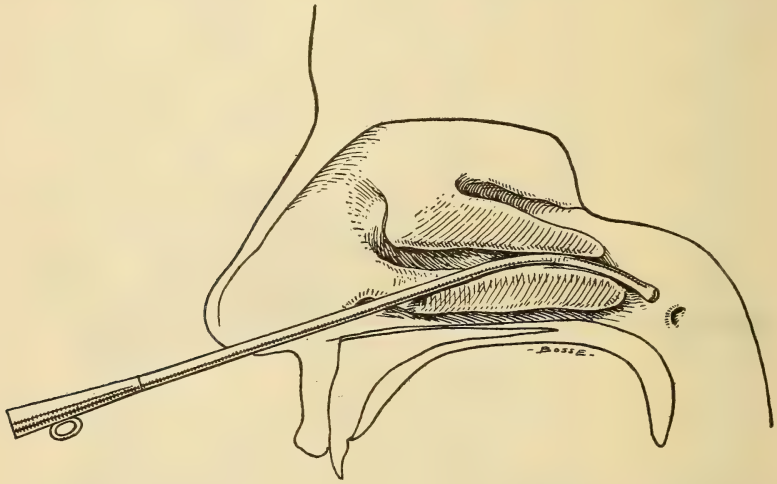

Fig. 26.—Faulty introduction of the Eustachian catheter. The catheter tip has been inserted through the middle meatus, consequently it fails to enter the orifice of the Eustachian tube when rotated.

inserted a conical tip (Fig. 24), one of which is placed in the ear of the patient, the other in the ear of the operator during catheterization. The character of the sound imparted to the ear of the surgeon is of diagnostic value in determining the condition of the Eustachian tube. In a normal tube the current of air produces a low, soft-blowing sound. In stenosis of the tube the note is high-pitched and rough. No sound is conveyed by the otoscope when the stenosis is complete. A tube which contains mucus emits a bubbling sound. When a perforation exists in the drum, the otoscopic bruit felt by the operator is like that of air coming into actual contact with his own tympanic membrane.

Obstacles to Catheterization.—The chief difficulties which arise during catheterization are, first, inability to pass even the smallest catheter through the nasal meatus on account of septal deflections or spurs. When the deformity is small it is often possible to enlarge the space by contracting the soft tissues by applying adrenalin

chlorid; otherwise the surgical removal of the obstruction is indicated.

As a substitute for such emergencies a catheter with a longer curve may be passed through the opposite side of the nose, and turned behind the posterior border of the septum into the affected tube.

An annoying difficulty commonly encountered is the variation in the form, position and prominence of the tubal orifice. These difficulties are overcome by adjusting the curve of the catheter together with skillful manipulation, and, in extreme cases, the rhinopharyngeal mirror allows a visual inspection of the field.

Whenever the Eustachian tube is found to be obstructed, a

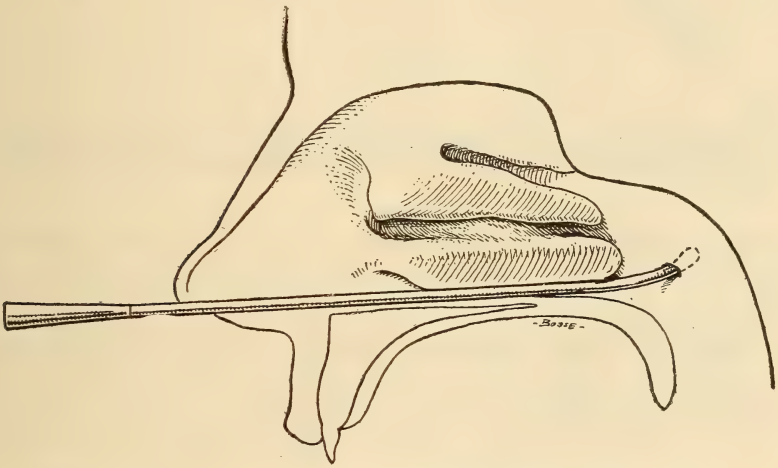

Fig. 27.—Catheter tip in position within the Eustachian orifice.

Eustachian bougie should be passed through the catheter and along the Eustachian tube into the tympanum.

Eustachian bougies are made of celluloid, whalebone or gold, and should be of sufficient length to project at least one and one-half inches beyond the distal opening of the catheter (Fig. 28).

Method of Passing the Bougie.—The catheter is first introduced in the usual manner described for inflation, and air is blown through the tube in order that the patient's statement may be confirmed by the diagnostic tube bruit and its proper position verified. A small-sized bougie is then passed through the catheter until its end comes in contact with the walls of the Eustachian orifice, where it produces a slight sensation of discomfort to the patient. The utmost gentleness must be used in forcing the bougie through the Eustachian tube, in order to prevent the formation of false passages or lacerations of the tubal membrane. If an obstruction is encountered, then gentle continuous pressure usually serves to overcome it. If not overcome after a few seconds of pressure, it is advisable to withdraw the bougie a short distance and make a second attempt.

It is rare to find an obstruction which cannot eventually be overcome. In obstinate cases it may become necessary to employ the electric bougie, perfected by Duel. As the bougie approaches the tympanic cavity the patient usually experiences a bubbling sound. Occasionally the operator is able to see the dark outlines of the bougie through the semitransparent drum membrane. Even in normal Eustachian tubes, slight resistance is usually found when the bougie passes from the membranous to the bony portion of the tube. If care is not exercised in properly adjusting the catheter



Fig. 28.—Eustachian bougie passed through a catheter, and projecting about 1¼ inches (about the length of the Eustachian tube) from the distal end.

before attempting to pass the bougie, the latter instead of engaging the Eustachian tube may pass down along the pharyngeal wall (Fig. 25). Whenever this occurs the catheter immediately rotates downward away from its position in the tubal opening.

Dangers of the Eustachian Bougie.—As before stated, great care must be exercised in order to prevent the formation of false passages or abrasions in the tubal membrane. If inflation is practised after such an accident there is danger of forcing air into the

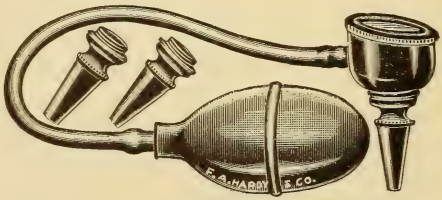

Fig. 29.—Siegel pneumatic speculum.

submucous tissue, and this evokes alarming emphysema. Emphysema from this source is immediately relieved by puncture at any convenient point. The distance traversed by the bougie must be carefully gauged, either by markings or by previous knowledge gained by comparing the proportionate lengths of the bougie and catheter; otherwise the bougie might be forced across the tympanum and made to perforate the drum membrane. Bougies should be inspected at frequent intervals and discarded upon the slightest evidence of weakness at any point, in order to prevent accidental breaking of a small segment while within the lumen of the tube.

Siegel Pneumatic Speculum.—In order to ascertain the mobility of the drum membrane and ossicles a suction or pneumatic speculum is employed. Two well-known varieties are in general use, the Siegel and the Delstanche.

The Siegel speculum is a modification of the usual aural speculum, so constructed that when snugly inserted (Fig. 29) into the aural meatus its interior is rendered air-tight by means of an oblique glass window covering the distal end, through which the movements of the drum may be observed. The speculum is fitted with a compressible rubber bulb attachment which enables the surgeon to exhaust or compress the column of air in the external auditory canal. A lens is sometimes provided which serves to magnify the drum and its landmarks, and gives a clearer view of its mobility. By compressing and relaxing the bulb, the long process of the malleus and the drum are forced fully inward and outward unless they are bound down by adhesions.

The functional tests of hearing are fully described in Chapter IV. For a description of translumination and radiography of the nasal accessory sinuses the reader is referred to Chapters XXXVII and XXXVIII.

CHAPTER III.

THE PHYSIOLOGY OF HEARING.

To better understand the physics of sound production, transmission and perception, we will briefly allude to some of the most authentic laws relating thereto. Sound is a physiological phenomenon or sensation, induced in the mechanism of hearing by the vibratory motion of matter. Any elastic medium is capable of conducting sound vibrations, and their intensity varies inversely as the square of the distance from the ear, not depending on the density of the air in which the sound is heard, but on that in which it is generated. The intensity is directly proportional to the square of the maximum velocity, and also to the square of the amplitude of vibration.

The intensity of sound does not weaken according to the law of inverse squares provided the sound is confined in tubes, inasmuch as the walls of the tubes prevent loss by diffusion.

The velocity of sound depends on the elasticity, density, and somewhat on the molecular structure of the medium through which it is transmitted, and it is directly proportionate to the square root of the elasticity of the air, and inversely proportionate to the square root of the density of the air; hence, velocity is not affected by changes in density if the temperature remains the same, as the elasticity and density vary in the same proportion but act differently. The velocity of sound in water is four times its velocity in air, in iron nineteen times, and in pine wood ten times, because the elasticity of these media is vastly greater in relation to their density than is the elasticity of air in relation to its density. The disturbance of bodies by any form of impact or friction produces vibration in the molecules of such bodies; this results in sound. Variations in the quality or pitch of sound depends upon the regularity and rapidity of the vibrations. If sonorous vibrations are rapid and occur at regular intervals, they are perceived by the normal ear as musical sounds. It has been proven by experiment that less than 16 double vibrations per second are received individually. The rapidity of the vibrations in order to procure musical sounds must be between 16 D.V. and 32,500 D.V. per second. When the vibrations are irregularly repeated, or are below 16 double vibrations per second, the resultant sound is perceived by the ear as a noise. Depending upon the rate of vibration, the note is of low or high pitch, until the vibrations follow each other too rapidly for the ear to perceive them.

The limits of sound perception are called the tone limits of the ear, and range from about 16 double vibrations per second to about 35,500 double vibrations per second. These figures are only approximate, as many ears can distinguish sounds below and above the figures given.

The sound *conducting* or *transmitting apparatus* is that portion of the hearing organ from the concha to the labyrinth.

The perceptive or analytic portion of the organ of hearing consists of that part of the ear extending from the labyrinth to the brain, and includes the labyrinth. Corti's organ, auditory nerve, and the distribution of the auditory nerve fibres to their respective brain centres. It may be remarked in passing that the peri- and endo- lymph circulating in the labyrinth belong to both parts of the hearing apparatus, since these fluids act as agents which assist both in conducting and in receiving wave impulses.

Individual sounds or musical notes, as ordinarily produced, are almost invariably accompanied by overtones of higher pitch which modify the timbre of the fundamental note. Harmonics (overtones) are more noticeable in the lower portions of the musical scale, and this should be remembered as a fact of considerable import in connection with the functional examination of the ear.

We record the various rates of vibration as follows: (C^{-2}, C^{-1}, C, C_1, C_2, C_3, C_4, etc.). This means that C^{-2}, having 32 double vibrations (D.V.) per second, is one octave below C^{-1}, having 64 D.V. per second, and this in turn is an octave below C, which has 128 D.V. per second. Whenever two notes are an octave apart they differ in their rates of vibration in the proportion of two to one. Any one or all portions of the conducting apparatus may become diseased, and it is the purpose of the hearing tests to differentiate, localize and diagnosticate the nature and degree of the lesion.

To illustrate: A sound wave, striking the concha, collected and reflected by its folds, travels through the column of air in the external auditory canal and impinges upon the membrana tympani. This starts a molecular movement in the ossicles, which, in their turn, transmit this impulse to the endolymph, compressing and then rarifying it, sensations which are perceptible at various parts of Corti's organ and interpreted in the remainder of the perceptive apparatus. The impulse thus received is carried, as every impulse received by a specific nerve is carried, to its proper receptive and analytical centre in the brain, and is there recognized as a given *sound*. In order that this physiological function shall be properly carried out it is necessary that the ear in all its parts be normal.

THE SOUND-CONDUCTING APPARATUS.

The Auricle (Pinna).—The functional value of the auricle is that of a collecting appendage—to collect the sound waves—and while its value as such is not very great, it undoubtedly exercises considerable influence in directing the sound waves toward the meatus. This peculiarity is more marked in animals than in man. Of the different depressions in the pinna that of the concha has been proven to have the most important bearing upon the act of hearing.

The acuteness of hearing is slightly influenced by the angle at which the auricle is attached to the head, but the direction from

whence a sound emanates cannot be accurately determined except by binaural hearing. The tragus acts as a reflector for the sound collected and reflected from the concha, and from it the sound caroms into the external auditory meatus. The muscles attached to the human pinna have practically no influence in aiding in the collection of sound waves.

The External Auditory Canal.—The external auditory canal conveys the sound waves to the tympanic membrane. Owing to the exaggerated concavity of the posterior end of the cartilaginous meatus and that of the anterior-inferior portion of the osseous canal, a considerable portion of the sound waves are deflected from their course, and thus do not directly strike the surface of the drum membrane.

Experiments show that the width of the auditory meatus has but slight effect on sound perception. The external auditory canal, like all tubes, has an intrinsic note of its own, but unless the canal is filled with fluid, or its membranes have become much thickened, this intrinsic note is difficult of demonstration, for it lies far above the range of the speaking voice.

The Membrana Tympani.—The drum membrane has two functions. It not only protects the middle ear from atmospheric, mechanical influences and bacterial invasion; but it also acts as a drumhead to receive and transmit sound waves to the ossicular chain. Being only slightly elastic, it is stiff enough to lessen the effect of after-vibrations. Its large size in proportion to that of the stapes footplate is a mechanical advantage for increased power transmission.

Like the auditory canal, its intrinsic note exerts an unappreciable influence upon the sense of hearing, and the drum therefore can receive and transmit simultaneously tones varying in intensity, in pitch and in velocity. A similar principle is observed in the artificially constructed diaphragms such as are used in the Edison and Victor phonographs; the most complicated combinations of sound are simultaneously transmitted.

According to Helmholtz, the funnel shape of the drum increases its power of resonance and mechanically augments the force transmitted to the malleus. Mach and Kessel observed that the greatest excursion of the membrane is obtainable in its posterior segment.

The Ossicles.—The vibrations of the membrana tympani induced by sound waves are now believed to be transmitted to the labyrinth, chiefly through the ossicular chain, although to some extent they reach the labyrinth through the medium of the air contained in the tympanic cavity and the fenestra rotunda.

The experiments of Politzer give considerable weight to his contention that the ossicles vibrate as whole bodies with extensive amplitudes, by the action of the sound waves upon the drum membrane, and that proportionately the amount of vibrations of the ossicles depends largely upon the mechanism of their joints.

By further experiments the same author demonstrated that when the air is condensed in the tympanic cavity a considerable out-

ward excursion of the membrana tympani with the handle of the malleus takes place, and a distinct motion of the articular surfaces of the malleus and incus is visible, while the excursions of the long process of the incus are trifling. Helmholtz emphasizes the importance of the peculiar mechanism of the malleo-incudal articulation, wherein with the inward excursion of the malleus its cog catches that on the body of the incus, forcing the latter to follow in turn. On the other hand, with the outward excursion of the malleus its cog unhooks itself from the incus, thus allowing the former to make a wide excursion outward; meanwhile the incus and stapes move only slightly. This principle serves as a protection against the injurious influences of violent concussions upon the drum membrane, and in like manner shields the labyrinth from excessive intratympanic pressure induced by violent inflation through the Eustachian tube. The relative range of motion attributable to the ossicles is roughly estimated in the following proportions: Stapes 1, incus 2, malleus 4.

Over-vibration of the ossicular chain is prevented, in large measure, by the articular ligaments and by the ligaments and the folds of mucous membrane which connect them with the walls of the tympanum. According to Rieman and Helmholtz, these ligaments and folds and the ossicular muscles maintain the necessary tension between the drum and the ossicles for a uniform reception and conduction of the various sound waves.

Tympanic Muscles.—The mobility of the ossicles is directly modified by two muscles which regulate the degree of tension between the ossicles, drum and labyrinth. The tensor tympani muscle, innervated through a branch of the fifth nerve, is attached to the manubrium, and on contraction draws the ossicles inward and upward, tensifies the drum membrane, crowds together the ossicular articular surfaces, forces the stapes footplate into the oval window and increases the intralabyrinthine pressure.

The stapedius muscle, innervated through the seventh nerve, antagonizes the mechanism described above, since by its traction the drum membrane is relaxed, the stapes footplate is rotated out of the oval window, the incus and malleus are pushed slightly outward against the drum membrane, and the tension in the labyrinth is diminished. Politzer maintains that the chief function of these muscles is to relieve alterations in the position and tension of the ossicular chain, and to protect the labyrinth from sudden condensations or rarifications of the air in the middle ear or external auditory meatus; hence, they regulate the degree of tension of the hearing apparatus.

The Eustachian Tube.—The Eustachian tube is chiefly concerned in the two important functions of (1) ventilation and condensation of atmospheric pressure, and (2) drainage of the middle-ear cavities.

A consideration of the action of the muscles attached to the pharyngeal end of the Eustachian tube is important, for the normal pneumatic balance in the middle ear is dependent on their efficacy as openers of the Eustachian tube. Experiments have conclusively

proven that the walls of the Eustachian tube during quiescence are in the main in contact throughout, and that the act of swallowing is the chief agency by which the air balance of the middle ear is maintained. The tensor palati and the levator palati muscles, both of which are concerned in the act of swallowing, possess the further function of increasing the patency of the Eustachian tube during contraction as a result of their area of attachment to its fibrocartilaginous orifice. When at rest the cartilaginous portion of the tube becomes permeable as a result of even a slight increase in air pressure.

This is especially true if the intratympanic pressure is raised, for the tube permits of air transit toward its pharyngeal mouth with more facility than in the opposite direction (Fowler).

It can be seen readily that the combined action of these muscles greatly increases the calibre of the inner end of the tube, and that the act of deglutition brings this combined action into play as often as it is repeated, so that under normal conditions the air balance in the middle ear is so frequently adjusted that the membrana tympani and middle-ear structures are not disturbed from their normal equilibrium.

Considered pathologically, the permeability of the Eustachian tube is in close relation to the hearing function. Inflammatory swelling and thickening of the tubal mucosa, accumulations of mucus within its calibre, tend to induce rarification of the air contained in the tympanic cavity and consequent retraction of the drum membrane, tinnitus and hardness of hearing.

A partial vacuum may also occur in the middle ear because of nasal obstruction, inasmuch as with this condition combined with deglutition the tube is opened and the air in the nasopharynx becomes rarified, and this rarification necessarily affects the middle ear. Rarification of the air in the middle ear, besides causing congestion and exudation, allows the atmospheric pressure in the external auditory meatus to carry the drum and ossicles inward, and thus the stapes crowds against the oval window.

Fowler has shown, by a series of interesting experiments, that the normal air tension in the middle ear is slightly above atmospheric pressure, especially after each act of swallowing, and he also claims that with each deglutition there is a tensification of the tensor tympani muscle to prevent disturbances in sound transmission and possible trauma to the conducting mechanism.

Fowler's Experiment.—At first sight this may appear to be a modification of Valsalva's or Toynbee's experiment, but as its performance is different from either of these and its results opposite to the latter, it would appear that the experiment is quite distinct.

While the nostrils are tightly closed by pinching them together with the thumb and forefinger as near their free borders as possible, gently increase the air pressure in the nose and nasopharynx by attempting to expire through the nose, and without letting up on this pressure execute the act of swallowing. The result will be the inflation of both middle ears. This is brought about by the

opening of the Eustachian tubes during the increased nasopharyngeal air pressure due to the patient's efforts and to the ascent of the soft palate.

During the second stage of deglutition a negative pressure is avoided because the primary increase in pressure and the bulging of the elastic lateral walls of the nose supply a sufficient amount of air to enable the descent of the soft palate to occur without creating a vacuum in the nasopharynx.

This method is of value because it accomplishes the inflation of the middle ears in a more physiological manner than any method which does not necessitate the use of instruments. In selected cases it may be used by the patient for regular inflation. To remove all possibility of harm Fowler uses a small rubber balloon attached to a nose piece (Fig. 30). If the patient closes one nostril and inserts the nose piece tightly into the other, he can automatically inflate his ears by distending the bag by filling it with air

Fig. 30.—Fowler's middle-ear inflation apparatus.

through his nose and then swallowing several times, or until the balloon has collapsed. The balloons are made of different tensile strengths so that any pressure desired may be brought to act on the Eustachian tubes during the act of swallowing. It is a peculiar property of these balloons that the pressure necessary for their inflation remains almost stationary no matter how fully they are inflated, and likewise during their deflation the pressure does not materially change until the balloon is on the point of collapse.

SOUND-PERCEIVING APPARATUS.

A study of the physiology of the sound-perceiving apparatus or internal ear necessitates a division of this portion of the hearing apparatus into that of: (*a*) the vestibule; (*b*) the semicircular canals; (*c*) the cochlea.

The inward excursion of the footplate of the stapes induced by the sound waves carries a like impulse to the labyrinthine fluid, which becomes displaced in the direction of the round window, which is the point of least resistance, and according to Helmholtz the membrana basilaris of the cochlea is forced in the direction of the scala vestibuli, where it is made extremely tense on account of the resistance encountered at the cochlear apex.

The exact function of the various structures of the labyrinth is not yet fully known, but it may be stated as the general opinion

of physicists that the vestibular apparatus is chiefly instrumental in controlling bodily equilibrium (Fig. 31).

The otoliths are supported in the medium within the utricle and saccule, upon delicate hair-like projections, and, according to Breuer, with each forward movement or inclination of the head they tend to retain their normal position and thus bend the hairs which are their support, thereby inducing the specific sensations in the brain centres, the interpretation of which gives to the individual a conception of the relation of the head to the line of gravity.

The Semicircular Canals.—Contrary to the belief of the earlier writers that the semicircular canals by their peculiar arrangement enable the ear to locate the direction of sound waves, it is now known that they have no influence relating to the perception of sound. On the other hand they constitute the organ of co-ordination of the movements of the body. The tests of Bárány and

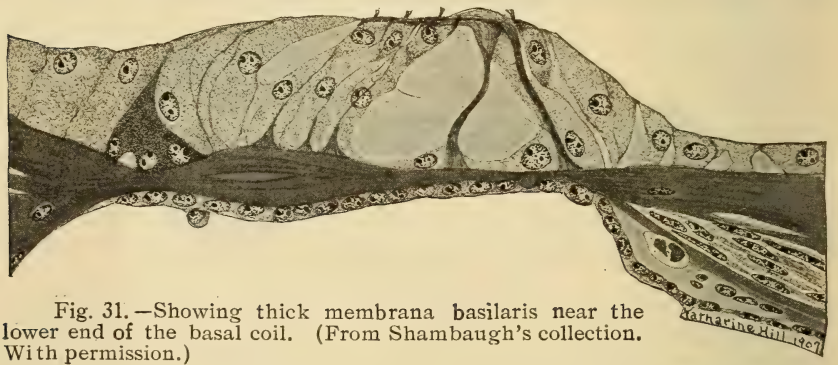

Fig. 31.—Showing thick membrana basilaris near the lower end of the basal coil. (From Shambaugh's collection. With permission.)

others, hereinafter described (see Chapter XXIII), explain more fully the function of the semicircular canals.

Cochlea.—Corti's cells (ciliated), about 2000 in number, are generally believed to constitute the terminal apparatus of the acoustic nerve. The cochlea, therefore, constitutes the organ for the reception and differentiation of sound waves, which are in turn conveyed through the auditory nerve trunk to the cortical centre of hearing. Many investigators believe the latter to be situated in the posterior two-thirds of the first and second temporal convolutions. Upon reaching the acoustic centres the waves are interpreted as sound.

Helmholtz's theory of sound analysis assumes that the basilar membrane of the cochlea contains a considerable number of sounding boards or resonators which are attuned to certain tones. These resonators are set into action by the aqua cotunnii, and the vibrations thus produced are transmitted to the brain as impressions of sound by the nerve fibres corresponding to these sounding boards.

Shambaugh, whose researches in the anatomy of the labyrinth of the ear have given him an intimate acquaintance with the details of the complicated structure to be found in the inner ear, has formu-

lated the following conclusions regarding the physiology of the cochlea:—

1. The end organ in the cochlea, the so-called organ of Corti, is the mechanism whereby the physical impulses of sound waves are transformed into the nerve impulses which result in tone perception.

2. The particular structure of the organ of Corti in which this transformation from a physical to a nerve impulse is accomplished is the hair cell.

3. The stimulation of these hair cells is brought about by an interaction between the projecting hairs and the overhanging membrana tectoria.

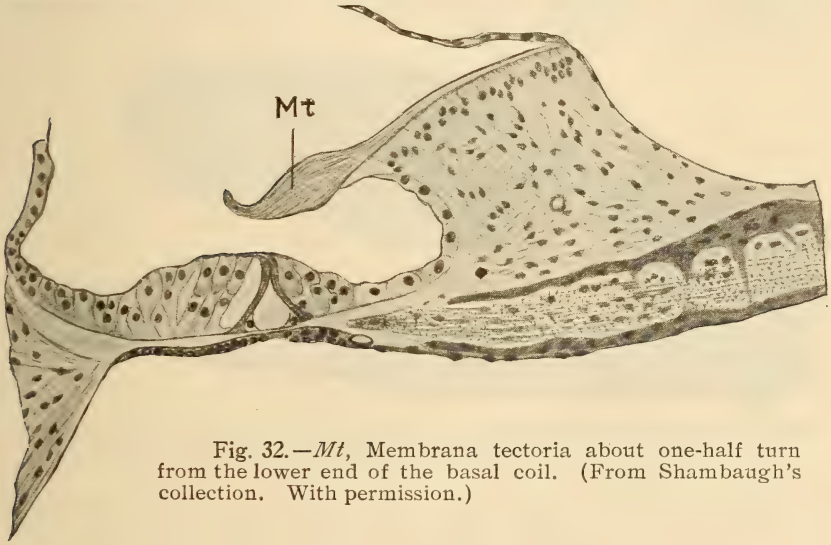

Fig. 32.—*Mt*, Membrana tectoria about one-half turn from the lower end of the basal coil. (From Shambaugh's collection. With permission.)

4. While Helmholtz, and those who have followed him, advocate the hypothesis that the membrana basilaris (Fig. 31) is thrown into vibrations by the impulses of sound waves passing through the fluids in the labyrinth, in this way carrying the hair cells up against the under surface of the membrana tectoria (Fig. 32) and resulting in their stimulation, Shambaugh concludes that the membrana tectoria is the active agent which, by responding to the impulses in the endolymph, vibrates and thus brings about the stimulation of the underlying hair cells.

His reasons for placing the active agent in the membrana tectoria rather than the membrana basilaris are stated as follows: In the first place, the three end organs found in the labyrinth of the ear, the macula acustica in the vestibule, the crista acustica in the semicircular canals, and the organ of Corti in the cochlea, all have a common origin in the primitive otic vesicle. They are all three constructed on exactly the same fundamental plan, consisting of hair-bearing cells and a superimposed epithelial structure. This

overhanging epithelial structure in the macula acustica is the otolith membrane, in the crista acustica it is the cupula, while in the organ of Corti it is the membrana tectoria. Since the stimulation of the hair cells in the macula acustica, as well as in the crista acustica, is brought about by a movement of the superimposed epithelial structure, the otolith membrane and the cupula respectively, it is rational to conclude that the stimulation of the hair cells in the organ of Corti is also brought about by the movements in its superimposed epithelial structure, namely, the membrana tectoria. In the second place, he has found that the membrana basilaris is incapable of performing the rôle of a vibrating structure, attributed to it by Helmholtz and those who have followed him, for the following anatomical reasons: The membrana

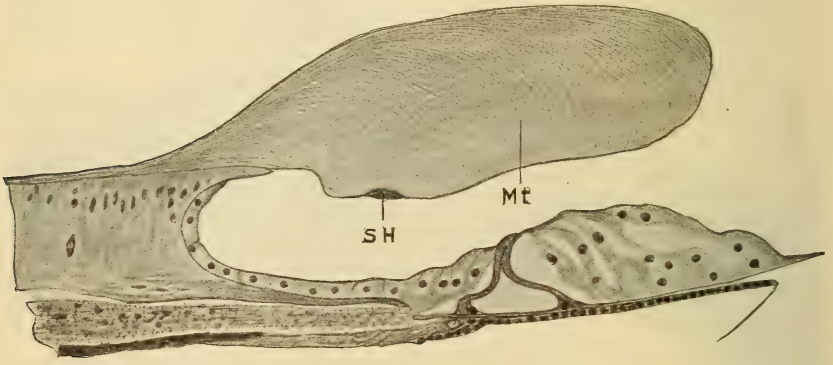

Fig. 33.—*Mt*, membrana tectoria near the apex of the cochlea. *S H*, streifen of Henson. (From Shambaugh's collection. With permission.)

basilaris disappears as a possible vibrating structure near the lower end of the basal coil at a point where the organ of Corti is still found. The radiating fibres of the membrana basilaris toward the lower end of the basal coil, where they are becoming shorter instead of becoming thinner, as they should do in order to fulfill the physical requirements of string resonators, in reality are found to become thicker as the end of the coil is approached. Again, a fundamental principle in the Helmholtz theory is that each radiating fibre of the basilar membrane must always respond to the same tone. This is rendered impossible because of a blood-vessel attached to its under surface, the dilation and contraction of which must cause the several radiating fibres to respond at different times to tones of different pitch. For these fundamental anatomical reasons Shambaugh concludes that the membrana tectoria is not only the logical structure for responding to sound impulses in the endolymph, but that it is anatomically impossible for the membrana basilaris to fill this rôle.

5. The response which the membrana tectoria gives to the impulses of the various tones must be such as to account for the following phenomena connected with tone perception:—

(*a*) The phenomenon of tone analysis, the faculty which the ear possesses of analyzing into its component parts complex tone impulses.

(*b*) The so-called secondary phenomena of tone perception, *i.e.*, beats, summation tones, difference tones, etc.

(*c*) The occurrence of certain pathological phenomena, especially the phenomena of tone islands and of defects in the midst of the tone scale.

6. The only possible action of the membrana tectoria in responding to the impulses from the various tones, that will account plausibly for the above phenomena, is that it responds in different parts of the cochlea (Fig. 33) to tones of different pitch, at the apex for the low tones, toward the base of the cochlea for the tones higher in the scale. Such a response would be in the nature of physical resonance.

CHAPTER IV.

FUNCTIONAL EXAMINATION.

THE TESTS FOR HEARING.

FUNCTIONAL examination, by which is meant the application of the approved methods for testing the hearing, is a procedure of importance in determining the degree of impairment or perversion of hearing. The value of these tests in the realm of diagnosis is to determine the location of pathological changes, and to record the progress of treatment. When other methods of examination give negative diagnostic results, the functional tests usually determine whether the cause of the disturbance of hearing has its seat in the sound-conducting or in the sound-receiving apparatus.

Diminished auditory function due to disease of the sound-conducting mechanism is indicated by a diminution or loss of aërial conduction, together with either normal or accentuated bone conduction. On the other hand, diminished function of the sound-receiving mechanism will be indicated by partial or complete loss of bone conduction and of aërial conduction as well. Unilateral deafness, when due to disease of the conducting apparatus, will show either normal or increased bone conduction, with partial or total loss of aërial conduction upon the diseased side. A description of the various tests will serve to elucidate these statements.

Impairment of the conducting apparatus is characterized by the loss of power to hear the lower tones of the musical scale. Impairment of the receiving apparatus is characterized by loss of power to hear the higher tones of the scale.

The tests are conducted (1) to determine the degree of perception of sound waves carried to the membrana tympani (aërial conduction); (2) to determine the degree of perception of sound waves transmitted to the auditory apparatus through the cranial bones (bone conduction); (3) to enable the examiner by a process of comparisons to localize the lesion and to record the degree of impairment of the hearing function.

The Watch Test.—Watches differ widely in the pitch and intensity of their tones, hence they are inaccurate in results and therefore unsuitable as a routine method of testing the hearing function. When no other means of testing is at hand the watch test should be employed and the results recorded. The record is made as follows: The distance in inches which the watch in use is heard by the normal ear is recorded as the denominator, and the distance heard by the impaired ear as the numerator. If the normal distance should be 40 inches and the patient's hearing distance only 20 inches, the record for the watch would be $^{20}/_{40}$.

The Voice Test.—The chief value of the voice test is to enable the examiner to determine the hearing function for conversation.

In this connection it may be stated that under normal conditions all individuals possess hearing power far in excess of the requirements for ordinary conversation; hence, the diminution of the hearing distance may be considerable and still in no wise affect the individual's conversational capacity. It is commonly observed that the first sign of gradually approaching deafness is the difficulty of comprehending the language of public speakers, or to hear general conversation carried on by a company of individuals. In this connection it may be noted that the vowels are heard more distinctly than the consonants, and that the pitch, timbre, quality and carrying power of individual voices vary widely.

The investigations of Wolf show that the human speech possesses a compass of about eight octaves.

The voice test should be conducted in the following manner: The patient should be placed at one end of the room. The examiner, taking his place at the opposite end, conducts the test. It is recommended that the whispered voice should be employed in all cases except severe forms of deafness for the reason that, as stated by Wolf, this test is more certain inasmuch as ordinarily the volume of tone is thus diminished by the speaker, and the waves of sound reach the ear with much less intensity than in loud speech. The patient is instructed to block off the canal of the opposite ear by pressing the moistened finger tightly into the external meatus. He is further instructed to repeat what he hears and to avoid visual observation of the examiner.

It is further recommended that the examiner establish a definite system of numerals rather than elaborate combinations of vowels and consonants, with sufficient variations to avoid frequent repetition. For instance—the examiner at the end of expiration may whisper the number 58, 44, or 88, gradually approaching the patient and repeating the number until patient hears and repeats it. The distance in feet heard by the patient is then marked in the proper column in the examination chart (Figs. 12, 13). In like manner the opposite ear is then examined, using a different set of numerals.

The Acoumeter Test.—A more accurate and reliable method of testing the hearing is found in using the Politzer acoumeter (Fig. 34), which, when properly constructed, produces a fixed tone of equal pitch and amplitude. Unfortunately the instrument makers do not always construct these instruments according to the rules laid down by Politzer, namely, that all the parts of every instrument should be exactly alike and all give a similar note in pitch and amplitude.

The acoumeter is heard normally at about forty-five feet. If a patient under examination should be able to hear it only six feet, the record should read (hearing for acoumeter equals $^6/_{45}$). If the acoumeter is not heard at all aërially, but is heard on contact, the record for the numerator should be contact + C.

The tone of a properly constructed acoumeter should correspond to C^2, and can be compared to a watch with an extremely loud tick. This tone is mechanically adjusted by drilling out the

cylinder. In cases wherein the acoumeter is not heard by aërial conduction the round metal plate may be attached thereto and placed in close contact with the tissues nearby the external ear, when the tone may be perceived. It is important that the patient's head should be so turned that the sound waves will pass in a direct line from the acoumeter along the external auditory canal. After some experience on the part of the examiner he becomes able to measure the distance heard by the acoumeter with sufficient accuracy, but a more exact system is that wherein the space usually employed for hearing tests is measured off upon the floor or wall.

The ears should be examined separately, and the opposite meatus tightly shut off with the moistened finger during each examination. The test is more accurate when the instrument click is commenced at a distance beyond the range of hearing and gradually moved toward the ear until heard. In some instances



Fig. 34.—Politzer's acoumeter.

it is necessary to cover the eye of the patient during this procedure in order to eliminate the element of imagination.

The perception of sound varies greatly in the same subject, depending upon atmospheric conditions, the state of the mucosa of the upper respiratory tract, and the variations in the physical and psychical condition of the individual. The hearing distance is also materially influenced by extraneous noises of all kinds. These variations are often noted upon examinations at different periods of the same day. Bezold and Politzer noticed that when there is an increase in hearing distance for the acoumeter there would probably be a corresponding increase in perception for speech, but this is not always true for the watch test.

It is commonly observed that a marked difference exists between the perception of speech and that of various musical or clicking sounds. Hence many individuals who exhibit marked defects in the perception of noises other than the human voice are able to converse, even after marked dimness of perception for other noises has become apparent. Unfortunately, the converse is also true. To accurately determine the condition of the auditory function repeated tests must be made, uniform results being necessary for definite and reliable conclusions.

The Tuning-fork Test.—The tuning fork possesses a special

diagnostic value in that by means of it and by comparison of the conducting power of the cranial bones with that through the air, the examiner is enabled to differentiate middle ear from labyrinthine affections. The power of perception of the human ear under normal conditions ranges from 16 to around 30,000 double vibrations per second. These may be recorded as the extreme limits, inasmuch as Howell[1] claims that the majority of adults are unable to perceive vibrations below 24 or above 16,000 per second. The hearing function may become defective either in the lower tones, or, per contra, the higher, or, for that matter, in isolated sections of the scale. Hence it becomes important to record in each instance that portion of the musical scale which has become impaired or defective as a result of disease.

While many authorities consider it important for diagnostic purposes to employ a complete octave series of tuning forks in



Fig. 35.—Set of Hartman's tuning forks.

order to secure absolute accuracy, a series of five forks constructed by Hartmann (Fig. 35) is sufficient, in the majority of cases, to make a fairly accurate diagnosis. Bezold recommends a continuous range of forks constructed by Edelmann, comprising ten tuning forks, two pipes and the Galton whistle (Fig. 36), the forks being equipped with movable clamps for varying the range of tones. For ordinary diagnostic purposes in testing the perception for the middle, the lower, and the upper tones, at least three tuning forks, C, C^2 and C^4 should be employed in each individual case. Whenever the upper tone limit is above the C^4 fork of the Hartmann set the Galton whistle may be substituted.

The tuning fork C^2—512 vibrations per second, corresponding to the middle C of the scale—is the one heard longest by the ear. A difficulty in the use of the fork test is to maintain a standard force to produce the vibrations, inasmuch as the intensity and amplitude depend upon this force. In order to accomplish this, Lucae constructed a fork with a hammer attachment. The Lucae fork is so arranged that by a mechanical device the hammer strikes the fork through the agency of a spring,

[1] American Text-book of Physiology, 1896.

thus causing a uniform striking force and consequently a uniform series of vibrations. The employment of such a fork gives a standard by which comparative results are obtained. The practical and valuable applications of the tuning-fork tests for diagnostic purposes are found in the following tests:—

(*a*) *The Schwabach Test.*—Schwabach observed that when the sound-conducting apparatus becomes impaired as a result of disease or obstruction of the external or middle ear, the vibrating tuning fork is heard with a diminished intensity and for a shorter period of time, aërially, and with an increased intensity and for a longer period of time, by bone conduction. He further observed that both aërial and bone conductions of sound are diminished in diseased conditions of the auditory nerve. The Schwabach test is based on these observations.

In conducting the Schwabach test a comparison of the perception of tone by aërial and by bone conduction is made in the dis-



Fig. 36.—Galton whistle.

eased ear, and the results thus obtained are compared in turn with results from similar tests in the normal ear.

By reference to the author's history chart (Figs. 12, 13) it will be observed that a space is arranged for recording the length of time, in seconds, which the fork is heard by both aërial and by bone conduction for the five forks of the Hartmann series. The numerator represents the aërial conduction, and the denominator that of the bone conduction. For purposes of comparison the figures which represent the normal time perception for each fork in seconds have been given with fair accuracy, these figures having been obtained as the average result of the examination of 100 United States soldiers. (Nichols.)

The test for bone conduction should be made by placing the handle of the vibrating fork directly over the mastoid antrum. A less reliable method of determining the duration of perception of tone is by comparing the time of perception of the patient with that of the examiner. Marked shortening of the duration of tone perception by bone conduction indicates disease of the auditory nerve. Normal or increased duration of perception by bone conduction with diminished aërial conduction indicates diseases of the middle ear, or of the sound-conducting apparatus. Diminution of both aërial and bone conduction of sound indicates disease of the auditory nerve or a combined affection of both the perceptive and the conducting apparatus.

(*b*) *The Rinné Test.*—The Rinné test is based upon the assumption that normally the duration of tone perception through the air exceeds that of the duration of tone perception through the bone. Therefore, if the tone of the vibrating tuning fork is perceived longer when held in front of the ear than when applied to the mastoid process, the result is recorded as a positive Rinné (Fig. 12), and is marked as follows: + Rinné. But when the tuning fork is heard longer when applied to the mastoid process than when it is held in front of the ear, the result is recorded as a "negative Rinné" (— Rinné). The latter may be considered indicative of disease of the sound-conducting apparatus. According to Rinné, in cases of impaired hearing whenever the duration of perception of the tone of the vibrating fork is longer before the ear than through the cranial bones (positive Rinné), we may conclude that the sound-perceiving apparatus is diseased.

While the value of Rinné's test is somewhat limited, it may be employed in order to corroborate conclusions reached from other tests.

(*c*) *The Weber Test.*—Weber found, by placing a vibrating tuning fork upon the skull of a person who had normal hearing, that it would be heard more distinctly or wholly in that ear the external meatus of which was closed or plugged. This phenomenon is believed to be due to amplified resonance within the external auditory canal. The test possesses a marked diagnostic value in unilateral deafness, following out the principle laid down by Weber, viz., that in any case of unilateral deafness it will be found that a vibrating tuning fork (preferably the C^2, 512 D.V.) placed upon the median line of the skull is heard with greater distinctness in the partially deaf ear, whenever the cause of the deafness is situated in the middle or the external ear (sound-conducting apparatus); on the other hand the sound will be heard more distinctly in the sound ear if the cause of deafness is located in the labyrinth—sound-perceiving apparatus. In the first variety, the reinforcement of sound on the diseased side may become so marked that the tuning fork is not perceived at all by the normal ear. In bilateral deafness the tone may be more loudly perceived in the ear most involved.

A positive localization of sound upon the part of the patient gives to this experiment its chief value. In combined affections of the middle ear and labyrinth the Weber test is scarcely available.

(*d*) *The Gellé Test.*—Gellé discovered that compressing the column of air in the external auditory canal diminished the perception of tone. Such compression may be accomplished by means of the Siegel speculum or air bag attached to a tip so shaped as to completely close the external auditory meatus, condensation being made by pressure upon the bulb. Diminution in tone perception results from the increased labyrinthine pressure evoked by an inward movement of the footplate of the stapes. Hence, Gellé's claim that if there is any great obstacle to sound conduction—especially ankylosis of the stapes—the tone remains unchanged during the application of the test, whereas, in labyrinthine affections, with a

movable stapes diminished tone perception obtains with each condensation of air in the external auditory canal.

(*e*) *The Bing Test.*—This test is employed as an aid in differentiating between affections of the middle ear and the labyrinth. Bing observed that, when a tuning fork placed in contact with the mastoid process ceases to be heard, the sound reappears upon tightly closing the orifice of the external auditory canal. In patients with marked deafness if the tone fails to reappear upon closure of the meatus, deafness must be the result of disease of the sound-conducting apparatus, and, conversely, if when there is severe deafness the tone reappears, the deafness must result from disease of the sound-perceiving apparatus (labyrinth).

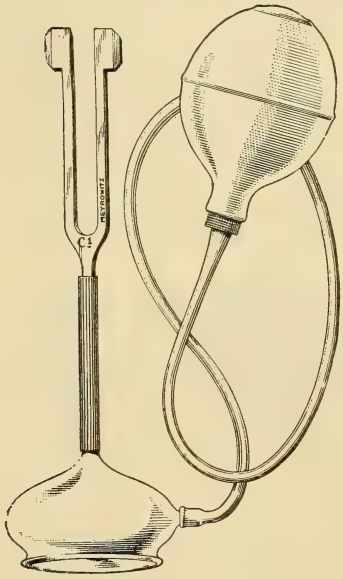

Fig. 37.—Fowler's resonator apparatus.

(*f*) *The Fowler Test.*—Dr. Edmund Prince Fowler, of the author's staff, has devised an apparatus which consists of a glass resonator so constructed that it will inclose the pinna and fit tightly against surrounding skin (Fig. 37). On this resonator is mounted, by means of a stout rubber tubing, a C^1 tuning fork, and, by a nipple on the under side of the bell, the apparatus is connected through rubber tubing to an air bag. Fowler claims that by means of his appliance ossicular ankylosis may be diagnosticated, and especially ankylosis of the stapes footplate. This latter condition is shown if, on air condensation, no diminution in the perception of the fork's note is observed. Malleo-incudal ankylosis exists if on rarefying the air in the external auditory meatus no diminution of sound ensues.

Fowler's test furnishes us with a simple method of obtaining phenomena similar to Gellé's. It is of special advantage in cases of severe deafness, for the fork mounted on a resonator is heard twice as loud and several times as long as a fork in direct contact with the scalp.

(*g*) *The Audiometer Test.*—A new and very promising phase of otology has recently been developed in coöperation with the physicists. This is the accurate testing and graphing of the acuity of hearing by means of machines which are activated by electrical currents. Drs. Dean and Seashore, of Iowa, and Wilson, of Chicago, with Mr. Bunce, have demonstrated several such audiometers. Edmund P. Fowler, M.D., and Mr. R. L. Weigel presented an audiometer (Fig. 38) before the American Otological

Society and the American Laryngological, Rhinological and Otological Society, in Washington, 1922, which is the last word in this line of research. With this instrument it is possible to determine with scientific accuracy the point of minimum audibility throughout a frequency range of eight octaves (from 64 V. D. to 16,000). By specially constructed electrical apparatus and a

Fig. 38.—The Fowler Audiometer.

method of plotting the curves obtainable by use of the instrument, not only is error reduced to a negligible quantity, but other phenomena of diagnostic importance are obtainable. Namely: the quality of hearing at each frequency and intensity, peculiarities of tinnitus, diplocousis and accommodation. The instrument enables us to obtain a definite intensity of sound pressure upon the drum membrane, and throughout the frequency and intensity scales, thereby for the first time furnishing us with an absolutely

accurate method of measuring the acuity of hearing. The method of plotting the graphs is unique in that it gives us readings in a scale of percentage of auditory capacity. The lower limit being the minimum audibility, and the maximum limit being a sound at every frequency at which the sound vibrations are felt. Sounds louder than this are painful. Without a doubt the use of this instrument will advance the knowledge of the acoustics of the ear

Fig. 38*a*.—Audiograph illustrating the shortening of hearing capacity by the method of Fowler and Weigel. This graph is from a case of progressive senile deafness. One of the chief advantages of the method is to furnish a means for accurately charting the progress of deafness at different frequencies.

and correct many misconceptions now entertained by otologists. The instrument is not yet available for general use, but it is the intention of the inventors to procure for the profession an instrument along similar lines which will be reasonable in price and sufficiently accurate for the usual diagnostic purposes.

CHAPTER V.

GENERAL ETIOLOGY OF EAR DISEASES.

THIS chapter is introduced for the express purpose of enumerating and defining, in a general way, the more common causes of aural affections.

ETIOLOGICAL AND DIAGNOSTIC VALUE OF THE BACTERIOLOGY OF EAR DISCHARGES.

Bacteriological investigation of middle-ear discharges when expertly conducted under proper conditions is of much value to the otologist.

The most reliable results are obtained from pure cultures of discharge which have been drawn from the tympanic cavity through an intact drum membrane, by means of a long hypodermic needle, the external auditory canal having been previously sterilized, or when taken from the first gush following a paracentesis.

The tip of the paracentesis knife rubbed upon the culture medium or slide immediately after withdrawal is a fairly trustworthy method of obtaining a portion of intratympanic infection. It is sometimes possible to obtain the primary pathological micro-organism through a mastoid opening in those rare cases where mastoiditis has developed without rupture of the drum membrane.

In chronic otorrhea the bacterial findings are of but little significance on account of the long-continued admixture of micro-organisms from without.

The earlier published reports of bacterial findings in middle-ear discharge are unreliable, inasmuch as smears and cultures were often prepared from pus which had been contaminated with extraneous bacteria.

In smear examinations the order of frequency of the various micro-organisms in the discharges is: The streptococcus, pneumococcus, pyogenic staphylococcus, Friedländer's bacillus, tubercle bacillus, diphtheria bacillus (Klebs-Löffler), influenza bacillus, diplococcus intracellularis meningitidis, typhoid bacillus, the bacillus coli communis, Neisser's gonococcus, Vincent's spirillum and bacillus, and the smegma bacillus. The author has reported one case of the latter variety in which the smegma bacillus was at first mistaken for the tubercle bacillus. The patient developed mastoiditis which required operation.

With the permission of Dr. Jonathan Wright, Director of the Pathological Department of the New York Post-Graduate Hospital, the author is enabled to state that, from the unpublished reports of examination of pure cultures of ear discharges obtained in the manner above described, the streptococcus prevailed in the majority of cases.

Dr. Dixon, of the Pathological Department of the New York Eye and Ear Infirmary, lays stress upon the unusual virulency of the streptococcus capsulatus, and advises early mastoid operations in all cases that do not immediately improve after free drainage has been established through the drum membrane. He and others have remarked that extensive destruction of the middle-ear and mastoid structures mark the invasion of this micro-organism, and very often these pathological changes take place without producing any symptom-complex by which the gravity of their attack is recognized. The fact that the streptococcus sometimes has a capsule is of doubtful significance, inasmuch as the stains employed for demonstrating it are unreliable, and the results are capricious.

The report of Dench[1] fails to verify the observations of Dixon, for out of thirteen cases wherein the streptococcus capsulatus was found only three came to operation.

MODE OF ENTRANCE OF PATHOGENIC BACTERIA INTO THE TYMPANIC CAVITY.

1. In a vast majority of all cases of purulent otitis media the bacteria find entrance through the Eustachian tube. Fortunately the small calibre of the tube and the opposing movements of its ciliated epithelium tend to prevent the entrance of bacteria; otherwise the ratio of intratympanic to intranasal infections would be much larger.

It is more probable that the infection enters the tube under pressure effected by blowing the nose, sneezing, crying, in young children, violent coughing, vomiting, or as a result of inflating by means of the Valsalva-Politzer air douche or catheter. Any deleterious effects arising from sea bathing and the employment of the nasal douche is due to the excessive blowing of the nose which follows, whereby pre-existing bacterial infections in the nasopharynx are forced into the tympanic cavity.

In exhausting diseases like typhoid fever and tuberculosis there is loss of tubal tissue and interference with its muscular and nerve function, thus reducing the normal resistance to the entrance of bacteria.

All forms of both acute and chronic infections of the upper air passages, especially when associated with intranasal obstructions or diseased tonsils and adenoids, favor bacterial invasion of the tympanic cavity.

2. Infection may reach the tympanic cavity through the external auditory canal only when perforation or traumatism of the drum membrane has taken place. Following paracentesis, unless absolute cleanliness of the canal is maintained, secondary infection is almost inevitable, and old unhealed perforations in active suppuration become permanent gateways for secondary infections to enter the tympanic cavity.

---

[1] Transactions of the American Laryngological, Rhinological and Otological Society, 1908, p. 201.

3. It is possible for bacteria to enter the tympanic cavity through the lymph channels and blood-vessels. Barnick has demonstrated this in cases of miliary tuberculosis. Future investigations may show a larger percentage of cases due to infection from the blood and lymph channels, even of pyogenic bacteria, than is now supposed to be the case.

4. Fractures of the temporal bone which communicate with the external world likewise permit the entrance of pathogenic bacteria, with extension by continuity to the tympanic cavity or mastoid cells. In the same manner intracranial infection may find entrance to the tympanic cavity by passing through the labyrinth, facial canal or petrosquamous suture.

THE SIGNIFICANCE OF BACTERIAL FINDINGS IN EAR DISCHARGES.

The external auditory canal contains the same micro-organisms that are found in the surrounding air, and it is the habitat of the forms of bacteria found upon the skin of other parts of the body—chiefly the staphylococcus albus. The tympanic cavity and the labyrinth, however, under normal conditions, have been found to be free from pathogenic micro-organisms.

Micro-organisms found in the discharge from the middle ear are not necessarily the primary pathological agents, especially when studied in the chronic forms, or in the later stages of the acute form. The prevailing micro-organism found in the discharge of the middle ear, when culture has been made from the first discharge, through either paracentesis or spontaneous rupture, may be considered as the pathological agent in the individual case. It is believed that the primary organism in a given case may give way to other forms. Funk is strongly inclined toward the belief that a definite grippal otitis is primarily due to the influenza bacillus, which, however, becomes quickly associated with or displaced by other organisms.

The early stages of acute purulent otitis are usually monobacterial in character; chronic purulent otitis is invariably polybacterial.

The streptococcus pyogenes must be considered the most virulent and destructive to both soft and bony tissues. It is, unfortunately, also the most frequent micro-organism demonstrated in purulent middle-ear disease, while in children the pneumococcus is mostly in evidence. The differentiation of the streptococcus and the pneumococcus in the published reports is of little value, inasmuch as the more recent investigations tend to show that they are variations which under certain conditions are interchangeable. Streptococcus invasions are always rapid, often requiring but a few hours to involve the entire mastoid process.

The pneumococcus is frequently seen. This form of infection while not as virulent as the streptococcus is, on account of its peculiar characteristics, often attended with serious complications.

This peculiarity is the tendency of a pneumococcus infection, wherever located, to heal rapidly, but, during the local healing process, the micro-organisms establish themselves in nearby spaces and set up a new infection, thus giving a series of infected foci, all producing their symptoms without any definite relations regarding time. Thus the tympanic cavity may become healed, even though the mastoid process is still the seat of the pneumococcic invasion.

The staphylococcus is the least active and destructive agent found in purulent otitis media.

Among the author's cases the diplococcus intracellularis meningitidis was observed with considerable frequency. As a type this infection may be considered moderately severe.

The tubercle bacillus is rarely seen in middle-ear discharges, and even when present does not become absolute proof of the tuberculous character of the disease. The presence of the tubercle bacillus in scrapings from the tympanic cavity is more significant, especially when culture methods are employed.

The Klebs-Löffler bacillus in purulent otitic discharge resulting from intranasal or pharyngeal diphtheria is demonstrable. It may be the primary or causal organism, or occur in combination with the streptococcus or pneumococcus; or it may be carried to an ear which is already infected, by means of the fingers or infected instruments.

Suepfle[2] in the study of the ear discharges of 100 cases obtained the streptococcus in 60 per cent., the pneumococcus in 15 per cent., the streptococcus mucosus in 14 per cent., staphylococci in 8 per cent. The pneumococci and streptococci were usually found pure, but the staphylococci rarely so.

His conclusions are as follows:—

1. Otitis media with staphylococcus secretion (these cases look more like tubal disease) will recover.

2. Staphylococcus and pneumococcus infections rarely cause complications.

3. In cases of infection by the streptococcus mucosus the chances are even for recovery with or without operation. The streptococcus mucosus seems to have a deleterious effect upon the bone.

4. The origin, course, and duration of otitis media depend less on the virulence of the infecting organism and more on the general and local diseased processes.

Libman found in 141 examinations of the ear discharges the streptococcus in 88, pure in 79, the pneumococcus in 8, the streptococcus mucosus in 10, and staphylococci in 7. Of these cases there were 5 brain abscesses, the pus from which showed streptococcus 3 times, colon bacillus once, and proteus bacillus once. There were 13 cases of sinus-thrombosis in the same series in which the streptococci occurred 10 times, while in 3 cases no bacteria were present;

---

[2] Centralblatt f. Bacteriologie, Bd. xl.

25 cases of meningitis secondary to otitis media occurred in the same series in which streptococci were found in 13, pneumococci in 4, streptococcus mucosus in 1, pseudoinfluenza bacillus in 1, influenza bacillus 1, colon bacillus 1, tubercle bacillus 1. In the remaining cases the results were negative.

Opinions differ as to whether the mere presence of pathogenic bacteria in the middle ear is sufficient to induce a purulent otitic inflammation unaided by some pre-existing pathological alteration in the mucous membrane.

So far as our present knowledge goes it may be assumed that the effects of micro-organisms, in so far as they relate to various complications of middle-ear suppuration, are modified by the anatomical relations of the parts in which they find themselves, the resisting power of the patient, and probably to some extent by the nature of the pabulum in which they live.

According to Libman, the dangerous and non-dangerous types of infection may be differentiated in the following manner:

1. *Dangerous.*—Purulent aural discharge containing diplococcus intracellularis, streptococcus pyogenes plus abundant leucocytes and myelocytes, also with epithelial elements, "acid-fast" squamæ.

2. *Non-dangerous.*—Staphylococci plus abundant living leucocytes.

3. *Giant Cells.*—Tuberculosis.

Finally, we believe that the information gained from bacterial examinations of the products of the middle-ear infection is of diagnostic value, and its value in the province of etiology, diagnosis and treatment will become augmented in proportion to the perfection of our knowledge, not only of bacteriology, but of the infinitely more interesting and intricate problem of vaccine therapy, at the gateway of which we seem now to be.

A review* of the laboratory records of the Manhattan Eye, Ear and Throat Hospital shows that the cultures from acute mastoids have for the most part contained streptococci. These streptococci have been studied on blood plates and have shown that about 90 per cent. of the cases were hemolytic and 10 per cent. nonhemolytic. These organisms have been further classified or typed according to W. L. Holman's sugar fermentations outlined in the Journal of Medical Research, Vol. 34, No. 3. According to this plan of examination 95 per cent. of all hemolytic streptococcus cases proved to be streptococcus pyogenes, 3 per cent. streptococcus anginosus, 1 per cent. streptococcus hemolyticus II. Of the nonhemolytic streptococcus 97 per cent. were found to be streptococcus mitis, 2 per cent streptococcus salivarius and 1 per cent streptococcus ignavis. In nearly every case, when complicated by sinus thrombosis, septicemia or meningitis, streptococcus pyogenes has been found to be the infecting organism. Nonhemolytic streptococcus mitis was responsible for septicemia in

* Review of the laboratory records of the Manhattan Eye, Ear and Throat Hospital, 1922, for the present (sixth) edition.

two cases and meningitis in one case. A few cases of mastoiditis have occurred wherein the infective organism in pure culture was found to be staphylococci. Two of these cases were complicated with staphylococcus meningitis. Streptococcus mucosus capsulatus was found in ten cases. This type of infection has proved to be quite treacherous in its delayed complications, particularly meningitis and brain abscess, and must be considered one of the most dangerous infections of the mastoid so far as unfavorable complications are concerned. Pneumococcus has rarely been observed in mastoiditis.

Traumatism.—Injuries of the middle ear and labyrinth occur from both direct and indirect violence. The external ear receives its injuries by direct means only.

They occur in the form of (*a*) fractures of the temporal bone and fractures and dislocations of the ossicles; (*b*) wounds and con-

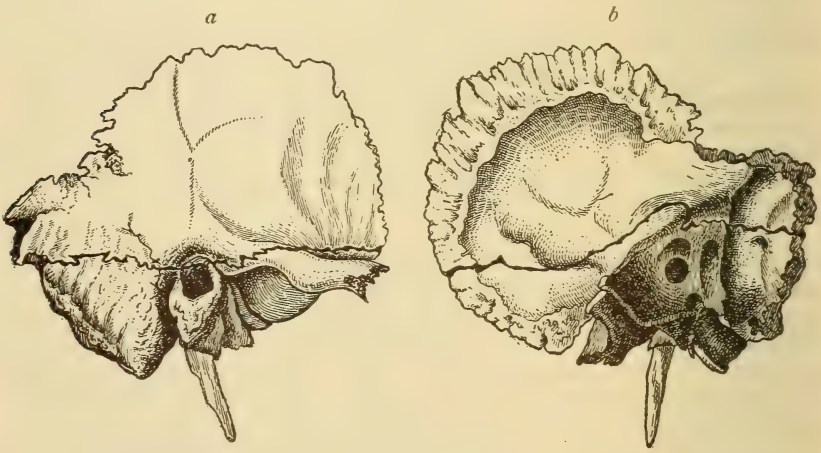

Fig. 39.—Fracture of the temporal bone through the labyrinth. *a*, Parietal surface. *b*, Visceral surface.

tusions of the soft tissues; (*c*) the impact of foreign bodies like bullets, splinters or knife-blades into both soft and bony tissues; (*d*) burns, scalds and escharotics; (*e*) concussion from explosions, loud noises, falls and blows.

Fracture of the temporal bone (Fig. 39) assumes a variety of forms, several of which are attended with most serious consequences to the ear. A fracture of the petrous portion of the temporal bone, which involves the labyrinth usually gives rise to labyrinthine hemorrhage, vertigo, and, in some cases, destruction of the sound-perception function as a result of pressure and inflammation.

If, by any means, a labyrinthine fracture communicates with a purulent ear, or otherwise becomes infected, a purulent labyrinthitis becomes imminent, with a probable extension to the meninges and a fatal termination.

A fracture may extend from the squamous portion through

the bony canal without injury either to the labyrinth or mastoid process. Likewise, it may rupture the membrana tympani and ossicular attachments, and thus open the middle ear.

Compound fractures of the mastoid process are prone to result in purulent mastoiditis, with extension to the middle ear and sometimes with meningeal complications. Any injury to the cranium, which is followed by hemorrhage from the external auditory canal, sudden deafness, vertigo or loss of consciousness, is of serious import.

Labyrinthine concussion from explosions or violence, when unaccompanied by fracture or rupture of the soft tissues may result in vertigo, vomiting, nystagmus and marked impairment of hearing for varying intervals of time. Concussion from "boxing the ear" is often of sufficient force to rupture the drum membrane.

The prominent location of the auricle renders it particularly liable to wounds, contusions, abrasions and other injuries. Contusions of the auricle tend to produce hematomata, abscesses and perichondritis, the latter often resulting in extensive destruction of the cartilage and subsequent deformity.

Stab wounds, bullet wounds, blows or falls produce an infinite variety of injuries both in location and extent, and involve the auricle, the external canal, or, by extending through the membrana tympani, the middle ear becomes exposed to infection from without. The brutal custom of pulling or twisting the ear as a means of punishment commonly results in traumatism along the postero-superior canal wall, and possible rupture or other injury to the drum membrane.

Foreign bodies in the form of splinters, bullets or other projectiles, are prone to lodge in the deeper portions of the ear, viz., the auditory canal walls, tympanic cavity, labyrinth and mastoid. Here they cause serious impairment or destruction of the auditory function, depending upon the location and extent of the injury and the attendant inflammation. Even the Eustachian tube is not exempt from occasional injury. In any form of traumatism there is much to be feared from subsequent infection of the wound.

Burns and scalds are usually accidental but none the less serious. Douching the ear with superheated solutions and the instillation of escharotics in the form of ear drops are the chief sources. Molten lead, hot oil, steam and similar substances produce violent and deep-seated inflammation, with ulceration and destruction of the aural tissues, often terminating in serious impairment of the hearing function, partial or complete occlusion of the external meatus, and deformity of the auricle.

Cold.—The influence of cold in milder forms, notably mild draughts, the introduction of cold water in the external auditory canal from washing or sea bathing, is overestimated by both practitioners and laity as a cause of aural inflammations.

The sudden entrance of cold water in surf bathing or diving may give rise to a slight congestion along the meatus, or even a mild myringitis, but it never produces purulent inflammation of

the middle ear except when a perforation of the drumhead already exists. Neither is it possible to induce middle-ear inflammation by exposure of the auricle to a draught of cold or damp air. Such an exposure in weakened or coddled individuals may induce a general cold from which an otitis may result, but under normal conditions this does not happen. The prevalence of aural infection following surf bathing, diving, etc., is not due to the cold or its effects, but invariably results from the more or less violent efforts to blow the surplus water from the nose and nasopharynx, whereby a portion of the existing infection is forced through the Eustachian tube into the tympanic cavity.

Adenoids.—Postnasal adenoids constitute an obstructive lesion in the nasopharynx and as such interfere with nasal respiration. Furthermore, the irregular corrugated surface of the lymphoid mass favors the growth and retention of pathogenic organisms; hence, they tend to interfere with normal tubal ventilation, and at the same time expose it to infection.

Frostbite is usually confined to the more exposed parts of the auricle, and ordinarily produces circumscribed redness, swelling and dermatitis. When of unusual severity it is characterized by nodular formations, ulcerations and permanent dermatitis, with some gangrenous sloughing of the auricle.

General Diseases.—The aural complications of systemic diseases are fully described in Chapters XXIX, XXX, XXXI and XXXII. These cover a wide range of causes, not only of purulent and catarrhal inflammations, but in some instances deleterious changes in the function of the auditory apparatus.

Heredity and Environment.—The influence of heredity, either through congenital defects in the auditory apparatus, or predisposition to catarrhal or labyrinthine deafness, is common. Deafness, unless congenital, usually commences in the different generations of a family at about the same age. It may skip one or two generations, only to recur in like form. This is especially true of the sclerotic and labyrinthine types. Home surroundings, mode of life and atmospheric conditions are causes of several forms of aural disease. Individuals who are continuously subjected to filth of body and house, vitiated air, insufficient nourishment and clothing, show a tendency to dermatitis of the auricle and external meatus, tuberculous otitis and feeble resistance to any form of inflammatory invasion of the ear.

Atmospheric conditions are deserving of mention. Vitiated air, especially when damp and cold, aggravates all forms of aural diseases, while serious results are experienced by those who are subjected to sudden rarefaction and condensation of the air within the auditory canal and tympanic cavity. Those who work in caissons, climb to high altitudes, or ascend in balloons, suffer from tinnitus, vertigo and deafness. In the caisson work connected with the numerous tunnels now being constructed in and about New York City, many cases of sudden labyrinthine deafness have occurred.

Drugs and Narcotics.—The excessive use of certain drugs, especially quinine, the salicylates, opium, alcohol and tobacco, especially when continued at great length, seriously interferes with the function of hearing, inducing aggravating tinnitus, with possible permanent loss of hearing.

It will be observed that the causative agents herein defined may be grouped under three headings:

(*a*) Those which originate in the nose and nasopharynx and enter the tympanic cavity through the Eustachian tube.

(*b*) Those which originate from without, in the form of traumatism of the soft and bony tissues, concussion, lodgment of foreign bodies, burns, scalds, etc.

(*c*) Those caused from heredity, environment and general systemic diseases.

The Causes of Deafness.—Brief mention is here made of the causes of temporary, partial and permanent deafness.

Hardness of hearing may result from: 1, diseases, obstructions and defects in the external auditory canal, among which are furunculosis (Figs. 67, 68), dermatitis, impacted cerumen (Fig. 69) and other foreign bodies (Figs. 70, 71), exostoses (Fig. 97), and congenital and acquired atresia.

2. Diseases of the membrana tympani in the form of perforations, sclerosis, myringitis, cicatrices and adhesions.

3. Diseases of the tympanum confined chiefly to acute and chronic catarrhs, sclerosis, acute and chronic inflammations (purulent), adhesions, ankylosis of the ossicular chain, congenital defects, caries and otosclerosis.

4. Labyrinthine disease the principal varieties of which are acute inflammation, purulent labyrinthinitis, hemorrhage, traumatism, necrosis, congenital defects, neuroses, tuberculosis and syphilis.

In conclusion, it should be noted that the various etiological factors considered in this chapter furnish the basis for innumerable suits for damages for loss of hearing, wherein the otologist may be called upon for an expert opinion.

CHAPTER VI.

GENERAL SYMPTOMATOLOGY OF EAR DISEASES.

TOTAL DEAFNESS.

(*a*) **Idiopathic Total Deafness.**—Total deafness sometimes occurs in the absence of all anatomical anomalies of the organ of hearing, the auditory nerve or the acoustic centres. Under these circumstances explanation of this loss of function is difficult, inasmuch as most cases of congenital deafness are due to anomalies occurring in some portion of the auditory mechanism. The idiopathic variety of congenital deafness does not always follow directly from generation to generation. The offspring of deaf mutes usually possess the power of hearing, mutism being more common when both parents are congenitally deaf. The deafmutism is prone to recur from time to time in later generations. The children of consanguineous marriages furnish a considerable proportion of all forms of congenital deafness.

Total idiopathic deafness occurs with extreme rarity, but sufficient data have been obtained by postmortem examinations to establish sufficient proof of its occurrence. Mutism from this source is invariably permanent.

Generally defective mental development seems to have no influence upon the function of hearing. As a rule those who suffer from loss of audition are found to be possessed of strong mentality.

(*b*) **Symptomatic Total Deafness.**—By far the larger proportion of cases of total deafness, whether congenital or acquired, exhibit anomalies or pathological defects of the organ of hearing, the auditory nerve or the acoustic centres. In some instances evidences of intra-uterine diseases are observed, and histories of traumatism, sclerosis, purulent inflammation or senile degeneration are common. Anomalies of the organ of hearing furnish a considerable percentage of all cases of congenital total deafness. The congenital absence of certain portions of the conducting apparatus, often associated with deformity of the external ear, is by no means rare—a fact which has been repeatedly demonstrated by postmortem findings. The external meatus may be partially or entirely absent (Fig. 75), but meatal atresia, in this type, should be differentiated from the acquired variety which does not usually occur in early life. The latter results from prolonged purulent inflammation of the middle ear, from exostoses or from traumatism. Any anomaly which permanently occludes the oval or round windows, or which destroys the functional activity of the auditory nerve may result in total deafness. Anomalies of that portion of the central nervous mechanism governing the acoustic centres occur either congenitally or as a result of disease or traumatism. Injuries to the head during childbirth, and rare instances of intra-uterine

disease, such as fetal meningitis or infantile otitis, are occasionally etiological factors.

The acquired variety includes a rather large series of cases resulting from epidemic cerebrospinal meningitis, traumatism and labyrinthine disease. Every epidemic of cerebrospinal meningitis results in a large increase in the proportion of cases of total deafness observed both in hospital and private practice.

Chronic catarrhal otitis media accompanied by extensive otosclerosis which walls off the labyrinth from the tympanic cavity, thus destroying its perceptive function, is a common cause of total deafness.

To this series must be added those cases of total deafness developing in advanced life, explainable on the theory of senile degeneration.

In both the idiopathic and the symptomatic varieties the predominating symptom is the complete absence of all sound perception, including the entire musical scale.

The intracranial lesions of syphilis, whether acquired or hereditary, are rarely of sufficient extent to produce total deafness. The author has observed but one case of this type.

PARTIAL DEAFNESS.

(*a*) **Congenital.**—The congenital form of partial deafness is due to some form of anomaly of the auditory mechanism.

(*b*) **Acquired Partial Deafness.**—Partial deafness, developing after birth, is common, and is due to either intrinsic or extrinsic disease along the auditory tract, or to traumatism. It involves the sound-conducting apparatus, the labyrinth, the acoustic nucleus or the acoustic centres.

Heredity exhibits some marked peculiarities, the onslaught of the disease occurring during the same decade in different generations of one family, whether due to catarrhal inflammation, otosclerosis or labyrinthine disease. The latter variety is more commonly associated with the hereditary tendency.

Symptoms.—The symptoms of partial deafness vary from a slight diminution of normal sound perception to total loss of the hearing function. Hardness of hearing may be limited to certain sounds or groups of sounds, in which event great difficulty is experienced in differentiation, especially ordinary speech and musical tones, while often a slight noise, like the click of the acoumeter or the ticking of a clock, may be readily perceived. The extremely variable behavior of altered function toward rhythmical and nonrhythmical sound waves has been explained as due to some pathological condition located in the sound-conducting portion of the ear, or to an abnormal activity of one of the roots of the auditory nerve. In the presence of rigid labyrinthine windows, speech and other noises are sometimes perceived only as a diffused noise.

Senile deafness presents some definite characteristics, among which may be mentioned the gradual disappearance of sound per-

ception, especially the conduction of sound through the bones. This is probably due to the altered power of bone conduction resulting from senile processes in the bone tissue. According to Bezold, bone conduction in old age is diminished in direct proportion to the general decrease of hearing, the hearing decrease being considered due to senile torpidity of the auditory nerve.

In the acquired forms of partial deafness certain tones are usually more distinctly heard, as a rule the higher pitched noises being the first to disappear. This depends somewhat upon the etiological factors, as well as to whether the deafness is due to defect of the conducting or of the receiving apparatus. Whenever partial deafness has been occasioned by an occupation which has confined the individual to very noisy quarters, the function of hearing differs from that occasioned by ordinary labyrinthine disease. In fact an almost infinite variety of hearing phenomena are observed. Occasionally the sound pitch is different in the two ears. Periodical variations in the degree of deafness are also of common occurrence. They may be of irregular duration, and often depend upon physical conditions, organic disease, or auditory nerve fatigue. Acquired deafness has a marked tendency to matitudinal exacerbations. Postprandial deafness deserves mention, especially when stimulants and tobacco have been indulged in too freely.

The physiological decrease of hearing during the act of yawning is probably explainable upon the theory of muscular inaction. Increase of the hearing is often induced by changes in bodily attitudes, such as stooping, bending of the head, or by alternation in muscular tension.

Intermittent deafness is often a symptom of tubotympanic catarrh. This symptom is also exhibited in hysteria, epilepsy, and vasomotor affections.

The periodical character of certain forms of partial deafness has been observed as accompanying malarial disease, cinchonism being included in this class.

Peculiarities in the functional relationship of the right and left ear to each other are occasionally observed.

It has long been known that in order to locate the origin of sound waves the function of both ears is simultaneously required, the direction being determined chiefly by a comparison of the sensation perceived in both. This function is so perfectly developed as to be well-nigh involuntary. Persons who are suddenly deprived of the hearing in one ear suffer great inconvenience in locating the direction of sound impulses. Politzer has termed this symptom paracusis loci. Victims of this phenomenon usually refer the sound to the more nearly normal ear, which may result in error of sound direction.

Hyperesthesia Acoustica.—A series of phenomena, usually of nerve origin, occasionally give rise to peculiar and often distressing deviations from the normal hearing function. These have been described under various synonyms, according to the peculiarities found in the individual case.

Hyperesthesia acoustica is an apparent abnormal increase in the sense of hearing, especially for certain tones and sounds. There is usually no real increase in the hearing function; an actual diminution may be present. The condition has been observed by Charcot to occur during certain phases of normal sleep and during hypnosis. It occasionally follows chloroform anesthesia, and may accompany the habitual use of morphine. Victims of hysteria, migraine and insomnia are frequently subject to it, in conjunction with a similar state of other special senses, and it may precede the evolution of deafness. Hyperesthesia of the sensory nerves is manifested in increased sensitiveness to sounds, causing painful or otherwise disagreeable reaction to loud noises or tones, especially those of high pitch.

Temporary hyperesthesia acoustica often persists for some time after the removal of an old impediment to sound perception, such as a mass of cerumen from the external auditory canal. The author has observed it in one or two instances following the sudden restoration of hearing subsequent to use of the bougie in overcoming strictures of the Eustachian tube.

In this class of cases the apparent hyperesthesia is the result of sudden restoration of normal hearing function.

Paracusis is a term applied to a variety of perversions of the sense of hearing, the chief of which is

Paracusis Willisii, in which the individual is deaf to speech uttered in silent surroundings, but, on the contrary, he is able to hear perfectly in the presence of loud, extraneous noises like those of underground railways, or the works of machine shops, etc. Occupation is a prominent causative factor, an illustration of the phenomenon being found in the so-called "boilermakers' deafness." It is supposed to result from compression of the labyrinth in the form of otopiesis. There is, however, no unanimous interpretation of this phenomenon, although attempts have been made to explain it on the basis of improved sound conduction through increased vibration *versus* increased sensitiveness to sound through stimulation of the auditory nerve by the more forcible accompanying sound waves.

Diplacusis, or double hearing, may occur in two forms: first, the hyperesthetic, in which the phenomenon is due to abnormal stimulation of the organ of hearing (the perceptive mechanism), the manifestation of which is the acoustic continuation of sound impressions after the sound has really ceased. The second form of diplacusis results from the duplication of sounds upon the basis of delayed or weakened perception in one ear, and often is manifested by hearing a given tone higher in one ear than in the opposite. This condition, known as diplacusiochotica, is usually observed in conjunction with middle-ear disease.

Autophony, or **tympanophony,** is characterized by an abnormal increase of perception of one's own voice, respiration or circulatory impulses, in one or both ears, and is a condition which may accompany a closed as well as a permeable Eustachian tube. Occasion-

ally it arises from a plugging of the external auditory meatus, and it may occur even with normal hearing. The nature of the phenomenon is obscure, but it has been explained as due to the increased resonance of the air column within the ear. Its occurrence is occasionally dependent upon catarrhal inflammation of the nasopharynx.

Acousma.—Auditory hallucinations are physical phenomena in which imaginary voices or sounds are detailed by the patients and persistently believed by them to be real. This symptom is sometimes the earliest indication of perverted mentality.

A case observed by the author was that of a woman of 35 years, who resided within hearing distance of the trains running over a steam railway. She persisted in her belief that she could hear the ceaseless rumbling of a train, even when she was in the examination room. Other hallucinations gradually developed. We must reckon with this symptom in making functional ear examinations.

Vertigo.—The generally accepted theory of physicists that the semicircular canals with their ampullæ are important factors in the control of the equilibrium of the body is explanatory of the frequency and significance of vertigo as a symptom in aural affections.

Clinical experience is in harmony with this theory to the extent that labyrinthine pressure, oticodinia and irritation, whether extrinsic or intrinsic, may induce attacks of vertigo, of varying intensity and duration.

When of intrinsic origin, the chief exciting causes are infection, anemia, hyperemia, meningitis, traumatism, gummata or granulations, usually with but sometimes without hemorrhagic, serous or pus exudate.

In all forms of labyrinthine disease, vertigo is one of the most constant symptoms. Extrinsically, it is induced chiefly by the transmission of impulses, through the conducting apparatus or by the pressure of impacted cerumen upon the drum membrane or by intratympanic fluids, whether in the form of blood, serum or pus. It is further induced by gummata and other tumors and granulations, and by fixation of the stapes from hyperplasia or otosclerosis. The air douche during catheterization, and the water douche, either by pressure transmitted from the drum membrane, or directly to the oval window through large perforations, may give rise to vertigo, which subsides only upon the cessation of the exciting cause. Nausea may accompany the attack. Occasionally catheterization has to be discontinued on this account. When induced by the water douche it is somewhat influenced by the temperature of the water employed, and when severe the douche temperature should be varied until little or no vertigo results. As a rule, there is less when the temperature is high; hence, it is well in all cases to commence with a temperature of at least 110°.

Some patients, who on account of vertigo are unable to endure the douche in the upright posture, complain but little when it is

employed while reclining, and it seems to be somewhat less when the suction douche (Fig. 50) is employed.

In a small percentage of cases it is quite impossible to use the water douche under any circumstances, the vertigo being so severe as to result in alarming nausea, vomiting and even loss of consciousness. Here its use is obviously contraindicated. Vertigo is an occasional symptom in purulent otitis media, and also in both acute and chronic mastoiditis. In these affections it may appear as a result of pressure of pent-up pus upon the labyrinth; nevertheless, it should invariably arouse suspicion of labyrinthine involvement, especially when accompanied by nystagmus. It is of a more serious import in chronic purulent otitic affections.

Otitic vertigo may be rotary (the most common form) in which the sensation is that of whirling round and round toward either the right or left; or the tendency may be to fall directly forward, backward or in a lateral direction.

The vertigo may be either objective, in which surrounding objects seem to move, or subjective, wherein the patient's body seems to be whirling or falling.

More commonly it occurs in the upright posture, but whenever present in the recumbent posture it is invariably severe, continuous and persistent. Such patients commonly remark that the bed seems to be floating away, leaving them to sink lower and lower. In all cases etiological differentiation is important, inasmuch as otitic vertigo should not be confounded with the toxic, cerebral, ocular, gastric, hepatic or laryngeal types. The above symptoms are of importance in keeping case records.

Ménière's Symptom-complex.—Ménière's symptom-complex, often designated Ménière's disease, is characterized by a marked sudden disturbance of hearing, invariably accompanied by three typical symptoms, viz., vertigo, tinnitus, nausea and vomiting. Of these the first named is the most pronounced. The attacks may be short or long, frequent or infrequent, and often terminate in an apoplectiform seizure minus loss of consciousness. In purely labyrinthine cases the symptoms persist with exacerbations and remissions until deafness is total and the nerve destroyed. Locomotion is temporarily interfered with as a result of the accompanying vertigo, and persistent disturbance of hearing in one or both ears is usually present. One attack predisposes to another, and recurrence is common, each attack subjecting the patient to the danger of further loss of hearing. Vertigo, nausea, tinnitus and sudden deafness sometimes result from labyrinthine traumatism. Here they are temporary, and should be differentiated from Ménière's disease, in which they result from a combination of pathological processes. It has also been observed that tinnitus and deafness arising from middle-ear disease may accompany a simultaneous cerebellar affection, with its symptoms of vertigo, nausea and vomiting. An extension of pathological processes from the ear to the central nervous system, or *vice versâ*, may also occur in cerebrospinal meningitis, with resultant symptoms of vertigo, nausea and

tinnitus. In the cerebrospinal meningitis of infants and young children there are additional differentiating symptoms of, first, fever and headache; second, a condition of stupor, developing during the course of the disease.

Deafness resulting from cerebrospinal meningitis is common, and, when total, the hearing rarely returns. Partial deafness due to the same disease often improves spontaneously, or as a result of internal medication. The recovery of speech is aided by methodical hearing and speaking exercises.

Deafness following Ménière's symptom-complex may be total or partial, or limited to certain sounds.

The component symptoms manifest themselves at the same time, but it is quite possible for a single symptom to precede the general attack, or for the series to develop successively. In some instances an aura may precede the attack.

The duration and frequency of the attacks are extremely variable. Etiologically, the evolution of these symptoms is due to primary disease or reflex excitation of the auditory nerve or the acoustic centres in the brain, the cerebral centres which determine the act of nausea and vomiting, and co-ordination. The symptoms are, as a rule, reflex, generally by way of the middle ear; more rarely, however, they result from disease of either the labyrinth or of the central nervous system.

PAIN (OTALGIA).

As a general symptom, referable to the ear or its surroundings, pain is usually due either to inflammatory conditions involving these parts, or to purely nervous or reflex manifestations.

Inflammatory Pain. (*a*) **Pain in the Pinna.**—The prominence of the pinna (Fig. 61) and its exposed location render it extremely liable to traumatism, while, on account of its rather meagre nerve supply, the various injuries to which it is subjected do not, as a rule, evoke severe pain. Even injuries which involve the cartilage, examples of which are frequently observed in prizefighters and boxers and described in their vernacular as the "cauliflower ear" (Fig. 66), in which hematomata develop between the layers of cartilage, are not attended by severe pain. On the other hand, phlegmonous inflammations and herpes (Fig. 65) do give rise to considerable pain of a burning character. Under these conditions, whenever the swelling involves the anterior and more unyielding plane of the pinna, more pain is experienced than when the posterior aspect is involved, wherein the tissues are relatively looser and more yielding to the inflammatory infiltrate. Primary carcinoma of the auricle is attended with excruciating pain.

(*b*) **Pain in the External Auditory Meatus.**—Traumatism involving the external meatus, on account of the resultant inflammation and infiltration, gives rise to severe pain, especially when the swelling is of sufficient severity to cause pressure.

Pain becomes an early symptom of external otitis, and varies

in intensity with the severity of the inflammatory process. It is the chief symptom of the early stages of furunculosis of the external auditory canal, being aggravated by the introduction of instruments, or by attempts to move the pinna. When attended with swelling or edema of the parts, the painful condition becomes aggravated by acts of mastication, yawning, and even by speaking.

The pressure of a foreign body and in rare instances impacted cerumen causes otodynia.

(*c*) **Pain in the Tympanic Membrane.**—In simple inflammations involving the membrana tympani, such as myringitis, slight pain may result, insufficient pressure being present to give rise to severe pain. Parasites deposited upon or penetrating the drum membrane have been known to cause severe pain. Traumatism, either direct or from concussions, causes pain, especially when sufficient to give rise to ecchymosis or rupture. An intense pain is produced during the act of injury to the drum.

The tympanum is sensitive to touch or instrumental interference, and following instrumentation pain may continue for some time.

(*d*) **Pain in the Tympanic Cavity, the Eustachian Tube, the Head and the Neck.**—Simple inflammations involving the tympanic cavity and its accessories are usually characterized by the presence of pain, the exception being tuberculous or syphilitic involvement. On the other hand, the more severe purulent inflammations are attended by severe, lancinating and almost unbearable pain, which is usually definitely located within the confines of the middle ear. Patients are prone to indicate the location by pointing the index finger directly toward the external meatus. Some radiation of the pain is occasionally manifest.

Caries involving the tympanic walls or adjacent bony structures is sometimes characterized by pain which is of deep-seated, boring and stinging nature, often extending from the ear in various directions, and occasionally being noted even upon the opposite side.

When intracranial or sinus involvement is present, the pain is referred to the head rather than to the ear, and may be diffused over the entire skull, or localized in the forehead, the middle cerebral region, or the occiput, and it manifests a tendency to nocturnal exacerbations. Otitic meningitis and brain abscess are characterized by severe pain during certain stages.

When the cartilaginous portion of the Eustachian tube is the seat of inflammation, the attendant pain manifests a tendency to radiate, especially downward along the neck, and is increased by the act of swallowing or by attempts to remove intranasal secretion by blowing.

Retained purulent exudate induces the most severe of all types of pain. Pain along the neck, radiating from the ear, is often reflex, the causal factor being swollen and inflamed tonsils, tonsillar abscess, or parotitis.

(*e*) **Pain in the Mastoid Process.**—Both external and internal

inflammatory processes involving the mastoid process are attended by varying degrees of pain. In traumatism and periostitis the pain is considerable, and is always increased by pressure or manipulation of the parts. It is an important symptom of mastoiditis, which is rarely absent, and is invariably aggravated by pressure, especially over the mastoid antrum and tip. The severity of the pain is not necessarily in direct ratio to the degree or extent of the mastoid involvement, and it is sometimes complained of even in the absence of any demonstrable inflammation involving these parts. In eburnization of the mastoid process, pain of a sharp intermittent character is often noted, even after all active processes in the mastoid have ceased.

Acute empyema of the mastoid cells generally gives rise to violent pain.

After mastoid operations, in certain cases, the patients complain of pain in the mastoid region. This may either be of a neuralgic type, or from the involvement of nerve filaments in the resultant scar.

Painful sensations are commonly felt about the mastoid process, coincidental to atmospheric changes. This type of pain is persistent and has no pathological significance.

Pain, on deep pressure over the region of the internal jugular vein, is an indication of sinus-thrombosis, other symptoms coinciding.

Sensations akin to pain, but usually described as fullness and pressure within the ear, are often observed in acute catarrh of the Eustachian tube, and in connection with the entrance of mucus into the tympanic cavity, during the act of violent blowing of the nose; or from the penetration of fluid from the nasal douche under similar conditions. In some individuals pain follows the entrance of air into the tympanum as a result of politzerization or catheterization.

(*f*) **Neuralgic Pain.**—Otodynia of neurotic origin may be referred to almost any portion of the auditory apparatus, the most common location being within the tympanic cavity. This form of pain is commonly associated with hysteria and other functional neurotic disturbances. Sensory branches of the trigeminus and glossopharyngeal nerves may be involved, either as a result of intrinsic disease or through a transmitted reflex.

Ramsey Hunt ascribes otalgias of the neuralgic type to affections of the sensory system of the seventh nerve (nerve of Wrisberg, the geniculate ganglion and the petrosal nerves), claiming that otalgia bears the same relation to the facial nerve as does prosopalgia to the trifacial, and that in the facial nerve is to be found a sensory and reflex factor of great importance in the innervation of the auditory mechanism. He further defines an idiopathic form of otalgia, reflex otalgia, double reflex otalgia, secondary (herpetic) otalgia, tabetic otalgia and reflex aural neurosis.

Dental caries or affections of the tonsillar or peritonsillar region are the most potent causes of otitic neuralgia. The pain

may be continuous or periodical, with remissions and exacerbations. There is usually a marked tendency to radiation toward the neck and shoulder. Neuralgic attacks located in the auditory canal may follow the entrance of cold water or air into the meatus. These are sometimes associated with generalized trigeminal neuralgia.

Aural Discharge. (*a*) **From the Walls of the External Canal.**—Various diseases and injuries involving the external meatus are attended by discharge, either of mucus, serum, blood or pus.

Herpes, lupus, circumscribed and diffuse otitis externa, otomycosis, foreign bodies, and certain forms of eczema, are often attended by discharges of mucus or serum, which is sometimes streaked with blood.

Hemorrhage from the canal walls is uncommon and occurs in connection with traumatism, otitis externa hæmorrhagica, vicarious aural hemorrhage, and from the ulcerations of malignant growths.

Pus discharge arises chiefly from the rupture of furuncles in the meatus, or from fistulous openings caused by burrowing abscesses in the parotid or lymph glands, or from the mastoid process.

(*b*) **From the Tympanic Cavity.**—The chief source of aural discharge is found in the various diseases and injuries which involve the tympanic cavity, the otorrhea consisting of mucus, serum, blood and pus. The mode of exit is either through the Eustachian tube to the pharynx, or through the external auditory canal, as a result of rupture or paracentesis of the membrana tympani.

Violent inflammation of the tympanic cavity occasionally induces blood extravasations into the walls of the drum membrane in the form of blebs.

Traumatism of the drum, both direct and from concussion, is usually attended by hemorrhage.

Hemorrhage from the vessels of the tympanic cavity or its adjacent structures, vascular neoplasms, aural polypi, intratympanic granulation tissue, or from the middle ear in general, is of comparative frequency. Another source of aural hemorrhage is observed in fractures at the base of the skull, especially when involving the petrous portion of the temporal bone. Extensive fractures through the labyrinth sometimes permit the escape of cerebrospinal fluid from the external meatus.

Intratympanic serous exudates are usually either absorbed or escape through the Eustachian tube, except when perforations already exist or rupture results from pressure. Otopyorrhea is an important symptom of acute and chronic purulent otitis media, with their various complications. The bacteriological characteristics of pus are described in Chapter V.

Ear discharge, besides the above characteristics, is odorous, or non-odorous.

Mucous, seropurulent, or hemorrhagic discharge usually is non-odorous. Purulency, unless of very short duration, is usually malodorous.

The fetid discharges seen so often in the longer standing otorrheas is due to the chemical degenerations of the bony elements. It is almost pathognomonic of bone necrosis.

Temperature.—Fever is a common symptom of phlegmonous inflammatory processes involving either the external or middle ear. Foreign bodies, whether in the external meatus or embedded in the deeper tissues, may indirectly produce fever as the result of attendant inflammation. Acute inflammation involving the tympanic cavity, whether catarrhal or purulent, is attended by more or less fever, especially in young children.

The temperature of such inflammation, however, is variable, and its absence is sometimes noted. Retention of pus in the tympanic cavity usually results in sufficient absorption to produce elevation of temperature.

Temperature variations in acute aural affections are rarely pathognomonic, even when serious complications develop, with the exception of infection of the venous sinuses. Higher temperatures invariably prevail in the aural affections of infants and young children than in adults, but a high temperature, unattended by other aural symptoms, should never be considered sufficient ground for diagnosis of aural disease, and under these circumstances, until all the other possible causal factors have been eliminated, no operative interference should be attempted.

High temperature, alternating with chills, associated with either acute or chronic purulent otitis media, indicates a pyemic or metastatic process, and should always direct the attention of the observer to involvement of the venous sinuses.

Fluctuations in temperature, such as are sometimes present in purulent otitis, are characteristic of septic processes in general with a tendency to persist until the pus flow ceases.

Ear Cough.—A peculiar spasmodic cough of reflex origin is often produced by the introduction of aural specula and other instruments into the external auditory canal, and it usually persists for a few seconds subsequent to the removal of the instruments. A similar cough is occasionally induced by the pressure of impacted cerumen, foreign bodies and swellings, in which it is persistent and alarming, on account of the suspicion which is aroused that some serious pulmonary or cardiac disease is present.

CHAPTER VII.

GENERAL DIAGNOSIS OF EAR DISEASES.

ONLY diagnostic points of general significance are discussed in this chapter. The diagnosis of each aural affection will be fully described in the chapters on these diseases.

In examining the external ear it is important to note its size, its position, the surroundings of its insertion, the configuration of the concha, the orifice of the external auditory canal, the lumen of the canal, and the condition of its integument (Fig. 61).

Otoscopic examination, the technique of which is fully described and illustrated in Chapter II, includes a minute inspection of the external auditory canal, the membrana tympani, the malleus, and any portion of the tympanic cavity which may be visible through a perforation of the membrana tympani, in the given case.

Familiarity with the anatomical topography of the region examined, and the normal appearances, is a necessary adjunct to correct otoscopic diagnosis. A brief anatomical *résumé* is therefore given here.

The **external auditory canal** is composed of a cartilaginous and an osseous portion, joining at an obtuse angle, the outer or cartilaginous portion being the longer, measuring about 21 mm. in length, and the inner or osseous portion averaging about 14 mm. in length.

Obviously the osseous portion admits of neither mobility nor dilatation; the cartilaginous portion, however, being a part of the auricle proper, admits of considerable motion in all directions, and dilatation is attainable to a slight degree. The auricle must be so manipulated as to render the meatus as straight as possible in order successfully to inspect the deeper portion of the canal and of the membrana tympani (Fig. 11).

There are various developmental stages of the external auditory meatus, and, also, individual peculiarities, both as to size and direction. In infants under one year of age the walls of the auditory meatus are more readily separated by pulling the concha outward and downward. In adult life the auditory meatus is brought more nearly to a direct line by pulling the concha in a backward, outward and upward direction. It is sometimes possible in adults to obtain a satisfactory view of the entire auditory meatus and even the membrana tympani, without the insertion of a speculum. Individual peculiarities often necessitate changes in the direction of traction in order to compensate for curvatures in the cartilaginous portion or abnormal direction in the osseous canal. In children the entire external meatus is practically straight and little or no traction is necessary. In infants, as a result of the

absence of the osseous portion, the superior and inferior canal walls are usually in contact.

The Membrana Tympani.—The inner extremity or fundus of the external auditory meatus is made up of the membrana tympani, which assumes an oblique position, being so located that its postero-superior attachment is nearest to the external world (Fig. 103).

In examining the drum membrane its relative position, form, color, inclination, curvature, thickness, and light reflex are to be determined.

In contour the normal drum membrane is a somewhat pear-shaped oval (Fig. 101). The diameter is from 8 to 10 mm. It is sufficiently indrawn toward the umbo to render it concave, the concavity being somewhat relieved by the position of the short process of the malleus. The irregularity of its surface and the impress of the malleus from behind enable one to locate certain typical landmarks. Of these the color of the membrane, the presence of the short and the long processes of the malleus, the position of the anterior and the posterior folds, the umbo, and the light reflex are the chief landmarks.

The most prominent landmark, and the one usually first sought for, is the short process (Fig. 102). It is located near the upper periphery, at the junction of the anterior and posterior folds, projecting into the lumen of the external auditory canal, under cover of the drum membrane, in the shape of a minute yellowish-white button. The long process (Fig. 102) extends downward and backward from the short process, terminating in the lower half of the tympanic membrane in the form of a small disk, which is termed the umbo. At the umbo the apex of the light reflex will be observed (Fig. 102), gradually broadening and entending toward the anterior inferior periphery, the cone normally assuming the shape of an equilateral triangle. Variations in the lustre of the drum membrane are of marked diagnostic significance. Disappearance of or any alteration in the light reflex (Fig. 101) is an indication of pathological changes in the drum membrane.

The anterior and posterior folds extend from the short process, the anterior forward and slightly upward, and the posterior backward and slightly upward, serving as the dividing line between the membrana flaccida and the membrana tensa (Fig. 102).

The color of the normal drum membrane, as seen in the living subject, is pearly white, but is admissible of rather wide variations, dependent upon the source of illumination and the condition of the tympanic cavity. The color also varies with age, from a milky white in the child, due to preponderance of epidermal structures, to a neutral gray, mixed with a faint tinge of violet or light brownish yellow, in the adult. In old age it returns to the whitish color.

In labyrinthine and auditory nerve deafness, when uncomplicated by middle-ear disease, the membrana tympani may be normal in position and appearance.

Obstacles to Otoscopic Diagnosis.—An otoscopic examination in a large meatus containing no *débris,* exostoses, deformities or

swellings is not a difficult procedure. Epithelial *débris* or masses of cerumen lying upon the walls of the external auditory meatus are liable to impinge upon the distal end of the speculum and obstruct the view. Another common obstruction is found in bulging of any portion of the external meatal wall into its lumen, denoting infiltration, exostosis, or abscess (Fig. 68) of the canal. Exostoses always arise from the osseous canal wall and are hard to the touch of the probe (Fig. 97). Abnormally small and tortuous canals are sometimes encountered, requiring the use of specially long specula of small calibre in order to inspect the deeper portions. The pressure of the aural speculum sometimes induces reflex cough, the avoidance of which is rendered possible by careful and gentle manipulation.

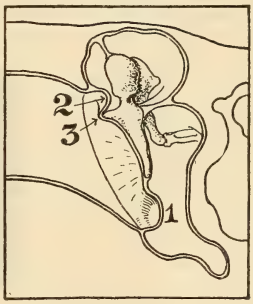

Fig. 40.—Lateral view of the tympanic cavity and drum membrane, with key plate. The illustration shows (1, 2) marked retraction of both the inferior and superior quadrants of the drum membrane and (3) marked prominence of the short process.

Pathological Changes in the Membrana Tympani.—Certain pathological changes in the drum membrane produce alterations in its appearance which are closely related to the general diagnosis of ear affections.

(*a*) **Hyperemia.**—The hyperemic drum is characterized by a local distention of the blood-vessels (Fig. 106), those about the manubrium and around the periphery being usually involved. When hyperemic, the numerous anastomoses about the periphery give to the membrane the appearance of being surrounded by a red ring which extends outward into the canal, often obliterating the tympanic boundaries. In severe hyperemia the entire membrane presents a bright-red appearance. A typical hyperemia is often observed after vigorous douching for the removal of impacted cerumen, or from accidentally touching it with probe or cotton carrier.

(*b*) **Ecchymosis.**—Extravasations of blood between the layers of the tympanic membrane usually occur in the form of dark-red dots or streaks, and these cannot always be differentiated from hemorrhages of the mucosa (Fig. 122).

(*c*) **Anomalies of Curvature.**—(Increasing concavity, convex-

ity, retraction, abnormal thickening). In partial convexity of the tympanic membrane, circumscribed portions appear sunken or retracted and somewhat funnel-shaped (Fig. 40). Marked retraction of the anterior segment alone is often partially masked by the anterior surface of the malleus handle. Marked retraction of the entire tympanic membrane with the handle of the malleus bound down by adhesions (Fig. 41) gives an appearance which is sometimes mistaken for destruction of the drum membrane, with dermatization of the tympanic cavity. Variations in the position of the malleus handle cause considerable variety of abnormal reflections and curvatures to the drum membrane. Retraction of the drum membrane gives undue prominence to the manubrium. The apparent prominence is sometimes noticeable even when the manubrium is indrawn and foreshortened. Retraction of a normal or atrophic drum brings to view various intratympanic structures, notably the

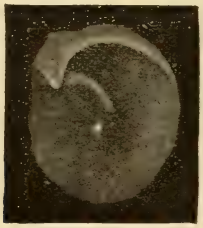

Fig. 41.—Marked retraction of the drum membrane, showing contact of the foreshortened manubrium with the promontory.

long process of the incus, the incudostapedial joint, and the promontory. Retraction always gives prominence to the short process of the malleus, and when the manubrium is simultaneously foreshortened the projection of the short process pulls the anterior and posterior folds into plain view (Fig. 42). Inflammatory thickening of the drum membrane alters or obliterates the normal landmarks. Commencing with the alteration in color, the light reflex, umbo, manubrium, and sometimes the short process becomes lost to view in the inflammatory exudate.

(*d*) **Solution of continuity** of one or more layers of the membrana tympani (rupture): Convexity or displacement of the membrane outward is commonly termed bulging. When convexity or bulging involves a single tympanic segment, whether anterior or posterior, the remaining segment has the appearance of marked concavity. When the entire tympanic membrane becomes convex the influence of the manubrium in holding that portion of the membrane covering it in place causes it to lie apparently in a furrow of the membrane. Bulging involving the posterosuperior segment changes the entire appearance of the tympanic portion of the canal, obliterating its oval proportions and narrowing its diameter from above downward, and partially obscuring the anterior segment

(Fig. 126). This condition, when accompanied by violent inflammation and stasis, is sometimes mistaken for granulations.

Sudden acute inflammation involving the tympanic membrane occasionally gives rise to the formation of blebs or extravasations into the membrane, which eventually break down and rupture either outward or inward, with or without the formation of a complete perforation (Fig. 122).

(*e*) **Perforations and Cicatrization.**—Perforations of the tympanic membrane are variable both in size and location. The discovery of perforations is never difficult to the experienced, but to the casual observer they often escape notice. Large perforations with well-defined borders, where no granulations or adhesions exist, are easily demonstrable (Fig. 43). When the whole drum is absent the fundus of the canal appears more distant from the eye and

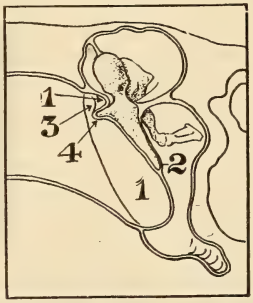

Fig. 42.—Lateral view of the tympanic cavity, drum membrane and bony meatus, with key plate. The illustration shows (1) marked retraction of the membrana tympani; (2) foreshortening of the long process of the malleus; (3) prominence of the posterior fold; (4) undue prominence of the short process.

the outlines of the intratympanic structures become visible. Old perforations, especially when they have become healed or are bound down at the edges by adhesions, can only be seen upon close inspection. Small perforations in the membrana flaccida above the short process are generally overlooked, unless the examiner habitually observes the entire peripheral attachment of the drum. If doubtful as to whether perforations exist the Siegel otoscope (Fig. 29) should be employed, and the membrane carefully observed when suction is made. This serves the double purpose of determining whether the drum membrane is adherent to the promontory or lateral tympanic walls, and the presence of perforations. If no movement is apparent, and no perforation borders come into view during suction, it may be assumed that the drum is wholly or partially absent. In chronic purulent cases with continuous discharge, granulations are usually present and are prone to fill and obscure the perforation aperture. In the acute stage the accompanying inflammation gives rise to marked reddening and swelling. Perforations resulting from traumatism are at first linear but

become oval after a time, and with less reddening and swelling of the parts. Close observation of the margins of perforations reveals the fact that they are almost invariably red.

Perforations usually occur singly, but multiple perforations in the same drum membrane (Fig. 175) are occasionally observed, especially in cases of tuberculous and syphilitic origin.

Perforations may remain unhealed long after the cessation of the purulent discharge. Nature's method seems to vary as to the process of healing. Commonly over a large perforation will appear a thin film of new formation, while at the same time the margins remain clearly outlined even though thickened and sclerosed. The atrophic appearance and transparent quality of the new formation is explained by the absence of the substantia propria in the scar tissue. Upon inspection the scar presents a darker appearance than normal, and the various parts of the tympanic cavity may be seen

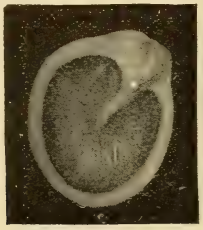

Fig. 43.—Large perforation of the membrana tympani. The malleus handle is attached to the promontory by adhesions. The illustration also shows outline of round window.

with more or less distinctness. The scar tissue may be so delicate as to give the impression that nothing intervenes between the eye and the tympanic cavity, and is, therefore, often mistaken for the perforation. At times the perforation scar has an unusually glistening surface. The margins of the scar are generally sharply differentiated from the rest of the tympanic membrane, but occasionally they merge into it gradually. In other instances the closing of the perforations is accomplished by a variety of cicatrices, the most common form being those in which the margins of the perforation become attached and held firmly to the walls of the tympanic cavity by cicatricial bands. Continued purulent exudate, with large perforations of the tympanic membrane, may finally become localized, leaving the remaining portion of the membrane comparatively normal. In other cases the destruction may be so extensive as to involve the entire drum, together with portions of the tympanic walls, leaving the surfaces rough and uneven in appearance, often complicated by the development of extensive sclerosis, with almost complete obliteration of the normal anatomical outlines. Occasionally scattered red spots devoid of epidermis, or yellowish disks due to a colloid deposit, or calcareous plaques appear in the sclerosed tissue (Fig. 113).

Circumscribed atrophy involving portions of the tympanic membrane is recognized by a somewhat darker coloration and an apparent umbilication. In extensive atrophy involving the greater portion of the membrane it presents an almost transparent appearance. Very frequently the irregular reflected light gives it the appearance of a piece of crumpled tissue paper (Schwartze). True atrophy of the tympanic membrane is differentiated from cicatrization by its general character and indistinct boundaries as compared with the sharper outlines of a scar margin. As a rule the study of the tympanic picture enables one to clearly differentiate between these conditions.

The Tympanic Cavity.—Certain portions of the tympanic cavity are visible when large perforations are present. Exposed ossicles, the promontory, the oval and round windows, and the pyramid are the parts commonly seen. Entire absence of the drum membrane and ossicles exposes the tympanic orifice of the Eustachian tube and a small portion of the epitympanic space. Small mirrors have been devised for inspecting other portions of the tympanic cavity, but they have proven of no practical benefit. The small curved silver probe of Hartman (Fig. 3), carefully and delicately manipulated, enables the observer to determine granulations, carious or necrotic tissue in this region by the sense of touch.

The Mastoid Process.—Inspection of the mastoid process is usually limited to its external covering. Limited opportunities for inspecting the internal portions are made possible only through large fistulous openings. Hyperemia and swelling of the external coverings of the mastoid process when present are not difficult of demonstration. In mastoiditis with postauricular swelling and occasionally as a result of enormous furuncles involving the posterior wall, the concha assumes a position almost at right angles to the head, indicating extensive periosteal involvement. Postauricular swellings in the very young are almost invariably the result of purulent mastoiditis. In the adult they may be indicative of sinus involvement, especially when the surrounding tissues are edematous (Kopetzky).

The Eustachian Tube.—The only visible portion of the Eustachian tube is its pharyngeal orifice. In rare instances obstruction in the pharyngeal orifice may be demonstrated by ocular inspection by means of the pharyngeal mirror. The diagnosis of Eustachian obstruction and stenosis is determined only by means of the bougie (Fig. 28). It occasionally becomes possible to use the bougie through large membranous perforations, entering the tube through the auditory meatus. The method employed for this purpose requires a slightly twisting motion given to the probe.

Auscultation.—Middle-ear auscultation possesses considerable value, especially in determining the condition of the Eustachian tube, and it is accomplished by means of a combination of ordinary catheterization in combination with the diagnostic tube, properly termed the otoscope (Fig. 24). Auscultation is of doubtful reliability for determining conditions prevailing in the tympanic cavity.

Under normal conditions an air current blown through the catheter and Eustachian tube into the tympanic cavity transmits a rather low-pitched, soft, smooth, unbroken bruit, free from roughness, bubbling or whistling. Stenosis of the tube, whether partial or complete, communicates a high-pitched, irregular, sharp bruit, sometimes becoming almost a whistle. After dilatation, whether by means of continuous pressure of air or by means of the bougie, the air again rushes into the tympanic cavity with a full, smooth sound. The character of the sound may be considerably affected by the condition of the tympanic membrane. A tense membrane gives a sharper tone, whereas the tone is much softened by a yielding membrane. When membranous perforations exist the air current produces a plainly audible whistling bruit as it passes through the gap in the auditory canal. Perforation whistles are heard for a considerable distance from the patient. Whenever there is pus or other secretion in the Eustachian tube the current of air produces a bubbling or rattling sound. Absence of such rattling sounds may not always be taken as conclusive proof that the Eustachian tube and tympanic cavity are free from secretion, inasmuch as it has been shown that rather smooth sounds may be heard even when the outer portion of the tube and tympanic cavity are more or less filled with tenacious secretion. Explosive sounds are produced by inflammation when the tubal walls are collapsed. The same character of bruit is transmitted when the tympanic membrane is partially or wholly in contact with the internal tympanic wall. The tympanic membrane has been known to rupture as a result of the impact of the air current applied with undue force, in which instance a loud explosive sound would be transmitted.

Absence of auscultatory bruit results from incorrect position of the catheter or of the aural tips of the diagnostic tube. It also results from various forms of tubal obstruction, such as extensive adhesions of the tubal walls, foreign bodies in the tubal canal, or possibly complete clogging of the tympanic cavity with masses of exudates.

Whenever inflation is induced by the Valsalva method certain auscultatory sounds may be heard which do not originate from the tube or middle ear but are transmitted from the nasopharynx.

Both ears should invariably be inspected at the preliminary examination of the patient, even though but one is complained of. For years the author has made use of the expression "Always examine the other ear" in his lectures to students. Even though the opposite ear is normal, its inspection is helpful by way of comparison. In a large proportion of cases of chronic affections both ears are involved. Retained cerumen is bilateral as a rule, but the patient may complain only of the ear in which it has become impacted. A patient's declaration that he has never suffered from abscess of the middle ear is not always reliable, inasmuch as such statements are often disproved by the presence of old perforation cicatrices in the drum membrane.

LUMBAR PUNCTURE.

From the standpoint of the otologist and the rhinologist lumbar puncture possesses both a diagnostic and therapeutic value.

Diagnostic Value.—Since Corning[1] published his monograph upon lumbar puncture, the procedure has become widely known. Quincke introduced it into the realm of diagnosis in 1891-1892. From that time until the present day over 150 monographs and reports upon this subject have appeared in medical literature. Kopetzky[2] has classified the essential points in the technique of the examination of the cerebrospinal fluid and outlined the diagnostic and therapeutic value of the procedure, and his classification, comments and references are as follows:—

In the examination of the cerebrospinal fluid the following points are to be noted: (1) The pressure under which it is obtained. (2) Its coloration (chromodiagnosis). (3) The bacteriological findings. (4) Cytodiagnosis. (5) The chemical examination. (6) Cryoscopy of the fluid.

Pressure.—The spurt of the fluid and the height of its curve while being withdrawn gives a fairly accurate idea of the degree of pressure, depending, however, upon the position assumed by the patient, the cardiac pulsation and respiratory activity. Quincke has observed a rise of pressure in persons with grave inflammatory conditions like tuberculous meningitis and tumors of the brain, the highest records resulting in tuberculous meningitis and acute hydrocephalus. Slow exit of the fluid is an indication of hypotonia. Heiman advocates the employment of a manometer for estimating the degree of pressure.

Color.—Normally the cerebrospinal fluid is clear and transparent. The pathological or accidental mixture with blood or micro-organisms produces a decided change. The presence of leucocytes is prone to give rise to a characteristic turbid appearance. The variations in color are usually from the normal clear transparent fluid to a cloudy yellow. In acute bacterial meningitis a well-defined purulent appearance is given.

The fluid is prone to be clear in chronic meningitis, and usually is the same in the tuberculous variety.

Bacteriological Findings.—Extensive investigations have been made in regard to the various micro-organisms which have been found. Of these nearly all forms have been differentiated, sometimes occurring as mixed infections while others are monobacterial. Diplococci are common in meningeal inflammations. Weichselbaum's diplococcus intracellularis is now the accepted exciting cause of cerebrospinal meningitis, and when found in the cerebrospinal fluid establishes a diagnosis.

The bacteriological tests may be by direct examination or by cultures and animal inoculations, the latter, however, usually requiring too long a period of time when the dangerous character of the affection is taken into consideration.

---

[1] New York Medical Journal, 1885.
[2] Surgery of the Ear, p. 309.

Among the pathogenic organisms which have been isolated from the cerebrospinal fluid are: the staphylococcus, streptococcus, Fraenkel's and Weichselbaum's pneumococcus, the Ebert bacillus, the colon bacillus, the tubercle bacillus. The tubercle bacillus is demonstrated only with considerable difficulty. Kroenig attributes the failure to an imperfect centrifugation or poor stain, thus emphasizing his belief in the possibility of demonstrating tubercle bacilli in all cases of tuberculous meningitis. A negative result may not necessarily prove the absence of pathogenic bacteria in the fluid for the principal reason that in such cases the medullary canal has not shared in the inflammatory process.

Cytodiagnosis.—This term is employed to describe the histological investigation of the cellular elements contained in the cerebrospinal fluid.

Lymphocytosis of the cerebrospinal fluid is believed to indicate the presence of meningeal irritation, which may or may not be purulent meningitis. Lymphocytosis is especially marked in chronic meningeal affections (tabes, multiple sclerosis, syphilis and tuberculous meningitis).

Polynucleosis indicates acute meningeal irritation—for instance, meningitis of pneumococcus, staphylococcus, or meningococcus origin. In this form the cerebrospinal fluid contains polynuclear leucocytes in sufficient quantity to produce a cloudy appearance. These tend to decrease as recovery takes place, being replaced by lymphocytes, which disappear after recovery. These observations are confirmed by Labbé and Castaignes, Sicard and Bricy. Leutert has observed marked general leucocytosis in meningitis of otitic origin.

The examination of the cerebrospinal fluid, while important, is chiefly valuable when considered in conjunction with the clinical evidences in the individual case.

Significance of Pathological Findings.—According to Chavasse and Mahu,[3] a clear, non-coagulable fluid indicates sinus-thrombosis, brain abscess (epi- or sub-dural), simple serous meningitis, meningismus, hysteria, and occasionally a circumscribed meningitis. If the fluid comes away in spurts under pressure the probability of serous meningitis, sinus-thrombosis, or more rarely brain abscess, is increased. A clear fluid without bacteria or coagulating elements indicates probable diagnosis of meningitis, toxic (?) or tuberculous. A clear or yellow or slightly turbid fluid with predominating lymphocytosis, or the tubercle bacilli, indicates tuberculous meningitis after clinical elimination of other causes of lymphocytosis, even if there are no tubercle bacilli present. An opalescent or purulent fluid, forming a coagulum with predominating polynucleosis, and eventual presence of various microorganisms, means acute diffuse meningitis, purulent or non-purulent, cerebrospinal meningitis (provided Weichselbaum's meningococcus is present), and if the puncture is hurried—*i.e.*, the fluid aspirated—sometimes it indicates a circumscribed meningitis.

---

[3] Reference to be found in S. J. Kopetzky's Surgery of the Ear.

Apart from the clinical symptoms, lumbar puncture does not give the mathematical certainty of establishing the differential diagnosis between brain abscess, serous meningitis, meningismus, or sinus-thrombosis. It is thus shown that lumbar puncture fails precisely for the differential diagnoses of greatest importance to the otologist, leaving doubt also as to the existence of a circumscribed meningitis.

Braunstein summarizes the conclusions of Leutert and Schwartz laid down at the Versammelung Deutsche Naturfoerscher und Aerzte zu Hamberg, 1901, as follows: A negative result, fluid clear and normal, definitely excludes the existence of diffuse purulent meningitis. A positive result, fluid turbid from increase of leucocytes, with presence or absence of micro-organisms, demonstrates the existence of diffuse purulent meningitis, or of cerebrospinal meningitis (if the meningococcus intracellularis is present). Braunstein does not consider it essential that the leucocytes present must be polynuclear, but he admits that the fluid may show turbidity in case of brain abscess.

Körner considers lumbar puncture as a frequent but not invariable positive diagnostic measure in otitic leptomeningitis. He makes the reservation that a fluid slightly cloudy containing bacteria may be found in diffuse as well as in circumscribed meningitis, and that there may be circumscribed meningitis with a clear fluid. Increased albumen and the presence of globulin with a decrease in the copper reducing substance, the presence of excess of lactic acid together with a polynucleosis, furnishes definite evidence of pyogenic irritation of the meninges. There is considerable experimental evidence that a lumbar puncture made upon a bacteremic patient is attended with considerable danger of sudden and fatal collapse.

Differential Diagnosis.—In children especially, tuberculous meningitis and cerebral tubercles are often observed, either as a complication of tuberculous otitis or as an accompanying result of non-tuberculous ear disease; moreover, tuberculous meningitis is often erroneously diagnosticated as ordinary meningitis or even as brain abscess. In order to prevent an eventual useless operation the examination of the cerebrospinal fluid is resorted to as a diagnostic aid.

The fluid obtained in these cases is generally clear and transparent, sometimes greenish yellow or tinged with blood.

Diffuse purulent meningitis due to various microbes is the most commonly observed form of this disorder as a complication of suppurative middle-ear disease. In diffuse suppurative leptomeningitis arising as a complication of purulent otitis media, or accompanying sinus-thrombosis or brain abscess, the fluid withdrawn by puncture is changed both macroscopically and microscopically. The seat of the suppurative process is commonly the subarachnoidal (exceptionally the subdural) space. The fluid is accordingly cloudy, greenish yellow, sometimes typically purulent, very frequently containing various forms of microbes, such as the staphylococcus, the

streptococcus, the pneumococcus, etc., and considerable quantities of leucocytes.

In cerebral or cerebellar abscess uncomplicated by other affections, intercranial in their nature, or by sinus-thrombosis, diffuse or circumscribed meningitis, the fluid is, as a rule, normally clear, without organisms, and yielding no coagulum. After centrifugation Lermoyez found the clear fluid to be normal. The quantity of the fluid may be altered by the existence of sinus-thrombosis, but it generally remains clear.

As a Therapeutic Measure.—Kopetzky defines the therapeutic value of lumbar puncture by calling attention to the fact that it affords two ways of therapeutically influencing a given lesion:—

1. By affording a road for the introduction of medicaments into the spinal canal, and from there to the cranial cavity, with the idea

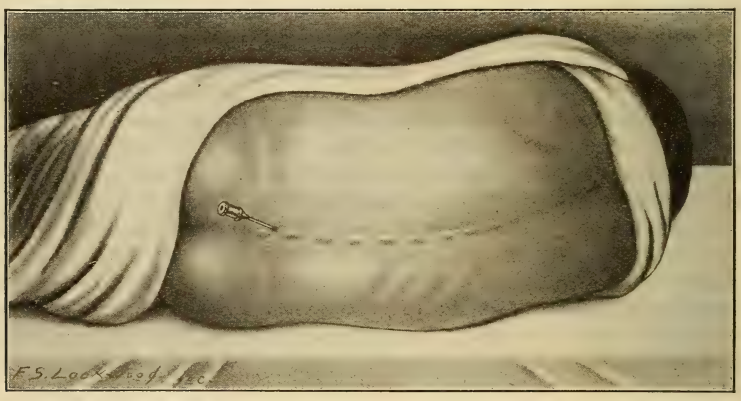

Fig. 44.—Position of patient for the operation of lumbar puncture. *(Louis Fischer.)*

of producing a resultant action directly upon the cranial or spinal lesion.

2. As a means of producing favorable therapeutic action both by relieving pressure as a result of the withdrawal of the excess fluid and by the removal of a proportionate quantity of the invading pathogenic organisms, and also simultaneously with the withdrawal of the fluid, bringing about the removal of the causative foci of the disease.

In the application of the first-named principle of lumbar puncture therapeutics many drugs have been employed. Sterilized air, sodium salicylate, potassium iodide, iodoform, and antitetanus serum are some of the many which have been recommended by various observers. Generally speaking the plan has not met with favor; the greatest success has attended the introduction of antitetanus serum.

The second therapeutic principle, that of producing a favorable therapeutic result from the withdrawal of spinal fluid, has brought forth wide divergence of opinion. We will study some of these opinions in detail.

The therapeutic value of lumbar puncture in meningitis has the endorsement and recommendation of many able observers; thus Quincke finds it useful in cases of serous and seropurulent meningitis. Its good effects in this condition are due to the relief of intracranial pressure.



Fig. 45.—Lumbar puncture needle and syringe.

In serous meningitis secondary to the exanthemata in children Wertheimer reports most favorably on its therapeutic virtue. Friedrich, in his recently published book, discusses the forms of

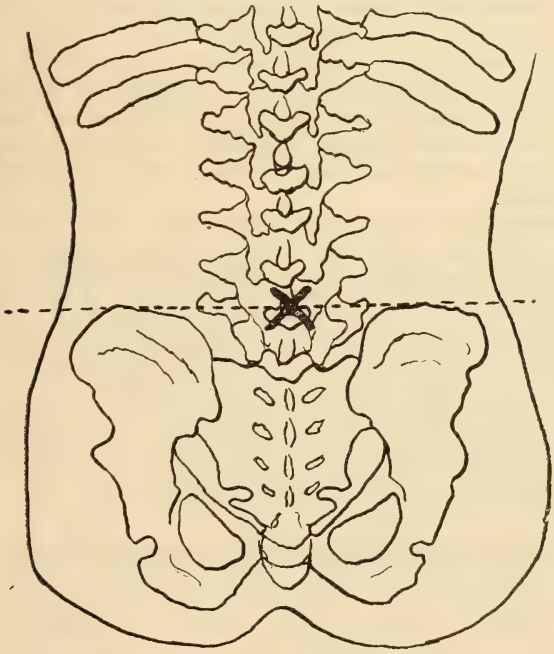

Fig. 46.—Anatomical illustration showing the place best adapted for lumbar puncture. The cross indicates the point of insertion. *(Louis Fischer.)*

operative interference in purulent meningitis inclusive of the method of repeated lumbar puncture, followed by injection of physiological salt solution for the evacuation of pus from the spinal canal. He, however, makes a counter-opening into the cranial cavity to secure free evacuation of the purulent exudate.

A variety of opinions exists among these various observers as to the relief which the measure affords to hyperdistention of the cerebrospinal fluid in this form of meningitis.

Francis Huber is of the opinion that the therapeutic effect of lumbar puncture is a great one, and he uses it as a therapeutic measure in otitic meningitis, the cerebrospinal type of typhoid, and also in cerebrospinal meningitis.

In addition to the relief of pressure symptoms lumbar puncture serves to evacuate with the spinal fluid a large portion of the agents of suppuration, microbic and toxic, which have penetrated into the subarachnoidal space.

Dangers of Lumbar Puncture.—In summing up the question of the dangers from this procedure one must take a conservative position. That it has caused death is undeniable; a horizontal posture lessens the danger (Fig. 44), and aspiration of the fluid is to be condemned. The procedure is contraindicated in cases of vascular sclerosis and aneurisms of the cerebral vessels, in all acute and chronic affections of the central nervous system without pressure symptoms arising from the spinal fluid, the more so since the cerebral vessels are secondarily implicated in many of these diseases. The possibility of cerebral hemorrhage should always be kept in mind, especially when withdrawing large amounts of fluid. Small hemorrhages represent no danger to life; they may, however, exercise an unfavorable influence on the patient's future well-being.

The Technique of Lumbar Puncture.—The instrument employed to make the puncture is the Quincke needle (Fig. 45). These needles are procurable in three sizes, of different lengths and diameters. Each needle is fitted with a stilette to aid its introduction. The length of the Quincke needle is from 4 to 10 cm., with diameters from 0.8 to 1.6 mm. The point of the needle is bevelled at an acute angle terminating at a sharp point.

The position of the patient is important in order to carry out the technique of the procedure easily. The patient should be placed on his side, with his back gently curved so as to effect as great a separation of the vertebral bones as possible (Fig. 46).

THE VALUE OF BLOOD EXAMINATIONS.

(1) Blood count. (2) The differential count. (3) Blood cultures. The value of blood examinations as a diagnostic feature in purulent otitis media, mastoiditis, and the intercranial complications occurring in connection therewith has been a subject of considerable experimentation during recent years. At the present time opinions vary in regard to the value of such examinations in purulent tympanitis and simple mastoiditis; but the majority of observers concede its value in sinus-thrombosis and purulent meningitis. Dench[4] in a study of sixty cases of purulent otitis media

[4] Transactions American Rhinological, Otological and Laryngological Society, 1908, p. 198.

with mastoid complications, in all of which blood counts were made, concludes that where there is no increased polymorphonuclear percentage, an increase in the leucocyte count is absolutely of no value in determining the absence of pus in the mastoid in doubtful cases; that where these variations from the normal blood occur in aural cases we must look for one of three conditions: (1) Some visceral lesion. (2) Some involvement of the soft tissues in the immediate vicinity of the wound. (3) For some involvement of the intercranial structures, either of the brain substance or of the lateral sinus. These views are based upon carefully prepared statistics.

A more detailed study of the leucocyte count shows a considerable increase of leucocytes in nearly all of the cases reported. In only eight cases was the leucocyte count below 9000, the range being from 9000 to 25,200. The variations were less marked in the polynuclear percentage, which varied from 60 to 80 per cent.

Blood Count.—The normal leucocyte count varies slightly, according to different observers. The following table[5] indicates the normal leucocyte count in 1 c.c.:—

Hayem	6000
Malassez	7500
Limbeck	8500
Rieder	7680
Thoma	8687
Beckman-Reinecke	7533
Groeber	7242
Tumas	6200

Any considerable increase of leucocytes is, therefore, suggestive of infection in some portion of the body. In the differential count an increase in the percentage of polynuclear neutrophiles to the total number of leucocytes is considered significant of infection.

McKernon and others consider a high polynuclear percentage to be particularly significant of lateral sinus-thrombosis, especially when accompanied by a high leucocyte count. In the author's experience lateral sinus involvement as a complication of otitic origin has been thus characterized. The accompanying table represents the result of a blood examination in a patient who had a purulent blood-clot extending from the lateral sinus, jugular bulb and internal jugular vein and torcular to the clavicle. Here it is observed that the leucocytes numbered 30,200 with a polynuclear percentage of 84:—

Patient, H. K. Date November 17, 1908.

Blood Examination.

Hemoglobin	
Erythrocytes	4,400,000
Leucocytes	30,200
C. I.	

[5] Waite D'Hematologie, by Bezançon and l'Abbé, p. 479.

DIFFERENTIAL COUNT.

Large mononuclear lymphocytes	26.0
Small mononuclear lymphocytes	3.0
Polynuclear neutrophiles	84.0
Mononuclear leucocytes	4.8
Transitional forms	4.8
Eosinophiles	
Mast cells	0.8
Myelocytes	
Basophiles	
Plasmodia	

The following table shows the normal blood-count and the percentages of the polynuclear to the total number of leucocytes (from Da Costa) :—

BLOOD EXAMINATION.

Hemoglobin	80-100 %
Erythrocytes	5,000,000 %
Leucocytes	7406 %

DIFFERENTIAL COUNT.

Large mononuclear lymphocytes	4-8 %
Small mononuclear lymphocytes	20-30 %
Polynuclear neutrophiles	60-75 %
Mononuclear leucocytes	
Transitional forms	
Eosinophiles	0.5-5 %
Mast cells	
Myelocytes	
Plasmodia	
Basophiles	0.5 %

Blood-cultures.—Invasion of the blood-current by pathogenic micro-organisms is a condition which is known under the term, bacteriemia. This interesting field of research so far as it relates to infections of otitic origin has received comparatively little attention on the part of those interested in pathological research. Statistics, up to the present date wherein blood-cultures have been made in otitic cases, have shown positive results in a considerable proportion of all cases examined, and in many instances the negative results obtained have seemed to be of considerable diagnostic value in the elimination of general infection as a cause of the symptoms indicated in individual cases.

Libman[6] made 75 blood-cultures in 55 cases. Of these the results were positive in 22 cases, 16 of which were fatal and 6 recovered. Of the 16 fatal cases 2 were streptococcus mucosus meningitidis. His positive results were almost entirely in cases of sinus-thrombosis and meningitis. There were positive results in but 2 cases of otitis media purulenta, both of which recovered, and without any record of examination of the jugular bulb. In simple mastoid cases, even with extradural abscess, there was bacteremia in but one.

[6] Archives of Otology, vol. xxxvii, No. 1, 1908.

Blood-cultures were made in 26 cases of sinus-thrombosis with 17 negative results and 9 deaths. All positive blood-cultures in these cases showed streptococci. He believes that blood-cultures may be negative under the following conditions:—

1. Bacteria may have escaped into the blood-current and all may have been killed off. Possibly a blood immunity is acquired.

2. Below the purulent clot there may be a non-infected clot, or an infected clot none of which breaks off.

3. A bacteremia may be prevented by tying the jugular vein. In such cases metastases (due to bacteria lodged early) may come some days after the blood is free from bacteria. All the foci in which bacteria have been deposited do not show activity at once.

4. The patient may have sinus-thrombosis; there may be secondary foci in the lungs, but the bacteria may not escape into the general circulation.

Libman's conclusions are as follows:—

Significance of Negative Blood-cultures.—1. If the mastoid has been exposed and there is no trouble in the sinus or brain, a negative finding will point against a continuance of the symptoms being due to a general infection. In such cases one may find that the patient has developed tuberculosis, may have rheumatism, or may have developed some other intercurrent disease.

2. If the blood-culture should be negative and the symptoms continue, whether there is a sinus-thrombosis or not, acute endocarditis can be excluded.

3. If there has been a sinus-thrombosis and bacteria have been present in the blood and the jugular vein has been tied, a negative culture will show that the general invasion has been stopped.

4. Occasionally a negative blood-culture has been of value in cases with a clinical picture of rheumatism coming on in a person who has otitis media or mastoid disease. It is very valuable in such cases to know that we are not dealing with an arthritis due to general invasion by known bacteria.

Significance of Positive Blood-cultures.—1. A positive blood-culture indicates a general invasion. A positive streptococcus blood-culture in Libman's experience nearly always points to the presence of sinus-thrombosis.

2. If the sinus has been operated upon and the patient is not doing well, a continued presence of streptococci in the blood shows according to Libman that the local focus has not been sufficiently dealt with. If the local focus has been thoroughly dealt with, streptococci generally remain in the blood only when endocarditis has been established or when the bacteria are multiplying in the blood. The establishment of endocarditis in these cases occurs, according to this observer's experience, quite infrequently. Multiplication of streptococci in the blood in such cases is also not frequent, so that a positive result continued after operation most often means that there is further trouble locally.

3. If the streptococci have been present in the blood and the sinus has been explored and the jugular vein has not been tied,

continued presence of organisms in the blood may give the indication to tie the jugular vein.

4. If the infecting organism in the ear has been the streptococcus, and the pneumococcus should be found in the blood-culture, the suspicion would be aroused that the patient was developing an intercurrent ordinary pneumonia.

5. In cases in which there is a question as to whether the patient has developed typhoid fever or a complication of otitis media, the presence of bacilli in the blood would prove that the patient had typhoid fever.

6. In a certain number of cases in which the ear phenomena are very slight or in which one is not ready to trace marked clinical phenomena to an old otitis, the presence of organisms in the blood may give the indication to explore the mastoid and surrounding parts if there be no other focus found through which the bacteria could gain access to the blood. Libman had three such cases which were operated upon by Gruening, and in two of these sinus-thrombosis was found, and in a third mastoid disease. All the patients recovered. In a fourth case which concerned a comatose man, streptococci were found in the blood and there were metastatic foci present in the body. The only possible entrance point found was an otitis media. The patient was in too poor a condition for operation, but the autopsy showed that a sinus-thrombosis was present.

To the significance of positive blood-cultures special emphasis should be given to the almost universal presence of the streptococcus in cases of sinus-thrombosis. This statement is abundantly confirmed by reports which have from time to time appeared in medical literature. Leutert in four cases of sinus-thrombosis found the streptococcus in all.

Libman concludes that "it may be affirmed that blood examinations and blood-cultures possess considerable diagnostic value, especially in relation to the complications of purulent otitis media, and, while they in no wise supersede or attain the importance which should be given to the value of clinical evidence, it is very probable that many of the conclusions here cited will have to be modified as we learn more of the subject of bacteriemia, inasmuch as the technique of blood-cultures has not as yet been sufficiently developed, and the examination of a sufficient number of controls has not been made in order to render the above conclusions satisfactory for clinical guidance."

It is the opinion of the author that in a given case if a blood-culture shows the presence of a bacteriemia which cannot otherwise be accounted for, the diagnosis of infection of the lateral sinus is indicated. Experience has shown, however, that in certain instances and under certain conditions a blood clot may be present in the lateral sinus without giving evidence of bacteriemia. We there-

fore may conclude that a sinus-thrombosis may be present which gives no evidence of bacteriemia, even after repeated laboratory examinations. Bacteriemia may be expected in cases of acute endocarditis, pneumonia and sometimes in infected tonsils.

CHAPTER VIII.

GENERAL THERAPY OF EAR DISEASES.

A CHAPTER on general therapy is introduced for the purpose of describing certain therapeutic measures which are referred to repeatedly in the subsequent chapters of Part I.

Hydrotherapy.—Water as a remedial agent in the treatment of affections of the ear is employed by various methods and for a variety of purposes. Douching or syringing applied by means of the fountain bag, piston syringe, or Fowler suction apparatus introduced into the external auditory canal reaches the membrana tympani and the tympanic cavity, when the drum is perforated, and is of value for the following purposes:

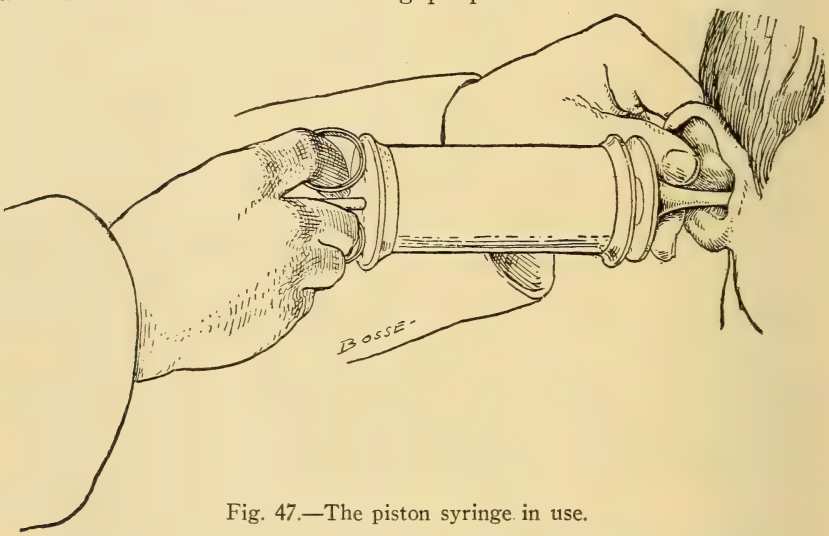

Fig. 47.—The piston syringe in use.

1. **For the Removal of Cerumen, Foreign Bodies, Pus, Cholesteatoma, or Other Débris.**—In removing cerumen, foreign bodies and large cholesteatomatous masses, warm sterile water will usually suffice, and the piston syringe (Fig. 47) enables the operator to control the force of the current (Chapter XI). The Fowler suction douche (Fig. 48) and the Lucae douche, both acting on the same lines, are the most effective methods for the removal of pus from the external meatus or open tympanic cavity.

The Fowler apparatus consists of a glass bell, so designed that its rim fits accurately about the auricle, wholly inclosing same, preventing any back flow or accumulation of fluid from wetting the patient or those administering the treatment, and subjecting the meatus to no pressure or possible traumatism. From the top and centre of the glass bell projects a nipple, for connecting the apparatus with its source of fluid supply—a fountain syringe. Projecting inward from the nipple is a nozzle, glass in its proximal and soft-rubber tubing in its distal portion.

The arrangement is such that this soft-rubber tubing can enter the external auditory meatus, taking a direction inward, downward, and forward, thus coinciding with the axis of a normal canal.

The nozzle extends about one-half inch beyond the rim of the bell in order that the fluid used may properly irrigate, and the end of the nozzle remain necessarily at a safe distance from the deeper portions of the canal.

On the circumference of the bell is situated the outlet nipple, to be connected with rubber tubing, the latter draining into a washstand basin or any suitable receptacle.

The apparatus being made of glass insures at all times a clear view of the parts under treatment and makes cleansing and steriliz-

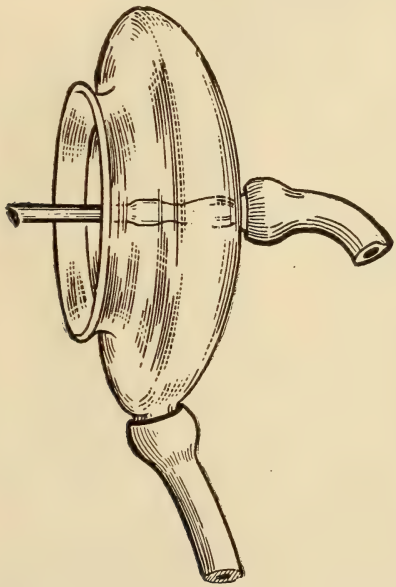

Fig. 48.—The Fowler suction bell douche.

ing easy. The apparatus irrigates safely, efficiently, and simply, but does more, it irrigates in the presence of a partial vacuum, brought about by the tight joint between the rim of the bell and the side of the head about the ear and by the syphonage through the drainage tube constantly tending to produce a vacuum (Fig. 49).

It draws the pus, detritus and inflammatory exudate to the surface and the irrigating fluid washes them away. It leaves the tissues clean, and without the boggy appearance resulting from ordinary irrigations. It produces a combined active and passive hyperemia locally in and about the ear with all the concomitant benefits claimed for this treatment (Fig. 50).

The solution employed for douching may be warm sterile water, warm sterile normal salt solution, or a solution of bichlorid of mercury varying from 1 to 3000 to 1 to 5000. Any preference

for the last-named solution must depend solely upon the germicidal power which it may exert. The entire cavity after douching should be wiped with cotton pledgets.

2. **Sterilization of the External Auditory Canal.**—After cleansing and scrubbing the external ear the canal should be subjected to a thorough douching with a large quantity of a solution of bichlorid of mercury, 1 to 5000, preferably by means of a fountain bag, and

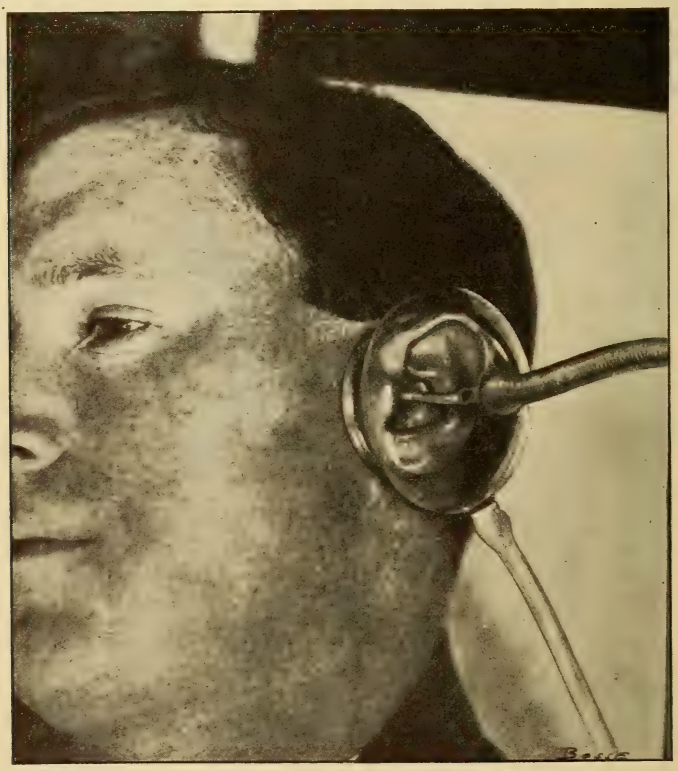

Fig. 49.—The suction douche applied to the ear, showing the indrawing of the auricle resulting from the partial vacuum within the glass bell.

then wiped dry again with sterile cotton. When the drum is intact the sterilization is made more effective by filling the canal with 95 per cent. alcohol for a few minutes after the preliminary douching. It is quite impossible by any process to render the external auditory canal absolutely sterile.

3. **Reduction of Pain and Inflammation.**—The hot-water douche is of much value for the relief of pain in acute catarrhal otitis media, the early stages of acute purulent otitis media, and other aural conditions wherein the application of heat is indicated. One to three quarts of water, at a temperature of 110° F., allowed to flow

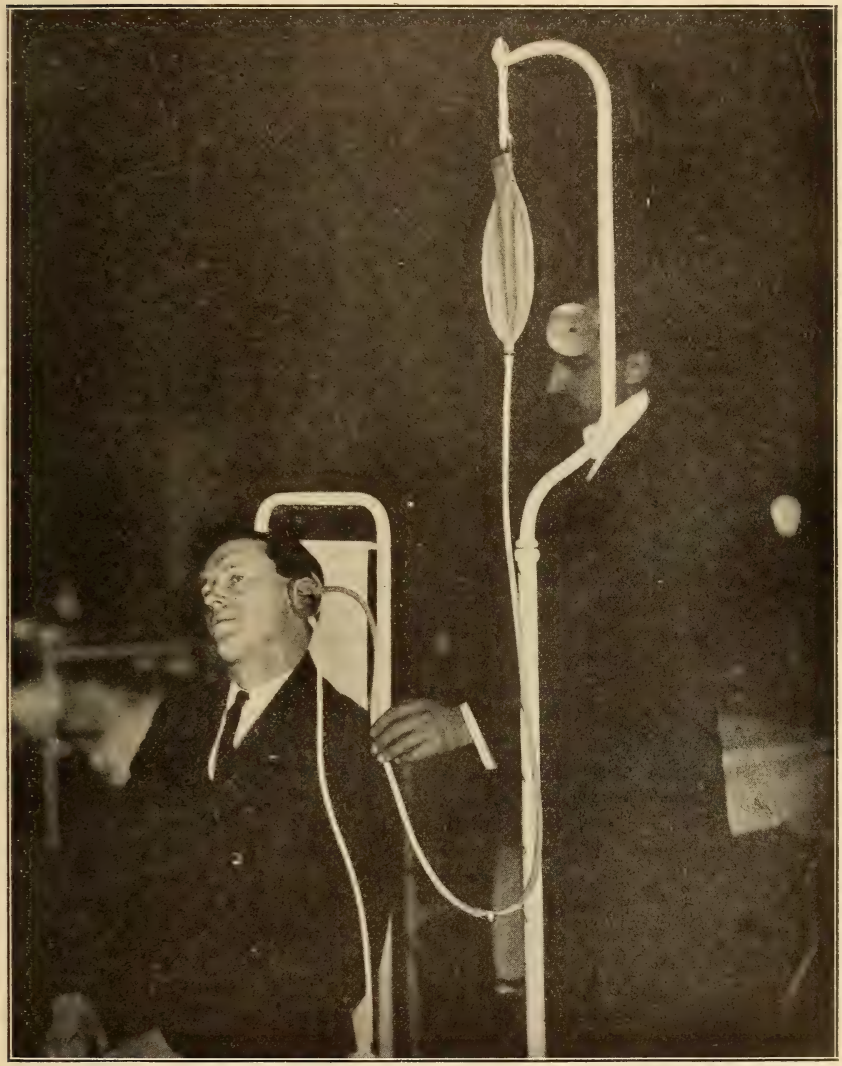

Fig. 50.—The suction douche apparatus complete, showing the supply bag, rubber tubing, etc.

into the ear from a fountain syringe elevated four or five feet from the patient's head, is gratefully borne and may be repeated at half-hour intervals if necessary. The force of the stream should not be sufficient to produce traumatism or injury to the soft tissues.

4. **Water Massage.**—Massage by means of the douche has its advocates. The ordinary ear or fountain syringe is the instrument commonly employed for this purpose, a small rubber tube being

drawn over the tip and allowed to project slightly. In this manner the walls of the auditory canal are protected from injury by the syringe, and the introduction of the instrument into the auditory entrance is made without risk. The water used in the ear must be warm, since cold water causes extremely unpleasant sensations upon entering the external meatus, often evoking severe vertigo. The temperature best borne is 110° F. When perforations of the membrana tympani are present ordinary water sometimes causes considerable irritation of the mucous lining. This may be avoided by the addition of two teaspoonfuls of common salt to the quart of water.

The pressure at which water massage is employed is of importance, and must be gauged according to the symptoms produced, but in no event should the force be sufficient to cause traumatism. Forcible water massage may also give rise to severe vertigo and pain, and it may become a dangerous procedure when forcibly brought into contact with necrotic portions of bone, or by the entrance of the fluid directly into the labyrinth through a gap in the labyrinthine capsule.

Water massage should always be carried out slowly and carefully, and it should be interrupted at once upon the first evidence of pain or vertigo. Before introducing the tip of the syringe into the auditory meatus all air should be expelled by allowing some of the fluid to escape from the syringe tip.

Water massage may also be effected by means of the suction douche heretofore mentioned. After adjusting the glass ear piece by intermittent compression upon the outlet tube, the column of water is forced inward and outward.

Contraindications to the Use of the Water Douche.—The ear douche induces vertigo in some persons. This occurs more often when perforations of the drum are present. Vertiginous attacks are sometimes of sufficient severity to render the reclining posture necessary for some time. Nausea occasionally accompanies the vertigo. Some patients are enabled to avoid vertigo by assuming the reclining posture while douching; others prevent the attack by varying the temperature of the water. There remains a small percentage both with and without perforations, who cannot employ the ear douche under any circumstances on account of the persistent vertigo and nausea.

Pain is rarely caused by the douche, but when it is experienced it will be found that the water is too hot or too cold. Pain also occasionally occurs when water fills the tympanic cavity through a small perforation in the upper portion of the drum membrane and is thereby retained.

Tinnitus may be increased by the water douche, the increase being more common in purulent cases.

In all instances sterile water only should be employed for irrigation, inasmuch as a strong current of water may become the causative factor in the entrance of micro-organisms into the tympanic cavity. The author has never personally observed serious

accidents resulting from the forcible use of the water douche; nevertheless, such have been reported.

The canal should be thoroughly dried with pledgets of cotton, after bending the head toward the affected side to allow the escape of the surplus fluid. In purulent cases, especially when acute, after drying it is advisable to close the external auditory meatus with sterile gauze in order to guard against further contamination. The same precaution should be observed in order to prevent the entrance of water into the tympanic cavity during bathing.

External Applications of Hot Water.—The hot-water bag is a valuable appliance for the relief of aural pain, especially that which accompanies acute otitis media, furuncle of the canal, and otalgia of reflex origin. It is gratefully borne and produces no ill effects. It may be used continuously or at intervals, but the temperature should not be sufficiently high to burn or scald the skin.

Hydropathic Applications.—In hydropathic institutions it has been observed that patients suffering from deafness with subjective ear noises due to chronic catarrhal otitis media, whenever the body is subjected to warm hydropathic packs lasting for an hour or so, are sometimes greatly improved in hearing and relieved of tinnitus for varying periods of time. Occasionally the same results are obtained in isolated cases of disease of the auditory nerve, especially when due to syphilis. Urbantschitsch claims that marked perspiration resulting from active physical exertion may cause a notable decrease in deafness and subjective ear noises, the symptoms all recurring subsequent to the cooling off of the body.

Air-douche Therapy.—The air douche is employed for both diagnostic and curative purposes, first, by forcing air vapors or fluids into the Eustachian tube and tympanic cavity, and, second, by pneumomassage or currents of superheated air through the external auditory canal.

In the first variety the mode of entrance is either through a catheter (Fig. 24) passed into the faucial opening of the Eustachian tube, or by condensation of the air contained in the nasopharyngeal space by means of the Valsalva or Politzer method (Chapter II).

The diagnosis of Eustachian obstruction, and to a slight extent the mobility of the membrana tympani, is dependent upon catheterization or Politzerization (Chapter II).

The mobility of the membrana tympani and ossicles is more effectually determined by means of the pneumatic otoscope (Fig. 29), which permits the surgeon to induce suction and condensation of the air confined in the external meatus and to observe the movements of the drum membrane.

Intratympanic Medication by Means of the Catheter.—The treatment of the inflammatory affections of the tympanic cavity requires some direct application to the diseased areas, a procedure of considerable difficulty except when large perforations are present. In the absence of perforations the only means of reaching this cavity is through the Eustachian tube. Whenever the oro-

pharynx is clear, with a sterile catheter any bland sterile fluid may, in small quantities, be introduced into the tubal canal without fear of inflammatory reaction. Neither is there any valid objection to the introduction of slightly astringent or otherwise non-irritating medicated fluids into the Eustachian canal. Fluids introduced in this manner rarely enter the tympanic cavity, but are deposited along the walls of the tube. A minute portion of fluid is taken care of by the membranous lining of the tympanic cavity not only without irritation but with benefit. The chief benefit to be derived may be expected from tubal medication only.

In the treatment of that form of chronic tubal catarrh which is accompanied by an accumulation of exudate, especially in the pharyngeal portion, six or eight drops of the appropriate medicated fluid may be dropped into the catheter by means of a dropper or a small syringe, and driven into the tube under moderate pressure by an ordinary Politzer bag. Too much force should not be used in this procedure, the inflation being performed two or three times in succession in order to expel the total amount of fluid from the catheter into the canal. A 1 per cent. solution of common salt to which may be added sufficient tincture of iodin to give a pale amber color has been found to give considerable relief in this variety of cases. This solution, however, is readily decomposed, and must therefore be prepared for each day's use. Other useful solutions are a 2 or 3 per cent. solution of sodium bicarbonate, a 1 to 3 per cent. solution of potassium iodid or ammonium chlorid, a 1 per cent. solution of ammonium muriate. The author's preference is for oily solutions in the form of properly medicated vaselin, several formulas for which will be found serviceable. A 2 per cent. solution of camphor and menthol in liquid benzoinol gives great relief to tubal inflammation, 5 or 6 drops being injected into the catheter and forced into the tube with the air douche. These instillations also make the tube more permeable for the passage of the Eustachian bougie. An injection given to facilitate the passage of the bougie should not exceed three or four minims. Sterile solutions of cocain or adrenalin may be employed in like manner.

Introduction of Vapors Into the Middle Ear.—In the presence of an intact membrana tympani it is not probable that medicated vapors introduced into the Eustachian canal through the catheter can be forced to enter the tympanic cavity even in limited amounts, but the column of air contained in the middle ear is displaced and made to advance and recede by this procedure, resulting in a gradual diffusion of the vapor employed.

For medicinal purposes the Dench middle-ear vaporizer (Fig. 24) is a useful instrument, and combines ordinary inflation with medication by using vapor-laden air. By pouring into the hard-rubber air chamber, which should be lightly packed with absorbent cotton, a solution of equal parts of iodin, camphor and menthol, a strong vapor is blown through the catheter into the Eustachian tube. This method is recommended as a routine treatment in all cases requiring catheterization. It often relieves distressing tinni-

tus, improves hearing, and tends to retard adhesive inflammation and possesses some slight absorbent power.

Ammoniated vapors are most simply introduced by pouring the rapidly evaporating fluid into the bulb of an air douche. In cases of difficult Politzerization it is customary to put 2 or 3 drops of chloroform into the air douche, taking advantage of the rarefaction attending the escape of air by the pressure upon the bulb to overcome the obstruction in the Eustachian tube. For the same purpose a few drops of a solution of one part of camphor to ten parts of ether have been employed. This procedure not only serves to aid in the process of Politzerization of the middle ear, but the vapors occasionally seem to cause at least a temporary decrease in the subjective ear noises, while neurotic patients are sometimes sufficiently impressed with the procedure to be entirely relieved.

Superheated Air.—The employment of the electric heater (Fig.



Fig. 51.—Electric air heater.

51) makes it possible to douche either the Eustachian tube or the external canal and membrana tympani with air which has been warmed to a proper temperature. This is recommended in obstinate cases of tubal catarrh with tinnitus, and applied through the external auditory canal for the relief of pain arising from intratympanic inflammations and otitis externa.

Pneumomassage of the Middle Ear, and Negative Air Pressure in the External Auditory Canal.—Alternating condensation and rarefaction of air within the auditory canal serves to produce vibrations of the drum membrane and the ossicular chain. Otomassage is employed for the prevention of adhesions of those parts, with diminished mobility of the sound-conducting apparatus, or for breaking down those already formed. If successfully conducted the hearing function is often conserved and distressing tinnitus benefited. In former years the motive force was derived from a small rubber bulb or some form of hand pump, types of which are those of Lucae, and the rarefactor constructed by Delstanche, either of which permits the regulation of changes of air pressure in the auditory canal. The control of these instruments is entirely within the province of the operator, who may at the same time

witness the effect upon the drum membrane through the glass window in the speculum. Of late the electromotor air pump (Fig. 3) is almost exclusively employed for the relief of pressure sensation and tinnitus, on account of the uniformity of pressure and rarefaction produced by the electromotor machinery. The electromotor air pump is a valuable adjunct in the treatment of the chronic forms of middle-ear disease when accompanied by adhesions. All massage procedures are employed to loosen the adhesions and increase the motility of the ossicles. Pneumomassage of the middle ear sometimes produces a transitory sedative effect upon the subjective ear noises of severe chronic catarrhal otitis. Deafness also is occasionally favorably influenced by this form of treatment, the relief being described by patients as due to a diminution of the pressure sensations in the ear and head and sometimes from vertigo. The hand otoscope is more positive in results when employed for the prevention of adhesions. In labyrinthine disease the intercurrent tinnitus and pressure sensations are usually aggravated by the employment of pneumomassage. Patients with mixed catarrhal and labyrinthine deafness are not usually benefited by pneumomassage except when employed for the prevention of adhesions, and it should be discontinued whenever it increases the tinnitus or aggravates the deafness. It is usually contraindicated when the drum membrane is atrophic, even though the ossicles are bound down and immovable on account of fibrous deposits, for the suction affects only the atrophic membrane and the ossicles are not moved thereby. Added to this is the danger of rupture.

All otomassage instruments should be used with due precaution, never indiscriminately, and only after ascertaining that the case is a proper one for massage.

The binaural attachment of the electric apparatus is convenient, but considerable experience is requisite in order to determine the proper suction force and vibratory speed for the individual case.

It is safer for the inexperienced to employ a window otoscope, and always under visual inspection, with the drum membrane in full view. The excursion of the drum and ossicles may thus be noted and all variations observed.

The first manifestation of pain during the employment of pneumomassage is to be interpreted as a sign of exaggerated force, especially if accompanied by vertigo or tinnitus. The degree and rapidity of the motions of the apparatus should be relatively diminished. Whenever this form of treatment is followed by symptoms of pressure, tinnitus or vertigo, or even if the patient states that he does not feel as well after the treatment, it should be discontinued.

Vibratory Massage.—Electric vibratory massage (Fig. 3) is a valuable aid in the treatment of chronic non-suppurative ear affections, its chief benefits being relief of tinnitus and intratympanic pressure. Unlike pneumomassage it is often well borne in labyrinthine and mixed cases. The soft-rubber cup-shaped tip gives better results than hard rubber. It relieves tension and produces a decidedly soothing effect upon the nerves in a class of patients

who are subject to marked depression and fits of despondency. It may be used only for from five to ten minutes and applied about the ear, face and cranium. The points of application are: (1) to the point of the chin; (2) at the anterior edge of the attachment of the masseter muscle to the lower jaw; (3) in front of the tragus; (4) completely over the opening of the external auditory canal; (5) above the ear; (6) upon the mastoid process; (7) at the occiput. These points are selected because they seem to carry the vibrations more directly to the region of the ear. Many patients seem to receive benefit from the vibratory massage who believe they are harmed when pneumomassage is employed. In any estimate of the results of the treatment, the personal equation must be given a large place.

Instillation of Eardrops.—Eardrops are employed (1) for softening masses of cerumen; (2) as dissolvents for the removal of inspissated crusts, scales, mucus and pus; (3) as antiseptics and deodorants; (4) for astringents, styptics and cauterants in the middle ear; (5) for local anesthesia, all of which are fully described in the various special chapters. In order to properly instil drops into the external auditory canal the patient should either lie down or the head should rest horizontally upon a stand or table with the affected ear upward. The canal may thus be filled from a glass dropper. The entrance is also facilitated by gently moving the external ear in a somewhat rotary manner, at the same time lifting it. Very cold fluids should never be used. Oils are contraindicated except as a dressing for dermatitis, or for scaly eczema of the external canal.

A simple method for heating eardrops is by immersing the uncorked bottle containing the fluid in hot water. After the instillation the ear should remain in the same position for four or five minutes, until the fluid has had sufficient opportunity to permeate the entire cavity. Should both ears be under treatment the same process may be repeated. If necessary to save time one canal may be entirely filled with the fluid and the entrance corked by a firm plug of absorbent cotton, the remaining one then receiving the same treatment. Various kinds of drops are used according to the requirements of the case.

Insufflations.—At the present time the insufflation of powders into the external auditory canal and middle ear for medicinal purposes is extremely limited. Until recently all cases of purulent otitis media were treated by insufflating the external canal and possibly the tympanic cavity with boric acid, or some other form of medicated powder. This form of routine treatment has, very properly, been abandoned, for, instead of absorbing and devitalizing the pus, the powder seemed to dam up the discharge, adhere to the walls of the canal, and thus become most difficult to remove, even by forced syringing, and altogether do more harm than good. A small quantity of boric acid insufflated directly into the tympanic cavity through a long cannula during the last stage of middle-ear suppuration hastens the healing process by direct contact with the

tissues upon which its effect is desired. It is not uncommon in clinic patients to be obliged to remove masses of iodoform or boric acid which have remained in the external auditory canal for several months.

Local Anesthesia in Operative Procedures Upon the Ear.—The local application of solutions of cocaine, eucain or alypin to the lining of the auditory canal or an intact membrana tympani produces little or no anesthetic effect. If injected underneath the skin at or near the point of incision anesthesia is produced, but at the expense of a painful needle prick. Efforts have been made to augment the anesthetic effect by the addition of other drugs, and it has been found that a solution made up of equal parts of the crystals of cocaine, carbolic acid and menthol—

℞ Cocaine (crystals),
Acidi carbolici (crystals),
Menthol (crystals) .....ää ʒj.
Sig.: Mix carbolic and menthol crystals, then add cocaine crystals.

has considerable anesthetic effect, especially upon the membrana tympani. These solutions act slowly and require at least twenty minutes for full anesthetic action. Before instilling the anesthetic solution the head should be bent, with the affected ear turned upward and the drops held firmly in position by means of a pledget of cotton pressed into the external meatus. Symptoms of toxemia rarely occur unless large perforations already exist. Anesthesia thus produced is usually sufficient to considerably lessen the pain of a paracentesis or abscess incision in the canal. A hypodermatic injection of a 1 per cent. solution made at the point of attachment of the membrane with the upper wall of the canal (Fig. 180) will produce sufficient anesthesia to admit of paracentesis, and would be ideal for this purpose but for the pain produced by the needle puncture, which is almost as severe as the paracentesis.

When the above mentioned formula is employed it becomes necessary afterward to instil a few drops of alcohol into the canal in order to counteract the escharotic effect of the carbolic acid.

According to Neumann, Day and Beck, simple and radical mastoid operations may be performed under local anesthesia by making deep injections of cocaine posteriorly between the membranous and bony canal walls, and subperiosteally over the cortex and at the zygoma, the mastoid tip and midway between these two points (Fig. 52). The solution should never be stronger than 1 per cent. cocaine in 1 to 5000 adrenalin.

The removal of granulation tissue from the external canal or tympanum, either by curet, snare (Fig. 179) or cautery, is rendered comparatively painless by instilling the solution of cocaine, menthol and carbolic acid, or by injecting a few drops of a 4 per cent. solution of cocaine into the growth. When perforations exist considerable anesthetic effect may be produced by the intratympanic application of the above solution, or by applying the crystals of cocaine direct. A 10 per cent. solution of cocaine in a 1 : 5000

solution of adrenalin, instilled into the tympanic cavity through a perforation, insures good anesthesia and controls hemorrhage at the same time. Dangerous physiological effects of cocaine result from the careless use of excessive quantities or strong solutions.

Before instilling cocaine the ear should be thoroughly cleansed with a warm normal salt solution and the whole area carefully dried. There is less danger of inducing toxemia from a few crystals applied directly to the part to be anesthetized than from a weak solution indiscriminately applied to a large mucous surface.

Local anesthesia thus produced is quite sufficient in plucky individuals for the performance of ossiculectomy, with curetment of the attic and tympanic cavity, with the advantage to the operator of the upright posture and less hemorrhage. It is contra-indicated for this operation in timid and neurotic patients and when extensive curetment is required.

Pulverized orthoform blown upon the mucosa produces a similar effect, the anesthetization being more permanent. The sub-

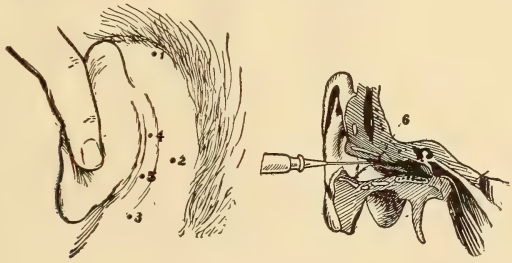

Fig. 52.—Points for the subperiosteal injection of cocaine to induce local anesthesia of the mastoid process.

cutaneous injection of a 1 per cent. solution of cocaine has proved sufficient for the painless removal of portions of the concha, and cancerous conchas have been removed under local anesthesia.

Ethyl chlorid is useful for minor operations about the ear in locations where it may be successfully applied by the usual method.

Incision of the Drum Membrane (Paracentesis).—Incision of the membrana tympani, or paracentesis, the indications for which are more fully described in Chapter XVIII, is an operation which is performed for the purpose of obtaining access to the middle ear from without, and of releasing retained secretions from the tympanic cavity proper and its accessory sinuses. It is chiefly employed to facilitate the drainage of pus in purulent otitis media, thereby becoming a valuable curative measure, and its performance for this purpose meets with the universal endorsement of otologists. The operation is rarely indicated in catarrhal inflammations, or for diagnostic purposes.

Preparation of the Patient.—The external ear and canal should be sterilized as thoroughly as possible by removing cerumen or other *débris,* with douche or moist cotton probe. Thorough douch-

ing of the external meatus with a quart or more of solution of bichlorid of mercury (1:4000), at a temperature of 110° F., is the most effective cleansing measure now employed. Asepsis will be more nearly attained by filling the external canal with alcohol or hydrogen peroxid for about five minutes immediately after using the bichlorid douche, the affected ear being turned upward, and the hairy portions rubbed with a cotton probe saturated with the



Fig. 53.—Electric ear speculum.

same solution. The deeper portions of the canal cannot be scrubbed without breaking down the delicate dermoid lining.

The nose and nasopharynx should be thoroughly cleansed of retained secretions, in case a subsequent inflation may be required.

Slides for smears or a culture medium should be at hand in order that an uncontaminated specimen of the infection may be secured for a laboratory examination.

The hands of the operator and all instruments are to be thoroughly sterilized and no precaution neglected to prevent the in-

Fig. 53*a*.—Pocket electric ear speculum.

gress of infection from without, always an unfortunate occurrence inasmuch as secondary infection complicates the case and tends toward chronicity. Under all circumstances a paracentesis is an extremely painful procedure, and especially so when performed upon a swollen and inflamed drum membrane, in a patient who has become hypersensitive from long suffering and loss of sleep. Whenever possible it should be performed under an anesthetic. The ideal anesthetic for this purpose is nitrous oxid gas, as narcosis produced by nitrous oxid gas is of sufficient length to allow of a complete and thorough paracentesis, and at the same time is quickly recovered from without disagreeable sequelæ.

If for any reason a general anesthetic cannot be given, much of the pain may be alleviated by an instillation of the local anesthetic mentioned on page 94 of this chapter.

If performed without an anesthetic the incision should be made with great preciseness and speed and completed before the patient has time to interfere.

The field of operation is to be illuminated either by bright reflected light, electric headlight (Fig. 7), or a speculum in which a small electric illumination lamp is concealed (Fig. 53). A speculum large enough to slightly stretch the soft tissues of the external canal gives the best view of the drum. With local anes-

Fig. 54.—Paracentesis bistoury.

thesia or nitrous oxid gas the operation is performed in the upright posture, which retains the landmarks in their upright position, while in the recumbent position a reversal of the relative position of the landmarks occurs, which the operator must bear in mind. The incision should be made with a sharp paracentesis bistoury (Fig. 54), its location depending upon the conditions present in the individual case.

In purulent cases with decided bulging of the drum membrane, and in other forms of inflammation or traumatism attended with sufficient exudate into the tympanic cavity to cause bulging and

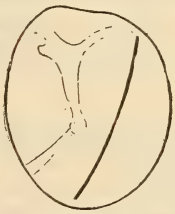

Fig. 55.—The heavy dark line indicates the incision commonly required for opening the drum membrane.

displacement of the drum membrane, the incision should divide all that portion of the drum at which the bulging is most prominent. Generally this will be found in the posterior inferior quadrant (Fig. 55), but in severe cases the entire drum, attic and the postero-superior canal wall may be intensely engorged and swollen.

A paracentesis incision should always be large in order to allow free escape of the secretion into the auditory canal and further to obviate the necessity of repeating the procedure. The incision should be so placed that the opening will extend from near the floor of the canal upward through the entire bulging portion of the membrane, carefully avoiding contact with the incus and stapes (Fig. 56). American surgeons usually incise the drum from below

upward, while among foreign surgeons the reverse is true. The point of the instrument must not penetrate too deeply into the tympanic cavity, although some authorities recommend the division of the inner wall of the tympanic cavity in the region of the promontory, for the purpose of local depletion—a procedure which is of doubtful value and liable to open up a new field for infection to enter; nor should the ossicles be wounded. The incision should be so arranged that the greatest possible number of radiating fibres will be severed, which will tend to promote the gaping of the wound and prevent too rapid closure. An incision running parallel to the malleus shaft in the posterior quadrant (Fig. 55) serves this purpose. In severe purulent cases the bulging involves Shrapnell's membrane, with infiltration of the posterosuperior wall. The fact that Shrapnell's membrane consists of but two layers, the cutis and the mucosa, with the absence of the strong lamina fibrosa, accounts

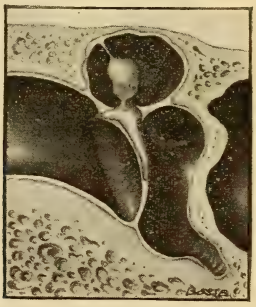

Fig. 56.—A lateral view of the inner portion of the external auditory canal and tympanic cavity, showing the relation of the ossicles to the membrana tympani.

for its lack of resistance to pressure from pent-up exudate, and explains why it quickly distends. In order to more perfectly drain the epitympanic space, as well as for purposes of local depletion, it is wise to incise it (Fig. 57, *A*), but the indications are best fulfilled by extending the original incision upward through the posterior fold (Fig. 55), thus severing the numerous reduplications of Shrapnell's membrane. If further depletion is desired, the incision may be extended outward through a portion of the drooping canal wall. The latter procedure is recommended by Dench and others.

Existing perforations in acute cases are usually too small or are located too high up to permit free drainage; hence, it becomes necessary to enlarge the openings.

If the small perforation is located in the upper segment of the drum membrane (Fig. 57, *B*) the incision should commence at that point and be extended downward to the periphery. But when the small perforation is located lower down the incision should be extended downward to the periphery and upward throughout the entire area of bulging (Fig. 58, *A*).

It is meddlesome surgery to open the drum membrane for purposes of exploration or for depletion alone, inasmuch as equally effective results may be obtained by local bloodletting elsewhere.

Immediately following the incision the ear should be douched with a warm solution of bichlorid of mercury, 1:4000, or normal salt solution, through a suction douche (Fig. 50) or fountain syringe, and every possible measure inaugurated to prevent the entrance of extraneous infection, the watchword being cleanliness and free drainage (Chapter XVIII).

A secondary paracentesis is occasionally required on account of the tendency to early closure of the wound before the pathological manifestations have subsided.

Depletion by Local Bloodletting.—Depletion locally applied to the tissues about the ear in the form of real or artificial leeches, wet cups or incision, was formerly employed in the treatment of acute purulent and catarrhal otitis media, mastoiditis, acute myrin-

Fig. 57.

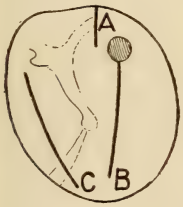

Fig. 58.

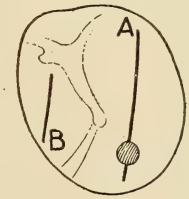

Fig. 57.—Incision of the drum membrane. *A,* Through Shrapnell's membrane. *B,* From a perforation downward. *C,* Incision made anterior to and parallel with the malleus.

Fig. 58.—Incisions of the membrana tympani. *A,* Enlarging a perforation. *B,* Short anterior incision.

gitis, hyperemia and hemorrhage within the labyrinth, upon the theory that the removal of blood from an inflamed area relieved congestion and removed a proportionate quantity of the inflammatory products and toxins. The procedure usually results in some relief of congestion and pain, but no permanent benefit is accomplished.

In acute purulent otitis media local bloodletting should never supersede paracentesis. The most effective and satisfactory means of local depletion in acute aural inflammations of sufficient severity to require a paracentesis is to extend the paracentesis incision upward and outward into the inflamed and swollen tissues of the canal wall, thus dividing the blood-vessels freely and producing copious hemorrhage. It has been described as an internal Wild's incision.

Artificially Induced Hyperemia.—In regard to the applicability of Bier's method (Fig. 59) in the treatment of ear disease, there is a wide divergence of opinion among the various observers who have personally investigated its clinical value. It has been estab-

lished, in a general way, that the congestion is readily tolerated, and often relieves pain; but this method has never come into general use nor is it employed in the larger special hospitals for diseases of the ear, nose and throat.

Vaccine Therapy.—Here is a broad field for research and experimentation and one replete with possibilities. The working theory of opsonic therapy is outlined by Beck[2] and is as follows:

1. Bacteria infecting the body are attacked by leucocytes which ingest them.

2. The number of bacteria which can be ingested is of varying quantity.

3. The number of bacteria which can be ingested depends upon their preparation by substances present in the plasma of the blood known as opsonins.

4. Opsonins are supposed to exert some influence upon bacteria, by which they become prepared for ingestion by the leucocytes. It has also been found by experiments that normal blood

Fig. 59.—The Bier treatment by constriction band about the neck. (*Kopetzky.*)

varies but little in opsonic strength, while in individuals who are infected the opsonic strength is materially lessened. Hence, in infected persons with lowered opsonic strength, but few bacteria are prepared for ingestion by the leucocytes.

The opsonic index is founded upon the ratio borne by the number of bacteria which become ingegsted by the leucocytes in infected individuals to that of the normal or healthy person.

Reduced to percentage—if within a given time 10 bacteria are ingested by the leucocytes in health while but 5 bacteria of similar type are ingested by one infected, the opsonic index of the one infected is 0.5.

The opsonic index is increased by injecting into the infected person dead cultures of the particular type of micro-organisms (preferably from his own body) from which he is suffering.

Should future experiments establish the earlier claims made by those who have experimented widely, notably Wright, and Douglas,[3] the era will mark an epoch-making advance in therapeutics.

---

[2] Transactions American Laryngological, Rhinological and Otological Society, 1908, p. 459.

[3] Proceedings of the Royal Society, vol. lxxiii and lxxvii.

The Hiss Leucocyte Extract.—In the following communication Dwyer gives a brief *résumé* of his experiments with the Hiss leucocyte extract in purulent affections arising from the ear and nose. Several of the cases treated have occurred in the author's service at the Manhattan Eye, Ear and Throat Hospital.

"Every clinician is aware of the importance of the leucocytes in the struggle against infection from microörganisms. The method heretofore pursued in treating these diseases has been to stimulate and support the patient until either the infection or the

Fig. 60.—Suction apparatus for inducing local hyperemia. (*Fowler.*)

patient's resistance proved the stronger. Experimental studies have seemed to warrant the employment of a more natural and hence a more rational method of combating these organisms by injecting into the circulation an extract of rabbits' leucocytes, which, when thus injected into the patient suffering from such infections as arise from the pyogenic organisms, seems to favorably modify the course of these infections. The experimental results in rabbits and the results obtained in human beings by the treatment with this extract were reported by Hiss, the author of this therapeutic measure, in the *Journal of Medical Research,* volume xix, No. 3.

"The results of Hiss were most gratifying. Dwyer employed the Hiss leucocyte extract in the treatment of 21 cases during one year for

varying periods and with gratifying results. Ten of this series were considered by the attending surgeons as desperate and probably fatal cases. Seven of these or 70 per cent. survived. In the complete series there was, with one exception, some response to the injections of the extract, the change generally noted being improvement in the general condition and in the delirium. In the majority of cases the latter symptom disappeared. In several there was a decided change in the temperature, a drop of 2 or 3 degrees taking place in a few hours. Four cases of erysipelas, occurring within a few days after the mastoid operation, recovered quickly; the erysipelas ceased to spread and the duration of the disease was apparently shortened. One of the main points in connection with these cases was the fact that the wounds remained perfectly healthy and healed in about the average time of an ordinary mastoid wound, which is contrary to the usual experience. The cases of pneumonia were much improved, as shown by the immediate lessening of the dyspnea, the improvement in the pulse and the general condition. One case of meningitis, complicating frontal sinusitis, responded very quickly to the extract and was discharged cured. Another similar case was slightly improved, but eventually succumbed. The most striking and satisfactory series comprised those of mastoiditis, complicated by sinus-thrombosis. The ligation of the jugular vein localizes to a large extent the septic process and prevents further infection, but sufficient septic matter has generally been absorbed to keep up the symptoms of sepsis for some days and in some cases to eventually overwhelm the patient. This class quickly responded to the injections and thereby were tided over a crucial period in their illness.

"The reports of others bear out the above results. Floyd and Lucas, of the department of bacteriology,[4] report 41 cases of pneumonia so treated with a mortality of 5, or 12⅕ per cent. This death rate is much below the average, as the prevailing mortality during the last five years at the hospital where these cases were treated was 21 8/10 per cent. Also, a comparison of a series of 25 cases treated with the extract and 25 treated by the ordinary means shows a mortality of more than double in the series of the untreated cases.

"Dr. Adrian Lambert, New York City, reports 51 cases of erysipelas so treated. His conclusions were that when the injections of the leucocyte extract were commenced within forty-eight hours of the onset the extract acted almost as a specific. In average cases, regardless of the time of inception of the treatment, the symptoms were much alleviated, the general condition much improved and the complications and sequelæ fewer and less severe. One of his series was interesting: six cases of infants under one year of age were treated with the extract with a mortality rate of 33⅓ per cent. His previous mortality rate with such cases had been 100 per cent. The evidence at hand seems favorable to this mode of treatment, and my conclusions are as follows:—

[4] Harvard Medical School, Journal of Medical Research.

"1. In no case has the extract done any harm to the patient treated. 2. No local reaction was observed at any time and the tumefaction produced by the injection of such a large amount of fluid was absorbed with great rapidity. 3. The chief advantage from a practical point of view is that the effects of the extract are apparent within a few hours after its use. 4. We inject into the body only substances which are normally present there. 5. There is no necessity of isolating the offending organism as must be done in the use of vaccines, and this is of importance in those obscure septic cases where we cannot isolate the organism.

"Such a method of treatment seems peculiarly suitable in the treatment of the systemically acute infections with the ordinary pus organisms. The consensus of opinion, as gleaned from the reports of those who have treated a series of cases with the vaccines, is that the latter are more suitable to chronic cases and that in fact much harm may result from their use in the acute infections when accompanied by general systemic symptoms. This has been the writer's experience, and if we are to use vaccines in such cases, then we must revise our whole conception of how antibodies and vaccines operate in the system. There are no objections to the extract, as the use of the latter does not call for the active participation of the system in the process.

"Analyzing as far as possible the action of the extract, it would appear that it does not act through the bactericidal, bacteriolytic or phagocytosis-stimulating power, but that its marked favorable influence on the general condition and in some cases on the temperature is in all probability referable to its neutralization of the toxic products, that is, ordinarily speaking, to its combating the condition spoken of as septic or toxemic.

"The extract is administered subcutaneously twice daily in doses of 10 c.c. It may be given more frequently if necessary. The soft tissues either at the back of the abdomen or buttocks should be selected for the site of puncture. It is necessary to keep the supply of extract in a cool place."

Blood-pressure.—Hubby[5] has found that the determination of blood-pressure (Fig. 302) is sometimes of value in suspected intracranial complications of suppurative diseases of the ear. The Janeway sphygmomanometer was used, the patient always being in a horizontal position. He states that it is only of value when frequently taken—*i.e.*, several times a day. He found that an exploratory operation was indicated in suppurative diseases of the ear (other causes of high blood-pressure not being frequent), on the finding of high blood-pressure associated with such symptoms as beginning edema of the optic papilla, and vertigo.

[5] Medical Review of Reviews, January, 1908.

SECTION II.

The External Ear.

CHAPTER IX.

SURGICAL ANATOMY.

THE external ear constitutes the most external of the anatomical divisions of the organ of hearing, and is composed of (*a*) the auricle (pinna); (*b*) the external auditory canal (meatus auditorius externus).

The Auricle.—The auricle consists of a thin, pliable, irregular, fibrocartilaginous framework enveloped in perichondrium and skin. The skin is thrown into folds and projections, the most extensive of which is at its lowest surface, where a large, loose, dependent fold of integument envelops a quantity of adipose tissue, but no cartilage.

The posterior surface of the auricle is generally convex, except near its free border, and is fairly smooth, while the anterior surface is generally concave, presenting numerous irregularities which form elevations and depressions. The attachment of the pinna is by extension of its cartilage into the external auditory meatus and the continuation of its integument to that of the temporal and cheek region. Normally the attachment to the temporal bone is at an acute angle. The nomenclature and illustration of the various folds, concavities, ridges, crura and notches are found in Fig. 61.

There are marked variations in the anatomical outlines of the auricle within even normal limitations, while malformations, anomalies and deformities occur in a variety of forms. Among the variations in size it will be noted that the pinna of the male is larger than that of the female, the right is usually larger than the left, and there is a tendency toward increase in length, in old age. Other variations have been noted by alienists in the criminal and the degenerate.

The integument of the auricle is thin, containing sebaceous glands, and in some locations hairs. Its attachment to the concave surface is considerably firmer than to the convex. There is but little subcutaneous fat present except in the lobule.

A number of rudimentary muscles are found on both the anterior and posterior surface of the auricle. These are of anatomical value only, and are not herein described.

The arterial supply of the pinna comes from the posterior auricular, the occipital and the superficial temporal arteries.

The pinna receives its sensory nerve supply chiefly from the auriculotemporal and the auricularis magnus; the motor supply

is derived from the facial nerve. Numerous lymph channels traverse the auricle.

The External Auditory Canal.—The external auditory meatus extends from the concavity of the concha to the margin of the tympanic membrane. The outer or cartilaginous portion extending inward passes upward and slightly backward, while the bony canal extends inward, downward and usually slightly forward, the highest level of the canal being at about the junction of the cartilaginous and osseous portions.

Fig. 61.—The normal auricle with landmarks.

The cartilage is absent along the superior and posterior portions of the canal, its chief direct attachment to the bony portion being in the form of a flattened process (the processus triangularis).

The outer, cartilaginous portion and the inner, bony portions are connected by coarse connective tissue which is rich in elastic fibres. Fibrous tissue also fills in two or three vertical fissures which are found in the anterior wall of the cartilaginous canal and which are known as Incisuræ Santorini. The larger of these is located near the base of the tragus. They add to the mobility of the cartilaginous meatus and are of clinical importance inasmuch as abscesses of the parotid sometimes rupture spontaneously through them into the auditory canal. In operations on the mastoid process and other operations in this region which require a posterior

incision, the dehiscences enable the operator to turn the pinna and membranous canal well forward and thus gain sufficient space for his manipulations.

The posterior wall of the external auditory meatus does not extend outward as far as the anterior, and any individual peculiarities in the orifice are generally due to variations in the size and position of the tragus plate. The contour of the external auditory

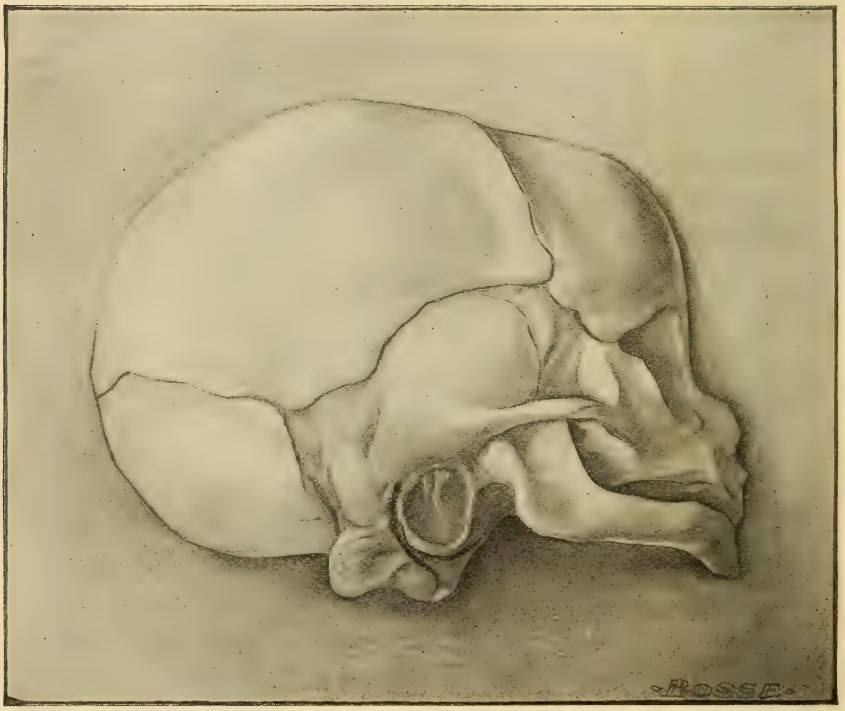

Fig. 62.—Outer aspect of the right side of the cranium of a fetus at birth, showing entire absence of the osseous meatus, mastoid tip, the drum membrane and ossicles *in situ.* (From Dunning's collection.)

meatus is somewhat irregular, cross-sections showing variations of form and size. The anterior and inferior walls are of greater length than the posterior and superior on account of the oblique position of the tympanic membrane. The length of the posterior superior wall averages about 24 mm., while that of the anterior inferior wall is about 35 mm.

In the newborn the pinna shows well-developed furrows and a fossa between the lateral convex folds, which, in the embroyo, lie so close together as to form very narrow fissures only. Schwalbe speaks of the flower-like unfolding after birth of the heretofore closed aural bud.

Morphologically there is a lumen in the external auditory meatus in the newborn; physiologically there is not, the internal, wedge-shaped tympanofibrous section being closed by desquamated epithelial cells, and the relatively wide outer funnel being filled up with vernix caseosa. On the removal of this external auditory meatus in the newborn it appears as a relatively narrow fissure flattened from above downward. At about two months of age the anterior and posterior walls have become differentiated.

The osseous portion of the canal is not present at birth (Fig. 62), but is represented by a partially formed bony ring, the annulus tympanicus; meanwhile all the sutures and fissures are still wide open. In the adult, however, the roof of the bony meatus is formed by an outgrowth of the squamous process of the temporal bone. The anterior, inferior and lower portion of the posterior walls are formed from the tympanic process, while the superior and upper posterior sections develop from the squamous plate of the temporal bone.

Some weeks after birth an increase of substance takes place on the tubercles at the lateral sides of the tympanic ring. The rapid growth of the tubercles and the simultaneous increase of substance in the whole tympanic ring lead to the bridge-like union between them, which is usually complete at the end of the first year. A gap or dehiscence filled with fibrous tissue remains between the lower periphery of the ring and the bony ridge which forms the outer section of the anterior and lower wall of the meatus. This gap usually becomes filled by bone about the third year, but it may persist up to the sixth year, and occasionally bony union never becomes complete. This dehiscence is of surgical significance, inasmuch as pus from the auditory canal may burrow through it into the inferior maxillary articulation.

The formation of the superior wall of the meatus out of the squamous portion of the temporal bone proceeds in such a manner that the squama proper above the temporal line retains its position, while the part situated below the temporal line gradually projects and assumes a horizontal position, in apposition with the anterior and posterior walls.

The relation of the walls of the adult osseous meatus is as follows:—

(*a*) **The Superior Wall.**—The superior wall is directly in relation to a layer of diploë of varying thickness, often with pneumatic cells which extend along the zygoma. Overlying the diploë is found the denser inner table which forms the floor of middle fossa. The section of bone between the superior canal wall and the middle fossa varies in thickness from 2 to 14 mm.

(*b*) **The Anterior Wall.**—The superior maxillary articulation and a portion of the parotid gland lie directly in front of the anterior wall, from both of which it is separated by an exceedingly thin plate of bone.

(*c*) **The Inferior Wall.**—The dense bone of the lower wall is in relation to the parotid gland.

(*d*) **The Posterior Wall.**—The posterior wall of varying thickness lies in direct relation to the mastoid cells. In its lower posterior portion it is in relation with the facial canal. In rare instances the sigmoid sinus passes close to the posterior canal wall.

The importance surgically of the development of the bony external auditory meatus becomes evident when operating upon the mastoid process during infancy, inasmuch as the relative position of the mastoid antrum to the infantile auditory meatus differs from its anatomical relationship in the adult, and the anatomy of the parts in infancy must therefore be well known, when operating.

The integument of the auditory meatus is exceedingly thin and delicate and lacks the resisting power observed in the integument of more exposed portions of the body. It is almost immovably attached to the structures lying underneath. The cartilaginous portion of the meatus contains hairs and sebaceous glands, also ceruminous glands, from which cerumen or ear wax is secreted. In the osseous portion no hair or glands are found. An exceedingly thin section of integument also forms the outer layer of the tympanic membrane.

The external auditory meatus receives its blood supply from branches of the posterior auricular, superficial temporal and external maxillary arteries, the accompanying veins emptying into the temporal, posterior auricular and internal maxillary veins.

The sensory nerve supply of the meatus comes from branches of the auricularis magnus, the auricular branch of the vagus, and the auriculotemporal, the motor supply coming from the seventh cranial.

Lymph channels are also found which communicate with the posterior auricular lymphatic glands and the parotid.

CHAPTER X.

DISEASES OF THE EXTERNAL EAR.

Eczema.—(*a*) Eczema intertrigo; (*b*) eczema acuta; (*c*) eczema chronica; and other skin lesions.

(*a*) ECZEMA INTERTRIGO.

This affection is characterized by epithelial desquamation and serous exudate without infiltration of the deeper dermal layers.

Etiology.—The pernicious custom of pressing or binding the ears of infants and young children to the side of the head by means of close-fitting caps or bandages is the chief cause of this disease. This procedure brings the posterior surface of the pinna into close contact with the cutaneous surface of the mastoid process, and thus the moisture and the normal dermal exudate collect in sufficient quantity to produce burning and itching, which the child attempts to relieve by rubbing or tearing at the binder. The superficial epithelium finally macerates and desquamates, leaving the raw surface of the deeper dermal layer exposed. Neglected children whose ears are rarely cleansed, whereby filth is allowed to collect about the ear, are prone to scratch and rub the parts until large surfaces become chapped, especially about and above the posterior attachment of the auricle. Additionally there is a copious irritating serous exudate which adds to the patient's discomfort.

Unless checked by treatment, infiltration of the deeper layers ensues, with a resultant true eczema.

Symptoms.—Superficial hyperemia is the first observable sign. This is soon followed by excessive moisture of the parts, and as desquamation progresses the secretion becomes copious. Burning and pruritus are severe, and are aggravated by the efforts of the child to relieve its suffering. Whenever the secretion is allowed to remain it becomes foul, malodorous and forms crusts which resemble sloughs.

Treatment.—The denuded surfaces should be cleansed with warm water and covered with vaselin, over which bismuth, aristol, or stearate of zinc may be shaken.

If necessary, the denuded parts may be separated by layers of gauze; applications of cold cream or equal parts of lanolin, vaselin and zinc ointment may be applied. It is essential to remove the primary cause of the affection, which, as a rule, is filth and the pernicious habit of binding the ears, or wearing tight-fitting caps for prolonged periods of time.

It is important to differentiate true eczema from excoriations and other forms of dermatitis to which the external ear is subject.

(*b*) ACUTE ECZEMA.

Acute eczema of the ear is characterized by local inflammatory swelling and redness of the ear, upon which numerous vesicles or blebs appear. The disease usually appears about the external meatus or behind the ear, along the groove which marks the attach-

Fig. 63.—Eczema of the auricle.

ment of the auricle to the head. From either of these points it may spread over the entire auricle and extend to the adjoining surfaces (Fig. 63).

The secretion is usually serum, sometimes tinged with blood. This exudate lifts the epidermis in vesicles or sweeps it entirely away.

Etiology.—A definite cause for aural eczema is not always determinable. The disease occurs primarily as a result of local irritation of the parts. The more common irritant is purulent aural discharge, especially when allowed to flow without the intervention of proper cleansing measures. Excessive cold from frostbite, or

the application of icebags; excessive heat from the injudicious employment of hot-water bags, and douches; accidental scalds and sunburn; local applications of iodoform, mercurial and other ointments, are among the local exciting causes of acute eczematous inflammation.

Intertrigo has been mentioned previously as a forerunner of both acute and chronic eczema. Prominent among the predisposing causes are heredity, gout, rheumatism, leukemia and malassimilation from various causes, notably overfatigue, and unwholesome or insufficient nourishment.

Symptoms.—A sharp burning sensation, followed by pruritus, marks the onslaught of the disease. Whenever the external canal is involved the swelling may be sufficient to block off its lumen and produce temporary deafness and tinnitus.

A moderate elevation of temperature is observed in young children. Restlessness and sleeplessness result from the pruritus, the latter being often noted if the surfaces are rubbed or scratched. As the vesicles rupture, the retained secretion covers the denuded surface, forming yellowish crusts, thus constituting the exudative stage of the disease. If the crusts are allowed to remain unmolested, the subsequent secretion, which accumulates underneath, becomes infected. This aggravates the local irritation and proportionately increases infiltration and thickening of the deeper layers.

The disease may run a long or a short course. In the milder cases, which result from local irritation, the vesicles quickly rupture, or the secretion becomes absorbed and the epidermis exfoliates at the end of three or four days. In severe cases the exudate may persist for some days, then disappear; or it may become purulent and persist indefinitely or until checked by appropriate treatment. In those who are subject to the disease elsewhere, or who are otherwise predisposed, an acute attack about the auricle may result in the development of the chronic form. The treatment of this disease is outlined in connection with that for chronic eczema.

(*c*) CHRONIC ECZEMA.

The chief characteristics of the chronic eczema are inflammatory thickening of the deeper dermal layers, persistent epithelial desquamation, and an aggravating pruritus.

Etiology.—The disease results from the acute forms in all cases. It is usually curable, but recurrence is common. In a small percentage of cases the disease persists throughout life, resisting all forms of treatment. The employment of earspoons, hairpins or other mechanical means for the relief of the pruritus, and the removal of scales from the canal aggravate the affection and often result in infection of the deeper tissues and the formation of furuncles. It is quite common to discover patches of eczema squamosum in the external meatus among individuals addicted to the use of narcotics, especially opium.

The disease may extend over the entire auricle, but usually it

is localized in and about the external meatus. The firm, red unyielding surface may be covered with scales or vesicles and traversed by fissures.

Efforts to relieve pruritus by scratching result in abrasions, increased exudate and sometimes hemorrhage, and occasionally furuncle.

In the chronic form the eczematous patches remain dry and scaly except in the fissures, or during periods of exacerbation. When the external auditory canal is the seat of the lesion, its lumen becomes much narrowed as a result of hyperplasia. This, together with the copious proliferation of flaky scales, serves to occlude the canal and interfere somewhat with audition.

In some individuals the scales protrude from the meatus and drop into the concavity of the concha or upon the clothing; or, if there is a pus discharge, an admixture is formed which becomes foul and irritating.

Itching is less intense than in the acute variety; nevertheless it may be sufficient to cause general nervous depression. Patients are prone to use earspoons, hairpins, matches or finger-nails to relieve itching, with considerable danger of inducing dermatitis.

Atrophy or destruction of the ceruminous glands is a remote consequence of chronic eczema of the external meatus, with a resultant partial or complete cessation of fluid cerumen.

Treatment.—Successful treatment of aural eczema requires a preliminary, painstaking, general examination, in order to determine the underlying cause for the disease.

Constitutional dyscrasias and neuroses should be corrected by proper attention to diet, occupation, habits and environment, and also by the administration of corrective tonic remedies in the form of cathartics, bitter tonics, iron, arsenic, strychnine, and iodin in proper combination to meet the requirements of each individual case. Arsenic leads the list in the treatment of chronic, scaly eczema, and should be given in the form of Fowler's solution, 5 to 10 drops. It should be withheld upon the first appearance of an acute exacerbation. For further details of general treatment the reader is referred to text-books on skin diseases.

Local Treatment of Acute Eczema.—Before considering the local measures to be employed it should be noted that both the diseased and the surrounding surfaces should be thoroughly cleansed, and, while water is an irritant to eczematous surfaces, it is often necessary to employ it for the removal of accumulated filth or pus. Its irritating qualities are minimized by the addition of table salt, a teaspoonful to a quart of water, or boric acid, 80 grains to the quart.

Thereafter, the surrounding integument only should be kept clean by washing with warm water or green soap and water. The wearing of bandages, coverings or tight-fitting infant caps should be interdicted. Purulent discharge from the meatus must receive proper treatment inasmuch as it excites cutaneous inflammation and infiltration. And here the dry form of treatment is obviously to be

preferred. Wiping away the secretion two or three times daily is usually sufficient to protect the eczematous surfaces from pus. Whenever the syringe is needed for the removal of retained secretion from the canal and middle ear, a warm saline or boric acid solution should be employed. After drying, the canal surfaces, unless actively vesicating, should be dusted over with calomel, bismuth sublimate, stearate of zinc, lycopodium or aristol. Some cases recover promptly without further treatment.

For the relief of the subjective symptoms—heat, pruritus and tension—soothing lotions or emollients are indicated. The following combination, which may be varied to suit the requirements of the individual case, is recommended:—

Lotio calamine:—

℞ Acidi carbolici ..... ʒj.
Pulv. calaminæ ..... ʒij.
Pulv. zinci oxidi..... ʒiv.
Glycerini ..... ℥ss.
Aquæ calcis ..... ℥ij.
Aquæ rosæ .....q. s. ad ℥viij.

Sig.: Shake well and apply as a wet dressing.

A soothing emollient dressing is prepared as follows:—

℞ Zinci oxidi ..... ʒj.
Morphinæ acetatæ ..... gr. ij.
Lanolini,
Vaselini .....āā q. s. ad ℥j.

M. Sig.: Apply locally plastered upon gauze.

The subsidence of the more acute symptoms ushers in the second stage of the disease, wherein the formation of yellowish white crusts is a prominent symptom. The crusts are to be carefully removed so as not to injure the underlying tissue, and aqueous solutions should be avoided. It is sometimes possible to remove all crusts without delay by gently rubbing them with olive-oil or lanolin and wiping the surface clean with dry gauze, but it may be necessary to apply a softening emollient for from twelve to twenty-four hours. For this purpose almond-oil, lanolin, or vaselin, applied freely and covered with gauze and a roller bandage is recommended. In young children especially the bandage prevents laceration from scratching with the finger-nails.

Removal of the crusts is accomplished by means of forceps or blunt curette, care being taken to avoid injury to the deeper layers, thus aggravating the disease. In mild cases all that remains to effect a cure is to protect the denuded surface by applying vaselin or cold cream until the epidermis is re-established. Where thickening is marked the healing process is hastened and infiltration reduced by daily applications of nitrate of silver solution in gradually increasing strength, from 10 to 60 grains to the ounce; or,

℞ Ichthyol ..... ʒj to ʒij.
Ung. zinci oxidi..... ℥j.

M. Sig.: Apply with brush or smear upon gauze and apply.

Local Treatment of Chronic Eczema.—The treatment of the chronic form is attended with greater difficulties and the results are more uncertain in consequence of the long-continued dermatitis and deeper-seated hyperplasia. No attempt will here be made to even enumerate the numerous remedies recommended in the various text-books and pamphlets, many of which are of questionable value, but rather to outline a few that have given satisfactory results in the author's private and hospital practice.

The indications for local treatment are:—

(*a*) To soften and remove the scales.

(*b*) To reduce the hyperplasia.

In the chronic form more vigor may be employed in removing the scales, and with the distinct advantage of stimulating the circulation of the parts; hence, the affected parts should be smeared with vaselin, lanolin or olive-oil and rubbed with a cotton-tipped probe or dry gauze until freed from all exudate. It is even permissible in very chronic cases with deep fissures to occasionally make vigorous use of green soap in order to thoroughly cleanse the parts.

Any sign of an acute exacerbation is an indication that the remedies are too stimulating, and milder treatment should be substituted for a time.

After the parts are clean, stimulating and protective applications should be made. The following formulæ are recommended with the understanding that their proportions may be varied to meet the requirements of each individual case:—

℞ Oleum cadi ..... ʒj.
Ung. zinci oxidi ..... ℥j.

M. Sig.: To be applied either as a dressing or plastered on freely, and covered with gauze and a bandage.

℞ Acidi salicylici ..... gr. xx.
Zinci oxidi pulv. ..... ʒj.
Ung. rosæ ..... ℥j.

M. Sig.: To be applied freely.

Nitrate of silver is advocated by many, notably Politzer.

It should be applied in gradually increasing strength from 5 to 20 per cent. In the more subacute forms the ichythyol formula mentioned above is sufficiently stimulating.

When feasible the local treatment should be applied daily. It is unwise to place sole dependence upon any one local remedy; hence, a change from one to another is found to hasten the healing process, and evidences of overstimulation of the tissues may necessitate the cessation of all treatment for a few days. For the relief of persistent pruritus in the external meatus, Barnhill recommends the following:—

℞ Iodin (crystals),
Carbolic acid .....āā gr. x.
Rectified spirits ..... ʒj.

M. Sig.: Paint the walls of the meatus after having removed all loose scales.

The more obstinate the case, the more persistently must the treatment be applied. Relief is always attainable; permanent cure is sometimes impossible, and during the progress of local medication the relative importance of general treatment must be ever kept in mind.

X-ray and Radium Treatment.—During recent years dermatologists have recommended the proper use of the x-ray and of radium for the treatment of the very chronic cases of eczema.

HERPES ZOSTER.

Ramsey Hunt,[1] in two valuable publications, asserts his belief that herpes oticus, wherein the cutaneous eruption is limited to the

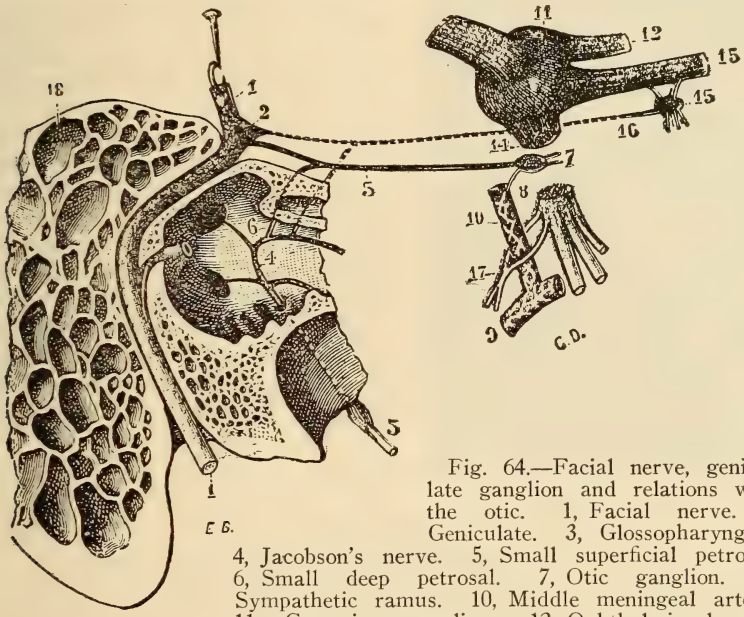

Fig. 64.—Facial nerve, geniculate ganglion and relations with the otic. 1, Facial nerve. 2, Geniculate. 3, Glossopharyngeal. 4, Jacobson's nerve. 5, Small superficial petrosal. 6, Small deep petrosal. 7, Otic ganglion. 8, Sympathetic ramus. 10, Middle meningeal artery. 11, Gasserian ganglion. 12, Ophthalmic branch. 13, Superior maxillary. 14, Inferior maxillary. 15, Sphenopalatine ganglion. 16, Vidian nerve. 17, Auriculotemporal nerve. (Testut's Anatomy.)

tympanum, external auditory canal, concha, tragus, antitragus helix and antihelix, is due to herpetic inflammation (posterior poliomyelitis) of the geniculate ganglion, the cone-shaped area of distribution being termed the zoster zone of the geniculate ganglion. While earlier authors have recognized the Gasserian gan-

[1] On Herpetic Inflammation of the Geniculate Ganglion. A New Syndrome and its Complications. Journal of Nervous and Mental Diseases, February, 1907. A Further Contribution to the Herpetic Inflammations of the Geniculate Ganglion. American Journal of Medical Sciences, August, 1908.

glion of the trifacial only, as the seat of an herpetic inflammation on a cranial nerve, he believes that the geniculate ganglion situated in the depths of the internal auditory canal at the entrance of the Fallopian aqueduct is the seat of this specific inflammation.

The peculiar situation of the ganglion within the confines of a bony canal (Fig. 64) and its immediate relation to the facial nerve and the auditory nerves are responsible for the characteristic complex symptoms which result.

The pathological researches of Head and Campbell have shown that the disease is characterized by a specific inflammation of the ganglia, which become infiltrated with exudate and often with extravasations of blood, and, further, that the inflammatory process may extend to the sheath and nerve roots. Anterior or motor root involvement results in paralysis. Complicating paralysis is common in herpes oticus. Hunt has collected 56 cases from literature and four from his case book, in all of which facial palsy accompanied the herpetic eruption, and attributes the phenomenon to the peculiar location and relation of the geniculate ganglion.

A severe type of the disease occurs when the acoustic nerve is also involved. In this form there are with the herpes oticus and facial palsy various auditory symptoms, ranging in severity from tinnitus aurium and diminution of hearing to the more severe forms of acoustic disturbance as observed in Ménière's syndrome.

The fact that these neural complications sometimes occur in herpes facialis, herpes occipitalis and cervicalis is explained upon the theory that while the inflammation may predominate in one ganglion, others nearby may participate in a milder form, the zones here named being controlled by the Gasserian, geniculate and cervical ganglia, which constitute together a continuous anatomical chain.

The geniculate variety is classified as follows:—

(*a*) Herpes oticus.

(*b*) Herpes oticus with facial palsy.

(*c*) Herpes oticus with facial palsy and hypo-acousis.

(*d*) Herpes oticus with facial palsy and Ménière's complex.

To complete the clinical types which occur in the region of the auricle, it is necessary to mention the other forms, viz., herpes facialis and herpes occipitocollaris, which belong respectively to the zones of the Gasserian and second and third cervical ganglia.[2] One of the author's cases gave the following history: G. N., age 50, had extremely painful herpetic eruption in the cavity of the concha for one week when a complete facial paralysis occurred The pain radiated from the ear, over the mastoid region and into the jaw of the affected side. The eruption did not involve the external auditory canal. There was no loss of hearing. He was obliged to give up his work for over two weeks, after which time both the eruption and paralysis began to improve, and in one

[2] The phraseology of the above remarks is taken largely from Hunt's papers, with such interpolations as have been found necessary to complete the text.

month his facial paralysis had practically disappeared. Scar tissue remains over the site of the herpetic spots.

Symptoms.—The initial stage is characterized by general malaise and slight fever. After a few hours shooting pains are experienced in the area involved, becoming most severe in some cases, and subsiding upon the appearance of the vesicles. There is marked swelling and redness of the skin for a period of two or three days preceding the appearance of the characteristic herpetic vesicles (Fig. 65). In herpes oticus the entire auricle may become red, swollen and project outward, and the external canal become narrow or occluded, with consequent difficulty in cleansing or draining, and with diminution of hearing. The vesicles remain from five to eight days, then desiccate. Infiltration gradually subsides and recovery takes place in about two weeks. Scars remain for some months, but are rarely permanent. Paresthesia may persist for some time.

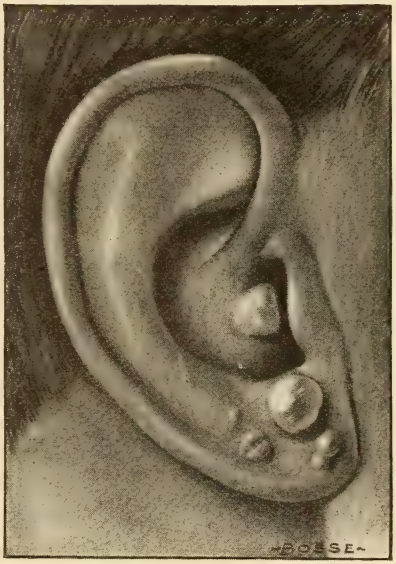

Fig. 65.—Herpes oticus. (Partly schematic.)

In class (*b*) complete facial paralysis appears about the time of the eruption and remains from a few days to several months, final recovery being the rule.

Class (*c*) is a type wherein disturbances of audition accompany the herpes in the form of tinnitus and hardness of hearing.

Class (*d*) is more severe, for, in addition to facial paralysis, the symptoms of Ménière's disease—vertigo, nausea, vomiting, tinnitus, deafness, and nystagmus are observed.

The relative frequency of herpes oticus is as follows:—

In 20,000 cases (Gruber) herpes of the auricle was reported in 5; in 65,000 cases at the Massachusetts Eye and Ear Infirmary herpes of the auricle was reported in 33; in 47,600 cases at the Manhattan Eye and Ear Hospital herpes of the auricle was reported in 2; in 15,000 cases at the Brooklyn Eye and Ear Hospital herpes of the auricle was reported in 1.

Treatment.—The treatment is expectant, and is aimed at relief from pain, reduction of temperature, and prevention of deep scars. Asperin, gr. v, or phenacetin, gr. v, will usually control temperature and pain when administered internally at intervals of four hours. In severe cases hypodermics of morphine may be necessary. The vesicles should be protected from accidental rupture and the irritation of the air by pads held in place by bandages. Some relief from the itching and burning will be obtained from dusting the surface with calomel, or stearate of zinc and boric acid.

PITYRIASIS CAPITIS.

This affection occasionally extends to the external ear, and is best treated by rubbing into the affected areas a mixture of green soap and alcohol in water, combined with the general use of tonics.

PSORIASIS.

Psoriasis involving the scalp, forming distinctly marked circles, may extend to the posterior surface of the concha. Its circular appearance and tendency to bleed are usually sufficient to establish the diagnosis.

Treatment.—The local lesion is usually curable for the time being, but it is more difficult to prevent its recurrence. There is probably some underlying diathetic disturbance for which appropriate treatment should be instituted. Locally, the Turkish bath tends to reduce inflammation, loosen scales and promote absorption. Pruritus is reduced by a lotion of carbolic acid 10 to 15 per cent. in glycerin,[3] or by nightly applications of chrysarobin in the following:—

Chrysarobin	10 parts.
Salicylic acid	10 parts.
Ether	15 parts.
Flexible collodion	100 parts.

Sig.: Apply to skin.

SEBORRHEA.

Two forms of seborrhea occur upon the auricle, the oily, seborrhea oleosa, and the dry, seborrhea sicca. It is an exceedingly troublesome condition, giving to the skin an unclean and unwholesome appearance. The oily form, or seborrhea oleosa, is the most common and is characterized in general by a smooth, oily appearance and the accumulation in the creases and folds of soft, oily, tenacious masses (sebum), with an admixture of flakes and scales of a dirty yellowish color.

In the dry form, seborrhea sicca, the skin, especially of the folds and creases, is covered with fine, flour-like scales or flakes. Pruritus is never severe and often absent, and there is no marked infiltration of the deeper dermal layers.

Treatment.—In seborrhea oleosa the secretion may be effectually removed by the frequent use of soap and hot water. After drying the skin apply precipitated sulphur or tannic acid.

In seborrhea sicca the scales are softened and removed by applying olive-oil, after which a stimulative ointment is rubbed in:—

Oil sweet almonds	10 parts.
Carbolic acid	1 part.
Alcohol	89 parts.
Oil bergamot	q. s.

Sig.: Apply locally.

[3] Fox, Photographic Illustrations of Skin Diseases.

PEMPHIGUS.

The disease is characterized by the formation of bullæ upon the helix or lobule. In severe cases pigmented spots remain after absorption. The disease runs precisely the same course as in other portions of the body. An acute benign form which runs a rapid course occurs in young children, and in hot climates a contagious endemic form is observed. It is a painless affection, and in uncomplicated cases the treatment consists of simple protection to the surface by a covering of gauze.

GANGRENE.

Gangrene of the concha is a rare affection, seldom developing spontaneously, or as a result of pressure. The most common causes of auricular gangrene are frostbite, phlegmonous inflammations, diabetes, measles and typhoid fever. The phlegmonous form is characterized by extreme redness of the surface (which does not disappear upon digital pressure), rise of temperature, swelling and tension. The enormous swelling of the concha tends to obliterate its normal outlines. In the circumscribed form the infiltration is limited to certain portions, such as the tragus or the lobule of the ear. In mild forms the phlegmon resolves without the formation of abscess or deep ulceration. When severe, the overlying integument becomes necrotic and sloughs away, leaving a deep-seated ulcer, which may involve the cartilage. Here, healing takes place by granulation. A rare form of gangrene has been described as noma. It occurs in infants and young children who are poorly nourished and the victims of constitutional dyscrasias. About the ear the gangrenous attack involves the cartilages in succession until a deep-seated necrotic ulcer is formed, which resists treatment and terminates fatally.

Verhoeff[4] reports such a case occurring in an infant of five weeks. The disease commenced in the cartilage of the external auditory canal and rapidly extended. General toxemia ensued, death occurring on the seventeenth day.

Autopsy.—Results showed streptococcic gangrenous ulceration of the auricle, middle ear and mastoid, with associated streptococcus bronchopneumonia, synovitis and croupous colitis.

Treatment.—There is invariably a predisposing cause, which should be discovered and appropriate treatment instituted, in the form of supporting and stimulating measures. Whenever gangrene is fully established it is important to stimulate and sustain the nutrition and circulation of the surrounding tissue, and to aid in the separation of the necrotic slough by warm applications to the skin, cleansing remedies to the ulcerated surface, removal of the sloughing masses by cauterizing with chemical caustics, galvanocautery or curette.

---

[4] Journal of the Boston Society of Medical Science, vol. v, May, 1901.

ABSCESS OF THE AURICLE.

Local infection with abscess formation may develop upon any portion of the ear from scratches, pinpricks, or piercing the lobule. These become infected and abscess results. They should be differentiated from perichondritis and sebaceous cysts.

WOUNDS OF THE EXTERNAL EAR.

The exposed position of the auricle renders it unusually susceptible to a variety of wounds and other injuries, many of which result from some form of combat. Simple incised wounds of the skin which remain uninfected heal by primary union. Even when surgical division of one or more layers of the concha has been made the results may be equally good. Lacerated and contused wounds, especially when the cartilages have been injured, are more serious and difficult to manage, both on account of infection and injury to the cartilages. Completely divided segments of the concha will sometimes heal even when suturing has been delayed several hours after the injury. The so-called piercing of the lobule for ornamental purposes is one of the more common wounds of the external ear. It is often performed by the laity with no regard for modern surgical asepsis. Sepsis results, which may extend even to the cartilaginous tissue or slough through to the periphery, resulting in fissure of the lobule. The usual treatment of wounds in general is applicable for these.

ERYSIPELAS.

From the standpoint of the otologist erysipelas assumes importance only when it occurs in connection with purulent otitis media, or following operations upon the mastoid. When it thus occurs it becomes a serious complication.

Erysipelas occurring in connection with a purulent middle-ear inflammation, whether acute or chronic, should occasion considerable anxiety, owing to the danger of middle-ear or mastoid involvement, since the erysipelatous infection is of the streptococcus type. Experience, however, has shown that the usual tendency of the disease is to spread over the integument of the face and head rather than toward the tympanum.

Following a mastoid operation its appearance is to be deplored for the following reasons:—

(*a*) The chills and extremely high temperature, which for from twelve to forty-eight hours precede the cutaneous flush, are most puzzling and always suggestive of intracranial complications.

(*b*) The enfeebled state of the patient.

(*c*) Contamination of the mastoid wound and consequent retarded healing.

(*d*) Extension to the meninges (a few well-authenticated cases have been reported).

(*e*) Removal of patient to special erysipelas wards.

The prodromic temperature of erysipelas, which is often accompanied by nausea, may easily be mistaken for lateral sinus infection, and erysipelas occurring as a sequela to mastoidectomy is apparently more common than in ordinary surgical operations. The similarity of infection may explain the phenomenon in part. This disease should not be confounded with iodin or iodoform dermatitis, which it somewhat resembles, the latter being more superficial and without high temperature.

Special Treatment.—The mastoid wound should be packed with moist bichlorid or Burrough's solution dressings, to be changed every two hours. The wound and middle ear may be douched with warm saline solution whenever accumulations of pus or masses of slough are found. A wet dressing of Burrough's mixture applied to the cutaneous lesion relieves the sensation of burning. Ichthyol in 25 per cent. solution serves the same purpose. The borders of the lesion may be seared with silver nitrate in solid stick, but there is no known specific for this disease, which usually runs its course unchecked by any form of medication. Hypodermic injections of the Hiss leucocyte extract (see page 101), are favored by Dwyer and others.

DISEASES OF THE AURICULAR PERICHONDRIUM.

Perichondritis.

Perichondritis of the cartilages of the ear is an inflammation of the perichondrium, with tumefaction of the superficial tissues and subperichondrial serous exudate.

Etiology.—Wounds, contusions and bruises of the aural cartilages and extension from furunculosis or other infectious inflammation. It does not occur idiopathically.

Symptoms.—Following an incision, blow, bruise or contusion of the auricular cartilage, or furunculosis of the external canal, the anterior surface of the concha becomes tumefied, with cutaneous redness, the tumefaction gradually extending until the normal lines of the concavity of the auricle become obliterated. The lobule, being free from cartilage, remains normal. If the swelling extends into the external meatus, the hearing becomes impaired temporarily.

The swelling is chiefly the result of subperichondrial effusion, whereby the perichondrium becomes detached over considerable areas, with proportionate loss of nutrition of the underlying cartilage. The exudate is always serous, and only becomes purulent after receiving infection from without.

Fluctuation marks the appearance of the exudate. Absorption may gradually take place without permanent injury or deformity.

If infection supervenes and the exudate becomes purulent, rupture may ensue, with fistulous formation, or further detachment of the perichondrium may ensue and necrosis of the cartilage result, leaving marked external deformity. The disease resembles othematomata, from which it may be differentiated by aspirating a

few drops of the retained exudate, which, in the latter, is invariably hemorrhagic.

The chronic form sometimes exists for weeks or months, terminating in hypertrophy and deformities of the cartilage, which may involve the external meatus.

Treatment.—The early treatment should consist in the employment of antiphlogistic measures—cold applications, local bloodletting, and the placing of the patient at rest after free purgation. A small Leiter coil may be applied to the affected area for a period not to exceed twenty-four hours. In some cases applications of heat seem to be more effective.

These measures are employed to prevent subperichondrial effusion, and if attended by failure it becomes necessary to remove the exudate in order to circumvent possible necrosis of the cartilage and subsequent deformity of the auricle. At first it is permissible to aspirate the retained secretion. This procedure should be followed by the application of pressure pads, so placed upon the opposite sides of the auricle that a roller bandage will hold the detached perichondrium in firm contact with the periosteum. In severe cases, especially when the secretion has become purulent, it is a wiser procedure to make a free incision through all the tissues down to the cartilage, and rely upon the open method of treatment, under strict asepsis.

By this means the operator is enabled to obtain exact knowledge of the extent of the diseased area, and to effectually meet the requirements of the individual case. The resultant deformities of the auricle are sometimes remediable by plastic surgery.

OTHEMATOMATA.

Othematoma, or hematoma auris, is an effusion of blood between the perichondrium and cartilage of the auricle, and usually occurs as a result of direct violence. It is quite common in the insane, where it seems to develop spontaneously. Even here the possibility of self-inflicted mutilation and accidental injury by attendants in enforcing restraint may account for many cases of so-called "insane ichor." Blows, especially such as are received in boxing and prizefighting combats, are accountable for the majority of cases. In sporting circles the othematous auricle is dubbed "the cauliflower ear" on account of its resemblance to that vegetable (Fig. 66). It is more common in the left ear, which is more accessible to the opponent's right hand. In one of the author's cases, that of a prizefighter, both ears were involved.

Symptoms.—Following an injury the effusion develops rapidly by separating the perichondrium from the anterior cartilaginous surface.

The tumefaction is tense, with less sense of fluctuation than is usual in fluid sacs, and tends to obliterate the normal outlines of the concha. The cutaneous surface is deep red, with a bluish tint. The tumors are smaller when of spontaneous origin. Audition is

unaffected except when the tumor encroaches upon the lumen of the external meatus.

Pain is never severe and consists of a disagreeable sensation of tension, heat and itching. In the idiopathic form there is no pain.

Treatment.—The form of treatment to be followed depends upon the variety and extent of the disease. Small tumors of probable spontaneous origin may disappear by absorption, with no treatment except warm applications. Compresses or massage

Fig. 66.—Othematoma of the auricle.

tend to excite renewed hemorrhage from the already weakened blood-vessels.

Should the tumor increase in size after two or three weeks, it should be treated surgically in exactly the same manner as those of traumatic origin.

In the treatment of large hematomata the indications are to reduce the hemic contents of the tumor and re-establish the circulation of the parts, and to conserve the conformity of the auricle. Whenever it is possible to institute treatment at the very outset, an icebag should be applied over the ear after placing pads of gauze or absorbent cotton before and behind the ear in such a manner that pressure will be minimized. In some instances heat is preferable to cold. Aspiration is convenient during this stage, to

be followed by moderate compression of the parts; but recurrence of the fluid is the rule. If the tumor shows no tendency to subside after a day or two, it should be classed as operative.

When the injury is severe and causes fracture or bruising of the cartilage or laceration of the soft tissues, infection becomes imminent and prompt surgical interference is imperative. In cases of long standing the clot is usually infected; hence, the treatment should be surgical.

Multiple puncture, styptic injections, electrolysis, and setons are at the best merely makeshifts and almost invariably convey infection.

A clean surgical incision possesses the following advantage: (*a*) asepsis; (*b*) complete evacuation of the tumor contents; (*c*) a wide open area which reveals any pus, granulations, necrosed areas of cartilage or soft tissue, and permits their complete removal; (*d*) minimizes the danger of subsequent destruction of cartilage and of deformity of the auricle.

Permanent thickening of the auricle is common. Marked deformity ensues in cases where destruction of the cartilage has been extensive. Here plastic surgery may be employed to cover denuded areas, to correct deformity, and to maintain the patency of the external meatus. The procedure necessarily varies in different cases, and too much must not be promised in the way of cosmetic results.

CHAPTER XI.

DISEASES OF THE EXTERNAL EAR.

(*Continued.*)

OTITIS CIRCUMSCRIPTA FOLLICULARIS
(Furunculosis of the External Meatus).

FURUNCULOSIS of the external auditory canal is an acute circumscribed inflammatory process involving the corium and subcutaneous tissues of the cartilaginous portion of the external canal. It is usually a purulent condition surrounding a central slough or core.

It occurs (*a*) as a primary or idiopathic process; (*b*) secondary to purulent otitis media; (*c*) as a result of such general diseases as diabetes, anemia and syphilis; (*d*) trophic disturbances; (*e*) bacterial invasion.

Etiology.—There are authorities who affirm the cause to be bacteria which enter through the hair follicles or sudoriferous glands; nevertheless the most common cause is direct infection through abrasions of the dermal layer. It is well known that the skin of the external auditory canal lacks certain elements which give it much resisting power in other parts of the body. Under these conditions abrasions, scratches or contusions are extremely liable to follow any form of manipulation, such as rough usage of the cotton-tipped probe in the hands of the careless or unskilled, which act is liable to cause abrasions of the canal with hemorrhage.

This is illustrated in the ease with which the laity may, by using various unsterilized appliances for the purpose either of removing cerumen, or scales, or in attempting to relieve pruritus, inoculate an otherwise healthy surface and cause furunculosis. The affection is more common in women than in men, probably on account of the employment of the ever-ready hairpin to clean the canal and relieve itching. A patient's efforts to remove pus from the auditory canal also often result in lacerations, and the pus becomes the infecting factor.

Inflammatory and suppurative processes in the walls of the external auditory canal, while usually provoked by mechanical means, result also from escharotic or corrosive agents. The milder forms of the disease usually subside without forming pus. The severe types, which are characterized by actual infection, and deep-seated inflammation, gradually develop into abscesses or furuncles.

Symptoms.—The subjective symptoms are variable during the early stages. An indefinite sensation of soreness and fulness is the initial symptom. This is aggravated by any form of manipulation of the auricle. Pain soon becomes severe and continuous, remain-

ing the most troublesome symptom throughout the course of the disease. It is greatly intensified by the slightest pressure, and tends to radiate to the jaw. The pain of furunculosis shows a tendency to nocturnal exacerbations and morning remissions. It is believed by some observers that furunculosis of the canal occasionally assumes an epidemic character. The severity of the attack increases proportionately with the distance of the inflammatory focus from the orifice of the auditory canal. Pain is intensified by mastication, inasmuch as the movements of the jaw affect the inner wall of the external auditory meatus.

Deafness is not common and when present is due to occlusion



Fig. 67.—Furuncle of the external meatus viewed through the speculum. The illustration shows three points of bulging coming into view as the speculum is pushed into the swollen and edematous tissues.

of the canal, either by the infiltration or by the accumulation of pus and epithelial *débris* in the canal lumen.

The Objective Symptoms.—A circumscribed inflammatory area appears at some point along the auditory canal, and the localized swelling diminishes or completely occludes the lumen. Its exact location comes into view as the tip of the speculum gradually impinges upon the walls of the meatus (Fig. 67). Several inflammatory foci are sometimes found. Occasionally the abscess will project from the external auricular orifice, the neighboring region participating in the redness and swelling. The lymph glands underneath the lobule and in front of the tragus are often swollen and painful upon pressure. At times the infiltration and abscess formation become so extensive that the superficial tissues external to the auricular attachment become enormously swollen. The author observed several such cases where the concha stood out at right angles to the head, generally giving the appearance of advanced

mastoiditis (Fig. 124) with external swelling and periostitis. Careful local examination cleared up the diagnosis. Constitutional disturbances are slight. There may be a slight elevation of temperature, with headache and diminished appetite.

Course of the Disease.—The disease is limited to the external auditory canal and the tissues in the immediate vicinity, and usually subsides after a few days of suppuration. When allowed to rupture spontaneously, relapses are common, owing to autoinfection, thus giving the disease the appearance of a chronic affection.

Early incision of the abscess shortens the course of the disease, and hastens the separation of the central slough or core. The surrounding infiltration and swelling subsides promptly with the evacuation and local treatment of the abscess.

Diagnosis.—In simple cases it is not difficult to determine the nature of the affection, a simple inspection through an aural speculum (Fig. 67) sufficing. Whenever the abscess is located at the orifice of the meatus the speculum may be dispensed with. If multiple abscesses are suspected a speculum of small calibre should be gently shoved into the deeper portions of the canal, in order to locate all suspected points. Every manipulation is attended with pain, and especially the impact of the speculum and the touch of the probe. By slowly inserting a medium-sized speculum, under good illumination, the bulging cutaneous wall of the abscess will often come into full view.

Differential Diagnosis.—The disease is differentiated from the following:—

(*a*) Exostosis of the auditory canal, by its density, painlessness, and absence of inflammatory appearance.

(*b*) Atheromata, by their sluggish growth and painless character.

(*c*) Polypi, by their granular surfaces and spongy feel under probe.

(*d*) Mastoiditis; when the tumefaction is extensive and the pus cavity large, with postauricular swelling, the case simulates mastoiditis and is difficult to differentiate.

On three occasions the author has been summoned to perform a mastoid operation, to find only a postauricular distention caused by a furuncle, which was entirely relieved by free incision through the canal wall. In mastoiditis there is no tumefaction in the outer portion of the canal; movement of the auricle causes no pain; there is usually a history of profuse aural discharge, preceded by some form of infectious process in the nose and nasopharynx, and pain upon direct pressure over the mastoid area.

(*e*) Parotid abscess; which may cause the wall of the canal to bulge upward, simulating furuncular infiltration. Here there is marked swelling over the parotid gland, and the amount of pus is entirely out of proportion to that of furunculosis.

Treatment.—During the early inflammatory stage, previous to the formation of abscess, abortive forms of treatment should be adopted. After thoroughly cleansing the canal of all *débris* of

every nature and ascertaining the location of the inflammation, a fairly large tampon or cone of cotton dipped in either a 50 per cent. boroglycerid solution, or, preferably, a solution of carbolic acid, 12 per cent. in glycerin, is introduced and allowed to remain in the canal from twelve to twenty-four hours. Should the tampon produce undue pain the patient is directed to remove it at any time, and to follow its removal by a hot saline or bichlorid of mercury douche. Ordinarily, patients bear the tampon with but little complaint. During this period a hot-water bag, continuously applied to the ear, gives much comfort to the patient. Applications of iodin, nitrate of silver, massage or electricity have been advocated, but are of doubtful efficiency.

Local bloodletting offers some relief to tension and may exert an abortive influence. If attempted the incision should be made directly into the infected tissues and be of sufficient depth to serve at the same time as a channel for the escape of pus whenever it

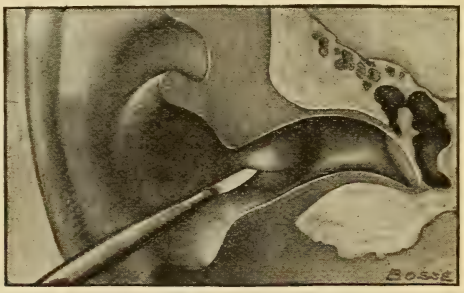

Fig. 68.—Lateral view of the external meatus showing furuncle in posterior wall. The furuncle knife is inserted and about to freely open the abscess.

may form. The internal administration of analgesics is rarely necessary, although occasionally the pain is sufficient to require them. The majority of cases terminate in abscess formation and it is useless to attempt incision until the abscess actually points. Furthermore, in the author's experience, cases in which the abscess is permitted to open spontaneously do as well as those which are incised (Fig. 68). If a carbolized tampon has been employed the meatus will need no further preparation for operation; otherwise, such a tampon should be introduced and allowed to remain in contact with the abscess for twenty minutes. A slight degree of anesthesia is then produced. A sharp furuncle bistoury (Fig. 54) and a quick thrust give the least pain. The patient's head should be firmly held and the field of operation brightly illumined. The point of the knife is then introduced to the inner border of the abscess and plunged to the bone, severing the entire abscess sac as the blade is pulled outward toward the meatus. Curetment of the abscess cavity will hasten the healing process. A small strip of gauze introduced into the abscess cavity serves for drainage and prevents the wound from closing too soon. A warm

saline douche every two hours removes accumulations of pus and keeps the parts clean. At the daily visit the abscess cavity should be irrigated and accumulations removed from the canal. In a space so confined it is difficult to remove the infected area with sufficient thoroughness to avoid the possible danger of auto-infection, whereby recurrences take place.

OTITIS EXTERNA DIFFUSA.

Synonym.—Diffuse inflammation of the external auditory meatus.

Etiology.—The disease is usually caused by traumatism, foreign bodies, lacerations during their removal, or from the entrance into the canal of caustics or irritant fluids, and infections from within the tympanum or from external sources. More rarely it results from eczema, herpes zoster, pemphigus, erysipelas, small-pox, measles, scarlet fever, gonorrhea, syphilis, lupus, and vegetable parasites.

The disease is characterized by diffuse inflammation of the auditory canal. It may involve the superficial cutaneous surfaces only and result in desquamation; or penetrate into the deeper tissues, causing thereby extreme redness, swelling, and terminating in suppuration.

Symptoms.—Patients complain chiefly of pain, tinnitus and deafness. The pain varies with the severity of the attack, and is due to swelling and tension of the parts. It is aggravated by the movements of the jaw. Deafness and tinnitus result from occlusion of the canal, inflammation of the drum membrane, or accumulations of exudate. In the simpler forms the walls of the canal and the membrana tympani become covered with desquamations, which may fill the entire canal. In the phlegmonous variety the canal walls become tender, swollen and narrowed to such an extent that examination of the deeper portions is difficult. When visible, the tympanic membrane appears inflamed and thickened, with indistinct outlines, and, in rare instances, perforations. Ecchymoses sometimes develop in the walls of the canal and after a few days rupture takes place, with a discharge of serum or seropurulent exudate, containing pathogenic organisms. This discharge is exceedingly tenacious, and, as it becomes dry, it tends to exfoliate in masses, leaving inflamed, angry-looking, moist areas, which obliterate the normal landmarks.

Diagnosis.—The diagnosis is rarely difficult. Bright illumination and the judicious use of the probe are usually sufficient, although the exact determination of the condition of the lower segment of the auditory canal and tympanum may be impossible on account of the swelling and tenderness.

The course and duration of the disease depends largely upon its mode of origin. The existence of grave constitutional disease is indicative of a protracted course. Simple acute cases usually terminate in recovery in from three to ten days. Prolonged

phlegmonous inflammations, with recurrence of abscess formations, sometimes finally result in periostitis or even exostosis of the bony walls, with atresia of the canal.

Prognosis.—In simple cases, unattended by grave infection, recovery takes place in a few days. In rare instances the middle ear becomes extensively diseased as a sequela to otitis externa diffusa, and the inflammation has been known to extend from the superior and posterior canal walls directly to the cells of the mastoid process, and finally to the meninges, the latter complication being more common in young children.

Treatment.—While this disease often requires more extensive local treatment and prolonged personal attention, the treatment corresponds in a general way to that given for circumscribed otitis externa. When of bacterial origin, carbolized tampons should be introduced, and, if well borne, allowed to remain from twelve to twenty-four hours. During the stage of secretion a hot saline douche every two hours will effectually remove the products without irritating the inflamed surfaces. After drying the surface, powdered stearate of zinc with boric acid, equal parts, dusted over the diseased area, tends to promote healing.

Whenever a stimulating medicament is needed, a solution of nitrate of silver gr. xx to ℥j, or 25 per cent. solution of argyrol will answer the purpose. When associated with eczema or other cutaneous affections, or constitutional dyscrasias, the scope of medication must embrace these disorders.

OTOMYCOSIS
(Otitic Externa Fungoides).

In the preceding paragraph, devoted to diffuse external otitis, the desquamative type of inflammation is considered. Another type, less common, is due to deposits of various forms of fungi upon the walls of the external canal and usually is termed otomycosis. These types are of vegetable origin (molds), and appear in a great variety of forms, of which the aspergillus niger, fumigatus and flavescens are the chief. The source and mode of entrance are rarely determinable, but there is reliable clinical evidence that the spores will not germinate in a normally healthy external meatus, but require some form of exudate upon which to grow. Certain types, like the mycelium, depend upon moisture; others require a dry exudate for their propagation. The seat of predilection is the inner third of the auditory canal and the membrana tympani. Extensive invasions of either type may take place without producing any subjective symptoms whatever, but their presence usually excites a sensation of irritation and itching, for the relief of which the patient scratches his ear and produces the excoriation of the meatal orifice noted in this condition. Deafness and tinnitus occur only in cases where extensive diffuse infiltration narrows the lumen of the canal. In rare instances the pain is severe and persistent until relieved by removal of the fungi.

The fungi spread over the surface of the inner third of the canal, and often the membrana tympani (myringomycosis), in the form of dirty white, yellowish, or blackhead deposits. The elevated surface of the mass appears dirty, uneven, but velvety in appearance, and is commonly mixed with cerumen, discharge or scales. It often requires a microscopic examination to confirm the diagnosis. The surface involvement may be extensive, or limited to one or more masses upon a circumscribed area. The parasites cling closely to the affected parts, and their removal is sometimes difficult to accomplish, leaving the surface more or less reddened and thickened. A permanent redness points to recurrence. Cutaneous desquamation, the employment of oils in the external canal, occupation, unsanitary environment and moisture, or discharge in the canal, are believed to be the chief predisposing etiological factors in otomycosis. The mere existence of a purulent exudate does not necessarily predispose to the disease. Otomycosis affects men more commonly than women, and children seem to be exempt. Observations bear evidence that the parasites reach their maturity within from five to seven days. If perforation of the drum membrane is present, it is quite possible for the parasites to enter and develop in the tympanic cavity, and cases have been reported in which they invaded the mastoid cells.

Treatment.—The treatment of otomycosis is directed toward the removal of the parasites and prevention of recurrence. A few drops of boric acid gr. xx in alcohol ℥j instilled into the meatus several times daily has proved most useful for their destruction as well as for the prevention of recurrence. Whenever the deposit is extensive, preliminary washing with the syringe or thorough removal by means of a curet may be necessary. If the growths persistently recur, a bichlorid of mercury douche followed by instillations of 95 per cent. alcohol will eventually effect a cure.

OTITIS EXTERNA KERATOSA
(Otitis Externa Parasitica).

This is a rare form of otitis, wherein a white pseudomembrane is observed, which is usually situated along the posterior wall of the bony meatus (Bezold). The fibrinous deposit is easily removed from the bony canal as well as the tympanum, although considerable pain attends its removal.

IMPACTED CERUMEN.

The normal secretion of the ceruminous glands, which are located chiefly in the cartilaginous portion of the external meatus, is light yellow, semifluid in character, and under healthy conditions tends gradually to approach the external orifice, where it becomes removed in the ordinary course of daily washing.

The proximity of the intermaxillary articulation, the capsular ligament of which stands in close relation to the tragus, is supposed to be an important factor in moving the cerumen toward the outer

orifice of the meatus, inasmuch as with each motion of the joint, whether in talking or mastication, there is an impingement upon the canal.

Etiology.—Several etiological factors, acting either singly or in combination, enter into the causation of retained ceruminous plugs.

1. *Anomalies and Obstructive Lesions of the Canal.*—Retention of cerumen sometimes occurs in canals which are of extremely small calibre at certain points throughout; in those that are congenitally tortuous, or when the walls are the seat of exostoses or hyperostoses.

2. *Foreign Bodies.*—Foreign substances which are allowed to remain in the canal serve as a nucleus to which cerumen adheres. Of these cotton pledgets carelessly left in the canal, either from attempts to remove *débris* or while worn for protection, are the most common. Beads, seeds and particles of dirt, coarse dust and splinters occasionally serve the same purpose.

3. *Diseases of the Middle Ear and External Meatus.*—Eczema and other cutaneous diseases, circumscribed and diffuse external otitis, and purulent otitis media, both by extensive exfoliations and by modifying the character of the ceruminous exudate, are prolific causative agents. The frequency of its association with chronic catarrhal otitis media suggests a possible concurrent alteration in the ceruminous glands whereby the quantity of secretion is diminished from lack of fluid elements. Cholesteatomata which have exfoliated from the middle ear sometimes form a portion of the mass. Hypersecretion of cerumen, while rare, sometimes occurs, and variations in the amount secreted are wide, even within normal limits.

4. *Mechanical Causes.*—Aside from foreign bodies, the agglutination and retention of cerumen is facilitated by wrong methods of cleansing the ears. Irritant solutions, portions of which are allowed to remain in the canal, thereby causing superficial inflammation and exfoliations, overstimulate the ceruminous glands or cause superficial dermatitis and exfoliation. In the ordinary cleaning of the canal, by wiping with cotton-tipped probe or twisted corner of a handkerchief or washcloth or earspoon, masses of cerumen are easily pushed deeper in, where they remain and increase in size.

Pathology.—Cerumen masses are usually of complex formation, having, in addition to the ceruminous exudate, variable admixtures of sebaceous matter, flakes of epidermis, and fragments of hair, spores and central foreign bodies. The color of the plugs varies from light yellow to reddish black, very old plugs often having a glistening appearance from the presence of cholesterin crystals. Prolonged contact of large masses of impacted cerumen probably excites more or less extensive desquamative inflammation of the walls, osteitis and perforation of the membrana tympani.

Symptomatology.—So long as the ceruminous plugs do not attain sufficient size to completely obstruct the calibre of the canal,

all subjective symptoms are absent. An extremely small channel seems to be sufficient to admit sound waves and maintain the hearing function practically unimpaired. A change of position of the mass, due to violent jarring of the body, or to the movements of mastication, whereby the canal becomes totally occluded, will produce deafness. The same result often ensues after bathing, and is explainable as follows: The bather, who has a cerumen plug which nearly fills the calibre of the canal, gets water into the ear, and sufficient moisture is absorbed to cause the mass to swell and close the entire lumen of the canal. Complete occlusion is immediately followed by a sensation of fulness in the ear, deafness, tinnitus, and often vertigo. Autophony is a common symptom. Upon inspection during the earlier stages, the accumulated cerumen may be seen covering certain portions of the meatal walls, either as sticky masses, or in the form of flakes, crusts, or wads. As these increase in size by accretions, they tend to extend in either direction until the entire canal is occluded with possible pressure upon the drum membrane. The tinnitus is variable in its intensity, but is at times so loud and troublesome as to become the sole cause for seeking relief. When perforations exist, all symptoms are aggravated, and trigeminal neuralgia, facial paralysis, and blepharospasm have occurred. Pain rarely ensues, although at times, owing to pressure, neuralgic pains may be felt, not necessarily localized, but radiating in various directions.

Among the reflex symptoms cough is most prominent. It may become so severe as to induce congestion in the upper respiratory tract.

Complete blocking of the canal necessarily perverts the function of audition, and in nervous subjects considerable mental disturbance may accompany the condition. Vertigo, nausea, and epileptiform seizures have been known to result from impaction of cerumen in the auditory canal. Impaction in canals which have long been the seat of a purulent process may lead to serious consequences on account of the obstruction to the outflow of discharge.

Diagnosis.—Careful inspection of the auditory canal is the only method by which a positive diagnosis may be made. It must be differentiated from cholesteatomata, blood-clots, foreign bodies, inspissated pus, and a variety of admixtures of ephithelium, mucus, spores and foreign bodies.

Prognosis.—The outcome is less easily determined, as hypersecretion of cerumen is frequently associated with other forms of disease. The mere cerumen mass in an otherwise healthy ear is never a grave condition. It is unwise to predict that a return of hearing will follow the removal of the cerumen mass, inasmuch as deafness from other causes may have pre-existed. Whenever the loss of hearing is sudden and entirely due to occlusion, the prognosis as to hearing is invariably good. Recurrence is the rule, and patients should be so informed, and advised to return at intervals of about six months in order to prevent a repetition of the impaction. It is wise to record the aërial conduction sound before remov-

ing cerumen, in order to circumvent any contention as to loss of hearing which the patient may subsequently make. In one instance, in the author's experience, a clinic patient threatened legal proceedings, claiming that the removal of masses of cerumen had resulted in great diminution of hearing. The record of the hearing distance previously made easily proved the patient's error.

Localized masses smearing the posterosuperior wall of the canal are usually indicative of a purulent process within the tym-

Fig. 69.—Syringing the ear for the removal of cerumen. The patient's clothing is protected by the bib (Fig. 9), augmented by a towel tucked between his neck and collar. The patient holds the pus basin for the return flow, which leaves the surgeon free to manipulate the syringe and hold the ear in proper position.

panic cavity, and their removal may be followed by renewal of the discharge.

Treatment.—Obviously the treatment should be directed to the removal of the mass. When the masses are small and not densely impacted, a few syringefuls of warm water will be sufficient to effect their removal. Hard plugs, densely impacted, are difficult to remove at the first sitting, and, inasmuch as a short delay is not a detriment to the patient, it is wise to desist for a day, in the meantime directing the patient to instill at short intervals either warm

saline solution, common salt ʒj to sterile water Oj or a solution of sodium bicarbonate ʒj to ℥iv of sterile water. Instillations of peroxid of hydrogen are more effective, and the author has never observed any harmful results from its use. The stream from the syringe (Fig. 69) should be directed to the borders of the cerumen mass as the most likely place for the solution to get behind and force it outward. Considerable force may be expended upon the current without damage to the parts. It is sometimes impossible by means of the syringe to throw the solution behind the hardened mass, and it becomes necessary to supplement its action by means of a small curet or probe, and make a groove between the cerumen and the canal wall through which the water may be forced, always pointing the syringe toward the groove. In rare instances cerumen resists all efforts at removal with water; hence, it becomes necessary to extract it piece by piece, with forceps and curet. Following the removal of cerumen the auditory canal should be carefully dried and inspected, meanwhile noting any injury to the canal walls or drumhead. The surfaces may then be thoroughly smeared with liquid vaselin containing menthol in the proportion of 10 grains to the ounce, and a small tampon of cotton inserted for a day. The patient should be directed to return in a day or two, at which time the canal should be thoroughly touched with alcohol in order to destroy any vegetable fungi, and such further applications as the condition of the parts may require. Unless absolutely necessary the introduction of forceps, spoons and curets should be avoided in the removal of cerumen masses. Finally, before dismissing the patient, the hearing distance should again be tested for purposes of comparison.

FOREIGN BODIES IN THE EAR.

On account of the exposed location of the ear and its open meatus, a variety of foreign bodies find lodgment in the auditory canal, and, occasionally, penetrate the deeper structures.

Etiology. (*a*) *In Children.*—There seems to be a natural tendency among young children to introduce small objects, either into the mouth, nose or ear. These accidents are usually self-inflicted, but occasionally they practise upon each other. The more common substances thus found in the meatus are pebbles, beads, bits of wood, glass objects, buttons, gravel, pasty substances, peas, beans, and other seeds.

They are likewise subject to the accidental impaction of gun wads, explosive materials, bullets, etc., and to the entry of animate objects, bedbugs, roaches, houseflies, ticks, maggots, etc.

(*b*) *In Adults.*—In adults the causes are: 1. The habit (usually pernicious) of wearing cotton in the ears, pledgets of which are carelessly forgotten, or pushed deeper into the canal by additional ones. 2. Efforts to remove cerumen, scales or pus, by means of hairpins, toothpicks, matches, and twigs, whereby portions are lost in the canal. 3. Animate objects, bedbugs, roaches, moths, flies, ticks, worms and maggots. 4. Explosives, gun wads, bullets,

portions of rockets, cloth and fibre. 5. Foreign bodies incident to occupations, seeds, chips, scales of iron or steel, coal, etc. 6. Otoliths.

Symptoms.—Unless producing distressing symptoms, a foreign body may remain undisturbed for an indeterminate period, during which it becomes encased in an admixture of cerumen and epithelial scales. Here the symptoms are similar to those already described under impacted cerumen. Those which enter under force and lacerate the tissues invariably cause sufficient hemorrhage, pain and discomfort to cause the patient to seek relief.

Explosives and knife or stiletto tips are prone to wound the deeper tissues, with very serious results.

Young children either inform their attendants, or the accident becomes known through inflammatory reaction or hemorrhage. Insects, when alive, produce agonizing, nerve-racking sensations by their crawling or clawing efforts to move about the canal.

The larger seeds like beans and peas become troublesome as a result of absorption of moisture, which causes them to swell and occlude the canal. Pain is always more severe when these objects lie against or lacerate the drum membrane.

The results are more harmful in ears which are the seat of purulent discharge, since by retarding the flow of pus, or by contamination with animate objects serious complications may arise.

Ballenger[1] calls attention to the ravages of the Texas screw-worm fly, which possesses a sawing movement which enables it to penetrate bone, and recalls Mackenzie's reports of cases where they penetrated the cranial cavity, causing death by meningitis.

Diagnosis.—The diagnosis is simple and easy in recent cases where no laceration, swelling, or hemorrhage has taken place, inasmuch as under strong reflected light the body may be both seen and touched with a probe.

This is the only reliable and proper method to follow. Unfortunately, these patients are seldom seen by the otologist at this stage, consulting him only after the walls of the canal have been lacerated, or inflamed as a result of unskilled efforts to extract the offending mass. Having already suffered considerable pain and discomfort, the patient, if a child or a hypersensitive adult, approaches in extreme trepidation; hence, the examination should be deferred for a few minutes, and his confidence inspired by reassuring statements. Rather than examine an unruly patient under force, with probable damage to the soft tissues, it is wiser to administer a general anesthetic, which permits both thorough examination and a painless and safe removal.

Treatment of Foreign Bodies in the Ear. *Insects.*—First determine positively by visual examination whether the insect still remains in the canal. Nervous patients are prone to complain of the crawling sensation long after the insect has escaped, and are sometimes on the "border line" of insanity. The author has the

---

[1] Diseases of the Nose, Throat and Ear, p. 601.

record of a woman who stoutly and persistently maintained that she had a bedbug in her ear, and would not be convinced to the contrary until, in desperation, a bedbug was procured and inserted into the canal without her knowledge. It was then withdrawn and exhibited to her with convincing effect.

If alive, the insect should be drowned or otherwise killed before attempting its removal, on account of its power to cling to the surface. Immersion in oil usually suffices, but in case it fails a few drops of chloroform diluted one-half will complete their destruction,

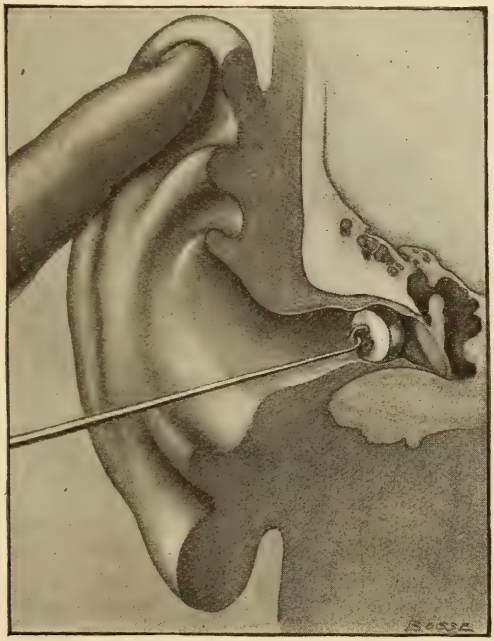

Fig. 70.—A method to be employed for removing buttons from the external meatus whenever the eye or eyelet can be seen by the surgeon.

after which they are easily removed, either with the syringe or forceps—preferably the former.

Inanimate Bodies in the External Canal.—The body should be removed by the safest possible method which may be suited to the individual case. Of these the syringe, employed in exactly the same manner as for impacted cerumen (Fig. 69), is the safest and most effective. Zaufel successfully removed the object with the syringe in 92 out of 109 cases, about 90 per cent.

The invariable rule should be to attempt removal with the syringe before resorting to any other method. In a large percentage of cases the syringe alone will successfully clear the canal of the obstruction. As already stated a careful preliminary examination through a speculum, with a bright illumination, should be made,

at which time all the lacerations and bruises, and hemorrhages, whether incident to the inward passage of the body or as a result of clumsy unskilled attempts to remove the object, may be seen.

If the tissues about the meatus are greatly swollen and painful and there are no indications of deep-seated injury, it is wiser to delay removal for a day or two until these symptoms subside. Rest, hourly warm douches, and depletion by wet cupping are helpful adjuvants. It now becomes possible to determine the form and nature of the object, its exact location, and whether it is firmly

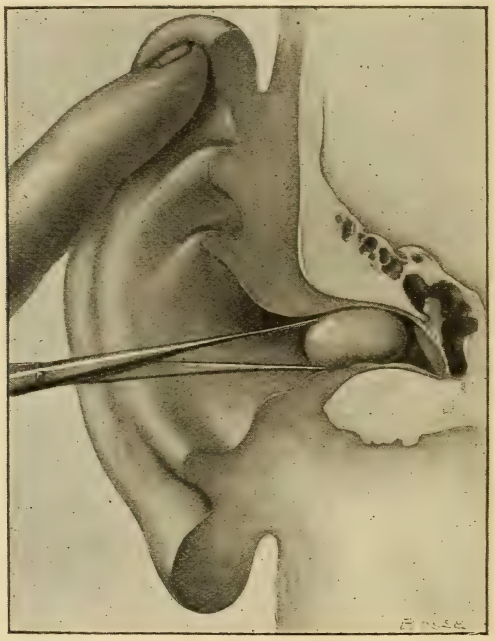

Fig. 71.—Removal of oval object (bean) from the auditory meatus with forceps. This method should be employed only in the hands of skilled operators, on account of the danger of pushing the foreign body deeper into the canal, wounding the membrana tympani, etc.

impacted in the lumen of the canal. If reasonable persistence in syringing fails to remove the object, the plan of procedure should be as follows: The object may be located in a manner which permits the operator to grasp it firmly with the forceps or hook into some eyelet or angle without danger of forcing it deeper into the canal. In this class are found wads of cotton, paper or cloth, the eyelets or thread holes of buttons (Fig. 70), the edges of metals, sticks, buttons and similar substances. After securing a firm hold, traction should be made directly toward the meatal orifice until the object is extracted. During this time the head should be steadied by an assistant. The removal of objects with smooth oval surfaces,

like beans, peas, beads, etc., is obviously a more difficult procedure. Here the employment of forceps is contraindicated unless in skilled hands (Fig. 71), inasmuch as in applying the jaws there is danger of forcing the object into the deeper portions of the canal, always an unfortunate occurrence on account of the added difficulties in removal incident to a location beyond the narrowed juncture of the osseous and cartilaginous portions of the canal. The agglutination method has been recommended in this type, and consists in gluing the end of a small piece of tape, or a small camel's hair brush to the surface of the object, and, after it becomes firmly fixed, to make sufficient traction to pull out the foreign body.

Another procedure is to gently slide a small hook between the canal wall and the object, and by a slight corkscrew motion imbed the tenaculum into the mass and thus withdraw it. Quires's foreign body extractor (Fig. 72) is also available here. It sometimes happens that the first insertion of the hook merely pries up one side of the object, in which event it should be reinserted upon the opposite side and the object thus removed.



Fig. 72.—Quires's foreign body extractor.

In removing denser objects, glass, metals, etc., it may be necessary to insert a small curet or spoon, even at the expense of slight laceration, in order to obtain sufficient hold to remove them. In young children and many adults it is quite impossible to remove the more deeply imbedded foreign objects except under general anesthesia; hence, it is advised, and its employment greatly simplifies the operation, but should in no wise lessen the importance of observing all precautions against injuries to the drum membrane and canal wall.

There are rare instances wherein large, dense objects become deeply imbedded in the bony or cartilaginous walls, when it is impossible to extract the object except by posterior incision and detachment of the canal from the bone in the manner followed in the removal of exostoses of the canal, or the radical operation.

Foreign Bodies in the Middle Ear, Eustachian Tube and Other Parts of the Temporal Bone.—These are usually bullets or other projectiles, or the broken tips of swords, knives or stilettos. Unless a projecting portion can be grasped with strong forceps and the entire object removed by traction a surgical operation should be performed without delay, and under all the precautions required by modern surgery. The preliminary steps are precisely those followed in removing an exostosis from the bony canal by the postauricular route. By this means it becomes comparatively easy to chisel or pry out the mass. It may, however, become necessary to chisel

away a portion of the bone from the canal wall at the transition of the auditory canal into the tympanic cavity, or even to open the antrum or labyrinth in case the foreign body has been lodged in these regions. The requirements subsequent to such operative procedure would be closure of the wound and the maintenance of the membranous canal in position by suitable packing.

Small bodies in the tympanic orifice of the Eustachian tube may sometimes be withdrawn by forceps through an open drum membrane, and, if protruding from the faucial opening, removed with properly curved forceps, aided by a rhinoscopic mirror. Operators have succeeded in dislodging Eustachian obstructions by Politzerization, first removing a window from the drum membrane.

Syphilis, diphtheritic and croupous inflammation, and lupus of the external ear form a part of Part II, Chapters XXIX, XXX, XXXI and XXXII.

ATRESIA (STRICTURE) OF THE EXTERNAL AUDITORY CANAL.

Etiology.—Constrictions of the auditory canal are either osseous, fibrous or in the form of new growths, and are due to inflammatory disease of the walls, purulent otitis media, traumatism and congenital deformity. The osseous form (exostosis) is described in Chapter XIII, Fig. 97. Those due to neoplasms of the auricle are also outlined in Chapter XIII.

Inflammatory affections (eczema, dermatitis, furuncle, perichondritis, otitis externa diffusa) in severe form may result in fibrous thickening of the deeper layers of the canal and constriction of its lumen. Circumscribed thickening of the skin, with cicatricial bands, or circular constrictions are produced both by prolonged otorrhea and traumatism. Similar results follow the ulceration of lupus, tuberculosis, and syphilis. Marked atresia is prone to follow a radical mastoid operation in which the operator has failed to divide the membranous canal by making the usual flap.

Treatment.—Various simple procedures have been devised to overcome contraction and adhesion of the soft tissues, the chief of which are vulcanized and soft-rubber tubes, tampons, sponge tents, caustics, etc. Unfortunately, they usually fail to produce permanent benefit. In the majority of cases a single cicatricial band which has resulted from traumatism will disappear under the pressure of a hard-rubber tube. The only positive and permanent relief is derived from detaching the concha by posterior incision and entering the auditory canal by way of the posterior wall in the same manner as in the radical operation. When the stricture is confined to the cartilaginous meatus it may require a division of the membranous canal and the formation of a skinflap similar to those which form a part of the radical mastoid operation. Whenever atresia occurs in conjunction with and as a result of prolonged intratympanic suppuration, it is advisable to perform the radical operation, and by so doing effect a cure both of the purulent disease of the ear and constriction of the canal. In those cases where the

walls of the cartilaginous meatus are simply collapsed, with no cicatrices, or tumors, the introduction of tubes for the purpose of improving the hearing is without avail except so long as they remain *in situ*.

Electrolysis has its advocates, and has been employed with success, in simple cases unaccompanied by suppuration, by inserting the needle of the negative pole into various portions of the fibrous tissue, and the positive sponge electrode elsewhere upon the body. Treatment should be given every other day unless too much reaction results, each *séance* lasting ten to twenty minutes, with a current strength of 8 to 30 milliampères.

CARIES OF THE OSSEOUS EXTERNAL AUDITORY CANAL.

Carious areas in the bony portion of the external canal wall are usually of serious import, and occur with sufficient frequency to merit a brief outline of its etiology and treatment.



Fig. 73.—Carious mastoid process. Removed from a child 14 years old. (Author's case.)

Etiology.—(*a*) Purulent otitis media, in which the inner portion of the osseous canal and outer attic walls become necrosed.

(*b*) Purulent mastoiditis. The majority of all cases of caries in this location result from purulent mastoiditis, with every evidence of a primary attack of unusual severity, and rapid extension of infection from the mastoid cells through the canal wall. Large sequestra of necrosed bone sometimes come away through fistulous openings in the canal wall, or remain exposed for indefinite periods. Fig. 73 is a photograph about the natural size of a necrosed mastoid process, including a portion of the posterior canal wall in a young child who had suffered with an offensive discharge from the ear for about three years. The author removed it by making the usual mastoid incision, followed by a radical mastoid operation, which proved entirely successful.

(*c*) Malignant neoplasms and infections. Primary carcinoma of the ear usually springs from the floor of the external canal, and erosion of the bone is one of the early symptoms. Tuberculous and specific ulceration may also result in necrosis of the canal wall.

(*d*) The author has seen a single case of caries which could not be traced to the above causes. It was a small circumscribed spot about the size of a millet seed, upon the floor of the canal. The exposed area was dry and there was no history of purulent otitis media, injury or cutaneous disease, nor evidence of syphilis, tuberculosis or malignancy. It was scraped away with a curet and has never returned.

Treatment.—A fistulous opening along the posterior canal wall, which communicates with the mastoid process, is invariably indicative of extensive necrosis of the mastoid cells, which in many instances extends through the inner table, exposing the meninges or lateral sinus to infection. From every standpoint a mastoid operation is the only treatment worthy of consideration, and usually the radical operation is essential in order to reach the limitations of the necrotic process.

Small sequestra in other partions of the wall, which do not communicate with the deeper bony structures, may be removed through the external meatus by means of the curet and forceps, after dislodging granulations and polypi.

Whenever the necrosis results from malignant or infectious diseases, the treatment should be governed by the requirements in the individual case, descriptions of which will be found under their appropriate headings.

HEMORRHAGE OF THE EXTERNAL AUDITORY CANAL.

Hemorrhage of the walls of the auditory canal occurs in three varieties:—

(*a*) **Spontaneous.**—This is a rare phenomenon in which the outflow is of a serosanguineous nature, without abrasion of the skin or periodicity.

(*b*) **Vicarious.**—Periodical hemorrhage from the external meatus sometimes occurs in young females as a perversion of the menstrual function.

(*c*) **Traumatic.**—Hemorrhage from traumatism may arise from deep-seated injuries to the temporal bone, either from direct or indirect violence. Severe injuries sometimes result in fatal hemorrhage.

In rendering a diagnosis the possibility of malingering must be eliminated.

CHAPTER XII.

DISEASES OF THE EXTERNAL EAR.

(*Continued.*)

MALFORMATIONS AND ANOMALIES OF THE EXTERNAL EAR.

MALFORMATIONS and defects of the auricle occur in various forms from slight deviations in size and shape of the individual parts to almost complete absence of the entire organ. Reduplication of one or more of its parts and supernumerary auricle (polyotia) also demand consideration. Any marked deviation from the normal is very noticeable on account of the prominent situation of the auricle in the general contour of the face and the head. The auricle, in man, has little to do with the hearing function; therefore, its defects do not produce impairment of audition unless the deformity occludes the entrance of the external meatus and prevents the free access of sound waves into the auditory canal. But deafness is common in malformed ears, and it is usually due to a coexisting maldevelopment, or entire absence of the external auditory canal, the middle ear, or the labyrinth.

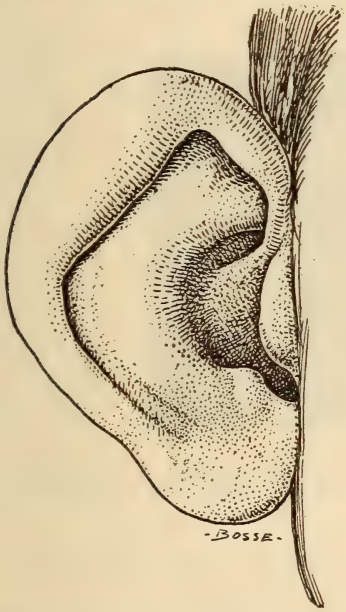

Fig. 74.—Projecting ear, with abnormal droop or lop. There is also redundant cartilage and deformity of the helix.

The treatment is largely designed for cosmetic purposes and is surgical.

Malformations and defects in the external ear are not necessarily indicative of perverted mentality, notwithstanding the large proportion of such abnormalities among individuals who are mentally impaired. They are usually unilateral, and occasionally accompanied by maldevelopment in the bones of the corresponding side of the face.

Some are due to the absence of cartilage, while in others there is entire absence of the auricular appendage, barring certain nodules or tags found in its usual location. The cartilage may be unduly thin or thick, or of irregular shape, or the normal folds, depressions and creases may be obliterated or abnormal, with corresponding alteration in the contour of the helix and antihelix. The angle of

attachment of the auricle, especially when its upper portion is unduly large, is responsible for many ill-formed appearing ears. The so-called "lop ear" (Fig. 74), whether congenital or acquired, is of this type, and occasionally the entire upper portion of the pinna droops downward and forward in a flabby, ill-shaped mass.

Occasionally the defect takes the form of abnormal enlargement or diminution of the concha, lobule, or entire auricle. One of the author's patients has a diminutive auricle of infantile proportions which has never grown since birth, and he is now 42 years of age. The helix is overhanging but otherwise the auricle is well formed (Fig. 75). There is no external auditory canal, but the Eustachian tube is normal, patulous, and is susceptible to inflation. Audition, however, is absent.

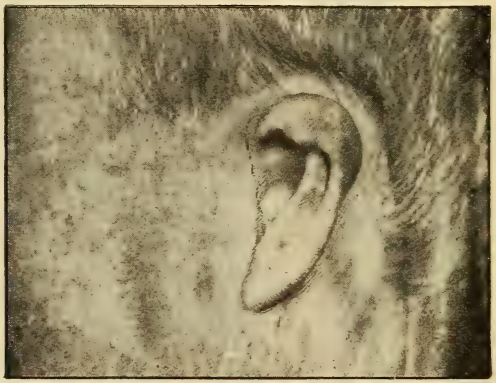

Fig. 75.—Diminutive auricle, with absence of external meatus. The patient has a normal and patulous Eustachian tube capable of inflation, but no hearing.

MALFORMATIONS AND ANOMALIES OF THE AURICLE.

(*a*) **The Auricle.**—The auricle as a whole may be overdeveloped (macrotia), there may be a marked difference in the size and contour of a person's auricles (asymmetry), or the point of attachment to the head may be abnormal (heterotopy).

Goldstein[1] measured a large number of auricles and found (Fig. 76) that the long axis measuring from the tip of the lobule to the highest point of the helix, *a, b,* should not exceed 7½ cm. (3 inches), and the width measured from the inner curve of the tragus, transversely to the outer edge of the helix, *c, d,* should not exceed 3 cm. (1¼ inches).

The angle of insertion of the auricle, described by Frigario as the auriculotemporal angle, in normal ears is acute; hence, an auricle which projects at a right or obtuse angle from the head (Fig. 74) occupies an anomalous position.

[1] The Laryngoscope, October, 1908, p. 826.

MICROTIA.—The term microtia is usually employed to define a class of congenital defects in which the auricle has no definite form, with absence of certain portions, perversion of the normal outlines, or almost entire absence of the appendage.

Strictly speaking, any under-sized ear, whether perfect or imperfect in outline, is classed as microtic (Fig. 75). Almost invariably microtia is associated with maldevelopment of other portions of the auditory apparatus, chiefly, absence of the external

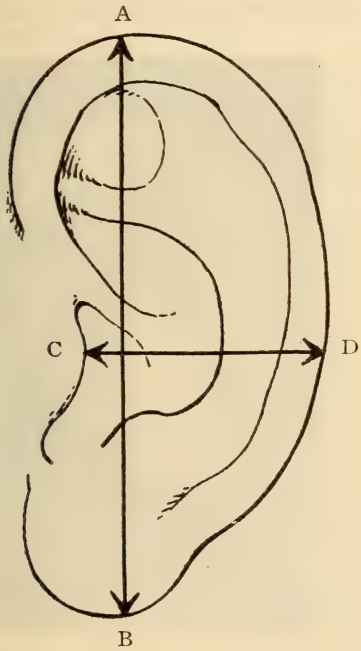

Fig. 76.—Diagrammatic representation of the normal measurements of the auricle. A to B = 7½ cm.; C to D = 3 cm. (After *Goldstein.*)

Fig. 77.—The satyr ear.

auditory canal. The Eustachian tube is usually intact and patulous, but the labyrinth may be defective.

The defect may be bilateral or unilateral, and coexisting defect of the contour of the face and perverted mentality are not uncommon.

(*b*) **The Helix and Antihelix.**—Minor variations in the scroll-like formation of the helix are common, and consist of abrupt angles or other irregularity of outlines, as is observed in the satyr ear (Fig. 77) or in a lack of development or overdevelopment of the part.

The upper portion is the usual seat of faulty development, and here the helix is oftener absent than overdeveloped. Cases of

enormous overdevelopment of the helix have been reported (Fig. 78). The anthelix shares with the helix in some of its deformities, and is susceptible to individual variations, chiefly that of undue projection and division into two or three crura. It is sometimes absent altogether.

(*c*) **The Lobule.**—The lobule is subject to a variety of malformations in size and in shape. Of these the enlarged bulbous lobule, common to the negro races, the thin elongated, and the flat fan-shaped are the chief types. The lobule is sometimes absent altogether, and it is occasionally bifid; the latter condition usually

Fig. 78.—Redundancy and deformity of the helix. (*Goldstein.* With permission.)

is a result of wearing heavy earrings, or results from the sudden tearing of earrings through the soft tissues (Fig. 79). In one case observed by the author (Fig. 80) a large horny excrescence projected from the tip of the lobule.

(*d*) **The Tragus.**—Deformities of the tragus are rare. It is sometimes much enlarged with a backward flare that partially or wholly closes the external meatus. Anomolous cartilaginous projections are occasionally observed. A supernumerary tragus, usually rudimentary, is sometimes observed on the surface near the ear (Fig. 81).

(*e*) **Fistula Congenita Auris** (Fig. 82).—The author has observed two cases of this anomaly, in both of which there was a small fistulous opening in front of the tragus. They are blind canals, from 3 to 6 mm. in depth, having no connection with the

middle ear, and secrete a thick serous exudate. Similar cases were first described by Heysinger, and are believed to be due to the incomplete closure of the first or second branchial cleft.

(*f*) **Supernumerary Auricles (Polyotia).**—Multiple auricles are extremely rare, and are usually without definite form, although a few which were well formed have been reported. The presence of cartilage in a supernumerary growth about the face or along the sternocleidomastoid muscle may rightly be considered a supernumerary auricle.

They are essentially cutaneous growths and may be either unilateral or bilateral.

Treatment.—Microtic auricles constitute a class of deformities that, unfortunately, cannot usually be corrected. In some instances slight improvement in shape may be effected by appropriate plastic surgery.

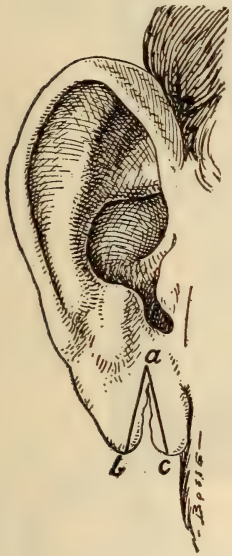

Fig. 79.—Bifid lobule. Showing line for incision *a-b* and *a-c* to be followed in performing a plastic operation to overcome the deformity.

An artificial pinna is less conspicuous and, therefore, preferable to the more exaggerated and unsightly appendages made of nodules of cartilage and skin tabs.

It is useless to attempt any operation to form an artificial external auditory canal, but, if a rudimentary canal is present and the hearing tests are positive regarding the conducting and perceptive function of the middle ear and labyrinth, it may be feasible to enlarge the meatus. The Stacke operation, modified if necessary to suit the individual case, and completed by a Koerner or a Panse flap, permits a wide opening in the outer portion of the meatus. Prolonged after-treatment by packing with gauze is necessary to insure success.

Macrotia.—To reduce an abnormally large auricle for cosmetic purposes, it is necessary to resect some portion of the redundant cartilage. Several procedures have been recommended and employed in which a triangular section is resected, the base of which forms an arc from some portion of the free border of the helix. (Figs. 83, 84 and 85 illustrate the steps of an operation commonly performed).

The primary incision should transfix the entire auricle from *a* to *b* (Fig. 83), the line of incision to be varied according to the degree of correction required. The upper segment is then slid downward, overlapping the lower, to a varying point, *c, d* (Fig. 84), which line represents the section to be resected. It is sometimes preferable to resect from the lower segment.

An additional section, *n, z, d* (Fig. 85), is then removed, in

order to permit perfect coaptation of the parts and without deformity of the free border. Goldstein[2] has ingeniously devised a plan of operation wherein he raises a large curvilinear flap of cartilage and slides it forward upon the remaining cartilage, from all of which the pericondrium has been separated. The opposing flaps are then held one upon the other by strong catgut sutures, and the cutaneous opening closed.

Projecting or "Lop-ear."—Two general types of auricles participate in this deformity. (*a*) Those without redundant cartilage. (*b*) Those with redundant cartilage.

Fig. 80.—Large horny excrescence projecting from lobule. (Author's case.)

(*a*) The deformity may be overcome without resecting any cartilage. A simple technique is that of denuding a sufficient surface both upon the dorsum of the auricle and the corresponding side of the head (Fig. 86), and suturing the borders to each other. Duel[3] has devised an ingenious but rather complicated operation whereby the auricle is drawn backward and upward by a strong skin flap, which is passed underneath a cutaneous loop raised from the scalp near the posterior auricular angle and anchored upon the denuded surface.

(*b*) An operation devised by Goldstein contemplates both reduction of redundant cartilage and correction of malposition of the auricle, the section of cartilage to be reduced subcutaneously

[2] Transactions of the American Laryngological, Rhinological and Otological Society, 1908.

[3] Transactions of the American Laryngological, Rhinological and Otological Society, 1908, p. 104.

through incisions made primarily for the purpose of correcting the malposition.

A curvilinear incision is made upon the posterior surface of the pinna, commencing at about its upper point of attachment (Fig.

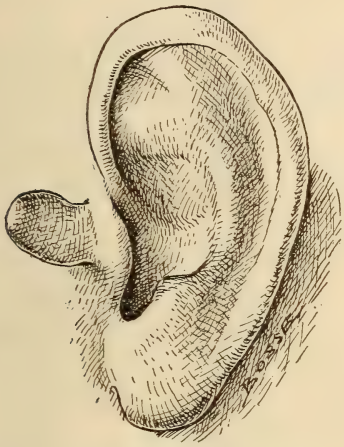

Fig. 81.—Supernumerary tragus.

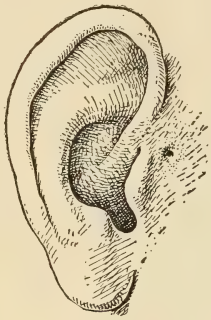

Fig. 82.—Fistula congenita auris.

87), *a, b*. The flap is then reflected backward over the upper mastoid region. A second incision is then carried through the cartilage (Fig. 88, *e, f*). The perichondrium is then separated from

Fig. 83.

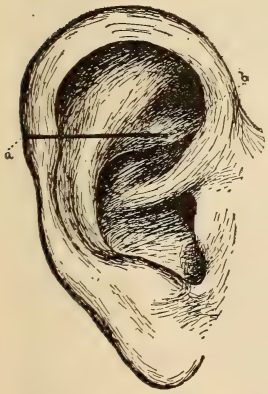

Fig. 84.

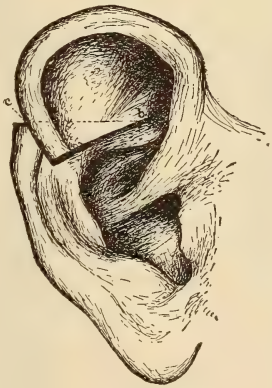

Fig. 85.

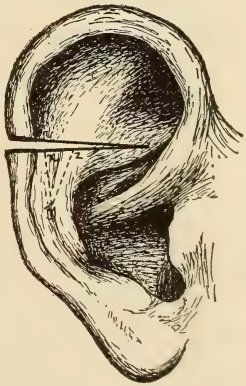

Figs. 83, 84, 85.—Usual technique for reducing macrotia. (From *Goldstein*, Laryngoscope, October, 1908. With permission.)

the anterior surface of the auricle and the cartilage flap *c, d* (Fig. 89) is made to overlap the contiguous cartilage, where it is retained by mattress sutures (Fig. 90).

After removing the redundancy of the original skin flap *a, b,* it is replaced and united (Fig. 90). The wrinkling of the skin upon the anterior surface of the auricle disappears in a short time. This operation is applicable for the correction of other forms of enlargement of the auricle by adopting the necessary modifications in each individual case.

The line of incision is then dusted with aristol, covered with flexible collodion and gauze. Loose gauze is now carefully placed upon the pinna in such a manner that the bandage will hold it in a normal position.

The cosmetic results, in cases where good judgment has prevailed in all the steps of the operation, are most gratifying.

The Lobule.—The lobule is vascular and contains no cartilage; therefore, plastic operations to correct those which are unduly wide or elongated are feasible.

Resect a wedge-shaped section of sufficient size to leave a normal-sized lobule after the denuded surfaces have been approximated. A bifid lobule is repaired by denuding the integument (Fig. 79) *a, b* and *a, c,* and coapting the wound margins with fine-silk or horsehair sutures.

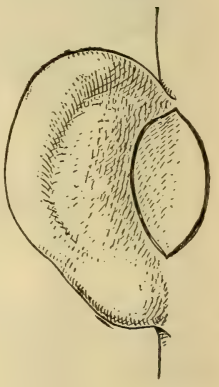

Fig. 86.—Usual incisions for correcting deformities of "lop ear."

Supernumerary Tragus, Cartilaginous Projections and Fistula Congenita Auris.—Resect the supernumerary tragus together with any cartilage by means of an elliptical skin incision, and close the wound by suture.

A cartilaginous projection is unsightly, and should be removed by resection of the entire projection. A small area of skin from the anterior surface may be retained for the purpose of covering the denuded base of the growth.

A fistula congenita auris is easily removed by excising the entire blind canal and coapting the raw edges with sutures.

Polyotia.—The removal of supernumerary auricles and rudimentary tabs is accomplished by plastic operations, in which all cartilage should be resected. A flap of integument is first dissected from the surface of the appendage, sufficiently large to cover the denuded space from which the growth is excised. This flap is then carefully stitched to the borders of the wound. By so doing the resulting scar is almost nil.

Operations involving the auricular cartilage should always be attended with due regard for asepsis. The blood supply is meagre, and, when once infected at any point, the whole cartilage is prone to succumb, with disastrous results, in which the auricle shrivels into an unsightly mass.

Fig. 87

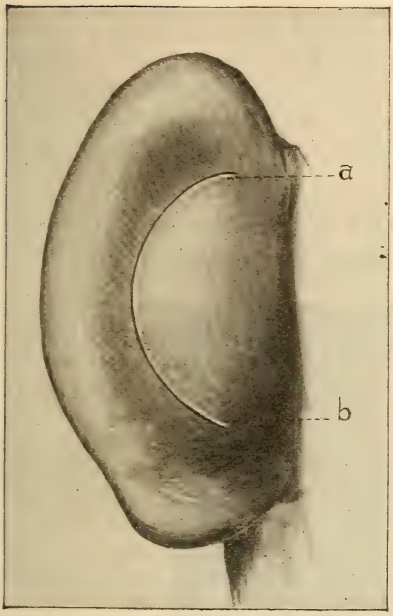

Fig. 88

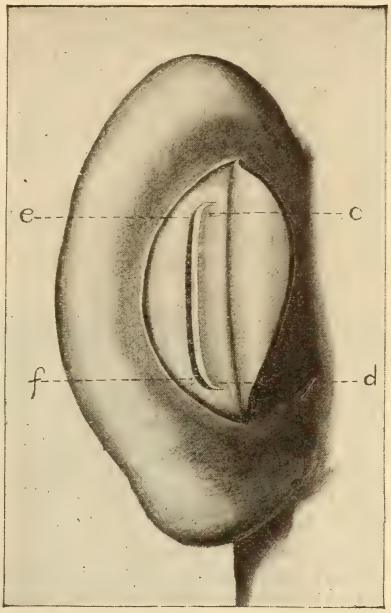

Fig. 89

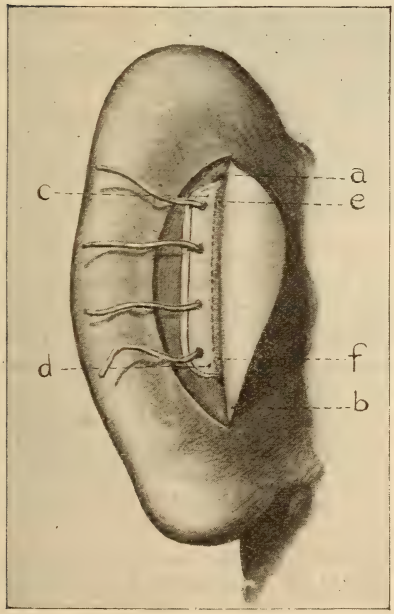

Fig. 90

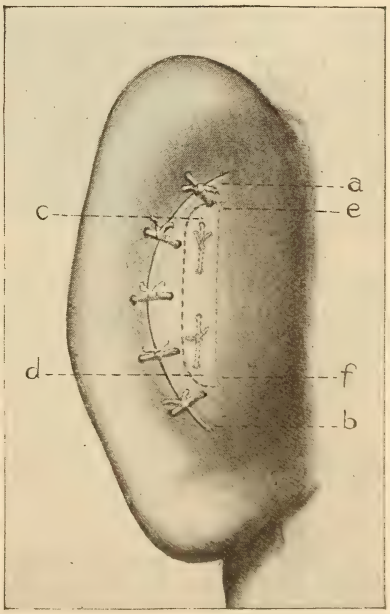

Figs. 87, 88, 89, 90.—Serve to illustrate the steps of operation for projecting auricle. (From *Goldstein,* Laryngoscope. With permission.)

CHAPTER XIII.

DISEASES OF THE EXTERNAL EAR.

(*Continued.*)

NEOPLASMS OF THE AURICLE.

1. Benign Growths. 2. Malignant Growths.

Papillomata.—Benign epithelial excrescences usually assume the form of ordinary papillomata, or common warts. Ordinary papillomata appearing on the auricle are similar to those observed in other portions of the body and require the same treatment. They are invariably small, being seldom larger than a small pea.

Dense horny offshoots with broad bases spring from the rim of the helix or the tip of the lobule. In one such case (Fig. 80) seen by the author the entire lobule had become elongated and hard and hoof-like in density. The mass was about three-fourths of an inch in length and one-half in diameter, and blunt at the distal extremity. These ossifications are rare and occur among uncleanly and ill-nourished people—at least, such was the environment of the author's case.

Treatment.—Common papillomata or warts should be clipped with scissors, close to the base of attachment, and the cut surface seared with fuming nitric acid or fused chromic acid.

Horny growths require complete removal by excision with the scalpel.

Fibromata; Keloid.—Of the deeper-seated tumors the fibroma type is more common, the lobule being the usual seat, although it may appear on any portion of the auricle. The negro race is especially prone to the development of both fibromatous and keloid growths.

Fibroma develops in the connective tissue and results from mechanical irritation. The numerous accidents and injuries associated with the wearing of earrings suffice to produce enough irritation to cause fibromata to develop. Old mastoid and other wounds about the ear become the seat of development in the same racial proportion.

In size the fibroma varies from a millet seed to that of a hen's egg, often becoming sufficiently large to partially or wholly occlude the external meatus. The surfaces are usually smooth and hard, with few if any nodules, and are rarely pedunculated. Recurrence after removal is common.

Prognosis.—The prognosis, so far as life is concerned, is good, there being no positive evidence, even in unoperated cases, of alterations in structure or degeneration into malignant type. Tendency to recur, even after repeated and most thorough removal, constitutes the chief obstacle to a favorable outcome.

TREATMENT.—The treatment consists in the thorough removal of the entire mass, under the strictest asepsis, the incisions to be carried well into healthy tissue. Much pains should be taken in coaptating the opposing surfaces and in stitching closely, with the minimum irritation, by means of fine catgut sutures. When located upon the auricle a V-shaped incision, including the tumor, followed by careful approximation of the cut surfaces, eventuates in but little deformity, when the growth is of moderate size. Small growths, unattended with marked disfigurement, should not be subjected to operation.

Fig. 91.—Postauricular sebaceous cyst. (Author's case.)

Sebaceous Cysts.—Sebaceous cysts (atheromata) are invariably the same wherever they may occur, the causative factor being the inflammatory closure of a normally open mouth of a sebaceous gland, with the inevitable accumulation of normal sebaceous secretion.

About the ear the favorite site is the lobule and the space posterior thereto, at the aural junction with the temporal bone (Fig. 91).

The sebaceous cyst is not painful even upon pressure, and it is slightly movable and soft to the touch. Spontaneous rupture, through the skin, from overdistention, sometimes takes place, in which event the sac becomes partially emptied of sebaceous contents, followed by closure.

TREATMENT.—Applying modern surgical precautions, the opera-

tion requires a free incision through the skin, avoiding, if possible, the sac wall, and careful dissection and removal of the cyst wall. This may require the vigorous application of the curet.

After cleansing and suturing a pressure pad is placed over the tumor site and a suitable bandage applied. In a majority of patients local anesthesia suffices.

Cystomata.—This form of tumor, when occurring in the concha, is a non-traumatic collection of fluid within the soft tissues of the auricle, without involving the perichondrium. They are sacculated, contain no clots, and usually contain serum only. Occasionally a small surface of cartilage will be found exposed at the inner wall of the cyst. They are usually found upon the anterior surface, often

Fig. 92.—Extensive congenital angioma of the auricle, the side of the face and the head (side view). Over a considerable portion of the central area the cutaneous surface is bluish red. On palpation the mass feels like an aggregation of distended blood-vessels.

assuming considerable proportions. The pain is slight, merely a sensation of heat, and no tenderness upon pressure. They usually appear quite suddenly, and, unless injured or unduly manipulated, there is but little tendency to increase in size after the first appearance. But little is known as to their causation.

Treatment consists in complete evacuation. This was formerly accomplished by means of aspiration. Later developments have shown that free incision, complete evacuation of the contents, and the application of sufficient pressure to hold the surfaces together until healing takes place, with perhaps a slight wick drain during the first two or three days, will usually effect a cure with but little danger of recurrence.

Angiomata.—Two varieties of vascular neoplasms are observed upon the auricle: 1, the simple, which usually occurs in the form of small bright-red or bluish patches of various sizes, with little elevation or swelling, and located chiefly upon the anterior surfaces.

2, the cavernous, which are large pulsating tumors, commonly involving the adjacent structures, notably the jaw and face. The cases observed by the author have all been congenital. Others have reported cases resulting from injury or frostbite.

Jungken[1] reports a fatal hemorrhage resulting from a congenital nevus. The deformity attendant upon these growths is so marked and disfiguring that the otologist is usually consulted as to the best means for promptly reducing the growth and otherwise improving the general appearance. In one of the author's cases similar to that reported by Chimary, and described as cirsoid aneurism,[2] the entire lobule was enormously enlarged from birth,

Fig. 93.—Same as Figure 92 (front view). The illustration shows that the auricle is completely detached from the temporal bone and hangs loosely as a part of the tumor mass. The face is asymmetrical.

the tumor involving the entire region of the squamous and mastoid portions of the temporal bone, and extending forward over the face to a point about midway from the ramus of the jaw to the point of the chin. It was deep-seated, semi-fluctuating, with bright-red surfaces (Fig. 92).

The auricle had become completely detached from its bony attachment and sagged an inch or more with the tumor mass and produced an ugly deformity (Fig. 93). This case was considered inoperable.

Treatment.—For simple birthmarks without extensive venous enlargement, electrolysis or repeated galvanocautery applications in the form of linear cuts may be depended upon to effect a cure, but not without some scarring. Multiple puncture has been recom-

[1] Schwartze's Ohrenheilkunde, p. 77.
[2] Archiv für Ohrenheilkunde, vol. viii, p. 63.

mended. Cavernous tumors, unless sufficiently limited in area to be operable by excision, may be destroyed by means of Esmarch's method of silk threads passed deeply through the tumor, having been previously immersed in the tinct. ferri perchloridi solution. Several of these are introduced at one time, the ends being allowed to project from the point of entry and exit, and the whole tumor surface protected by a stearate dressing until healing is complete. Various forms of styptic injections, administered with the hope of coagulating the tumor contents, have not proven successful and are attended with more or less danger arising from the dislodgment of small portions of any resultant clot in the form of emboli. Excision is applicable in appropriate cases, numerous ligatures being employed through the base in order to control hemorrhage. Whenever the entire auricle is the seat of cavernous angioma, but little improvement may be hoped for from any form of treatment.

Deposits of lime or uric acid salts found about the upper half of the concha in the form of hard oval lumps, sometimes as large as a pea, are not infrequently found. These usually occur in gouty individuals.

MALIGNANT TUMORS OF THE AURICLE AND EXTERNAL MEATUS.

Malignant tumors of the auricle and external auditory canal are not common. They may occur in these parts either primarily or as offshoots, by continuity, from those located elsewhere. Sarcoma is rarely primary.

The neoplasm may originate in any portion of the auricle and subsequently extend to the meatus, or the order may be reversed. The cases of epithelioma observed by the author have invariably originated in the external meatus, and gradually extended throughout the pinna, and at the same time they have slowly migrated inward through the tympanum, mastoid process, labyrinth, and finally have entered the cranial cavity, with fatal results.[3] Of the two varieties—epithelioma and sarcoma—the former is much more common.

Epitheliomata.—Epitheliomatous neoplasms originate in the form of small, shiny, tough nodules, superficially located, the nature of which may be long unsuspected until ulceration and degeneration ensue. They also become a local manifestation of more generalized carcinoma.

The cancerous proliferation extends throughout the entire tympanum and accessory spaces, usually reaching the cranial cavity, where it produces a fatal issue. Occasionally the carcinomatous development in the ear is secondary, and reaches this location either by way of the tubal canal or from the cranial or nasal cavities. It rarely occurs in the young, the larger proportion of cases recorded being between the ages of forty and sixty years.

[3] According to Toynbee, carcinoma usually develops in the mucous membrane of the tympanic cavity.

The condition is associated with severe pain, early and persistent, and a profuse offensive and bloody discharge, often containing small particles of bone. In the later stages, vertigo, severe tinnitus, deafness and even facial paralysis may appear. The ulcerated surfaces are covered with exuberant granulations, elevated above the surrounding surfaces, and associated with redness and swelling in the adjacent tissues. In the later stages the ulcerations are covered with a sanious exudate. Death usually occurs as the result of exhaustion or extension to vital organs. The duration is from one to two years, seldom longer, although one of eight years and another of twenty-one years have been recorded. Previous to the development of pain, the symptoms are those of intense irritation and pruritus, which later on gives way to active ulceration, with discharge.

In the present state of our knowledge of the etiology of malignant disease, it is only possible to state that the ear furnishes the same field for its development, though to a somewhat less degree, as other portions of the body. Its exposed position tends to aggravation of the symptoms on account of mechanical irritation. They progress more slowly than in other tissues, and glandular complications also appear later, general infiltration is slower, and operative treatment, when instituted early, may be considered more hopeful, especially in the ephithelial form.

These somewhat favorable conditions arise from the fact that cartilaginous tissue absorbs any form of infection slowly. Even after the ulcerative stage has become well established, it is quite possible to successfully and permanently eradicate the disease by operation. The diagnosis may be obscure previous to the stage of ulceration, and must be based upon the characteristics of the malignant nodule. The ulceration is characteristic and usually unmistakable. In suspected cases, and in all cases of ulceration of the auricle or external auditory canal characterized by exuberant granulations, eroded surfaces, elevated borders, and, later on, necrotic areas in the cartilage, sections should be removed for microscopic examination.

Treatment.—But one general form of treatment for malignant growths of the auricle is worthy of consideration. In every instance and under all circumstances and conditions, barring advanced cases, the entire mass should be removed by means of the knife. The incision should be carried well into the surrounding healthy tissue, in order that no trace of the disease remains. The plan of procedure will depend upon the limits of the area of tissue involved. At times it becomes necessary to remove the entire auricle in order to reach the limits of the disease, an operation which is entirely permissible on account of the favorable results which may ensue. In amputating the pinna it is important, if possible, to preserve the epithelial lining of the meatus by suturing it to the edges of the skin at the external surface of the wound, thus insuring an open meatus. Unfortunately this is seldom attainable for the ulceration has usually extended too far into the canal, in which event some

form of tube should be introduced and kept *in situ* until the wound heals. Even with the tube, atresia of the canal may result, requiring some form of plastic operation. Skin grafting may be attempted, providing open surfaces remain, the grafts being so applied as to tend to maintain the lumen of the canal. Infiltration of the parotid gland is serious, and indicates progressive general infection.

Fig. 94.—Epithelioma of the auricle. (Author's case.)

Removal of the tumor under these circumstances is unwise and attended with extreme danger to life. Facial paralysis usually contraindicates operative measures.

Where only portions of the auricle are removed, a careful study should be given to the best means to be employed in molding and shaping the remaining portion of the ear so as to maintain as nearly as possible the normal position. Surgical principles should be followed in the removal of nearby lymphatic enlargements.

Much has been written of the merits of the X-ray and radium applied for the cure of superficial carcinoma. While there seems

to be well authenticated evidence that these measures tend to retard cell proliferations in some individuals, the author is still doubtful as to permanent benefit.

These measures should never be relied upon to the exclusion of the knife, but are worthy of trial in inoperable cases, and to prevent recurrence after surgical extirpation.

Fig. 95.—Same as Figure 94. Later stage of the disease.

Fig. 95 illustrates a case which was attended by some unusual incidents:—

Miss B., aged 36 years. Had a severe cold in head in June, 1907, followed by a watery discharge from the left ear, which occurred without pain.

After one month she began to complain of pain, which gradually increased and prevented sleep. The pain was located in the canal.

She consulted her family physician, who found the canal swollen, inflamed, and bathed in discharge. His diagnosis was acute purulent otitis media.

About September 1st the discharge became offensive and the pain increased. There was no mastoid tenderness, but the probe came in contact with exposed bone along the floor and posterior wall of the canal.

At this time the mastoid was opened by the family physician, who found no pus or necrosis therein, but much pus and granulation in the external auditory canal. The posterior wound healed promptly, but there was no cessation of discharge from the canal, while the pain became so severe that morphine was commenced.

I first saw her in consultation on September 24th. There was much swelling and granulation tissue in the canal, offensive discharge, and the posterior inferior canal wall was necrotic. All typical symptoms had become obscured by the previous operation. There was no external swelling.

A complete radical mastoid operation was performed at this time. There was no involvement of the mastoid antrum, but the attic and posterior canal wall were necrotic and covered with granulations. This was all carefully scraped away and the posterior wound sutured.

There was no appearance of a neoplasm, and the scrapings when submitted to the laboratory gave no evidence of such a growth.

Subsequent history, however, of continuous pain, profuse uncontrolable malodorous discharge, gradual opening of the healed posterior wound, and general protruding of the entire pinna, with a peculiar neoplastic appearance of the granulation masses, was sufficient evidence for a diagnosis of malignancy. Accordingly, a section was sent to the laboratory of the Manhattan Eye, Ear, and Throat Hospital, in January, 1908. Laboratory report was as follows:—

"Proliferation of granulations. Regular in appearance.

"Microscopic examination: This specimen is a typical example of a flat-celled epithelioma, contiguous to the areas of a typical epithelium and others of round-cell granulation tissue. In one area of this granulation tissue there is a detached island of the epitheliomatous tissue. Some of the blood-vessels are plugged with abnormal epithelial cells.

"Signed: Jonathan Wright."

By this time there was much swelling of the entire auricle, but no glandular complications.

About this time the patient was exhibited at a meeting of the New York Otological Society, and varying opinions were expressed as to the treatment, some members advising complete excision of the entire pinna, and others recommending treatment by either X-ray or radium.

The patient was advised to have the pinna removed. She refused further operative interference of any form, and was referred to Dr. Robert Abbé for treatment with radium. Several applications of radium were made under his direction, apparently without any effect on the disease, her pain being aggravated for some hours after each sitting. The X-ray proved equally ineffective.

The infiltration gradually extended over the mastoid and squamous regions and throughout the pinna, the latter being gradually eaten away. (Fig. 95.)

During August, 1908, facial paralysis appeared, not, however, as a result of involvement of the parotid gland.

She became much emaciated, with constant pain, which yielded only to large doses of morphine, and died from exhaustion in December, 1908.

Sarcomata.—This variety of malignant neoplasms rarely develops primarily in the external ear, being less frequent than epithelioma. Occasionally the auricle becomes the seat of secondary deposits from adjacent sarcomatous tissue, notably the cervical regions (Fig. 96).

Development may be slow or rapid, depending upon the variety of cell proliferations, the small round-cell type tending to rapid growth. Sarcoma nodules are softer and more vascular than carcinoma, and ulceration takes place later. The spindle cell and

fibrosarcoma develop slowly, after remaining practically inert for indefinite periods.

Disintegration is characterized by ulceration, with raw granulating surfaces of fungoid appearance, exuding unwholesome-appearing secretion, which may be sanious, watery or purulent, with a tendency to bleed upon the slightest touch, while the clinical appearance is usually sufficient to establish a diagnosis beyond reasonable doubt. It may wisely be reinforced by microscopical examination of a section obtained from the suspected growth.

Fig. 96.—Postauricular osteosarcoma. (Patient of Dr. E. Terry Smith.)

Prognosis.—The prognosis is invariably bad, except in the primary giant-cell type, when by early and complete removal a permanent cure is possible.

Treatment.—Destruction by caustics and galvanocautery is contraindicated. The treatment for sarcoma is precisely that recommended above for epithelioma—viz., radical extirpation with the knife, if possible, before the stage of ulceration. Advanced cases which give evidence of extensive ulceration, or involvement of the temporal bone, or parotid gland, should be considered inoperable, and sufficient morphine should be administered to control the attendant pain and suffering, until death occurs.

NEW GROWTHS IN THE EXTERNAL AUDITORY MEATUS.

The external auditory canal sometimes becomes the seat of various forms of new growths, which may be classified as benign tumors, malignant growths and infectious granulomata.

Benign Growths.

Of the benign tumors, polypi, enchondromata, and bony neoplasms are the chief. Polypi almost invariably spring from some portion of the tympanic cavity and never from any portion of the external auditory canal, except its walls have become the seat of some form of chronic purulent inflammation. The treatment of aural polypi is described in Chapter VIII.

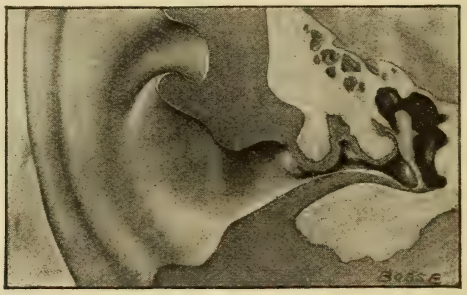

Fig. 97.—Exostosis of the external auditory canal. (Partly schematic.)

Enchondromata.—Enchondromata in this location are exceedingly rare, although they sometimes occur and usually result from some prolonged irritation or injury in the outer portion of the canal. They are always amenable to treatment by removal, and show but slight tendency to recurrence.

Exostoses of the External Meatus.—Exostoses spring from the bony portion of the external auditory meatus, and furnish by far the larger portion of all benign growths developing in this location (Fig. 97). Various causes have been assigned, no one of which furnishes sufficient evidence to explain every case. It is, therefore, assumed that the disease may originate from several sources, among which may be mentioned:—

(*a*) *Rheumatic or gouty diathesis,* which may predispose. Clinically, there is no apparent evidence that gout ever leads to the formation of exostoses in the external auditory meatus.

(*b*) *Chronic purulent otitis media.* In the author's experience they have usually been found in canals which have long been subject to the discharge from a chronic purulent otitis, resulting from the prolonged irritation of said discharge, or as a result of the manipulation connected with its various forms of treatment. Suppuration may have ceased, leaving evidences of its former ravages.

They do, however, occasionally develop in the canals of those who have never suffered from otorrhea.

(*c*) *Heredity.* In two or three instances meatal exostoses have been observed in several individuals in the same family.

(*d*) *Race.* It has been noted that certain races are more liable to exostoses, the percentage being greater among Europeans. The Hawaiians also manifest a tendency to exostosis of the canal, which may be explained as arising from the irritation of prolonged and frequent immersion in salt water incident to their habits. The skulls of the aborigines show a preponderance of meatal exostoses.

(*e*) *Traumatism.* The favorite location, aside from the postero-superior wall, is at the junction of the cartilaginous and bony portions. Occasionally, these outgrowths are pedunculated, although wide bases are often seen, and at times they assume a sessile form. The tumors are usually extremely dense and hard, although considerable cancellous material will be observed in some.

So long as exostoses remain small in size, no subjective symptoms are noted. They are of slow growth, and years may pass with no symptoms pointing to their presence; indeed, it is quite possible for them never to assume sufficient size to produce any symptoms whatever during the life of the individual. The first notable symptom appears when the size of the growth becomes sufficient to interfere with audition, the sensation being that of fullness in the ear and diminishing audition. Occlusion of the canal lumen by exostoses gives rise to pressure symptoms of an annoying type, often with decided neuralgic pain and disagreeable autophony, while tinnitus becomes troublesome. The impingement of an exostosis upon the membrana tympani may eventuate in pressure necrosis of this membrane, and thus open up the tympanic cavity to infective inflammation.

The diagnosis is never difficult to the experienced eye. The osseous nature of the growth, its location and immobility, render the diagnosis easy and simple. There is no external evidence visible, and a good reflected light serves for purposes of inspection. In some instances the tumor will be found covered with cerumen; in others the patients' attempts to remove the cerumen leaves a more or less ulcerated surface, thus obscuring the diagnosis. Ordinarily there is no reddening, roughness, or ulceration of the surfaces, but rather a covering of smooth, shiny integument. Removal of the cerumen restores the outlines.

A patient now under observation has a very large exostosis, which nearly fills the lumen of the tube. It does not, however, seriously interfere with hearing, and he complains of no symptoms except at such times as the small remaining segment becomes clogged with cerumen or epithelial *débris*. Thirty-six years ago the growth had been pronounced epithelioma of the canal. There is no history of purulency, the growth has been present for a period of about forty years and still does not interfere with audition or manifest any annoying symptoms.

Prognosis.—These neoplasms are never dangerous to life, and

impairment of hearing occurs only after the canal becomes completely occluded. They develop slowly, their progress varying in different individuals and under different circumstances. When accompanied by otorrhea, growth is evidently more rapid. There is much doubt whether, under any circumstances, they ever assume a malignant type. They are always amenable to surgical removal, with no tendency to recur; hence, prognosis may be considered good.

Treatment.—Unless located sufficiently near the drum to cause pressure symptoms or ulceration, tumors of small size which produce no symptoms require no treatment. The size and location of the growth should be noted, and a drawing made upon the patient's history chart for purposes of reference. He should be informed of the condition and instructed to appear from time to time for observation. Furthermore he should be warned that at some time operative interference might become necessary, to relieve pressure and maintain audition. As a preventive measure, the employment by patients of any mechanical means for the removal of cerumen, whereby the surfaces of the tumor might be irritated, should be forbidden.

While it is unnecessary to interdict sea-bathing, the ear should be stuffed with cotton to prevent the entrance of salt water, which might otherwise irritate the growths, and, in addition, the general employment of fluids in the canal should be avoided, except when necessary to remove impacted cerumen, and then only by the attending physician. Surgical procedures only are worthy of considerations for the eradication of these growths, and the indications for their removal are as follows:—

(*a*) Impairment of hearing on account of occlusion.

(*b*) Relief of pain and other pressure symptoms.

(*c*) To terminate ulceration caused by impingement of the neoplasms upon the drum membrane, or upon each other.

(*d*) To facilitate local treatment of an accompanying purulent otitis media.

(*e*) Invariably as a step in the performance of a needed radical mastoid operation.

The exact mode of procedure to be followed in the removal of exostoses depends upon their site, kind of base, and whether multiple or single. Neoplasms situated near the external orifice, or those with narrow bases located more deeply in the canal, are amenable to removal through the external orifice, and under local anesthesia by means of deep injections of cocaine. Following the ordinary measures of asepsis, the skin is incised and the periosteum elevated. A fine narrow chisel is now introduced and held firmly to the base of the growth, and a few taps of the mallet will suffice to separate the growth from its attachment, with but little danger of puncturing the drum or otherwise wounding the deeper structures. Any remaining roughness about the site may be smoothed by scraping with a curet or by the dental burr, the latter to be employed with great caution on account of the danger

of accidental injury to the surrounding tissues, and it is never to be used by the inexperienced.

Deep-seated, broad-based and multiple exostoses are more skillfully, thoroughly, and safely ablated by detaching the auricle by a posterior incision, similar to that employed for the mastoid operation, under general anesthesia, although it is quite possible to perform the operation painlessly, by injecting a solution of cocaine deeply at points under the skin and periosteum of the mastoid and posterior canal wall. After proper preparation of the surface to be incised, a Wilde incision close to the auricular attachment is carried directly down to the mastoid bone. The periosteum is then retracted forward only to the border of the bony canal, and then without break the elevator is directed inward along the canal wall, lifting the periosteum of the canal forward until the exostosis comes into full view. In skillful hands it is usually possible to reach this step without danger to the drum, or tearing through the integument covering the neoplasm. The growth should now be separated by means of a small, sharp chisel, driven home with a few taps of a mallet, and the rough surfaces smoothed by scraping with a curet. After washing away all *débris* and clots from the wound, the tissues should be replaced throughout and the posterior wound sutured. It is a wise procedure to pack the external canal quite firmly with sterile gauze for three or four days, in order to hold the replaced soft tissues firmly in place and maintain its patency. There is no external deformity following this operation, and the linear scar from the incision is scarcely observable after a few months.

One of the author's recent cases:—

F. A., aged 21, purulent otitis media in childhood, and complained of tinnitus, increasing deafness, and, more recently, pain in the right ear.

Diagnosis.—Large sessile exostoses upon posterior and superior canal walls, pressing upon the drum membrane. He was operated upon by posterior incision as above described.

Examination after a lapse of three months; hearing normal, no tinnitus and no pain, and the external auditory canal is patent.

When removing an exostosis during the progress of a radical mastoid operation, it is advisable to excavate the bone deeply throughout the bony canal, and thus avoid the narrowing and contraction which is prone to follow these operations, and here the usual flap is constructed from the membranous canal. In suitable cases an ossiculectomy may be performed simultaneously with the external operation for ablation of an exostosis. There is no scientific basis for treating these growths by resorting to laminaria tents, electrolysis, X-ray, or antirheumatics.

Angiomata.—True cavernous angioma of the external auditory canal does not occur except in conjunction with other larger surrounding areas. The affection is fully described under the heading "Angioma of the Auricle."

Myxofibromata.—Myxofibromata, while found occupying the

external auditory canal, usually spring from some portion of the tympanic cavity.

Osteosarcomata.—The growth is rare in this location and seldom occurs primarily, but rather as an extension from the jaw or temporal bone. Any operation involves a coincident removal of the entire mass.

Epitheliomata.—Epitheliomata develop primarily in the external meatus in a considerable proportion of all malignant neoplasms which spring from the auricle. They also appear as a result of extension from contiguous structures, even from the tonsil. The course and treatment have been described on page 156.

NEW GROWTHS ON THE MEMBRANA TYMPANI.

The membrana tympani may become the seat of a variety of new growths in the form of vascular tumors, or epithelial neoplasms. It may also be the seat of infectious granulomata, tuberculous ulceration, and syphilis. Occasionally inflammatory or hemorrhagic cysts appear, while calcification is of common occurrence. Malignancy does not appear primarily, but may extend from other localities and involve the drum membrane. Inasmuch as these affections are described in detail in their appropriate chapters, they are merely mentioned here, and only for the systematic arrangement of topics.

NEW GROWTHS IN THE EUSTACHIAN TUBE.

Outgrowths in the form of connective-tissue proliferations, granulation tissue, polypoid excrescences, and fibrosarcoma spring from the membranous surfaces of the Eustachian tube, while denser neoplasms like hyperostosis, exostosis and calcification involve the cartilaginous and bony portions. The Eustachian tube may also become the seat of infectious granulomata, tuberculosis, and syphilitic gummata.

NEW GROWTHS IN THE MASTOID ANTRUM AND CELLS.

Polypi and Granulomata.—Polypoid degeneration and granulation-tissue proliferation are common in this region, where they usually complicate purulent otitis media. These outgrowths spring from diseased surfaces of the antrum, the mastoid cells or epitympanum. They may occur single or multiple. As the mass increases in size it invades the tympanic cavity, thence through the aperture in the drum, often reaching to the mouth of the external meatus. Those of large size are usually pedunculated, and have been divided into ordinary hard, round-celled and mucous polypi, fibromata, and myxomata. Of these the simple granulomata are by far the most common, and often during the course of a mastoid operation surprisingly large quantities are excavated.

Infectious granulomata, a term here applied to syphilitic and tuberculous neoplasms, are occasionally found in the mastoid

process. They consist of a desquamative inflammatory process, associated with the active formation and breaking down of epithelial cells, from the superficial epithelial layer of the middle ear and its adnexa. The epithelial formations consist of large polyhedral cells with nuclei, resembling epidermal cells, and frequently containing cholesterin crystals between the individual layers.

TREATMENT.—Removal by either the simple or radical mastoid operation.

Cholesteatoma of the Temporal Bone.—The seat of cholesteatomata is usually at the upper and outer portion of the tympanic cavity, often involving the epitympanic space, and mastoid antrum. Their tendency is to grow upward and develop into organized masses, which press upon and ultimately destroy the mastoid cell walls. If a cholesteatoma has existed for a long period of time, large pneumatic spaces will be found occupied by the mass, their walls being composed of ivory-like, eburnated bone. These large spaces always connect with the tympanic cavity. The above condition does not usually take place before the thirtieth year (Virchow). The development of cholesteatomata is often attended with considerable danger, on account of its tendency to invade and destroy the bony structures, in which event infection may secondarily be carried to the meninges or large blood-vessels. Demonstrations by Kershner have proven that cholesteatomata possess the power to migrate into apparently healthy bone and to invade even the Haversian canals.

The radical mastoid operation is the only feasible measure for the cure of this condition. Even after complete excavation, recurrences are common, often necessitating repeated operations.

SECTION III.

The Middle Ear.

CHAPTER XIV.

DISEASES OF THE MIDDLE EAR.

DISEASES AND INJURIES OF THE MEMBRANA TYMPANI.

THE membrana tympani occupies an intermediary position in which it completely divides the external from the middle ear, its outer (dermal) layer being continuous with the skin of the external meatus, and its inner (membranous) layer with that of the tympanum. It is therefore liable to participate in the diseases both of the external meatus and the middle ear.

Idiopathic inflammation of the drum membrane is extremely rare. A vast majority of its diseases originate in the adjacent structures on either side. Bezold and Siebenmann[1] contend that, inasmuch as so-called acute and chronic myringitis is so rarely unassociated with simultaneous inflammation of the external or middle ear, they should not be given an independent classification, while Politzer[2] advocates in strong terms his belief that primary myringitis with distinct pathological changes does occur, and, further, that it is sometimes induced by pathogenic organisms. He lays much stress upon the slight interference with the hearing function in myringitis, even when it extends beyond the confines of the drum to the tympanic walls. It is the opinion of the author that primary idiopathic inflammation of the drum membrane is exceedingly rare, and that in no instance where the inflammation of the drumhead is secondary to disease of the adjacent structures should the term myringitis be employed.

ACUTE MYRINGITIS (PRIMARY ACUTE INFLAMMATION OF THE MEMBRANA TYMPANI).

Etiology.—The chief etiological factors are localized infection of the drumhead from traumatism, and local irritants in the form of caustics, impact of cold water from sea-bathing or douching, and foreign bodies. The disease may extend over the entire surface of the membrane and penetrate the entire structure; or it may be superficial.

Symptoms.—The initial symptom is severe pain in the ear, often radiating in all directions, sometimes preceded by a sensation

[1] Text-book of Otology, p. 123.
[2] Diseases of the Ear, p. 280.

of fullness lasting for several hours. In severe cases the pain radiates over the parietal region. Tinnitus is usually present, with slight disturbance of hearing which persists until the disease subsides. Some rise of temperature may be expected in young children. Examination of the drum membrane reveals localized inflammation, varying from a moderate congestion, which is confined to the dermal layer without exudate, to severe swelling with intralamellar exudation in the form of blebs filled with serum. Petechial spots in the membrane are sometimes visible. After a few hours the blebs rupture externally, and healing gradually ensues after exfoliation of the dermal layer has taken place. For some time after the rupture of the blebs, considerable moisture will be found in the canal, while the desquamative period is characterized by the presence of detached flakes and shreds in the inner portion of the canal. Resolution is usually rapid, the congested appearance of the membrane gradually subsiding upon the formation of new epithelium.

Diagnosis.—It is difficult to differentiate myringitis from acute catarrhal and the early stage of acute purulent otitis media. Otitis media of either type is usually preceded by an attack of acute rhinopharyngitis, and there is marked loss of hearing from the commencement, while in myringitis there is but slight interference with the hearing function at any stage. In purulent otitis media the pain is apt to be persistent and to increase in severity until the drum membrane ruptures. There is also marked bulging of the entire drum after a short interval. Even though a discharge appears in myringitis there is no perforation of the drum membrane. Myringitis is of shorter duration than acute catarrhal otitis media and usually terminates in recovery without permanent pathological changes in the tissue of the drum. Even when cuts, scratches and blebs have been present with copious exudation, recovery usually takes place without loss of hearing.

Treatment.—The course of treatment depends upon both the causative factors and the severity of the case. In simple cases unattended by blebs or traumatism the treatment is palliative. If the pain is severe codeine may be administered in doses of one-fourth grain every three hours until relieved, and the patient should remain indoors for a day or two and subsist upon a light diet. Local treatment of the drum is unnecessary. The hot-water bag applied to the ear relieves pain.

As soon as the acute symptoms begin to subside, the patient may be permitted to go about his daily duties. When the inflammatory process is sufficiently sudden and severe to produce blebs or blisters, they should be incised at once, the incision to penetrate only the dermal layer of the drum, inasmuch as perforation of the inner layer permits infection to enter the tympanic cavity. In order to obviate possible infection through the incision, the operation may be preceded by douching the external canal with a warm bichlorid of mercury solution and carefully wiping with sterile cotton, and likewise pledgets of sterile gauze may be placed in the external meatus until the surface of the drum becomes healed.

Should the cause of the attack be traumatism wherein the rupture, laceration or cut extends entirely through the drum membrane, there arises the danger which would result from the entrance of pathogenic bacteria into the tympanic cavity; indeed, in a limited proportion of cases of this nature, purulent otitis media ensues in spite of all preventive efforts. To combat infection the canal should be douched at once with a bichlorid of mercury solution and carefully wiped clean and dry with sterile cotton. A pledget of sterile gauze lightly packed into the outer orifice of the canal will serve as a protection to the drum. The drum membrane and canal should be inspected daily and all moisture and *débris* removed at each sitting. Any resultant tinnitus or slight deafness will usually yield to moderate inflation, which procedure may be inaugurated after the acute symptoms have subsided.

TRAUMATIC LESIONS OF THE MEMBRANA TYMPANI.

General Remarks.—Diseases of the drum membrane, barring injuries, are almost invariably those associated with the different types of affections which originate primarily in the external auditory meatus, or still more commonly in the middle ear and its adnexa. The various pathological changes in the membrana tympani and their significance are fully described in the chapters covering the diseases of the external and the middle ear.

Traumatism.—Traumatism of the membrana tympani results from: (1) Direct violence. (2) Indirect violence: (*a*) By sudden condensation of air, either in the external canal or tympanic cavity, and occasionally by sudden rarefaction of air in the external meatus. (*b*) By extension from a fracture of the temporal bone.

Direct Violence.—The location of the membrana tympani, deep in the somewhat tortuous external auditory canal, the outer aperture of which is afforded considerable protection from invasion by the lid-like tragus, is such that it is seldom the seat of direct traumatism.

Direct injuries to the drum membrane may be self-inflicted or wholly accidental.

Those first mentioned occur in the form of wounds from bullets, sword or stiletto thrusts, portions of shells; the thrust of sharp-pointed objects like hatpins, sharp sticks, received accidentally or in combat, and from the impact of portions of explosives, flying sparks, chips and stones, and from clumsy attempts to extract foreign bodies from the external meatus. Twisting or pulling the auricle has been known to tear the drum membrane in its upper segment. Occasionally a rupture occurs from accidentally puncturing the drum from within while passing the Eustachian bougie. Self-inflicted injuries usually arise from digging, scratching or picking the ear with a pointed or sharpened instrument for the relief of meatal pruritus, or the removal of scales, cerumen or foreign bodies. The usual implements employed for this baneful procedure are ear-spoons, hairpins, toothpicks, penholders, matches, lead pencils and

the earpieces of spectacles. There is considerable variation in the location and size of direct injuries to the drum, depending upon both the course of the canal and whether the implement is sharp, blunt, smooth or jagged. Most of the injuries, however, are located in the upper segment. In recent injuries it is possible to obtain a clear outline after all extravasation of blood has been removed, while later on the infiltration may be so extensive as to render the outlines of the wound unrecognizable. In rare instances sharp penetrating instruments or projectiles pass entirely through the drum membrane and invade the labyrinth, producing serious and even fatal results.

During the preparation of this chapter the following unusual case came under the observation of the author:—

Patient X, aged 38, blacksmith, with an unusually large and straight external meatus and a small tragus, which nowise obstructed its orifice. Ten days previously, while swinging a piece of red-hot iron in an upward and downward direction preparatory to plunging the same into cold water, a spark flew directly into his left ear. He was immediately seized with violent, deep-seated earache, which continued for about eighteen hours. Some sweet oil was poured into his ear on several occasions, and no other treatment was given. After two days a mucopurulent discharge appeared, and he complained of moderate tinnitus and slight deafness. Upon examination there was a slight, nearly healed excoriation at the orifice of the meatus; otherwise the entire external canal was free from evidence of injury. There was a large, grayish slough upon the drum membrane, covering about one-fourth of its surface and located in the upper posterior section, while the remaining portion was intensely inflamed and infiltrated. There was a small quantity of mucopurulent exudate along the floor of the canal. Upon inflation a distinct whistle was heard. After thorough cleansing it was found impossible to locate the chip of iron. Careful hearing tests showed but little loss of hearing by aërial conduction. The treatment advised was a warm 1:5000 bichlorid of mercury douche four times a day, the canal to be wiped dry with sterile cotton after each douche, light packing of the outer orifice of the canal during the interval. The discharge continued about one week longer, after which the perforation healed without perceptible loss of hearing.

With rare exceptions all extensive perforating wounds of the drum membrane eventuate in middle-ear suppuration, the probable source of infection emanating from the penetrating object. In neglected cases the open perforation permits an invasion of pyogenic organisms from without. The treatment of this form of injury is not unlike that of acute purulent otitis media.

Self-inflicted injuries are usually less severe and rarely perforate the drum membrane, although a few cases are upon record (Bezold and Siebenmann) where patients have not only torn open the drum membrane but have dislocated or dragged away the ossicles. Single scratches or bruises of the drum usually heal promptly and without suppuration, providing ordinary aseptic precautions are followed out in the treatment.

Indirect Violence.—Indirect violence in the form of sudden condensation or rarefaction of air in the external meatus may produce complete rupture of the drum. It would seem that the drum membrane either entirely resists the sudden change in air

pressure or sustains a rupture through all its layers, since partial rupture or extensive ecchymosis is rarely observed.

These ruptures are slit-like, occasionally oval, with sharply defined edges which in recent cases are covered with hemorrhagic exudate. They are seldom multiple. The most common location is the anterior inferior quadrant. Among the causes the following are enumerated: Condensation of air in the external meatus as a result of blows (boxing the ear); diving from heights, bathing in the surf, explosions (dynamite, gunshot, cannon, mortars), falls upon the ear, and concussions from caissons, bell diving and lightning strokes.

The air douche employed for inflating the middle ear produces rupture of the drum membrane only when it is the seat of scar tissue or marked atrophy. The same holds true of rarefaction in the external meatus, depending upon suction by otoscopic instrumentation, kissing upon the ear, or atmospheric pressure in high

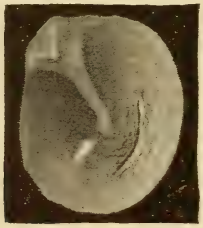

Fig. 98.—Rupture of the drum membrane due to concussion from "boxing the ear."

altitudes. Unfortunately, the concussion wave may be of unusual severity and extend through the ossicular medium to the labyrinth, with disastrous effect upon the auditory nerve terminals. Subjectively, the symptoms of rupture in the order of occurrence are: loud sound in the ear, violent but momentary pain, tinnitus (severe cases are often accompanied by nausea and vomiting and vertigo when the labyrinth is involved), slight deafness, Weber test heard in the injured ear (in labyrinthine cases of marked deafness Weber test heard in normal ear), suppuration in the majority of cases.

Indirect Violence from Cranial Fractures.—Rupture or tearing of the drum membrane, when resulting from injuries to the skull from falls or blows, may occur independently of bony fracture, or more commonly in conjunction with fractures of the temporal bone.

Since such ruptures are continuous with the bone fractures, they are located in the upper portion of the membrane and accompanying luxation or fractures of the ossicles are occasionally observed. The symptoms are hemorrhage from ruptured vessels of the membrane, from the fractured diploë and from the labyrinth or meninges when those structures are implicated. A flow of cerebrospinal fluid occurs in occasional cases.

Treatment.—Hemorrhage may usually be controlled by tamponing the external auditory meatus with sterile cotton or gauze. In a patient coming under observation soon after an injury and without serious hemorrhage, the chief requirements are to remove accumulated exudation from the canal without disturbing the edges of the perforation. At the same time the canal walls should be carefully rubbed with alcohol or bichlorid of mercury solution 1 : 4000 for purposes of disinfection. Furthermore it is important to prevent if possible the access of infection to the middle ear through the rent in the drum membrane. A loose sterile wad of gauze or cotton placed in the outer orifice constitutes the most available protection against outside infection. During this stage instillations and douches do positive harm and are contraindicated. If middle-ear suppuration ensues the further treatment should conform to that advised for acute purulent otitis media, Chapter XVIII.

Finally, since the otologist is often required to give expert testimony in suits for damages to the ear, it is important to carefully record even the minutest facts relating to the causation and history of every case of injury, to note the appearance of the external canal walls, membrana tympani, and in case of perforations the condition of those portions of the cavum tympani which may be inspected or felt with a probe, and to ascertain all symptoms, both objective and subjective.

Politzer[3] lays much stress upon the medico-legal aspect of otitic injuries.

---

[3] Diseases of the Ear, p. 247.

CHAPTER XV.

DISEASES OF THE MIDDLE EAR.
(Continued.)

SURGICAL ANATOMY OF THE MIDDLE EAR AND EUSTACHIAN TUBE.

Anatomy.—The middle ear consists of the Eustachian tube, the tympanic cavity and its contents, together with the aditus ad antrum, antrum mastoideum and mastoid process (Fig. 99).

The tympanic cavity is about 15 mm. in height, 3 mm. in width, and from its anterior to its posterior wall measures about 10 mm. It is a four-sided cavity, having three bony and one membranous wall, in addition to a roof and a floor. Its upper portion is anatomically differentiated from the tympanic cavity proper, being designated the aditus ad antrum. It is also termed the epitympanic space. This corresponds roughly to that part of the tympanic cavity situated above a line drawn horizontally at the level of the processus brevis. The head of the malleus and the body and short process of the incus are contained within this space (Fig. 100, *F, G*). This part of the tympanic cavity is often termed the "attic."

Laterally (externally) the tympanic cavity is separated from the external auditory canal by the membrana tympani (Fig. 100, *B*). Above the floor of the aditus this wall is bony, made up of the outer wall of the aditus (Fig. 39). The anterior wall is really a convergence of the inner and outer walls, and the orifice of the Eustachian tube (Fig. 99, *G*).

Above, the tympanic cavity merges into the aditus ad antrum, while posteriorly a hard, bony wall forms its lower boundary. Above this bony wall and within the region of the aditus an opening, the aditus proper, is shown leading to the mastoid antrum. The roof of the aditus is the tegmen tympani. The floor of the tympanic cavity is a rather thin lamella of bone. It separates the dome of the jugular bulb from the tympanic cavity (Fig. 100, *C*). This lamella of bone occasionally presents defects (dehiscences), placing the blood-vessels in direct contact with the tympanic mucous membrane. The posterior wall of the tympanic cavity rises from the tympanic floor in a slight curve, and presents at its upper limits a number of pneumatic cells. This wall is limited below by a square ledge of bone, merging toward the median line into a pyramidal eminence from whose lateral end a small bony canal runs toward the facial canal. The canal of the facial nerve runs its course deeply down on the posterior tympanic wall.

The mesial or labyrinthine wall of the tympanic cavity presents a rounded protuberance—the promontory (Fig. 100, *D*). This is a flat, rather hard bulging plate of bone formed by the basal turn of the cochlea. It presents a smooth surface toward the tympanic

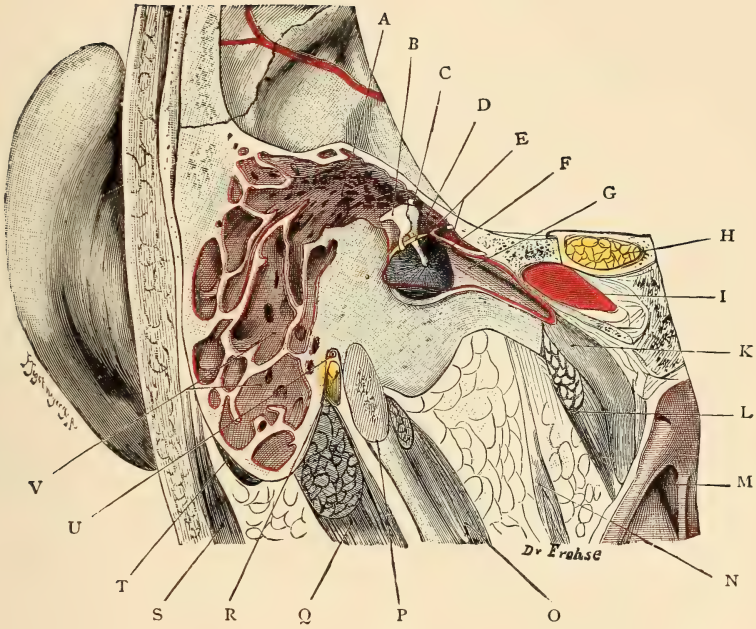

Fig. 99.—Vertical section through left temporal bone in the plane of the axis of the petrous portion. (From Bardeleben's Applied Anatomy, with permission.) The mastoid cells (red) are shown radiating from the antrum mastoideum. The lower part of the tympanic cavity is removed so as to expose the external auditory canal. The ossicles and the drum are seen from behind.

A, Antrum.
B, Incus.
C, Superior ligament of the malleus.
D, Chorda tympani.
E, Tensor tympani muscle.
F, Malleus umbo.
G, Eustachian tube.
H, Fifth nerve.
I, Internal carotid artery.
K, Cartilage of Eustachian tube.
L, Levator palati muscle.
M, Pharyngeal orifice of the Eustachian tube.
N, Superior constrictor of the pharynx.
O, Stylohyoid muscle.
P, Styloid process.
Q, Digastric muscle.
R, Facial nerve.
S, Sternomastoid muscle.
T, Splenius capitis muscle.
U, Stylomastoid artery.
V, Mastoid cells.

cavity, merging anteriorly into the wall of the Eustachian orifice. At its lower part, the labyrinthine wall is lost in the tympanic floor. Above, posteriorly, the wall presents the fenestra ovalis, while below, posteriorly, the fenestra rotunda is situated.

The aditus ad antrum is a triangular prism-shaped space, leading from the tympanic cavity to the antrum mastoideum. This space is bounded anteriorly by the tensor tympani muscle together with a spur of bone—the crista transversa—situated just above the tensor tendon and by a series of mucous folds (plicæ transversæ) exceedingly variable in form and extent. These serve

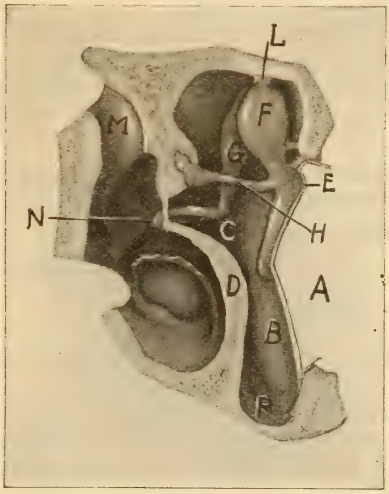

Fig. 100.—Partly schematic drawing from specimen (enlarged) after *Siebenmann,* showing: *A,* External auditory canal. *B,* Posterior surface of drum. *C,* Tympanic cavity. *D,* Promontory. *E,* Process brevis malleus. *F,* Malleus head. *G,* Incus. *H,* Tensor tympani. *L,* Suspensory ligament of malleus. *M,* Part of superior semicircular canal. *N,* Footplate of stapes seen from labyrinthine side. (From Kopetzky's "Surgery of the Ear," Rebman Co., Publishers.)

to connect the tensor and the crista transversa by forming a curtain which occupies a position perpendicular to the longitudinal axis of the aditus (Siebenmann). Posteriorly the aditus ad antrum is gradually merged in the antrum mastoideum.

Contained in the tympanic cavity and aditus ad antrum is a chain of small bones, the ossicles. These are three in number, the malleus, the incus and the stapes.

With this general sketch of the anatomy of the tympanic cavity as a background, we take up some of its more important structures, which concern us more intimately in the study of the diseases of the middle ear.

The Membrana Tympani (Fig. 101).—This is a translucent, pearly, delicate, smooth and glistening membrane, the borders of

which are attached to the slightly curved edge of the internal end of the bony auditory canal, called the annulus tympanicus. The membrana tympani is divided anatomically into the pars membrana tensa and the pars membrana flaccida (Fig. 102). The *pars membrana tensa* forms the chief portion of this membrane, while the *pars membrana flaccida,* or Shrapnell's membrane, is a small, crescent-shaped area lying above or superior to the *processus brevis* and the *incisura Rivini.* Shrapnell's membrane is not as obliquely placed as the neighboring portion of the *pars tensa,* and in the living subject, especially, it is more or less distinctly differentiated from the latter by two flat folds known as the anterior and posterior folds of the membrana tympani (Fig. 102).

In form the membrana tympani is irregularly oval, or elliptical, and the *margo tympanicus* is often distinctly rounded off. At the *incisura Rivini,* or Rivinian fissure, which is made up of the break in the upper portion of the bony ring, the membrana flaccida, or

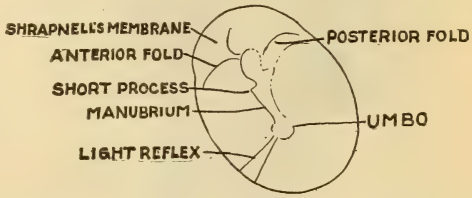

Fig. 102.—The landmarks of the membrana tympani.

Shrapnell's membrane is rather loosely attached, which accounts for the greater mobility of this part of the drum. The form and size of the Rivinian fissure varies, averaging in height 2 mm. and in width from 2.5 to 3 mm. The exact form of the membrane is determined by that of the surrounding ring.

The membrana tympani is made up of three layers, the outer of which is continuous with the lining of the external meatus, and is composed of derma. The inner layer is a part of the mucous lining of the tympanic cavity, while between these two layers a third, or fibrous layer, is found.

The size of the membrana tympani is not materially affected by age, for the reason that both the ring and the membrane are almost fully developed in very early life.

The inclination of the membrana tympani depends upon its relation to the walls of the external meatus, observations and measurements varying with the angle from which the observation is taken. It is stretched obliquely downward and inward at the inner end of the bony meatus, so that its plane forms an obtuse angle with the upper wall and an acute angle with the lower wall of the tube (Fig. 103). Anteriorly the angle is very acute, and posteriorly it is obtuse, because the plane of the drum is slanted in two directions.

The membrana tympani presents a more or less concave surface, the dome of the concavity encroaching upon the tympanic

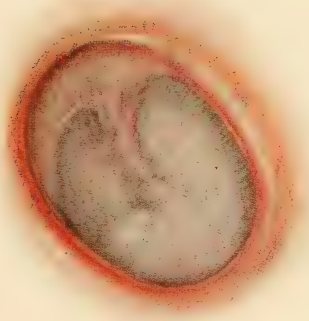

Fig. 101.—The normal membrana tympani. Both the artist and the author have combined in endeavoring to produce the normal color, contour and landmarks of the drum membrane in its entirety as seen through the speculum by reflected light.

cavity. The deepest portion of the dome, the umbo (Fig. 102), marks the insertion of the distal end of the malleus handle between the layers of the membrane.

The Light Reflex.—Illumination of the tympanic membrane brings to view a cone of light in the form of a triangle, the apex of which is near the umbo, the general direction being downward and forward toward the periphery, the base-line being rather poorly defined, parallel with and a short distance from the drum periphery (Fig. 102). Between Shrapnell's membrane and the neck of the malleus a marked depression is found, corresponding to Prussak's space. Here the mucous lining folds upon itself so that it passes over the chorda tympani nerve on the inner side of the membrana tympani.

Fig. 103.—Lateral view, showing the normal relations of the external auditory canal, drum membrane, ossicles and tympanic cavity. Special attention is called to the angles formed by the drum membrane with the walls of the osseous meatus.

Deviations in the anatomical relations in infancy and early childhood are referable to the incomplete development of the temporal bone at that age.

The diseases of the Eustachian tube form a part of the diseases of the tympanic cavity, and, in the treatment of the diseases of the latter, attention to this important structure becomes of prime importance; therefore, a brief consideration of the anatomical peculiarities of the tube deserves attention here.

Eustachian Tube.—Physiologically considered the Eustachian tube serves both as a ventilating apparatus for the middle ear and as the channel of communication between the rhinopharyngeal space and the tympanic cavity, for the purpose of equalizing the ratio of pressure between the external air and that contained in the middle-ear spaces.

In direction the Eustachian tube passes from the upper anterior portion of the tympanic cavity inward and downward toward the pharyngeal vault. Its length in the adult is about 36 mm. For about one-third of the distance from the tympanic cavity the walls

of the tube are bony; the remaining two-thirds are cartilaginous. The point of junction between the bony and cartilaginous portions is very narrow and is designated the isthmus (Fig. 99, *g, k, m*). The dimensions of the lumen of the Eustachian tube are subject to individual variations. Its walls are probably altogether closed at its middle portion while at rest, but they open during the act of swallowing. The lining membrane of the tube is made up of ciliated epithelial and goblet cells. The deeper layers of its structure are made up of cartilage and bone in the outer one-third, and cartilage in the inner two-thirds. The layer of ciliated epithelium in the cartilaginous portion of the tube lies directly upon a layer of adenoid tissue of variable thickness. This adenoid stratum has been called the tubular tonsil (Gerlach and Teutlevan). In the young child the adenoid tissue of the tube is much more developed than in the adult, and assumes the form of prominent lymph follicles, hence occlusion of the tube occurs much more frequently in childhood than in later life because of swelling in the tissue. The mucous glands are acinous in structure and form a thick layer, frequently interrupted by a stratum of fibrous tissue. Isolated glandular ducts occur throughout the adenoid tissue. Both the mucous glands and the adenoid tissue decrease toward the isthmus of the tube.

The cartilage of the Eustachian tube does not form a complete and rigid tube, but, like the trachea and the cartilaginous auditory canal, consists of a furrow, the open part of which becomes closed by membranous tissue, to form the tube. Ossification of the cartilaginous tube is apt to occur as a senile change. The lower end of the tubal cartilage projects to a variable degree into the rhinopharyngeal space, and its posterior lip forms the back boundary of the triangular, funnel-shaped excavation, designated the ostium pharyngeum. The mucous lining of the posterior lip of this ostium contains an abundance of adenoid and glandular tissue. It has a diffuse and more or less vivid coloring, contrasting sharply with the more or less pale and yellowish tint of the general tubal opening. Occasionally a salpingopharyngeal fold may be seen extending perpendicularly into the mucous lining of the lateral pharyngeal wall springing from the ostium tuba.

The bony walls of the tube gradually widen toward the tympanic cavity without sharp differentiation. In the bony tube the mucosa is firmly united to a layer of thin periosteum and this is closely adherent to the bone. Mucous glands are very rare, only one or two being found in the adult Eustachian tube. Ciliated cylindrical epithelium is found throughout the mucous lining of the tube. The bony tube presents cells containing air and lined with mucous membrane, the cellulæ tuberæ, fully described by Bezold. These are of importance in radical mastoid surgery and will be reverted to later. In the adult they arise from the bottom, from the median wall and from the outer median angle of the tube. These are not present in the newborn, although by the end of the first half year of life they become plainly visible.

In the newborn the membranous part of the cartilaginous tube predominates over the cartilaginous section. There is no perceptible isthmus at its junction with the bony tube, the os tympani being as yet imperfectly developed, but at the age of nine months the topography of the tube practically resembles that of the adult. The faucial orifice of the tube in the fetus lies below the horizontal plane of the hard palate, reaching the level of the palate at about the time of birth. At four years of age it is 3 to 4 mm. above this, according to Kunkel, and in the adult it is about 10 mm. above the level of the hard palate. In the young child the posterior lip of the tube does not present a distinct projection into the pharyngeal vault.

Within the tympanic cavity and the aditus ad antrum and lying mostly in the latter is the ossicular chain, which is composed of the malleus, incus and stapes.

The Malleus and its Ligaments.—The malleus, the largest of the three bones, is irregular in shape, being made up of the oval head, which gradually tapers into a narrow portion known as the neck. The neck converges into an expansion of bone, which forms two processes: (*a*) The processus brevis, a small tubercle below and posterior to which is attached the tendon of the tensor tympani muscle, is plainly visible on inspection from the external auditory canal, and constitutes one of the landmarks of the middle ear. (*b*) The processus gracilis, a long slender and somewhat fibrous process, which passes forward into the Glaserian fissure, and is only well marked at birth. The remaining portion of the bone gradually tapers into the long process (handle or manubrium), the distal end of which is imbedded between the layers of the membrana tympani, to which it is firmy attached.

Four ligaments, the anterior, superior, external and internal, serve to hold the malleus in position. The anterior is attached to a groove found in the anterior portion of the neck and head, its other attachment being the wall of the Glaserian fissure and anterior wall of the tympanum, surrounding the processus gracilis. The function of this ligament seems to be to limit somewhat the motion of the malleus.

The superior or suspensory ligament is attached to the tympanic roof in its outer portion, also to the head of the malleus. Its function seems to be to hold the malleus firmly, limiting its motion downward and outward.

The external ligament is fan-shaped, its broader attachment arising from the margin of the Rivinian notch, its apex from the neck of the malleus. By these attachments outward rotation of the manubrium is limited.

The internal ligament is in reality the sheath of the tensor tympani muscle and therefore passes from the processus cochleariformis to the inner surface of the malleus handle around the attachment of the tensor tympani tendon, its function being to limit the outward motion of the handle of the malleus.

The Incus and its Ligaments.—The incus or anvil occupies the

central position in the series, its upper portion assuming the form of an anvil, and is made up of a body, a short and a long process. The short process presents rather more the form of a tubercle, being somewhat conical in shape, and its tip projects beyond the level of the floor of the aditus ad antrum (Fig. 99, *B*). The long process passes downward and backward, parallel with but at a plane deeper than that of the malleus handle, terminating in its attachment to the head of the stapes, the joint of attachment being known as the incudostapedial joint. At its lower portion it curves inward in order to unite with the stapes. The long process is also known as the lenticular process. The incus ligament is a fibrous band passing from the posterior extremity of the short process to that portion of the tympanic wall near the mastoid antrum.

The Stapes and its Ligaments.—The remaining ossicle, the stapes, is in direct communication with the auditory mechanism by the attachment of its foot-plate with the cavity of the oval window. The general form of the stapes is quite similar to that of a stirrup, and almost the entire bone is submerged in the pelvis ovalis, the head, neck and a small portion of each crus sometimes being visible. The stapes assumes an oblique position in the oval window, its position being nearer to the posterior and inferior walls of the fossa. Adhesions occasionally form between the posterior wall and the nearby stapedial crus. Various forms of adhesions, in fact, are found in this vicinity. These are pathological.

Surrounding the foot-plate of the stapes and confining it in position in the oval window is a ligament known as the stapedio-vestibular ligament.

The remaining ossicular ligaments are of the capsular variety, covering the articular surfaces of these bones.

The Intratympanic Muscles.—Two muscles are found in the tympanic cavity, the *stapedius* and the *tensor tympani.* The first originates in the interior of the pyramid, through the apex of which its tendon passes to be inserted into the neck of the stapes. This muscle receives its nerve supply from a branch of the facial, and it acts upon the head of the stapes by causing the bone to make pressure upon the contents of the vestibule.

The tensor tympani muscle, larger than the stapedius, lies in a bony canal, running parallel to the Eustachian tube. It arises from the cartilage of the Eustachian tube, and from the surface of the great wing of the sphenoid, some fibres also arising from the walls of its own canal. Its tendon passes round the processus cochleariformis on the posterior tympanic wall, then turns outward into the tympanum, which it crosses to become attached to the inner surface of the malleus handle just a little below the level of the processus brevis.

It receives its nerve supply from the motor root of the fifth nerve. This muscle has the power to make traction inward upon the malleus, thus controlling the tension of the membrana tympani.

Blood-supply of the Middle Ear.—Tympanic branches from the internal maxillary and internal carotid arteries, also from the stylo-

mastoid branch of the posterior auricular artery, the petrosal branch of the middle meningeal, together with a small branch of the ascending pharyngeal, furnish the blood-supply of the middle ear.

The distribution of the veins of the middle ear is such that the venous blood escapes into the superior petrosal sinus, the lateral sinus, the internal jugular vein, the temporomaxillary vein and the pharyngeal veins, while a few small veins pass upward through the tegmen to communicate with those of the dura mater.

The lymphatics of the middle ear form a part of the parotid and posterior auricular lymphatics.

The chorda tympani is the nerve seen as a whitish streak, just below the posterior fold of the drum membrane, in Prussack's space. This nerve emerges from the aquæductus Fallopii above the eminencia pyramidalis and it crosses the tympanic cavity from behind forward between the long process of the incus and the handle of the malleus. It leaves the tympanic cavity through the Glaserian fissure to join the lingual branch of the trigeminus, reaching the Glaserian fissure by the posterior fold of the membrana flaccida as designated above. The importance of this exact localization of this nerve becomes evident during some of the intratympanic operations to be hereafter described. Its severance impairs the sense of taste of the injured side.

CHAPTER XVI.

DISEASES OF THE MIDDLE EAR.

(Continued.)

THE most satisfactory classification of middle-ear diseases is obtained by adopting a pathological basis.

Primarily, we divide the diseases of the middle ear into those which are bacterial and into those which are non-bacterial in origin. The non-bacterial diseases of the middle ear are known as "catarrhal," and those of bacterial origin we designate as inflammations. The latter are the lesions which result from the invasion of micro-organisms; the former—the catarrhal—are due to the mechanical effects produced by closure of the Eustachian tubes. Both the catarrhal and the inflammatory groups of middle-ear diseases are divisible into acute, subacute and chronic types of middle-ear disease. Incidentally it is to be noted that the chronic catarrhal type of otitis media is distinctly different from another chronic middle-ear disease, viz., otosclerosis.

ACUTE MIDDLE-EAR CATARRH.

Etiology and Pathology.—The pathological changes in this condition are largely confined to the pharyngeal portions of the Eustachian tube. There are few pathological changes in the structure of the middle-ear spaces. The mucous membrane of the tube becomes reddened and swollen, the tube lumen narrowed or closed. The result of this closure of the lumen of the Eustachian tube is a retraction of the membrana tympani. This is a common clinical observation. The mucous membrane of the middle ear seems to have the property of absorbing the air contained in the middle-ear spaces (Boeninghaus). With the lumen of the tube closed by catarrhal swelling, this faculty of air absorption in the middle ear causes a negative pressure in the middle-ear spaces, and the air pressure in the external auditory canal forces the drum inward toward the promontory in an effort to establish compensation.

Regarding the air absorption within the tympanic cavity, little is known. Bezold regards it of similar nature to the air changes which take place in the lungs. Körner, on the other hand, regards the faculty as similar to the absorption of air which takes place in cases of pneumothorax, where the air is absorbed by the pleura. The air is taken up according to this authority by the lymph spaces in the mucous membrane. When the air absorption continues, the drum membrane is drawn inward (Fig. 40), and this process continues until the elasticity of the drum has reached its limit. The tendency to vacuum formation continuing, a hyperemia of the

mucous membrane (Fig. 106) results, from which a transudate finally flows into the tympanic cavity (Fig. 104).

The quantity of transudate which is exuded is commensurate with the amount of negative pressure within the tympanic cavity, and its formation ceases when this negative pressure has been balanced.

The transudate is sterile, it having been examined by Scheibe (1892), Brieger (1896), Launois (1896), Kümmel (1906), and found to contain no micro-organisms. Therefore, we class these cases with the non-bacterial involvements of the middle ear. The sudden closure of the Eustachian tube which is characteristic of catarrh of the Eustachian tube and tympanic cavity is immediately followed by diminished hearing, tinnitus and a sensation of fullness or stuffiness in the ears.

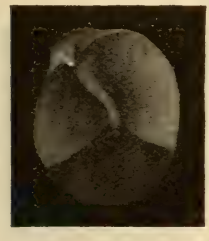

Fig. 104.—Showing early stage of serous transudate into the tympanic cavity as a result of an attack of acute catarrhal otitis media. (Partly schematic.)

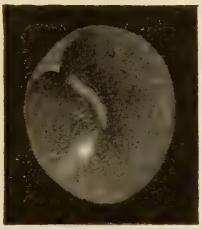

Fig. 105.—Congested blood-vessels along the line of the malleus handle. The drum membrane is retracted.

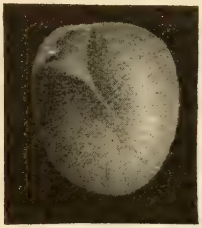

Fig. 106.—Hyperemia of the blood-vessels of the drum membrane during the early stage of acute catarrhal otitis media. Note the retraction which is characteristic of this disease

Symptoms.—Pain is sometimes present but is never severe. Patients are prone to point to the region of the tonsil as the seat of pain, probably on account of the involvement of the Eustachian tube.

The affection is more pronounced in children who have chronic rhinitis or are affected with adenoid vegetations and hypertrophied tonsils.

In childhood the disease is often overlooked and usually neglected. It is only after the lapse of time, as the loss of hearing becomes gradually apparent to the parents or teachers, that the condition is brought under observation, and by this time it may have progressed into one of the chronic catarrhal forms.

Upon examination, the hearing may be found much impaired. When much impaired the whispered voice is apprehended at but a short distance, or only at the concha. While the deafness is a characteristic symptom, the power for sound perception varies widely in different cases. At times the patient hears almost normally, and at other times he is exceedingly deaf.

Adults complain of a feeling of "fullness" in the affected ear

and pressure within the head, usually combined with tinnitus aurium. The tinnitus is characterized as deeply pitched, is not of strong quality, and often is only observed by the patient during the evening hours. More rarely it is loud and clicking in character.

Autophonia, by which is implied a peculiar loud resonance to one's own voice, is sometimes a most annoying symptom. During the exudative stage the movement of the fluid within the tympanic cavity evokes variations in the hearing function, the hearing being worse when the patient is in the recumbent position. This, in brief, constitutes the clinical picture.

Course.—As the causative factor becomes eliminated, that is, when the coryza, the rhinitis, epipharyngitis, etc., abate, the catarrhal condition in the middle ear and tube gradually subsides, except among children with adenoids or where the nasal condition of "cold" is quasi-permanent, in which event the tubal

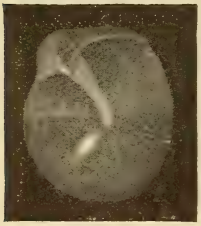

Fig. 107. — Showing upper level of tympanic transudate. Drum membrane retracted.

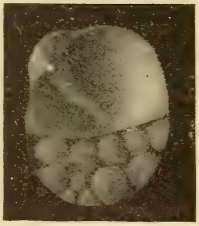

Fig. 108. — Air bubbles in the tympanic transudate, following inflation. (Partly schematic.)



Fig. 109. — Change in the level of the fluid induced by tipping the patient's head backward. (Partly schematic.)

and middle-ear catarrh often persists for months and even years, until finally physiological involution of the adenoid tissue takes place at puberty, and then, if the changes in the middle ear have not become permanent, the catarrhal otitis subsides. Generally, however, irreparable damage has been done the hearing apparatus by permanent changes in the mucous membrane of the middle ear, and so fortunate a result as spontaneous recovery does not occur. Rupture of the drum membrane does not occur in uncomplicated otitis media of the catarrhal form, inasmuch as the exudate is only compensatory and invariably non-bacterial.

The appearance of the drum membrane varies with the stage of the disease. Soon after the onset it presents a reddish tint. It is retracted; the concavity distorts the light reflex, and a pathological fold running from a point behind and below the processus brevis toward the posterior drum margin becomes evident. Shrapnell's membrane is usually drawn inward, and presents a second light reflex—a pathological finding—at its point of greatest concavity. The malleus handle inclines toward the promontory, appearing foreshortened. The processus brevis is usually sharply outlined. The blood-vessels of the drum are injected, especially

about the malleus handle (Fig. 105). The reddish tinge of the drum is due to the hyperemic condition of the mucous membrane in the tympanic cavity, including the mucous membrane layer of the drum itself (Fig. 106).

When the transudate has formed, a transverse line of demarkation becomes visible on the drum surface, denoting the upper level of the fluid in the tympanic cavity (Fig. 107). *There is no bulging* of the drum membrane in the catarrhs of the middle-ear spaces, because the fluid collects only to the extent of compensating the negative air pressure.

Diagnosis.—The diagnosis is based upon the otoscopic findings described above and this is substantiated by catheterization of the

Fig. 110.—Lateral view of the tympanum, showing air bubbles in the transudate. (Partly schematic.)

affected ear and interpreting the auscultation sounds thus obtained (Fig. 108). The level of the transudate will be found to have changed after inflation, or, upon changing the position of the patient's head (Fig. 109), and, in addition, air bubbles are often noted (Fig. 110).

Boenninghaus notes that in these cases postrhinoscopic examination will often show the pharyngeal orifice of the Eustachian tube narrowed, having a somewhat yellowish tinge against the surrounding red of the pharyngeal vault. Often the tubal orifice is covered with secretions, and, where inflamed adenoid tissue is present (in children especially), there may be purulent exudate in the pharynx.

In conclusion, the acute and subacute stages of acute catarrhal otitis media are variations in the degree of involvement rather than of kind, and the extent of the involvement indicates either an isolated tubal catarrh, or, what is a much more common observation, a tubal catarrh combined with varying degrees of catarrh of the middle ear.

Prognosis.—Prognosis is favorable whenever each attack is promptly relieved by appropriate treatment, but procrastination in treatment, or indifference as to the serious effects which are produced by repeated attacks often result in the chronic form of the disease, and permanent damage may be reached during childhood.

Treatment.—Having ascertained the nature of the immediate cause of an attack of acute catarrhal otitis media, the plan of treatment adopted should aim both to ameliorate or cure the primary affection and to restore the patency of the Eustachian tube.

The treatment of inflammations of the nasopharyngeal mucosa is fully described in the chapters covering these topics wherein emphasis is given to: (*a*) internal medication—cathartics, eliminatives, vasomotor constrictors, etc. (*b*) Local treatment of the nasopharynx: cleansing sprays, soothing emollient applications, anesthetic and vasomotor stimulants. (*c*) Surgical: the correction of abnormalities and deformities and the removal of adventitious tissues whether hypertrophied turbinates, mucous polypi, adenoids, hypertrophied tonsils or new growths.

Ventilation of the Eustachian tube and tympanic cavity is of still greater immediate importance, for herein lies the only means of affording relief from the distressing symptoms and of shortening the course of the disease. Of the approved methods of tubal inflation the catheter is the most effective for this condition, inasmuch as an oft-repeated and prolonged application of the air douche is necessary. (See Chapter VIII.)

As a preliminary to catheterization the nose and nasopharynx should be relieved of all accumulations of secretion and so far as possible made clean in order to minimize the danger of forcing any pathogenic material into the deep portions of the tube or tympanic cavity. An application of a solution of cocaine 2 per cent. in adrenalin 1 : 5000 along the floor of the nares and about the orifice of the Eustachian tube serves the double purpose of reducing the swelling of the soft tissues and facilitating the introduction of the catheter.

In children the removal of adenoids and hypertrophied tonsils often terminates the attacks of acute catarrhal otitis media without further treatment. The adenoid operation should never be performed during an acute attack. After the removal of the adenoids the air douche should be continued for some time, until all signs of the disease have disappeared. One of the chief benefits of the various operations for the relief of intranasal obstruction lies in the fact that a prominent contributing cause of acute and chronic catarrh of the middle ear is at the same time eliminated.

CHAPTER XVII.

DISEASES OF THE MIDDLE EAR.

(Continued.)

CHRONIC MIDDLE-EAR CATARRH.

Etiology.—The tissue changes involving the tympanic cavity and Eustachian tube in chronic catarrhal otitis media are of such a nature that they result in the production of new connective-tissue elements. These changes may result either from a long-continued inflammatory process or from a succession of acute attacks. These are usually traced to childhood and young adult life, during which attacks of inflammation of the nasopharyngeal mucosa attended with tubotympanitis, catarrhal or purulent, have been allowed to exist without proper treatment.

It is often possible to determine a predisposing tendency in the form of intranasal diseases and deformities, or affections of the pharynx and fauces which serve as the primary factor in the development of this condition. Chronic affections of the nose and nasopharynx extending to the middle ear through the Eustachian tube; adenoid vegetations in the vault of the pharynx; hyperplasia and bony enlargement of the turbinal bones; deflections of the nasal septum; chronic pharyngitis, all of which render the nose and nasopharynx liable to frequent attacks of acute inflammation with or without marked infection, tend to produce tubal inflammation. Prolonged tubal obstruction materially affects the tissues of the tympanic cavity, and, by producing improper aëration of the cavity, materially aids in the development of tissue changes there.

In young children diseased lymphoid tissue in the vault of the pharynx is the most prolific source, not only of acute and subacute catarrhal attacks, but finally of the development of chronic catarrhal middle-ear disease.

We find, therefore, the chief etiological factors to be (1) chronic inflammations and obstructive lesions of the nose and nasopharynx extending to the middle ear through the Eustachian tube (diseased lymphoid tissue, hypertrophied tonsils, hypertrophied turbinal bones, deflected septa, and chronic pharyngitis); (2) chronic tubal catarrh extending to the tympanic cavity; (3) recurring and persistent acute inflammations of the rhinopharynx.

Pathology.—The mucous membrane of the tympanic cavity is changed in character because of an addition to its connective-tissue elements. The mucous membrane of the Eustachian tube is similarly affected. The mucous membrane usually becomes thickened, and in addition there is a tendency toward the formation of adhesive bands. In the Eustachian tube there is a tendency toward stricture because the apposed walls of the tube, especially at the tubal isthmus, become eroded, and adhesions take place. Finally,

a thick glairy mucous exudate may cover the membrane. This latter is often absent.

Symptomatology.—The development of the disease is slow and insidious, and until some marked symptom such as tinnitus or an appreciable deafness appears patients may be entirely unaware of its existence. Pain or fullness of the ears usually occurs only during the acute exacerbations. Slight indefinite sensations of pain also occur during the intercurrent subacute exacerbations. The two most prominent symptoms are a gradually increasing deafness, and tinnitus. The tinnitus does not always appear early in the disease, but when it is present it clearly indicates to the individual that some functional intratympanic disturbance exists. It is usually intermittent, but may become constant and evoke great discomfort and nervous depression.

There is no uniformity in the decrease in the hearing power. Extensive changes may take place in certain localities unattended by a marked decrease in audition. On the contrary in localities essential to the hearing faculty comparatively slight tissue changes may seriously interfere with the hearing function. The disease shows a tendency to progress more in a series of consecutive exacerbations than as a steady progressive advancement. The loss of hearing frequently shows varying modifications, one of the chief being *paracusis Willisii,* or a manifest increase of the hearing power in the presence of extreme noises. This has been described by Roosa and others as "boilermakers' deafness," the phenomenon being explained by some writers as resulting from more or less rigidity of the ossicular chain, with contraction of the tensor tympani muscle. This peculiarity of hearing is always indicative of a rather grave form of the disease, with an unfavorable prognosis. Occasionally individuals complain of painful sensations when in the presence of loud noises (dysacousia, dysacousis). Deafness may be either unilateral or bilateral during the early stages, but eventually both ears succumb to the catarrhal process. When the tissue changes have resulted from a former purulent process the affection may remain unilateral. At any stage the deafness is aggravated by physical exhaustion, worry, damp weather, and the impairment of the general health.

A common symptom is described as a sensation of fullness and intratympanic pressure which is due to the partial closure of the Eustachian tube. The discomfort is marked. In other instances certain sounds are heard with more clearness than others. Sometimes this is the human voice, and at other times metallic clicks or noises in general, while the human voice seems to be more or less indistinct. The patient's own voice at times appears to him altered either in pitch or in character, often sounding extremely loud, or, on the contrary, is heard with extreme difficulty and as though coming from a long distance; the latter symptom is termed *autophony.* Patients usually hear better and feel freer from their symptoms during clear, dry than during moist, humid weather.

Other subjective symptoms, such as the hearing of sounds

twice repeated or echoed, with alterations in intensity or pitch, are known as *paracusis duplicata* or *diplacusis*. These symptoms are more easily defined when but one ear is involved and when the patient is musically educated, as then the normal pitch as distinguished in the healthy ear will be found altered when the same fork is applied to the diseased one. This has sometimes been termed *false hearing*, especially when the alterations are sufficient to be a source of discomfort and annoyance to the patient. The term "false hearing" or "pseudoacousma" is applied to this symptom when it is extremely well marked.

Tinnitus.—Tinnitus is variable both in constancy and character; hence, it becomes most difficult to adequately describe it. Tinnitus is a marked symptom of labyrinthine disease and of various intracranial affections. The tinnitus of chronic catarrhal otitis media is rather superficial and the patients do not usually refer to it as deep-seated or within the head. It may partake of a ringing, clicking character, or it may sound like the escape of steam, or the humming of seashells. In the acute and subacute stages of the disease the clicking variety of tinnitus often indicates an obstruction of the Eustachian tube of sufficient density to demand energetic measures of relief. This refers to strictures and adhesions. Tinnitus many times is the first and only symptom complained of by patients suffering from chronic catarrhal otitis media even before the loss of hearing is sufficient to interfere with audition in any marked way. The tinnitus is usually more marked at night and under appropriate treatment it may subside or disappear altogether. The proportion of people in general who suffer from tinnitus and from partial or complete one-sided deafness is comparatively large, and many times a severe attack of tinnitus is the first warning of approaching deafness.

At times vertigo, with or without disturbance of equilibrium, becomes a symptom of chronic catarrhal otitis media, although as a rule aural vertigo results from some diseased condition in the labyrinth. When present the vertigo is usually attributed to alteration of intralabyrinthine pressure, and it is believed that this may be brought about as the result of pressure upon the stapes and the round window by an accumulation of fluid in the tympanic cavity. The slight vertigo occurring as the result of chronic otitis media must not in any way be associated with those forms of vertigo ordinarily described as aural vertigo and Ménière's symptom-complex.

Symptoms of intratympanic pressure are occasionally of sufficient severity to give rise to actual unilateral headache. All these symptoms in the later stages, especially in hypersensitive subjects, manifest a decided tendency to the production of nerve depression and despondency.

The Otoscopic Picture.—Marked changes in the drum membrane are not always indicative of relatively extensive changes within the tympanum, nor do they necessarily impair the hearing function; on the other hand, extensive intratympanic changes, and

much diminution of audition may be present with a comparatively healthy looking and normal appearing drum. As a rule, however, in such cases the drum will be found to have lost some of its normal lustre, and unless atrophic changes have taken place other evidences of thickenings or adhesions will be found in at least certain portions of its surface. From the nature of the disease, interfering as it does with the function of the Eustachian tube, retraction of the drum membrane is to be expected (Fig. 111). In the earlier stages the gross appearance reveals, in addition to the retraction, more or less congestion, which is most marked along the manubrium (Fig. 105). Not infrequently the retraction becomes so marked as to change the normal position of the handle of the malleus by forcing it inward sometimes until it comes into contact with the promontory (Fig. 112). Under these circumstances the handle of the malleus appears foreshortened, occasionally to such a degree as to appear almost horizontal.



Fig. 111.—Drum membrane retracted.



Fig. 112.—Malleus handle foreshortened.

The light reflex will be found to be altered from the normal (Fig. 112). Often the reflex is double and the color of the drum is usually paler than normal unless it is so thin that the reddened mucous membrane within is seen through it. The retraction of the drum membrane brings the short process and often the malleus handle into sharp outline. The appearance of the pathological anterior and posterior folds is pathognomonic.

In certain cases during the later stages, when the patient has been subjected to over-inflation, the drum will be found relaxed, a multiple light reflex being indicative of this condition.

Atrophy is usually present during some of the stages, and as a result the translucency of the drum reveals to the eye the outlines of the promontory, the descending process of the incus, the incudo-stapedial articulation, and occasionally the crura of the stapes.

As the lesion gradually progresses evidences of infiltration in the form of opacities make their appearance. These usually first appear in the form of crescents near the periphery (Fig. 112); occasionally, however, patches of opacity appear near the umbo. The light reflex becomes less marked, less regular in form, and may finally disappear altogether. Occasionally a light reflex may be

observed in almost any portion of the drum. Calcareous deposits in the drum of varying sizes and shapes are occasionally seen (Fig. 113).

Whenever contraction of Shrapnell's membrane takes place the short process becomes apparently more prominent, with a marked depression above (Fig. 40). Sclerosis of the drum may in time become so extensive as to finally result in the obliteration of the smooth, glistening, external surface, and also to completely obscure the outlines of the malleus handle, at the same time causing the anterior and posterior folds to disappear.

The outlines of the old but healed perforations sometimes observed bear evidences of former suppuration (Fig. 114).

Examination of the membrana tympani is never complete until its *mobility* has been determined. For this purpose some form of suction apparatus is employed to determine just what portion of the drum is held down by adhesions. The manubrium should also



Fig. 113.—Retraction of the drum membrane with calcareous plaques.

Fig. 114.—Large perforation healed over with a thin layer of tissue.

be carefully tested in the same manner and its mobility determined. The tension of the drum at such examination should be compared with that which obtains under normal conditions, and both rarefaction and compression of the air in the external auditory canal are necessary to properly ascertain these data. Normal mobility may be present over certain areas and absent in others, and deep depressions may be found at spots where the firmest adhesions have taken place (Fig. 115).

The actual conditions present in the Eustachian tube are ascertained by inflation, catheterization, the employment of the auscultation tube and the bougie. The patency of the Eustachian tube is not always clearly shown by the appearance of the drum membrane after Politzerization, but the character of the sounds produced when air is forced into the Eustachian tube through a catheter and transmitted to the ear of the observer has marked diagnostic value. Under normal conditions a soft, smooth, low-pitched, blowing noise is heard, indicative of a patulous and unobstructed tube. When, however, a high-pitched, rough or crackling sound is heard, or if the bruit is obscure or almost entirely absent, some form of tubal obstruction is present. Tubal obstruction when unassociated with

extensive tissue changes in the tympanic cavity is considered favorable so far as restoration of hearing is concerned, while marked patency of the tube with advanced deafness indicates an unfavorable prognosis.

A variety of functional tests (see Chapter IV) to determine the character and extent of deafness are employed; some of these give definite diagnostic data, and others are useful for differential diagnostic purposes. The tests recommended and outlined in the examination chart (Figs. 12, 13) will usually be found sufficient for practical purposes and a diagnosis is possible by the employment of a few simple tests. It is advised that tests for distance be tried first. By the employment of the whisper and the acoumeter, the latter being more positive, the tests for distance are sufficiently

Fig. 115.—Lateral view of the tympanic cavity, with key plate, partly schematic. The drum membrane is much retracted (1) and the inferior segment (2) is held firmly adherent to the internal tympanic wall by inflammatory adhesions (3).

covered. The watch and the spoken voice may be added. Of these three methods the acoumeter is preferred, as neither the intensity nor the character of the sound produced by this instrument ever varies, a condition which does not obtain when employing the voice or the watch as a test.

Functional tests should be made at the first visit, before inflation is attempted. When one ear only is involved, or even in bilateral cases where marked difference in the hearing distance is present, the Weber test, in which a vibrating tuning fork placed either upon the vertex, the forehead or the teeth is heard best in the affected ear, suffices to establish a deafness due to interference with the conducting apparatus, except, perhaps, in those rare cases where, late in the course of the disease, impairment of the auditory nerve has taken place.

The other tests, the Rinné, the Schwabach, are then carried out. For details of these see Chapter IV.

Diagnosis.—Diagnosis of chronic middle-ear catarrh therefore depends on the history of progressive deafness and tinnitus, of periodical attacks of tubal catarrh, of an otoscopic picture showing retraction and sclerosis of the membrana tympani with occasional atrophic areas, changes in the character and position of the light reflex, and occasionally calcareous deposits. Confirmatory evidence is furnished by the employment of the hearing tests already referred to.

The nasopharyngoscope devised by Holmes (Fig. 116) marks a distinct advance in the examination, diagnosis, and treatment of affections located in and around the pharyngeal orifice of the Eustachian tube. By introducing the 'scope into the nostril opposite the tube which is to be inspected, one is able to obtain a satisfac-



Fig. 116.—The Holmes pharyngoscope.



Fig. 116*a*.

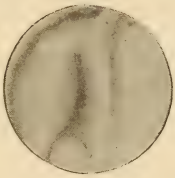

Fig. 116*b*.

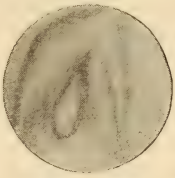

Fig. 116*c*.

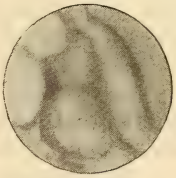

Fig. 116*d*.

Fig. 116*a*.—Pharyngeal opening of a normal Eustachian tube. Fig. 116*b*.—Anatomically constricted tube. (Chronic epipharyngitis and salpingitis.) Fig. 116*c*.—Papilloma attached to the posterior superior wall and about one-third inch from the orifice of the tube. Fig. 116*d*.—Two adenomatous polypi arising within the tube. Both turbinals, much hypertrophied, resting upon the anterior lips of the tube and in contact with the growths within the lumen of the tube.

tory view of the entire orifice and surroundings. The illustrations, are instructive and at the same time significant of the usefulness of this instrument. The instrument is also available for examining the orifices of the sphenoidal sinuses and, in some instances, those of the posterior ethmoidal cells. Furthermore, it may be employed in examining the larynx.

The pharyngeal opening of a normal Eustachian tube is shown in Fig. 116*a*. A papilloma attached to the posterior superior wall of the orifice of the Eustachian tube is shown in Fig. 116*c*. Two, adenomatous tumors within the Eustachian tube, together with the posterior ends of the inferior and middle turbinals, the latter resting upon the anterior lip of the Eustachian tube and in contact with the growths, are shown in Fig. 116*d*.

Differential Diagnosis.—The disease should be differentiated from otosclerosis, an affection which is characterized by progressive deafness, running its course without evidence of catarrhal symptoms, and independent of those contributory factors found in the nose, throat and Eustachian tube. Affections of the labyrinth differ from chronic catarrhal otitis media in the characteristic symptoms of vertigo and deep-seated tinnitus and in loss of the bone conduction of sound, the latter alone indicating disease of the sound-perception apparatus.

Prognosis.—The prognosis in chronic catarrhal otitis media depends upon the nature and location of the tissue changes, the age of the patient, the degree of deafness present, and the chronicity of the disease itself. The disease promises a more favorable prognosis during the early or hypertrophic stage, also when occurring as the result of pathological conditions in the nose and nasopharynx, and finally when the disease is largely confined to the limits of the Eustachian tube. Timely institution of rational treatment in the earlier stages renders the prognosis more favorable. The return of normal or nearly normal hearing may be expected after restoration of normal conditions in the nose and nasopharynx, as a result of removal of diseased lymphoid tissue from the pharyngeal vault, of diseased or hypertrophied turbinate bones or deflected septa, the radical treatment of suppurating accessory sinuses, and by the maintenance of normal tubal conditions.

Intratympanic adhesions, extensive sclerosis, and prolonged and unvarying deafness, especially when occurring with but slight tubal involvement or intranasal disease, are conditions which render the prognosis unfavorable.

Symptoms of commencing labyrinthine involvement are always to be regarded unfavorably, and little improvement is to be expected from any form of treatment in the way of amelioration of deafness in such cases.

Treatment.—The treatment of chronic catarrhal otitis media should be based not only upon the visible signs exhibited upon examination of the membrana tympani, the nose and nasopharynx and the Eustachian tube, together with a complete series of functional tests, but also upon a complete general physical examination of the patient, together with a proper supervision of his habits, occupation, and mode of life. Should examination bring to light any organic disease, either of the nervous, circulatory or glandular system, or those of a more general character, such as tuberculosis, syphilis, diabetes, Bright's disease, rheumatism, gout, or digestive affections, appropriate and vigorous treatment must be instituted to combat the condition found. Proper habits of rest and exercise should be insisted upon, and excesses, especially in the use of alcohol and tobacco, interdicted.

The author has repeatedly proven by observation and treatment of hundreds of cases, especially in early life, that intranasal pathological conditions and deformities have exercised a marked influence upon the middle ear. Diseased lymphoid tissue (adenoid

vegetations or hyperplasia of Luschka's tonsil); malformations and hypertrophies of the inferior turbinate bone; cystic enlargement of the middle turbinate bone, with or without polypi (ethmoidal suppuration); deflection of the cartilaginous and bony septum, and chronic atrophic rhinitis all predispose to chronic catarrhal otitis media. In children with extensive lymphoid (adenoid) tissue in the pharyngeal vault an almost constant state of middle-ear inflammation is maintained, as may be observed from the congested appearance of their drum membranes. Hence, as a preliminary to any direct treatment of the ear all pathological conditions in the nose and nasopharynx must be corrected, and no intratympanic treatment may be considered as effective and thorough until the nose and nasopharynx shall have been rendered comparatively healthy.

Of the methods employed for the restoration of normal conditions in the Eustachian tube, we briefly refer to the following: Those already described relating to the restoration of normal conditions in the nose and nasopharynx. In the simpler forms of Eustachian catarrh intranasal treatment alone will suffice to effect a cure.

When the disease has been long continued or of sufficient severity to result in infiltration, with thickening of the membranous lining and consequent diminishing of the calibre of the tube, much may be accomplished either by simple inflation, the use of the catheter, or the introduction through the catheter of vaporized medication or superheated air.

These tend to promote absorption of exudate and to maintain a healthy state of the mucous membrane. Of these methods catheterization with sufficient persistency, or catheterization plus the introduction of medicated vapors, remain the two most effective methods of procedure. Inflation by means of the Politzer bag is usually less effective than catheterization, and is attended with more or less danger of over-inflation, inasmuch as the method is less controllable than when the catheter is employed.

The employment of medicated vapors, notably the combination of camphor, menthol and iodin, equal parts, by means of the Dench vaporizer (Fig. 24), is of considerable efficiency, and, while it must be admitted that but little of the remedy actually reaches the surfaces of the tube, yet sufficient is introduced to exert considerable influence upon its mucous lining. The technique of catheterization is described in Chapter II. Air-douche therapy is described in Chapter VIII.

The author is a strong advocate of the employment of the Eustachian bougie in all rebellious cases of tubal obstruction. It is in no wise a "cure-all," but in many cases the relief of tinnitus and increase in hearing, which follows the introduction of the bougie, are gratifying. The tinnitus may never recur and some degree of the increase in hearing may be permanently maintained. Should either the tinnitus or deafness recur after a few weeks or months, relief may again be effected by means of a reintroduction of the bougie. Among the author's patients are those who appear at

regular intervals of from one to six months "to be bougied," claiming to receive much benefit from the procedure. With rare exceptions the whalebone bougie fulfills all the requirements.

The electric bougie advocated by Duel may be employed whenever the stricture proves impermeable to the whalebone bougie. It is a complicated procedure, requiring a galvanic current, and insulated gold bougie. The technique is difficult, and in a few instances reported portions of the distal extremity of the bougie have broken off while in the tube. Nevertheless, the electric bougie can be made to overcome strictures which are impermeable to other forms. For the technique of passing the bougie see Chapter II.

Occasionally a tube will be encountered which is impermeable, with all the attendant aggravating symptoms of extreme deafness and tinnitus. Fortunately this occurrence is rare and, in these cases, treatment is usually without avail.

Otomassage (for full description see Chapter VIII).—Otomassage is of sufficient merit in the treatment of chronic catarrhal otitis media to deserve a brief mention. It is employed to prevent adhesions within the tympanic cavity, to break down those already formed, and to relieve tinnitus. The use of the pressure-sound for the purpose of massage is painful, and of doubtful efficiency. Vibratory massage relieves tension and usually lessens the severity of tinnitus and produces a marked soothing effect upon the nerves of those who are depressed and despondent.

Whenever intratympanic adhesions exist, especially those involving the stapes on the one hand and the round window on the other, a more or less severe deafness is present. Adhesions may form in almost any locality. The membrana tympani may be found retracted and attached to the walls of the tympanic cavity; occasionally the long process of the malleus may be found adherent to the promontory—in fact, a variety of results of adhesive inflammation may be present. But little may be accomplished for the relief of adhesive inflammations. The results obtained come chiefly from intratympanic inflation, or some form of forced manipulation, such as may be secured from the use of the Siegel otoscope or electric massage. The adoption of these methods may result in considerable relief of tinnitus, with occasional cessation of the tendency to progressive deafness and sometimes slight betterment of hearing.

A number of drugs have found employment in the treatment of these cases. Among these the one which has given the most promising results is thiosinamin. Theoretically, the properties of this drug make it an ideal one to influence the absorption of new connective tissue. Practically, however, we have no exact evidence of its usefulness. One can use it in combination with inflations, or separately. It is generally given hypodermatically in doses of gr. $\frac{1}{10}$ to $\frac{1}{5}$. Fibrolysin has lately been recommended for the same purpose by E. Urbantschitch.

Finally, in desperate cases, operative measures are occasionally resorted to in order to relieve the adhesions and improve the

hearing. These operative measures consist in making a flap from the accessible drum membrane, and, through the opening thus made, explore the intratympanic space. The adhesive bands are then severed.

The incision is usually made with a small bistoury, and the adhesions are severed with an angled knife, introduced through the first incision.

Occasionally, it is necessary to cut the tendon of the tensor tympanic muscle. The drum being incised, an angled knife is introduced so that its edge impinges upon the muscle tendon, the blade being pushed along the back of the malleus handle. A slight pressure severs the muscle. The tensor tympani is reachable from either in front or behind the malleus handle.

The stapedius muscle is sometimes also cut. Although this operation was formerly performed, it has now fallen into disuse because no good effects are obtained.

Complete ossiculectomy (see Chapter XXI), performed to sever adhesions and improve hearing in this class of cases, has never given good results.

CHAPTER XVIII.

DISEASES OF THE MIDDLE EAR.

(*Continued.*)

ACUTE INFLAMMATION OF THE MIDDLE EAR AND MASTOID PROCESS.

(Acute Purulent Otitis Media.)

Introductory.—Acute inflammation of the middle-ear spaces is characterized by a bacterial invasion of these spaces, resulting in the production of a purulent exudate from the mucosa of the tympanic cavity. The outpour of exudate gradually accumulates until it completely fills the tympanum, thereby causing a swelling of the lining mucosa of the entire cavity and Eustachian tube. This, in turn, finally occludes the Eustachian tube, bulging of the drumhead ensues, and later, if not artificially relieved by a paracentesis, spontaneous rupture of the drumhead takes place. If the disease progresses it spreads by contiguity through the aditus into the mastoid antrum, and finally involves the mastoid cells, a complication which is termed *acute mastoiditis.* Various complications characterize the advanced stages if the disease remains unrelieved, the details of which we shall describe later.

Pathology.—The early stages of acute purulent otitis media are not sharply definable clinically from some of the catarrhal forms.

The inflammatory involvement of the Eustachian tube results in an obliteration of its lumen. The determining factor of the disease is the invasion of micro-organisms. These grow in the mucoserous fluid which obtains in the tympanic cavity, resulting in the formation of a purulent exudate.

The lining mucosa of the tympanic cavity meanwhile becomes swollen and thickened, and the mucous lining of the membrana tympani becomes likewise involved. Hence its red and thickened appearance at this stage. As the purulent exudate increases in amount, it reaches the upper chambers of the tympanic cavity and the aditus becomes affected. Following the line of least resistance the exudate flows into the mastoid antrum, which gradually becomes filled and the neighboring cells gradually involved until, in a case which progresses to its ultimate end, all the cells become infected. As the pus in the cells increases in amount it exerts undue pressure upon the mucosa and the intracellular walls, and their nutrient blood-supply is finally shut off with the inevitable result that these walls become necrosed, coalescing one cell into another, until in the advanced stages one often finds nearly the entire mastoid process converted into one large bony pus cavity, with areas of the inner table of the mastoid process broken through and the underlying vital structures exposed.

One is often surprised that the accumulation of pus under pressure within the mastoid cells does not more frequently break through the thin roof of the antrum. It often does break through, but more commonly it invades the entire mastoid process first. Explanation for this on a pathological basis is found in the excellent blood-supply of the tegmen tympani, tegmen antri, and tegmen cellulæ through the blood-vessels of the dura mater, which acts to these structures as their periosteal coating.

Bacteriology.—It is now generally conceded that the micro-organisms almost invariably find their way into the tympanic spaces through the Eustachian tube. The character of the invading organism and its virulence are potent factors in determining the clinical picture; this together with the variations in degree of the resisting power of individuals explains the difference in the course and termination of the attacks. In one case resolution will follow incision and drainage of the middle ear, while in a second case cure is not effected until the mastoid process is opened.

Secondary infections occasionally enter the tympanic cavity through a perforation in the drumhead, and many observers contend that a tuberculous invasion may also enter the tympanic cavity by way of the lymph channels and the blood-streams.

The bacteriology of the ear discharges forms a part of the chapter on General Etiology, page 45.

Etiology.—The causes of purulent middle-ear affections are grouped as predisposing and inciting.

The predisposing factors to middle-ear diseases are to be sought for among those irritants in the upper respiratory tract which interfere with the physiological play of the cilia on the cells lining the walls of the Eustachian tube. Among such, rhinopharyngeal abnormalities are prominent, as is also hereditary taint, and the presence of general debilitating diseases, as, for instance, diabetes.

The inciting causes, heretofore mentioned under the pathology, are found in the invasions of the middle-ear cavities by large numbers of micro-organisms which develop their characteristic lesions over various areas of the intratympanic mucosa. The source of the invading micro-organisms is the infections commonly found in the nose and nasopharynx, which, in turn, are usually the result of specific infections, such as the exanthemata, epidemic influenza, etc.

Out of 6000 cases of scarlet fever, measles and diphtheria, treated at the Willard Parker Hospital, collated by Duel, 20 per cent. of the scarlatina cases, 10 per cent. of the diphtheria cases, and about 5 per cent. of the measles cases developed purulent otitis media. There were 26 mastoid cases, nearly all of which occurred in cases with combined infection. In children under five years postauricular swelling was common, which he believed to be the result of the escape of pus through the Rivinian fissure.

Incidentally, various other factors tend to influence and aggravate the purulent process in the middle ear, such as bad habits, excessive alcohol, neuroses, etc.

Finally, trauma is in etiological relationship to acute purulent middle-ear disease, when either by direct violence or by indirect violence the drum is ruptured, and the middle-ear spaces are thus laid open to bacterial invasion.

In mentioning some of these factors more in detail, we note that trauma often results in more or less severe inflammation of the tympanic cavity, and, when no efforts are made to prevent infection, the inflammation eventuates in purulency. Traumatism from bullets or other penetrating objects, by destroying smaller or greater areas of the middle ear not only directly destroy the parts, but, by subsequent infection, cause middle-ear suppuration.

In children carious teeth may indirectly become a source of middle-ear infection, and unless corrected these may continuously breed micro-organisms which constantly invade the tympanic cavity.

Another factor of etiological moment in the causation of middle-ear inflammations is commonly observed during the summer season, the attack following a sea bath, or a swim in fresh water.

Here evidently the water, contaminated with bacteria from the nasopharynx, is forced into the tympanic cavity through the Eustachian tube because of faulty breathing while swimming or diving or by forcibly blowing the nose, and once having gained entrance it acts as a foreign-body irritant. Later on the bacterial invasion evokes a purulent exudate. In newborn infants the same thing occurs, when, during parturition, amniotic fluid is forced through the short, straight, open Eustachian tube. This form of otitis has been termed *otitis media neonatorum.*

The presence of adenoid tissue in the vault of the pharynx, hypertrophied tonsils, intranasal obstruction of various types, furnish examples of respiratory lesions which indirectly induce middle-ear infection. Obstructed nasal breathing from whatever cause is injurious to the middle ear, while diseased lymphoid tissue in the vault, or even in the tonsils, must retard intratympanic aëration. The masses of lymphoid tissue, however, on account of their peculiar structure, become seriously menacing during the course of acute infections of the mucosa of the nose and nasopharynx, inasmuch as they both retain infectious material, and by becoming swollen and obstructive they facilitate the entrance of infection in the Eustachian tube. It may be stated definitely that diseased lymphoid tissue in the pharyngeal vault is a most prolific indirect cause of purulent middle-ear disease. The writer has never seen a case of recurrent middle-ear suppuration, especially in childhood, unaccompanied by a greater or lesser development of lymphoid tissue in the vault of the pharynx.

Hypertrophied and diseased inferior turbinals, by obstructing the chief channel for the entrance of air, often show a marked tendency to aggravate middle-ear inflammations. Cystic and polypoid middle turbinals tend also to produce the same result. A more or less completely deflected septum, interfering as it does

with nasal respiration, likewise aggravates the symptoms of middle-ear inflammations.

Tumors, whether malignant or otherwise, acting directly as a result of obstruction or indirectly by lowering the vitality, must also be considered.

The vascular and lymphatic systems with which the mechanism of the middle ear is so liberally supplied, necessary as they are to its proper maintenance, as well as for the proper control of its functions, and working so perfectly as they do under proper conditions of health, may become a serious menace when influenced by diseased conditions either local or general. That infection reaches the middle ear through these channels has been definitely proven, especially as regards the tuberculous variety.

Changes also in the tissues which enter into the make-up of the tympanic cavity are undoubtedly directly influenced by derangements in the character and normal functions of the blood-vessels and lymphatics.

Systemic diseases, such as diabetes, gout and rheumatism, and those resulting from the improper use of medications, intoxicants or narcotics, by acting upon the vascular system in general, also affect, to a marked degree, the tissues of the tympanic cavity.

All infectious diseases, from their very nature and because of the fact that the membranes of the upper respiratory passages are thereby involved, possess a marked tendency to involve the tympanic cavity. The routes by which these infections travel have already been described. Measles, diphtheria, typhoid, scarlet fever, parotiditis, grippe, and other forms of infectious colds and inflammations, furnish a supply of their peculiar pathogenic micro-organisms, and the middle ear is never free from danger while such infections exist.

Of the more chronic forms of infection those involving the accessory sinuses of the nose are quite prolific in the causation of purulent otitis media. The author has repeatedly observed cases of violent purulent otitis media that could be directly traced to the forced introduction of the discharges from the accessory sinuses through the Eustachian tube into the tympanic cavity.

Tuberculosis and syphilis, on account of their frequent occurrence, warrant special mention. The manifestations of tuberculosis are always those of ulceration and destruction of the membrana tympani and also of the intratympanic structures.

The infection may, and probably does, enter the cavity through the Eustachian tube with comparative frequency, but it may also extend from tuberculous glands or other forms of tuberculous infection directly through the lymphatics.

The question as to the route by which tuberculosis reaches the middle ear and mastoid has aroused endless discussion; various observers, even when basing their opinions upon autopsy findings, hold diametrically opposite views. At the present state of our knowledge we may say that the middle ear becomes involved not only by the Eustachian-tube route and the lymphatic channels, but

also directly through the blood-vessels. The reader is referred to Part II of this work (The Influence of General Diseases upon the Ear, Nose and Throat) for details and statistics relating to infection of the middle ear from the various general infectious diseases.

Manifestations of syphilis in the tympanic cavity are extremely rare, being found only when a broken-down gumma appears in this locality.

Symptomatology and Course.—The onset of an attack of acute purulent otitis media is usually sudden, following a "cold," an attack of grippe, or during the later stages of one of the exanthemata. There is usually a prodromal stage lasting a few hours, during which the ears feel "full," the patient's voice sounds unduly loud (autophony) and he thinks there is some obstruction in the external ear. The most significant symptom is the excruciating pain, which persists without cessation until relieved by rupture of the drum membrane. The onset of pain is simultaneous with the filling of the tympanic cavity with pus. In children the onset is often marked by chill and a considerable rise in temperature. Among those just having passed through an attack of measles or scarlet fever, a rise in temperature alone, if unaccounted for otherwise, is gravely suggestive of ear involvement. Among adults fever is not a usual sign. Convulsions are common among young children—in fact, symptoms which would seem to indicate meningeal irritation are commonly observed in very young infants, all of which subside as soon as the drumhead is incised. Furthermore, in these young patients, among the early stages, a diarrhea may develop which is prone to mislead the attending physician. This symptom must be borne in mind by those in attendance upon infants and young children.

Pain.—The earache soon becomes intense. It is throbbing, lancinating, boring and not intermittent in character, although often found to be less in the morning than at night. With the advent of the otorrhea, through either spontaneous rupture of the drum or incision by the surgeon, the pain rapidly ceases. Infants are unable to give expression to the suffering except by crying, which often amounts to agonizing shrieks. They are restless, roll the head with a boring motion, and seem to rest best when held in the lap with the affected ear downward. It sometimes happens that young children develop virulent otitis media with but little pain, the pressure being sufficiently relieved by drainage through the Eustachian tube. Even after the otorrhea is established, the pain recurs if the flow is interrupted from any cause, such as a blocking of the perforation.

Certain cases of acute purulent otitis media run their entire course without pain. These are first and foremost the tuberculous and syphilitic forms.

Pain is also absent in cases where from the very beginning for some cause a perforation is present in the drum. Since the pain is the result of pressure by the pus in the tympanic cavity, no pain is found in these cases because the pus is never under pressure.

Examples of this type occur when an acute middle-ear inflammation takes place in an adult, who in early life had suffered from a chronic otorrhea with destruction of part of the drum membrane. The cessation of pain also marks the period in the infant when the meningeal irritative symptoms are wont to stop. That is with the establishment of the otorrhea.

Fever.—The temperature deserves some special comment. In many cases, especially among adults, it is entirely absent. In children and young adults it lasts some days, ranging from 100° to 105° before the advent of the otorrhea, and often a few days thereafter. In these cases, where the temperature persists after the advent of the otorrhea, the question as to whether or not the disease has spread beyond the tympanic cavity becomes one for serious consideration. If the general status of the patient remains good, if the sensorium remains clear, and if the pain remains slight, and no tenderness appears behind the ear, there is no cause for alarm, nor is operative interference indicated. In children one should also carefully watch for glandular swelling, as a swelling at the angle of the jaw may mean a mastoiditis.

It requires a certain time for the body economy to establish its lines of resistance to the invasion, and until this is established the temperature is likely to continue.

Finally, the fever may continue because the original lesion, the rhinitis, pharyngitis, bronchitis, pneumonia (especially in children) or typhoid may not yet have subsided.

The Otorrhea.—The otorrhea begins usually from one to three days after the advent of the disease. In children the rupture of the drum may be delayed because there is an outflow of pus through the Eustachian tube. In rare cases the otorrhea begins a few hours after the commencement of the disease. On the one hand we may be dealing with an abnormally thin drum, or with a thickened drum from previous catarrhal attacks.

At the commencement the otorrhea is mostly serous in character, or serosanguineous; generally it is profuse. Later it becomes thicker and more purulent. It contains the exciting microorganisms in abundance.

As the disease progresses, if toward resolution, under appropriate treatment, it gradually subsides and in from three days to five or six weeks it disappears.

In cases which resolve, with the cessation of the discharge, a cicatrization of the drumhead supervenes. The membrana tympani becomes paler and thinner; meanwhile the outline of the malleus becomes visible. The hearing gradually returns toward the normal. The accompanying tinnitus aurium, under treatment by inflation, gradually subsides and the hearing becomes normal. In cases which do not go on to resolution the infection extends, with involvement of the structure of the mastoid process, following which, if unrelieved, intracranial, labyrinthine complications become imminent, or perforation of the mastoid cortex may supervene. A considerable

proportion of cases of this type terminate in the chronic form of the disease with necrosis, loss of hearing and cholesteatoma.

Lastly, involvement of the facial and abducens nerves (Gradenigo, 1904) may take place, or brain lesions may end the patient's life.

Diagnosis.—Otalgia with otorrhea may arise from either otitis media or otitis externa. If the external auditory canal is not swollen and not painful to pressure, then the supposition exists that the patient has purulent middle-ear disease. If the external ear is filled with pus which pulsates, the diagnosis of an acute middle-ear purulency can be made, even if no otoscopic examination is possible. An otoscopic examination is not always possible in the very young. Severe pain, associated with intense redness and bulging of the membrana tympani are the characteristic early symptoms.

Fig. 117. — Inflammatory engorgement of the blood-vessels of the membrana tympani.



Fig. 118.—Bulging of the drum membrane.

Otoscopic Examination.—Otoscopic examination will show a bluish red (Fig. 117) or very red swollen membrana tympani during the first stage, preceded by a short stage during which the blood-vessels are intensely engorged. Bulging, in whole or in part, soon appears (Fig. 118), with absence of light reflex and other normal landmarks (Figs. 118 and 119; also Fig. 120). If already perforated one sees a small puncture, irregular in outline (Fig. 121), and the drumhead covered with desquamated epithelium so that its outlines are hardly recognizable.

In severe cases the onset of the disease is characterized by the appearance of large blebs (hemorrhagic and serous) in the layers of the drum membrane (Fig. 122).

Among children the slanting of the drumhead toward the horizontal renders the exact determination of the conditions present harder, and in addition the surgeon is occasionally hampered in his examination by narrowing of the canal lumen.

When seen later in the course of the disease, there is distinct bulging in one or more segments of the drumhead (Fig. 123), and often a yellowish tinge to the drum due to the light shining on the pus behind the drum. Mastoiditis presents its own peculiar symptomatology, to which we will refer below under appropriate headings.

Prognosis.—Under favorable conditions in patients of otherwise good general health, when managed in accordance with approved modern methods which meet all the indications for treatment, the prognosis is good, both for cure of the otorrhea and a full recovery of hearing. The outcome is influenced unfavorably whenever serious complications develop, and especially so in strumous, cachectic, tuberculous or syphilitic patients; when some other grave constitutional disease is present; in children who are victims of diseased lymphoid tissue in the pharyngeal vault, and when the treatment has been unskillful, uncleanly or faulty in important particulars.

Repeated attacks of acute purulent otitis media are considered unfavorable, especially in their effect upon hearing.

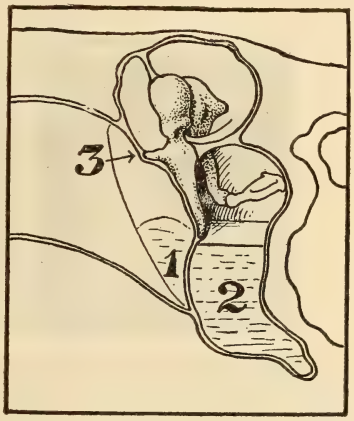

Fig. 119.—Lateral view of the tympanum, with key plate, partly schematic, showing bulging of the drumhead (1), pus in the tympanum (2), and absence of the usual prominence of the processus brevis (3).

Treatment.—At the commencement of an attack of purulent otitis media, the patient should be placed in bed in a well-ventilated room of even temperature.

These patients usually have an elevation of temperature; furthermore, there is an infectious process going on in the tympanic cavity, the progress of which is favorably influenced by rest and freedom from exertion, and the patient in bed is less apt to take cold, thus avoiding much of the danger of serious complications.

Rest in bed, therefore, is of supreme importance, the length of time varying from two to three days to two weeks until the acute inflammatory symptoms have passed away, the temperature becomes normal, and the danger of complications has passed.

A brisk cathartic at this time, preferably calomel, materially relieves congestion and produces a favorable effect upon the inflammatory process.

A variety of remedies have been advocated for the relief of

pain during the early stages before rupture or incision of the drum membrane has taken place. Of these but two are worthy of mention, while many are productive of considerable harm. There is no better local method for relief of pain than by douching the external auditory canal with hot water (Chapter VIII, page 86). For this purpose a douche bag filled with hot sterile water or a bichlorid of mercury solution 1:4000 or 1:5000 is used. The bichlorid of mercury accomplishes no other good than to sterilize a field which may have to be operated on later.

The second measure recommended for relief of pain is opium. Under favorable conditions, in older children and adults, moderate doses of opiates often aid in tiding the patient over the period of excruciating pain which often precedes the time when sufficient indications for paracentesis appear. The instillation of oily prepa-

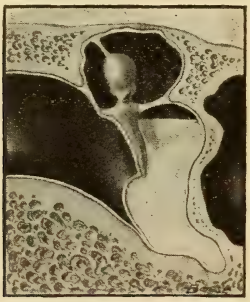

Fig. 120.—Lateral view of the tympanum, with key plate, partly schematic, showing (1) bulging of drumhead. The tympanum is nearly filled with pus (2), the long process of the malleus (3) is forced outward with the bulging drum and the usual prominence of the short process (4) is partially obliterated.

rations into the external canal is invariably contraindicated, inasmuch as the oily mass remains in the canal and becomes intermingled with the exfoliations of epithelium from the canal walls, thus forming a rancid mass which is most difficult to remove.

Furthermore, this condition adds to the difficulties experienced in sterilizing the external meatus as a preliminary to incision of the drum membrane. Many authors have recommended the employment of leeches during the preliminary stage of purulent otitis media, believing that the local bloodletting tends to abort the infective inflammatory process. The author does not hold this view, and deprecates the employment of the leech under any circumstances.

In cases wherein there is extensive inflammatory infiltration in the early stages some relief from pain is obtained by local bloodletting, either by incisions in the canal wall or by the employment of artificial leeches applied about the insertion of the auricle.

Incision of the Drum Membrane (Paracentesis).—The ex-

udative stage of the disease furnishes the indication for surgical interference in the form of an incision of the drum membrane. If no perforation is present, or if too small a perforation has taken place spontaneously, incision of the drum membrane becomes the first therapeutic indication. This little procedure, since its introduction into otology by Schwartze in 1867, has become one of the most useful surgical measures employed in otology. The technique of this operation is fully described in Chapter VII.

The author's views as to the indications for incision of the drum membrane are as follows:—

Paracentesis is employed principally for the purpose of evacuating the purulent contents of the tympanum, the ultimate object being to relieve pain, limit the extent of the infection, shorten the course of the disease, and prevent complications.

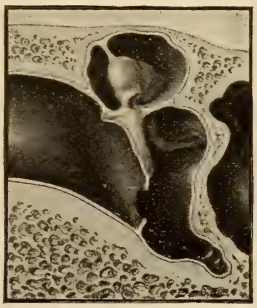

Fig. 121.—Lateral view of the tympanum, partly schematic, showing perforation in the lower segment of the drum membrane.

Paracentesis of the drum membrane is indicated in acute purulent otitis media when attended with intense redness and bulging of the drum membrane, in whole or in part. With these objective symptoms there are coexisting pain and fever, the latter being more marked in young children. The syndrome above described, viz., bulging of the drum membrane—intense aural pain and fever, is invariably of sufficient import to warrant this operation. In infants bulging is a later manifestation than in adults.

Occasionally the purulent process may have continued for some days without rupture, especially in infants, in which event the intense redness gradually assumes a yellowish color, due to attenuation of the membrane and the accumulation of purulent exudate in the tympanic cavity. An early paracentesis, when performed under strict aseptic precautions, is preferable to a delayed spontaneous rupture. It is a safe rule to open the drum membrane as soon as the diagnosis of purulent tympanitis becomes positive.

A clean-cut incision in the drum membrane, and by this is not meant a puncture, immediately relieves the pressure, establishes drainage, and the subsequent healing of the wound takes place with but little damage and no scar tissue. Nature's

opening is usually a small jagged hole, the borders of which are more or less necrosed, and as healing takes place it is prone to result in scars, and considerable deposits of new connective tissue in the drum membrane.

Paracentesis is also indicated for enlarging perforations which already exist, providing they are too small or are unfavorably located for purposes of drainage. A pinhole perforation in the presence of an extensive intratympanic purulent process affords insufficient drainage. These small perforations are usually accompanied by a sensation of throbbing or pain in the ear or mastoid region. They do not entirely relieve the bulging of the membrane, especially at the site of the opening. In enlarging the pinhole perforation it is often necessary to cut both upward and down-

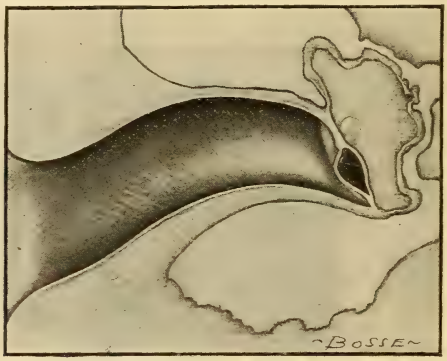

Fig. 122.—Lateral view of the tympanic cavity and drum membrane, partly schematic, showing extravasation of exudate between the layers of the membrana tympani.

ward, in order to establish drainage both of the tympanic and attic region.

The operation releases pent-up pus from the tympanic cavity, and thereby retards the tendency to bacterial invasion of the contiguous structures, establishes free drainage of inflammatory exudate, shortens the course of the disease, and lessens the danger of mastoid, intracranial and labyrinthine complications. These results come chiefly from the rapid removal of the inflammatory products from the tympanic cavity, which otherwise might be forced under pressure through the aditus into the mastoid antrum.

Relating more specifically to the disease under consideration it may be observed that any point of marked bulging of the drum membrane is the area through which the incision should pass. If the drum is generally bulging the posterior half of the drum is selected as the site of election.

The incision is curved, paralleling the posterior periphery of the drumhead (Fig. 55). This severs both the radiating and the circular fibres in the drum and tends to cause the incised wound to gap and thus favors drainage of the tympanic cavity. Care

should be exercised that the knifeblade does not impinge upon the ossicles, and the entire procedure must be characterized by gentleness. Experience has shown that just in these cases the drumhead is often very thick, and therefore the incision must be made long enough to cause a gaping wound. In children the horizontal slant of the drum may cause the inexperienced to either miss it altogether, or only make a slight incision because the lower parts (deeper-lying parts) are missed by the knife, therefore the blade must be introduced sufficiently deep to incise the entire extent.

After-treatment.—Immediately after the incision a strong flow of exudate ensues, mingled freely with blood. The ear is now cleansed and a gauze drain placed into position for a few hours. It is well to allow the patient some rest immediately following paracentesis, because usually they have had severe pain and nervous strain for some time previously. Then later, after some hours, the regular treatment of the otitis begins. Sometimes it becomes

Fig. 123.—Marked bulging of the posterosuperior quadrant of the drum membrane.

necessary, because of recurrence of the symptoms and cessation of the discharge, to repeat the paracentesis. This should not be delayed when the symptoms show it to be indicated. The indications to be fulfilled in the subsequent local treatment are: (1) cleanliness; (2) free drainage. Cleanliness is best maintained by douching the external auditory canal with physiological salt solution or solution of bichlorid of mercury, 1 : 3000. The quantity of fluid (which should be heated to about 110° F.) to be used should be from 1 to 2 quarts, and the treatment should be repeated every two hours. (For detailed information in regard to douching see Chapter VIII, page 86.)

In order to guard against secondary infection efforts are directed to prevent the entrance of infection from the external meatus. This may be accomplished by loosely placing in the concha and external orifice of the canal a strip of sterile gauze, to be removed as soon as it becomes moist from pus and then replaced with a fresh piece. In young children, or whenever it is found difficult to maintain perfect cleanliness by this means, the whole ear should be protected by bandaging. Thus the requirements above mentioned are fulfilled. At least once in each twenty-four hours a careful ocular examination of the drum should be

made to ascertain the size and character of the perforation, so as to enlarge it whenever it becomes too small to maintain drainage, likewise the mastoid process should be examined to discover evidences of mastoiditis. The condition of Shrapnell's membrane and the posterior superior wall of the external auditory canal must always be carefully noted. At each visit firm pressure is made over the mastoid antrum, tip and posterior angle, and the condition of the nose and throat ascertained. Unless specially trained nurses are in attendance to carry out the local therapeutic measures, careful instruction should be given to those in charge, with an actual demonstration of the treatment administered at each daily visit, in order to insure the proper care of the patient.

Inasmuch as this affection is rarely unaccompanied by nasopharyngeal infection, it becomes necessary to instigate proper intranasal treatment at the very onset, in order to remove accumulations of infected secretion and relieve the attendant inflammation of the mucosa. Non-irritating sprays, both aqueous and oily, aid in bringing about the required result. Such treatment should consist of non-irritating alkaline sprays for cleansing and medicated oily sprays or mildly astringent applications to the mucosa, employed with sufficient frequency to maintain the utmost cleanliness and to relieve inflammation. Later on measures to promote absorption of inflammatory exudate and to prevent the formation of adhesions in the tympanic cavity become necessary. The internal administration of such remedies as the iodids in various forms, intranasal cleanliness, gargarisms, and occasionally a diaphoretic will be found to aid in this process.

In uncomplicated cases the discharge gradually subsides and disappears altogether in from one or two days to four weeks.

Careful hearing tests are made and recorded from time to time following an acute otitis media until the record shows practically perfect hearing, without tinnitus or evidences of adhesions. Recovery is never considered complete until the absence of exudate in the Eustachian tube has been clearly demonstrated by aural auscultation.

During the later stages, after the intranasal infection has subsided sufficiently to permit it, beneficial results are occasionally obtained by catheterization, thus blowing the pus into the external auditory canal.

In every case immediately after paracentesis a smear should be prepared for laboratory examination, always bearing in mind that a culture examination is preferable. Tuberculosis, diabetes, or syphilis as types represent conditions which seriously interfere with the general treatment of purulent otitis media, and the general examination of the patient at the first visit should elicit information on these points. In several instances the author has seen an apparently uncontrollable acute purulent otitis media rapidly subside as the result of proper dieting of a diabetic patient.

After the acute symptoms have subsided, especially when the inflammatory exudate has been extensive, it becomes necessary to

maintain the mobility of the drum and ossicles by means of various forms of massage.

The complications are to be met as individual conditions. Pus retention must be relieved, furuncles incised; eczematous excoriations must be treated locally, periostitis subjected to incision or relieved by local measures. Glandular swellings require the proper internal medication and application of soothing ointments—in other words, each complication as it arises must be treated as an individual lesion, and the treatment given must include the treatment of the otitis at the same time.

OTITIS MEDIA NEONATORUM.

This is a separate and distinct class of acute purulent otitis media occurring in the newborn child, the suppurative process being due to decomposing amniotic fluid in which bacteria find growth in the tympanic cavity. The disease is practically limited to its occurrence in badly nourished and marasmic infants. While it presents the same etiological factors as purulent otitis media in adults, it has, in addition, to contend with the extreme susceptibility of the infantile mucosa to the influences of infection. The type of infection is usually pneumococcus. The general symptoms of fever and emaciation frequently predominate over the local ear symptoms. In fact, extreme pain is rarely present. The temperature, however, is considerable. The exudate in the tympanic cavity, usually of a purulent character, shows no tendency to perforate the membrana tympani; it should, therefore, be permitted to escape by performing paracentesis even in the absence of violent ear symptoms, since the beneficial effects upon the digestion and general nutrition become most marked. Whenever a newborn child presents the general symptoms of intestinal disturbance, catarrhal or pulmonary affections or malnutrition, the ear should be carefully examined, even in the absence of any symptoms pointing definitely to this organ.

The otitis media of the newborn infant is somewhat characteristic, and we therefore include it here as it is a type of acute purulent otitis media.

Acute purulent otitis media in very young children may be complicated by the extension of the inflammatory agents from the tympanic cavity by way of the still open tympanomastoid fissure, resulting in mastoid abscess. The disease, while usually simple and amenable to treatment, commonly results in extensive necrotic mastoiditis, requiring operative interference. It may be stated, however, that usually otitis media neonatorum purulenta is a mild inflammatory process.

CHAPTER XIX.

DISEASES OF THE MIDDLE EAR.
(Continued.)

ACUTE DISEASES OF THE MASTOID PROCESS.

Periostitis of the Mastoid Process.

By periostitis is meant an inflammation of the periosteal covering of the mastoid process. It may be either primary or secondary. A periostitis localized to the posterior osseous canal wall, which is often observed, is in reality a subdivision of the secondary type of the disease.

Primary Acute Periostitis of the Mastoid Process.

Primary acute periostitis is a rare disease, and is more common in adults than in children. It is an inflammation which involves the periosteum of the mastoid process, and which varies in degree from that of a simple type to that of purulent periostitis.

Symptoms.—The disease is characterized by a circumscribed inflamed area of periosteum of solid consistency, without involvement of the membrana tympani or external canal. As the disease progresses the soft tissues overlying the diseased area become rapidly tumefied and exhibit marked superficial redness. When located near the postauricular attachment the pinna is made to project unduly. Pain is severe and is accompanied by marked superficial tenderness upon pressure over the surface of the swelling. When severe, the affection induces considerable headache, slight fever and stiffness of the muscles upon the affected side.

Primary periostitis often runs its course to resolution without suppuration; occasionally an abscess formation results, but the disease rarely terminates in fistulous tracts and caries of the mastoid cortex. The latter complications occur only as a result of severe traumatism or some constitutional disease like syphilis or tuberculosis.

Diagnosis.—It becomes necessary to eliminate primary disease of the mastoid cells, acute purulent otitis media, edematous dermatitis, glandular swellings and deep-seated furuncles in the posterior canal wall in order to establish a diagnosis of acute primary periostitis of the mastoid.

Prognosis.—The prognosis is favorable in uncomplicated cases.

Secondary Periostitis of the Mastoid Process.

Etiology.—In secondary periostitis the primary focus of inflammation is located either in the periosteum of the external auditory canal, with extension to that portion of the periosteum covering

the mastoid, extension by contiguity from an acute or chronic suppuration of the middle ear, or the mastoid cortex breaks down as a result of purulent mastoiditis. In nearly every case of furuncle involving the posterior wall of the external auditory canal there is more or less involvement of the periosteum covering the mastoid process. The author has observed many such cases accompanied by marked displacement of the pinna as a result of the tumefaction

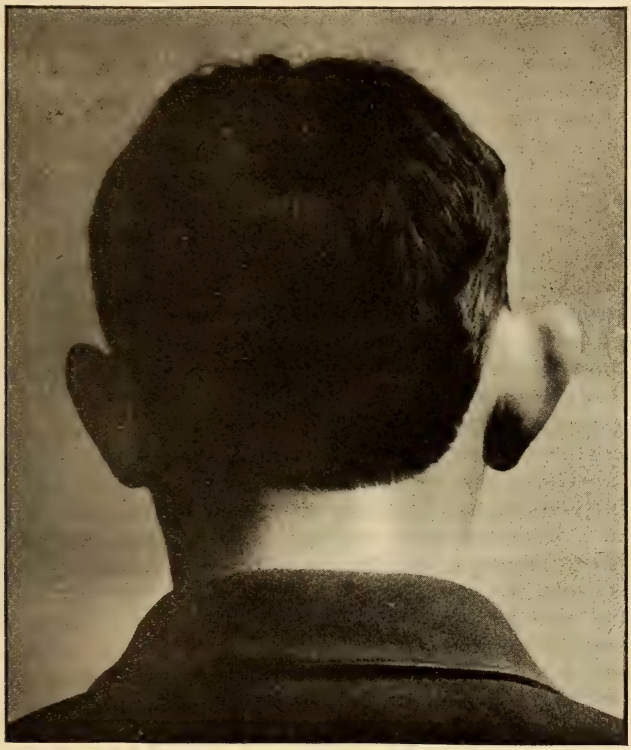

Fig. 124.—External periostitis of the mastoid process due to furunculosis of the external auditory meatus and simulating advanced acute mastoiditis.

and inflammation of the tissue. In both cases the external appearance seems to indicate advanced mastoiditis. One such case was referred by the family physician with a request that a mastoid operation be performed (Fig. 124). A free incision of a large furuncle within the canal in this case resulted in a cure, inasmuch as the mastoid cells were not diseased. When secondary periostitis is accompanied by acute or chronic purulent otitis, the periosteal involvement takes place by extension, from the tympanic cavity, or it results from the breaking down of the cortex, following involvement of the mastoid cells.

Secondary periosteal suppuration resulting from purulent mastoiditis is more common in children than in adults, because the cortex is less dense and the anatomical sutures, being more or less open, permit pus from the deeper parts to reach the surface more easily than in the fully ossified sutures of the adult.

Course.—Since secondary periostitis of the mastoid process invariably has a purulent origin it usually terminates in abscess. As a rule, the periosteal abscess either communicates directly or indirectly with a primary abscess located elsewhere.

Secondary periostitis of the covering of the posterior bony external auditory canal wall may either follow acute or chronic purulent otitis media. In children, because the pus from the middle ear often finds vent externally through the petromastoid suture, it irritates and inflames the periosteum covering the bone in the auditory canal. Furthermore, the latter type of secondary periostitis may result from deep-seated furuncle or from injury. The later appearance of exostosis at the site of the periosteal inflammation is an unpleasant sequela.

Diagnosis.—The diagnosis of secondary periostitis of the mastoid process must be determined by the presence of a postauricular fluctuating swelling occurring in conjunction with the purulent mastoiditis, purulent otitis media, or furunculosis of the external auditory meatus.

Treatment.—During the early stage of primary acute periostitis of the mastoid process the treatment is mainly antiphlogistic. The Leiter coil was formerly employed in these cases for from twenty-four to thirty-six hours, but has now been discarded. While it relieves pain, it is questionable whether it actually retards the purulent process. Dry heat, preferably the hot-water bottle, applied to the surface is soothing, and its employment is permissible, especially during the pus stage. Local depletion by blood-letting is also advised during the early stage. Two or three drams of blood withdrawn by means of an artificial leech applied near the border of the tumefaction may materially reduce the tension and afford relief.

Whenever the inflammatory symptoms persist for three or more days and deep-seated fluctuation can be felt, the tumor should be incised freely in obedience to the laws governing all suppurative processes. Observing the usual rules as to asepsis, the incision should be of sufficient length to freely open the abscess cavity, extending through the periosteum to the bone. After evacuating the pus, all detritus or necrosed areas are to be removed by curettage, and the resulting cavity packed with sterile gauze. Since secondary periostitis arises from inflammatory or purulent disease of the auditory canal, tympanum or mastoid process, the essence of treatment lies in curing the provocative lesions.

Acute Purulent Mastoiditis.

The term mastoiditis is here employed to define an inflammatory process involving the tissues of the mastoid antrum and mastoid cells, which is induced by an invasion of pathogenic micro-organisms.

With rare exceptions the disease originates in a similar process which has primarily developed in the tympanic cavity, the extension being by contiguity through the aditus.

General Pathology.—The contiguity of the mucous membrane in the mastoid process (lining of the mastoid cells) with the mucous membrane of the middle ear—tympanic cavity (Fig. 99)—having long since been definitely established by Bezold and Politzer, it follows that the mucosa of the mastoid antrum and mastoid cells usually becomes involved to some extent in every case of middle-ear suppuration. In the majority of cases, however, the purulent invasion of the mastoid process subsides very quickly in response to drainage and as a result of final resolution of the inflammation in the tympanic cavity.[1] According to Bezold, however, in at least 9 per cent. of cases of acute purulent otitis media, the inflammatory invasion attacks some portion of the bone and tissues of the middle-ear tract, necrosis of varying degrees ensues, and thus a condition is produced which, strictly speaking, is pathologically designated as *otitis rareficans simplex.*

The periosteal covering of the bony surfaces within the mastoid process, which is composed of the mucous membrane lining the cells, becomes swollen through hyperemia and infiltration with inflammatory exudate. The infiltration of the lining mucous membrane of the cells of the mastoid process interferes with the blood-supply of the intracellular bony walls. The tissue thus loses its fatty elements, and becomes converted into inflammatory granulation tissue. The blood-supply of portions of the osseous structures having become lessened because of pressure on the vessels by the swollen tissues, bone necrosis ensues, and some absorption of the intercell-walls results. Thus from a series of small cells, lined with healthy mucous membrane, the mastoid process becomes, in a case of progressively advancing purulent mastoiditis, a bony process containing a series of larger cavities formed by the breaking down of the walls of the small cells, the inflammatory contents of which also coalesce. Eventually the progress of the disease reaches the outer (cortex) or inner (cranial) table, and, continuing, it may cause absorption at some given point. Absorption of the inner wall permits the infection to invade the middle or posterior cranial fossa, the lateral sinus or the labyrinth, depending upon the exact portion attacked. Absorption of the outer wall opens the cortex from within and the pus pours out directly underneath the periosteum. In this event we have the condition designated as *subperiosteal mastoid abscess* (Fig. 125). Often, especially in children,

[1] Boenninghaus, Lehrbuch der Ohrenheilkunde, 1908.

the inflammatory invasion advances even farther by penetrating the periosteum, from which point it either escapes by directly perforating the skin, or burrows downward into the cellular tissues of the neck.

The determining factor in the entire pathological process is the purulent exudate, which seems to become caught in the network of cells in the mastoid process, and which, because of lack of outflow, *stagnates* and spreads the infection. Boenninghaus claims to have proven that when, either through spontaneous perforation or surgical opening of the mastoid cortex, a flow of the retained pus is established, the further progress of the destruction of bone

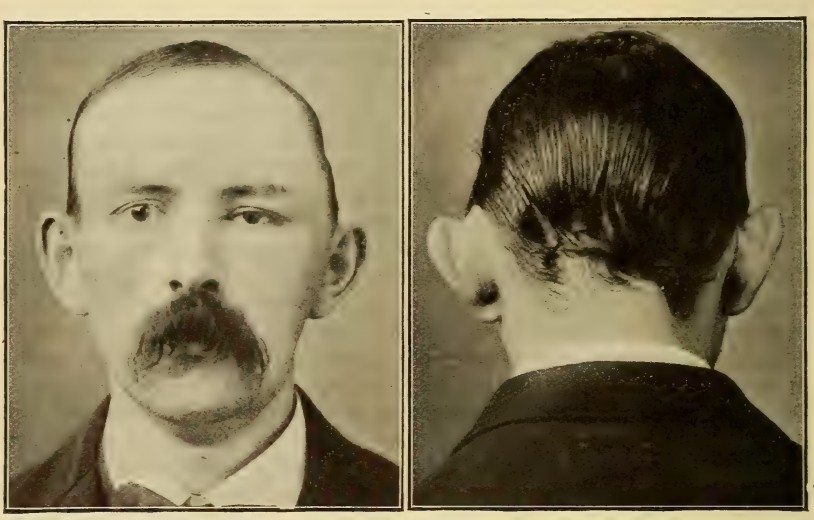

Fig. 125.—Subperiosteal mastoid abscess.

ceases, thus demonstrating that the retention under pressure of the pus is the principal cause of the destruction of bone within the mastoid process.

The pathologic lesions thus outlined have been grouped clinically under the general term *acute purulent mastoiditis.*

Etiology.—The same factors which enter into the causation of purulent otitis media may be considered as etiological to acute purulent mastoiditis. Strictly speaking, purulent mastoiditis is induced by an invasion of pathogenic micro-organisms into the mastoid antrum and cells from the tympanic cavity by the contiguous route, viz., the aditus ad antrum.

Acute purulent mastoidal inflammation sometimes develops during the course of chronic purulent otitis media, and, while the apparently acute attack may only seem an exacerbation of the existing chronic mastoiditis, the fact remains that, during the course of a chronic purulent otitis media, an acute purulent mastoiditis may occur at any time, so that chronic purulent otitis media must be

considered as being in etiological relationship to acute purulent mastoiditis.

Richardson and others have shown that the mastoid process may become involved in an osteomyelitis of the temporal bone. Occasionally a purulent process which has primarily involved the periosteum of the posterior external canal wall extends directly through its bony wall into the mastoid cells. This occurs in young children more often than in adults.

Failure to establish timely and efficient drainage of pus through the drum membrane, either by spontaneous rupture or through incision in cases of acute purulent otitis media, is a common determining factor in the causation of acute mastoiditis. Infectious diseases, notably the exanthemata, influenza, typhoid fever and pneumonia, are provocative of middle-ear suppuration and mastoiditis, the invasion being partly due to the distinctive types of pathogenic organisms which characterize these diseases, and partly also to the greatly lowered vitality of the individual who has been subjected to prolonged suffering.

Lowered vitality from any cause, whether from general systemic diseases, such as diabetes, Bright's disease, anemia, constitutional vices or physical exhaustion, strongly predisposes to mastoiditis, whenever a purulent otitis media ensues.

The constitutional status undoubtedly plays a prominent rôle in the development of mastoiditis, whatever may be the exciting cause. Thus, syphilis and tuberculosis in the parentage or in the individual may be said to act as predisposing etiological factors, although the mastoiditis *per se* may not necessarily be either syphilitic or tuberculous in character. Among children this predisposing dyscrasia, according to Körner and others, is of more than passing interest as an etiological factor in mastoid disease. The types mentioned in the preceding paragraph should not be confounded with true tuberculous mastoiditis.

Course and Symptoms.—Acute purulent mastoiditis is divisible into two general types:—

1. A form which is almost painless but characterized by a very profuse otorrhea.

2. A form evidencing intense deep-seated pain from the very beginning and having only a moderate amount of ear discharge.

The first-mentioned type, wherein the attack of mastoiditis develops without pain and with a very profuse otorrhea, is the rarer of the two forms. Occurring in this form it is not easily recognizable, because of the absence of pain. There is but little pus retention and consequently little pain. The only fact that impresses the observer in this group of cases as significant is the excess of the ear discharge. Ordinarily, after an early incision of the drum membrane for the relief of an attack of acute purulent otitis media, the ear discharge gradually subsides in from two to three days to as many weeks. As it subsides it gradually becomes less and less purulent, then mucopurulent and finally it gradually ceases. In such cases the cessation of the pus flow is coincident

with the healing of the perforation in the drum membrane. But, in the cases of mastoiditis of the type under discussion, instead of this finding, the character of the otorrhea becomes gradually more and more purulent as time goes on, even when the discharge was less marked at the commencement of the attack. The external auditory canal immediately refills with pus after being cleansed, and it is hardly possible to obtain an exact otoscopic picture. The momentary view reveals a red, infiltrated, and macerated drum membrane containing a perforation of varying size and location, through which there is a flow of pus which during the early stages may be streaked with blood. It is evident that this excessive flow cannot emanate from the tympanic cavity alone, and hence must come from the interior of the mastoid process. Especially pathognomonic, therefore, is the evidence furnished by a gradual increase in the quantity of purulent exudate.

The general health necessarily must suffer under the bodily loss which is induced by the drainage of the excessive discharge. Hence the patient gradually becomes weak, the appetite suffers, there is loss of weight, and occasionally there are elevations of temperature to be noted. During the latent stages the mastoid cortex may show no swelling and no tenderness to pressure, and subjectively the patients complain of no pain. The condition may continue thus for a considerable period, although at any time pus retention may take place and cause pain and the other symptoms typified in type two.

In certain cases the mastoid cortex becomes perforated and then, as the periosteum is reached, pain on pressure begins and swelling behind the ear becomes evident. In other cases, because of advancement of the lesion, the perforation takes place through the inner table of the mastoid and intracranial complications ensue. More rarely the labyrinth becomes involved. This type of mastoiditis is, fortunately, not the most common, and it usually attacks those whose bodily resistance is lessened through intercurrent or preceding disease, especially young children and individuals of all ages who are affected with diabetes.

The regular type of acute purulent mastoiditis, which is accompanied from the beginning by pain and a more moderate otorrhea, is the most common type of the disease. Pain is evinced upon pressure and also felt subjectively by the patient. The initial point of tenderness from pressure is found over the mastoid antrum (Fig. 127). (See diagnosis for details regarding points of tenderness on pressure.)

The pain is due both to pressure from pent-up pus and to the inflammation of the intracellular mucosa. After perforation or incision of the drum membrane, the pain becomes less and remains less for a day or two as the otorrhea becomes established; then during succeeding days it gradually becomes more intense, and meanwhile there is increased tenderness to pressure over the cortex of the mastoid. The latter symptom establishes a positive diagnostic sign.

The pain of this type of mastoiditis, while rarely as excruciating as that which accompanies an attack of acute purulent otitis media previous to rupture of the drum membrane, is continuous, deep-seated and radiates over the entire side of the cranium.

The facial expression is that of anxiety and suffering, and the patient usually inclines the head toward the affected side.

A symptom of mastoiditis, which appears with comparative frequency and one which the author has never seen described in otological literature, is tension of the sternocleidomastoid muscle. This symptom is not invariably present. The tension is most marked when the tip cells are involved and when rupture of the mastoid cortex has taken place.

In neglected cases, wherein the purulent process has not been relieved by timely operation, the fold (retroauricular) behind the concha gradually becomes obliterated, the ear, as the disease advances, stands off from the head (Fig. 125), the tenderness on pressure over the antrum and tip of the mastoid process and posteriorly over the entrance of the mastoid emissary vein increases, and, finally, if a subperiosteal abscess forms, fluctuation becomes evident.

With the establishment of the subperiosteal abscess, the subjective pain usually ceases; but the swelling continues to extend over the region of the cortex, and unless relieved by operation the pus may reach the skin, which then becomes red and inflamed, and spontaneous perforation, especially in children, takes place.

In a certain number of cases the pus from the interior of the mastoid process breaks through the *incisura mastoidea* behind the digastric muscle. This type of cases has been designated *"Bezold's mastoiditis."* It is more common in children, although Bezold estimates its occurrence in 20 per cent. of all cases. Hartmann (1888) describes another type wherein the pus penetrates outward through the zygomatic root and rupture takes place.

The author has recently had under observation, at the New York Post-graduate Hospital, a case of this type. The patient, a child of about six years, had a fistulous opening into the zygoma, located about one inch anterior to the upper attachment of the auricle. The accompanying chronic purulent otitis media and a postauricular fistula, the result of an incomplete mastoid operation, furnished indisputable evidence that the zygomatic fistula was primarily the result of a purulent mastoiditis.

In rare instances the pus burrows between the membranous canal wall and the posterior bony meatal wall.

Finally, perforation may take place through the inner cranial wall and cause an intracranial complication.

The general health may remain undisturbed. Fever is present in about 50 per cent. of the cases, and in the majority of these only during the evening. In children temperature elevations are more frequent, and even convulsions are sometimes observed.

In both types of mastoiditis we find drooping of the posterior

superior canal wall, thus narrowing the lumen of the canal (Fig. 126).

The drooping of the posterior superior canal wall, together with the bulging of the upper segment of the drumhead, the pain on pressure over the mastoid fossa (antrum), mastoid tip and mastoid emissary vein, and the significance which must attach to excessive and continuous otopyorrhea which resists all approved measures of local treatment, constitute the classical symptoms of acute purulent mastoiditis.

Diagnosis.—The so-called classical symptoms of acute mastoiditis mentioned in the preceding paragraph, viz., pain in the mastoid process, tenderness upon pressure upon the mastoid cortex (antrum, tip, zygoma, mastoid emissary vein) (Fig. 127), the quantity and character of the pus discharge, the bulging of the

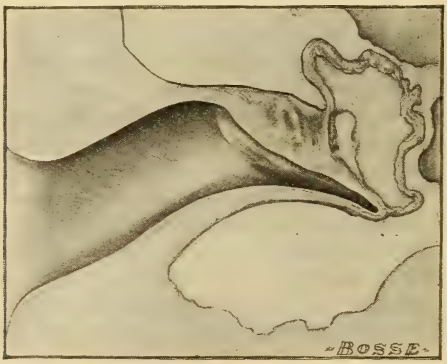

Fig. 126.—Lateral view of the external auditory canal and tympanic cavity, showing bulging of the posterosuperior canal wall into the lumen of the external auditory meatus.

upper segment of the drum membrane and the drooping of the posterosuperior canal wall, when considered in conjunction with certain minor and less constant concomitant symptoms, to be hereinafter mentioned, are sufficient to determine the diagnosis.

A differential blood-count (see Chapter VII) which records a marked increase in the leucocyte count and a high polynuclear percentage, when occurring in conjunction with other symptoms of the disease, tends to establish a diagnosis of purulent mastoiditis.

Likewise the identification of the offending micro-organisms by a bacterial examination of the pus discharge, the methods and significance of which are described in Chapter V, aids in determining the probable severity of the disease and its diagnosis.

Fever is not constant in adults, but is usually present in young children. There is no characteristic range of temperature in acute purulent mastoiditis, but when present fever is of diagnostic import.

In a considerable proportion of the advanced cases an examination of the mastoid process furnishes important material data regarding the diagnosis. The manner in which this is carried out

deserves special mention. The patient should be seated with his back toward the light, and the examiner, standing directly behind him, should make a minute inspection of the exterior of the mastoid process and compare it with the mastoid process of the opposite side.

Upon inspection, the first noteworthy fact developed in a case is the absence of the auriculomastoid skin fold. The external ear

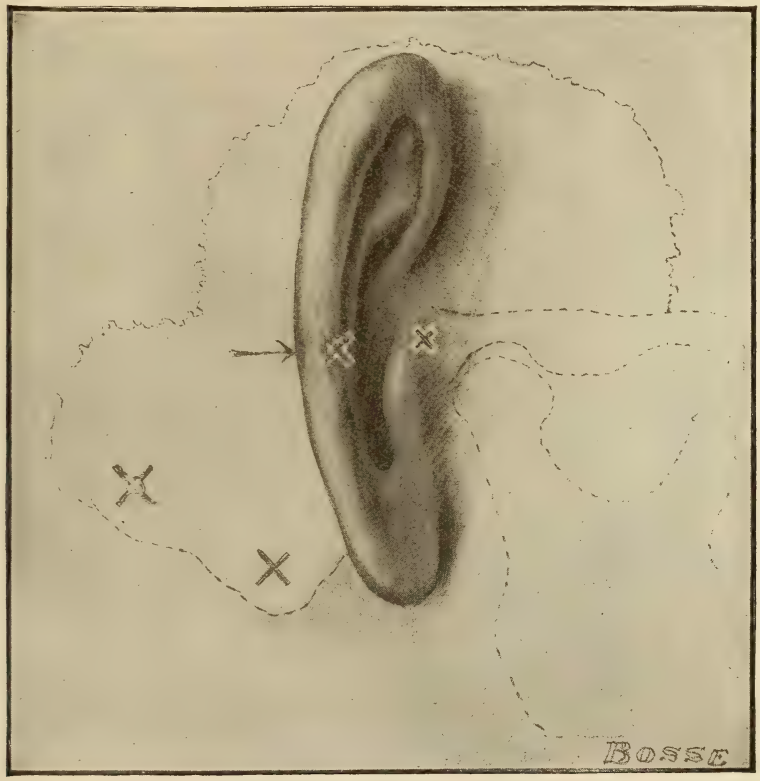

Fig. 127.—Showing the localizing points of tenderness upon pressure over the mastoid process.

(concha) is often pushed outward and forward and lowered relatively to the concha of the opposite (healthy) side (Fig. 125).

Upon pressure, tenderness is elicited at the fossa mastoidea (over the mastoid antrum) (Fig. 127). This is the most common localization of tenderness. Then, in the order of frequency of occurrence, pain is evinced by pressure upon the mastoid tip and along its posterior margin and over the seat of the zygoma (Fig. 127). Finally, pain is evident when pressure is applied at the site of the mastoid emissary vein, and upon its advent the mastoid operation should be performed.

Radiography (Figs. 128, 129, 130) furnishes valuable confirmatory evidence of purulent invasion of the mastoid process. Successful radiographs of the mastoid process are exceedingly difficult to obtain and in every instance both mastoids should be taken, both for the purpose of comparison and for study of the anatomical relations. The latter are oftener discernible upon the affected side. It should here be noted that, except in rare instances, the two mastoid processes are symmetrical. The radiograph (Figs. 129, 130) is particularly useful in cases of atypical mastoiditis wherein the usual typical symptoms are absent. An experienced otologist should be able to render a diagnosis of acute mastoiditis without the radiograph, but as confirmatory evidence the radiograph is of extreme value. A more recent development in the employment of radiography in mastoiditis and one of great help, is the repeated radiography of the mastoid wherein the progress of the disease may be noted from day to day.

Differential Diagnosis.—In rare instances there is pain and swelling over the region of the mastoid process as the result of edema due to a furunculosis of the external auditory canal (Fig. 124). In this condition, in contradistinction to the swelling in acute mastoiditis, severe pain is evoked by any manipulation of the auricle, and the skin over the mastoid region can be pitted by pressure more than is possible in mastoiditis. The inspection of the external auditory canal finally, however, settles the diagnosis.

Pain and swelling about the mastoid process may also occur as a result of inflammation of the mastoid lymph glands. This condition is generally the result of an eczema of the posterior folds of the concha or other neighboring parts. These glands are also often enlarged as a complication of chronic otorrhea.

The diagnosis is easily made by means of the otoscopic picture. In acute mastoiditis it is extremely rare not to find the middle ear involved, while in the cases where the swelling is due to an inflammation of the lymphatics, the latter are usually localized and somewhat movable, and the examiner is often able to make out the outlines of the diseased glands.

Whenever the external swelling is some distance back—that is, when it seems to lie over the mastoid emissary vein—it furnishes evidence of deep-seated and extensive disease of the mastoid process, and possibly of sinus-thrombosis or other intracranial complications. When the external swelling is low on the mastoid process, and has spread downward from the mastoid tip along the muscles of the neck, it is indicative of the type of mastoiditis heretofore designated as Bezold's mastoiditis.

Preventive Treatment of Acute Purulent Mastoiditis.—The preventive treatment of acute purulent mastoiditis has already been clearly covered by the statement that patients at the very commencement of an attack of acute purulent otitis media (Chapter XVIII) should be placed in bed, given free purgation, and that free drainage of the tympanum should be established by means of a large incision through the drum membrane.

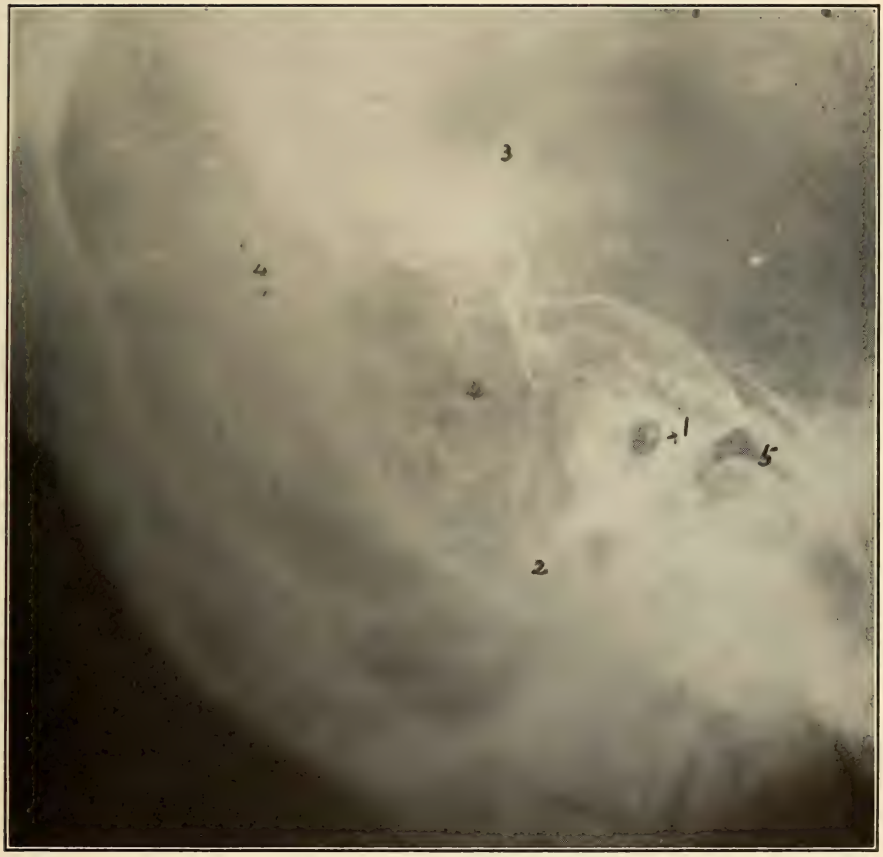

Fig. 128.—The radiograph represents a normal mastoid process (pneumatic type). It will be noted that the zygomatic cells extend well forward. The numbered points in the radiograph are interpreted as follows: 1, the external canal through which the malleus is visible; 2, the tip of the mastoid process; 3, the outlines of the auricle; 4, the outlines of the lateral sinus; 5, the condyle of the lower jaw.

Fig. 129. The radiographs of the mastoid represented in Figs. 129 (left) and 130 (right) serve to compare a healthy (Fig. 129) mastoid process and a diseased (Fig. 130) mastoid process. The history was that of acute mastoiditis on the right side with the classical symptoms. Upon operating the cells were thoroughly broken down, even in the zygomatic region. As a rule, the outlines of the lateral sinus are defined in the radiograph. In this case, however, only the anterior sinus wall in the descending portion is visible.

Fig. 130. The diseased mastoid process.

In grippe cases or whenever the microscope reveals a streptococcic invasion of the mastoid process, no prolonged abortive attempts should be maintained. The same holds true in all cases of acute mastoiditis occurring in cases of chronic purulent otitis media. In fact, as soon as a positive diagnosis of pus invasion of the mastoid cells can be made, the time has arrived when operative interference must be seriously considered. The great increase in the number of mastoid operations performed in recent years has raised the question in many minds as to whether these operations are not performed with too great frequency. The question is proper and worthy of consideration. Intelligent conservatism should be the basis of action.

There is but little doubt that the enthusiasm of some otologists has carried them beyond reasonable limits in operating upon cases of acute mastoiditis. Of the cases of acute purulent otitis media with tenderness over the mastoid antrum and even more general mastoid tenderness, when seen early, and placed in bed for observation, drainage and local treatment, more than 50 per cent. recover without operation except incision of the drum membrane.

On the other hand, in the private and hospital practice of expert otologists, a mistaken diagnosis is a rare exception.

Even in the face of the large numbers of mastoid operations being performed today many patients are still deprived of their hearing and many lives are still sacrificed, as a result of either delayed operation or neglect to operate at all. Conservatism, so far as it relates to operation for acute mastoiditis, while always commendable and much to be desired, is, when carried to the extreme, detrimental to the interests of the patient.

Treatment.—The treatment of acute mastoiditis in its early stages is exactly similar to that indicated for acute otitis media. The patient is put to bed, the membrana tympani freely incised, the patient's bowels and diet carefully regulated, and the affected ear is meanwhile douched with normal salt or warm bichlorid of mercury solution (1 : 2000 to 1 : 6000) every few hours. (For full details regarding douching of the ear the reader is referred to Chapter VIII.)

In fully developed purulent mastoiditis, or in a case where abortive measures have failed, the only treatment of value is of a surgical nature, and the operation indicated is the simple mastoid operation. Operation is indicated then, when the symptom-complex heretofore described is presented, or in cases developing more slowly and somewhat atypically, when the ear discharge has persisted from two to four weeks (Körner), or to eight weeks (Bezold), and has increased in quantity as the time passed rather than diminished. The operation is indicated when swelling, pain, or tenderness of the mastoid region persists longer than a week in spite of the instituted local treatment (Schwartze).

In a recent paper[2] the author formulated his views as to the

---

[2] New York State Medical Journal, April, 1909.

indications for the simple mastoid operation as follows: A simple mastoid operation is indicated wherever a purulent inflammatory process has invaded the mastoid antrum and mastoid cells with the following evidences:—

1. Pain over the mastoid region. The pain is deep-seated and continuous, and radiates over the entire side of the cranium. The facial expression is that of anxiety and suffering.

2. Tenderness on pressure over the mastoid cortex. The localizing points of tenderness are found over the mastoid antrum, the mastoid tip, along the zygoma and about the entrance of the mastoid emissary vein. Tenderness is sometimes entirely absent.

3. Drooping of the posterosuperior canal wall, and bulging of the drum membrane which does not diminish as a result of paracentesis.

4. Fever. The rise in temperature is not characteristic, but is more marked in infants and young children.

5. Discharge. The discharge may be simply excessive with a tendency to increase rather than diminish; it may be of virulent type, or a sudden cessation of discharge may take place with simultaneous increase of mastoid pain. A prolonged profuse aural discharge which resists all approved measures of local treatment, including paracentesis, is considered by many otologists to furnish sufficient indication for the performance of the simple mastoid operation. Some recent experiences have led the author to believe that, given an acute purulent otitic inflammation with fetid odor, wherein it has been demonstrated that the invasion has been one of the more virulent types of pathogenic bacteria, and in patients of weakened vitality if the discharge manifests no tendency to abate after six or eight weeks, a mastoid operation must be seriously considered. In the majority of cases of this type occurring in my practice extensive disease of the mastoid cells has been found.

6. Subperiosteal, postauricular swelling, with or without superficial abscess.

7. The operation is imperative in the presence of symptoms of intracranial complications, or of purulent labyrinthitis.

8. The advent of facial paralysis. This complication invariably indicates the necessity for an immediate mastoid operation, on account of the intimate relationship which exists between the facial canal and the labyrinth.

9. Blood examinations (see Chapter VII) in conjunction with other symptoms of mastoiditis are of great diagnostic value. A high leucocytosis and polynuclear percentage indicates the presence of infection in some portion of the body.

In addition to the above-mentioned indications, it may be stated that, on account of the manifest danger of serious complications, the mastoid operation is a life-saving measure, and, although it is performed primarily in the interest of the life of the individual, there are secondary considerations which materially enhance its value, and, as a consequence, are worthy of note at this point.

The mastoid operation in acute mastoiditis quickly terminates

a purulent necrotic process which otherwise might become chronic and attended with all the train of deleterious and dangerous results which accompany this troublesome affection. To mention them is sufficent: 1. Necrosis of bony areas which are closely related to vital structures. 2. The prolonged and constant danger of serious labyrinthine and intracranial complications. 3. Loss of hearing and persistence of otorrhea.

It will thus be seen that, even though a patient suffering from acute mastoiditis might recover from the acute symptoms without loss of life, such recovery is prone to be followed by the sequelæ above mentioned; whereas an operation, skillfully performed, in due season, brings to an end the purulent process, *with perfect hearing results.*

The time for operative interference is ever dependent upon a satisfactory diagnosis of the presence of destructive purulent inflammation in the mastoid cells. Just when the exact time has arrived may not be measured by days or hours, but the simple mastoid operation should be performed in acute purulent inflammation which involves the mastoid cells, whenever a permanent remission of symptoms has not been effected either by drainage through the drum membrane, rest in bed, or the employment of the local measures heretofore described.

Much has been written in favor of a so-called early, simple mastoid operation, and if by this is meant operation as soon as it can positively be demonstrated that a purulent inflammatory process has invaded the mastoid cells, which is too virulent and too extensive to offer any hope of spontaneous cure either by drainage or absorption, then the early operation is to be recommended.

On the contrary, it is not wise to operate immediately upon every patient who has tenderness on pressure over the mastoid antrum, during the first three or four days of the attack, for the reason that in the milder cases it is quite possible for drainage through the aditus, combined with local absorption, to effect a cure without operation, and, further, it is deemed safer in the interest of the patient to operate after nature has thrown out some protective limitations to the disease within the mastoid cells.

There are some dangerous indications which call for immediate operation, whatever the concomitant symptoms may be, and among these are:—

(*a*) An acute mastoiditis occurring in an ear which is the seat of chronic purulent otorrhea.

(*b*) Upon the advent of symptoms of labyrinthitis, the chief of which are destroyed audition, nausea, vertigo and nystagmus.

(*c*) The appearance of facial paralysis.

(*d*) The appearance of symptoms of intracranial involvement.

To define the simple mastoid operation it may be stated that when properly performed it should extend to the limitations of the disease, and this usually calls for the removal of the mastoid cortex, the complete excavation of all mastoid cells, especially the large cells at the tip, those posterior to the sigmoid flexure, those about

the roof of the zygoma; the curetment of all granulations and necrosed areas, and the establishment of postaural drainage of the mastoid cells and antrum.

The simple mastoid operation, when skillfully performed and previous to the advent of serious complications, yields brilliant results, and is practically without danger to the life of the patient.

The results may be summed up as follows: 1. Relief of pain and suffering. 2. Cure of a destructive purulent process, which otherwise menaces life and comfort. 3. Preservation of the function of hearing, which otherwise might become destroyed on account of continued suppuration. It is the most invariable rule that the simple mastoid operation, when performed for the cure of acute purulent otitis media and mastoiditis, results in perfect hearing, and this is no mean argument in its favor. 4. It lessens the tendency to serious intracranial and labyrinthine complications, and the possibilities of recurrence are rare.

In acute mastoiditis it is important to give careful attention to the patient's general condition, to the nature of the infection, and, so far as is possible, to the general conformity and character of the mastoid itself, making every effort to determine the extent to which the infection may have invaded the mastoid tissues.

The nature of the infection, also, must receive due consideration. Various micro-organisms of the more virulent types have of late been carefully studied (see Chapter V). There is no specific germ of purulent otitis media; neither is its invasion invariably monomicrobic. In our present state of knowledge we must assume that the effects of the invading micro-organisms, so far as they relate to the various complications of purulent otitis media, are modified by the anatomical surroundings, the resisting power of the patient, and probably to some extent by the nature of the pabulum with which they are bathed.

ATYPICAL CASES OF MASTOIDITIS.

Among the more recent developments pertaining to the problem of acute mastoiditis has been the accumulation of knowledge and experience with atypical cases of mastoiditis. The author and Dr. Isidore Friesner recently reported a series of these cases with comments,[1] in which attention was called to the fact that there are many instances of osteitis of the mastoid process requiring operative interference which are secondary to tympanic infection but in which the tympanic portion of the disease, so far as signs are concerned, plays a comparatively insignificant rôle. In many of these cases there is no history of aural discharge at any time. In others the events pertaining to discharge are more or less remote. The author has seen and known of so many cases of this type that he has been forced to conclude that atypical cases are far more common than he had hitherto supposed. In other words, that there are many operative cases of mastoiditis in whom the

[1] American Medical Association Journal, June 10, 1922.

majority of the typical symptoms are absent. In children, particularly where a history of headache or pain is not obtainable, we frequently see a subperiosteal abscess as the first evidence of mastoid disease or middle ear infection. Many of these cases, on account of the absence of discharge from the ear, are admitted into the wards of general hospitals and only come under the observation of otologists after the external symptoms of mastoiditis have developed. There is considerable variation in the symptoms of these atypical cases. The radiograph is of great assistance as confirmatory evidence (Figs. 129, 130). A brief history of one of the author's cases is as follows:

D. B., adult. Nine months ago had been treated for nose trouble, probably sinusitis, but without apparent ear complications. Five weeks previous had severe attack of pain in left ear and left temporal region. External swelling soon became marked and he sought relief in the Ear Service of the Manhattan Eye, Ear and Throat Hospital. The external swelling was so extensive, partially closing the external auditory canal, that the majority of the staff considered it to be furunculosis. He then consulted an otologist at his office, who opened the ear drum, but no discharge followed. At no time during the subsequent treatment was there any discharge from the external auditory canal. External swelling extended anteriorly until it involved both left eyelids, and when we saw him both eyelids were edematous. At this time a radiograph showed extensive involvement of a large pneumatic mastoid. Arrangements were made for operation, but the man disappeared for about a week, claiming that the external swelling had subsided. It however returned and became so extensive that the left eye was entirely closed and the eyelids of the right eye were considerably swollen and edematous. Mastoid operation was then performed and a large cortical perforation was found at the root of the zygoma. He had an enormous abscess involving the soft tissue of the temporal and parietal region of the scalp. He also had a very large perisinus abscess and the dura of the middle cerebral fossa was denuded over a wide area. He made a rapid and uneventful recovery with good hearing.

CHAPTER XX.

DISEASES OF THE MIDDLE EAR.

(Continued.)

THE SIMPLE MASTOID OPERATION.

Preparation of the Patient.—The preparation of the ear and area about it prior to the performance of the mastoid operation is of importance; hence, the process is herein described.

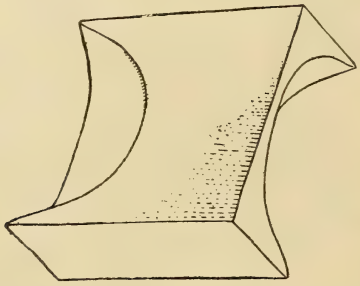

Fig. 131.—Wooden block, grooved for head rest during operation upon mastoid process. (Devised by *S. Richardson.*)

The patient should receive a general bath, including a thorough flushing of the hair and scalp. This is followed by washing the scalp with a solution of bichlorid of mercury (1 : 5000). The hair

Fig. 132.—The head in position upon grooved block.

should be shaved from behind and above the ear for a distance of at least one inch from the hair line. The absence of hair on recovery is a source of considerable mortification to sensitive females, and no more should be sacrificed than is necessary in order to safeguard the wound during the healing process. It is not usually necessary to remove the portion immediately anterior to the auricle, and this serves to cover the denuded space when all dressings are over.

The external auditory canal should be irrigated with a warm bichlorid of mercury solution 1:2000, wiped dry and then lightly packed with gauze. The area behind the ear should be thoroughly scrubbed with green soap and water, followed by ether, bichlorid of mercury solution 1:3000, and alcohol, care being taken to thoroughly cleanse the crease at the attachment of the auricle.

Fig. 133.—Photograph showing the arrangements completed for performing a mastoid operation.

A coating of collodion painted on the hair around the margin of the shaved area will prevent any stray hairs from getting on the operation field.

In cases where from cosmetic or other reasons it is inexpedient to shave off any hair, it should be carefully combed toward the scalp in all directions from the mastoid area and thoroughly matted with collodion or a wide strip of adhesive plaster. A wet bichlorid of mercury compress is then bandaged over the mastoid process and

the ear, and the patient placed in bed to await the call to the operating room. If time permits, an enema should be given before the operation.

After the induction of anesthesia (for local anesthesia of the mastoid process see Chapter VIII and Figs. 52 and 180) and a sterile sheet and sterile towels have been adjusted about the shoulders, the nurse, after removing the compress from the mastoid, places a rubber bathing cap over the patient's head to prevent blood and solutions from getting into the hair. The operative field is again cleansed with ether and alcohol and three sterile towels are ad-

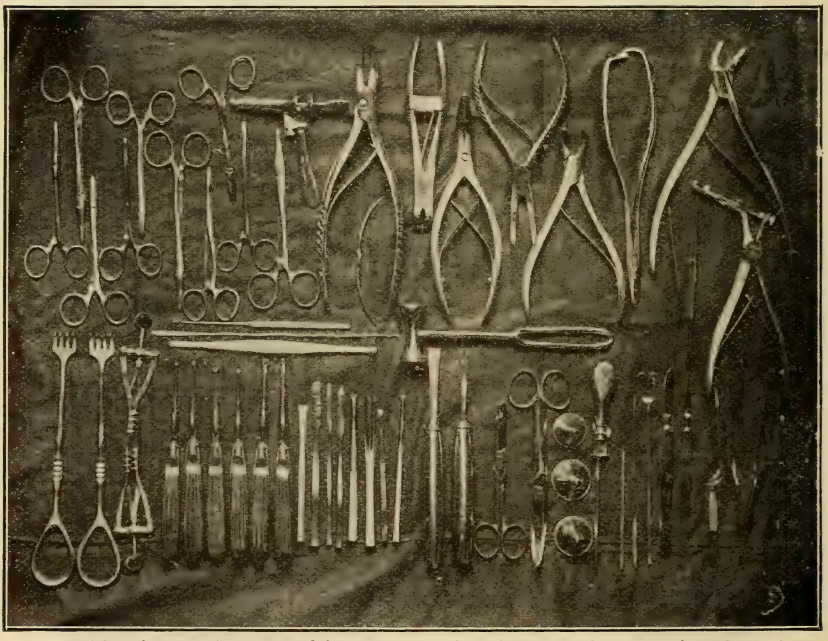

Fig. 134.—A complete set of instruments for the mastoid operation, including the emergency instruments required for complications.

justed over the head, face, and neck, in such a manner that the auricle and operative field only show through a triangular space left for that purpose. The exposed area should now be painted with tincture of iodine as a precaution against skin infection.

The patient is now ready for the operator, who removes the tampon from the auditory canal. A wooden block (Fig. 131) or headrest placed underneath the head and neck serves to hold the former firmly in position (Fig. 132) and is much preferable to sandbags, because the block does not easily become displaced. The surgeon should have the aid of one experienced assistant and two nurses, in addition to the anesthetist (Fig. 133).

Instruments.—A complete set of instruments, carefully sterilized by boiling, should be at the command of the surgeon, for,

while only a few may be required, every emergency should be provided for. In order to meet the requirements a rather extensive armamentarium will be found necessary. The accompanying cut (Fig. 134) illustrates those which the author's experience has found sufficient to meet all requirements.

It is of extreme importance that the operative field be fully illuminated. Artificial light is usually necessary, although occasionally operating rooms are so arranged that sufficient direct light is obtainable. Artificial light, when required, is usually obtainable through the employment of the ordinary hand electric light, or,

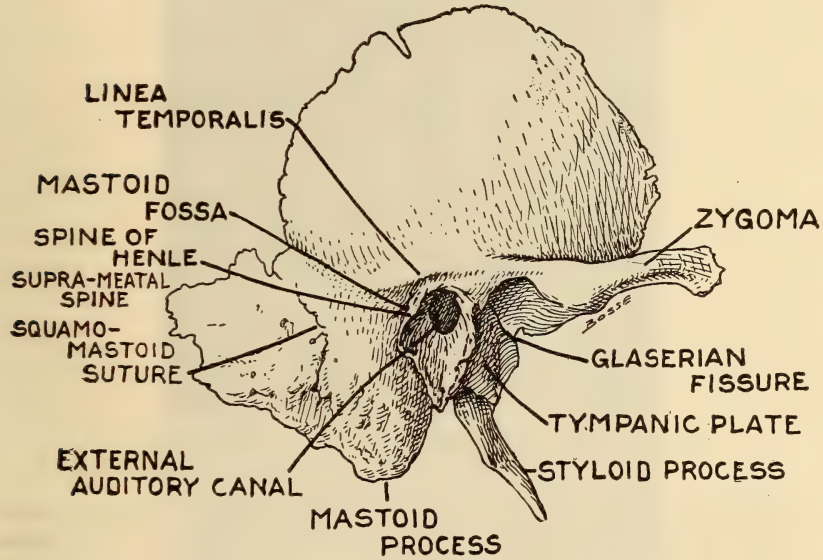

Fig. 135.—Temporal bone, external surface, showing landmarks.

preferably, an electric headlight. The author's headlight (Figs. 7 and 133), which is portable and can be used with a dry-cell battery or attached directly to the street current by the interposition of a suitable controller, has been found exceedingly serviceable in this connection. By its use a strong, steady bright light is thrown directly into the operative field.

It is especially efficacious in illuminating the deeper portions of the operative field.

Surgical Anatomy.—The exposed bone (Fig. 141) after retraction of the soft parts shows a field limited in front by the posterior wall of the external auditory canal, and an irregular line downward to the mastoid tip. Above and extending backward from the root of the zygomatic process is seen the linea temporalis (Fig. 135). This line serves as a guide, above which it is unsafe to go, as it marks in a general way the level of the middle cranial fossa. From the mastoid tip, extending upward, there is often seen,

in the very young and in childhood, the squamomastoid suture or its remains, which in the adult is only marked by a fine shred of adherent periosteum.

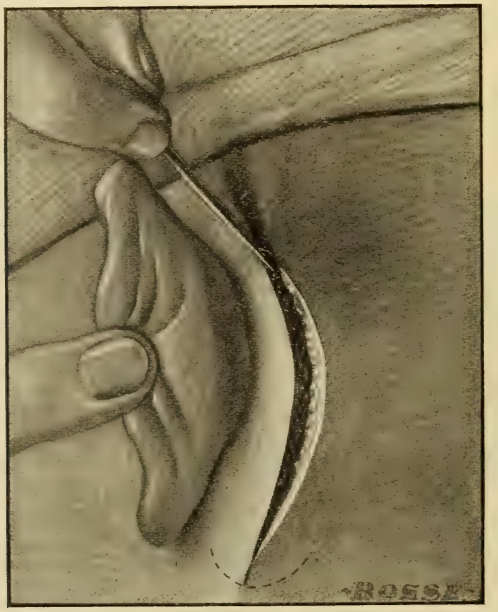

Fig. 136.—The primary incision through the soft tissues of the mastoid process.

Behind the upper posterior angle of the external auditory canal we see the spine of Henle, and immediately behind Henle's spine the spongy spot, usually a depression known as the supramastoid fossa, is located (Fig. 135). This supramastoid fossa, with the

Fig. 137.—Langenbeck's hoe periosteal elevator.

Fig. 138.—The Douglas periosteal elevator.

spine of Henle, together with the curved outline of the bony meatus, form important guides in approaching the mastoid antrum while operating upon the mastoid process.

There are several methods for locating the mastoid antrum. It is usually located by using the suprameatal triangle as a guide (Fig. 135). This triangle is an imaginary triangle bounded *above*

by the continuation backward of the zygomatic root or the linea temporalis, in *front* by a line coincident with the direction of the posterior bony canal wall, and *behind* by an imaginary line connecting the other two lines.

This triangle has been used for a long time as the safest guide to the antrum, but the author has discarded this guide in favor of the depression or fossa which lies immediately posterior to the spine of Henle, for the reason that the small fossa above mentioned is a safer and more positive guide to the mastoid antrum. When

Fig. 139.—Cutting the outer portion of the attachment of the sternomastoid muscle to the tip of the mastoid process.

the suprameatal triangle is followed it cannot be safely entered at all points of its area, inasmuch as occasionally the course of the lateral sinus is so far forward as to encroach upon this space. When the suprameatal triangle is used as a guide the operator should in all cases bear in mind the importance of keeping as close to the osseous meatus as possible. While Henle's spine is not invariably present, the depression is always to be found, and generally a slight elevation at least marks the position of the spine. With these landmarks to guide him the surgeon may gradually chisel directly inward, forward and upward through the bone, without fear, to a distance equal to the depth of the external auditory canal, when the antrum will be found to have been entered (Fig. 144). The available space is often limited to a small area on account of anomalies

in the course of the lateral sinus, or because the dura lies unusually low.

The Operation.—The primary incision should be made in a

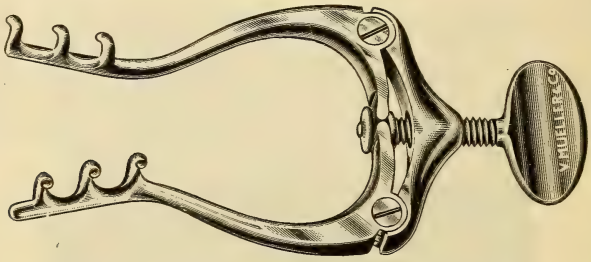

Fig. 140.—Jansen's mastoid wound retractor.

manner which will facilitate and simplify the subsequent steps of the operation. The lower portion of the mastoid should be care-

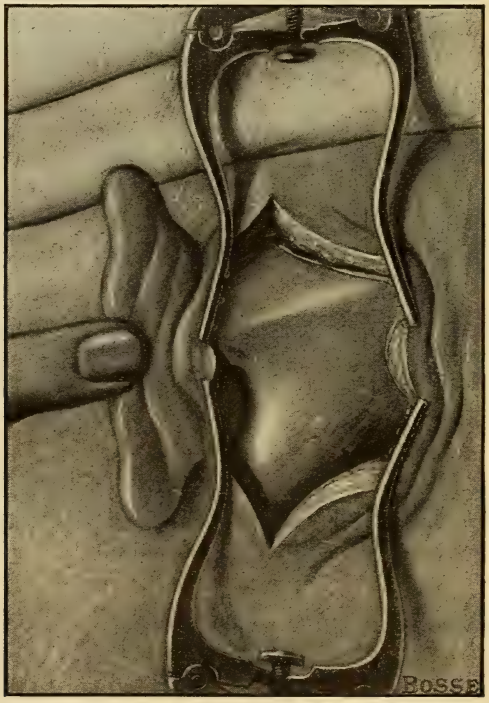

Fig. 141.—Showing the cortex of the mastoid process with the soft tissues retracted by self-retaining retractors.

fully palpated and the incision commenced as nearly as possible to the centre of the tip near its lowest border. The point of a medium-sized scalpel is then plunged through the soft tissues, including the

periosteum, to the bone and the incision extended directly upward for a short distance, or until the blade has reached the upper point of attachment of the sternocleidomastoid muscle. From this point the incision is extended forward toward the auricular attachment and is completed upward in curvilinear form, following the curve

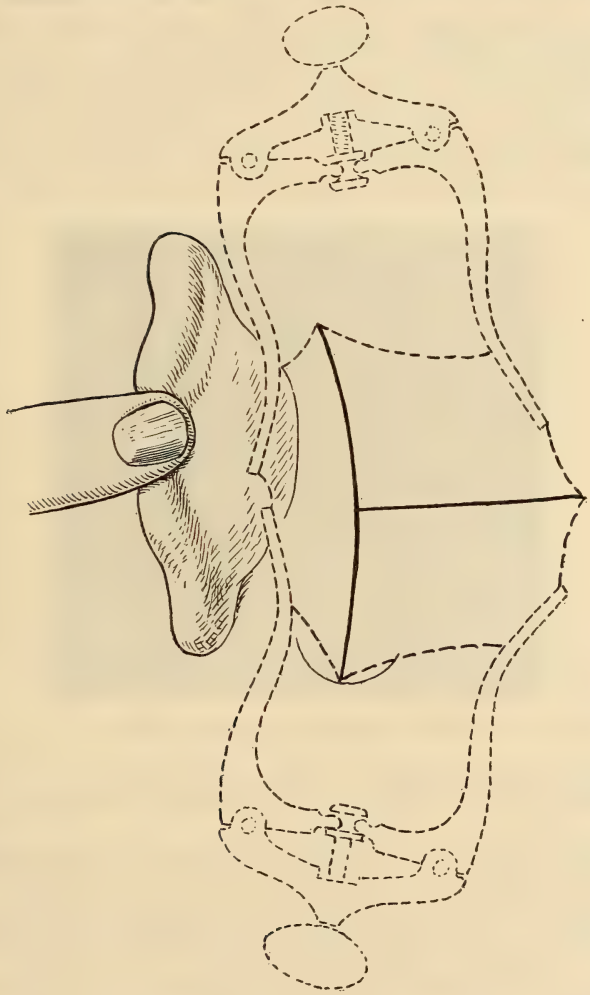

Fig. 142.—The posterior mastoid incision.

of the auriculomastoid attachment to a point even with or above the higher point of said attachment. The curvilinear portion of the incision should be about ⅜ inch posterior to the auriculomastoid skin fold (Fig. 136).

In order to control the line of incision the pinna is folded forward and held firmly against the head, without being pulled away

from its normal location (Fig. 136). Assistants are prone to pull the ear forward, in which event the incision may enter the external auditory canal instead of being posterior to it.

By commencing the incision at the middle of the mastoid tip, the operator is afterward enabled with one or two clips of a curved scissors to quickly sever the outer portion of the mastoid attachment of the sternomastoid muscle (Fig. 139), and thus denude the tip area of its covering. Whenever the primary incision is made at too great a distance from the attachment of the auricle, it becomes difficult to retract the anterior portion of the wound sufficiently to reveal the necessary surgical landmarks, especially the spine of Henle and the posterior border of the bony meatus; and, furthermore, the remaining scar being further from the auricular

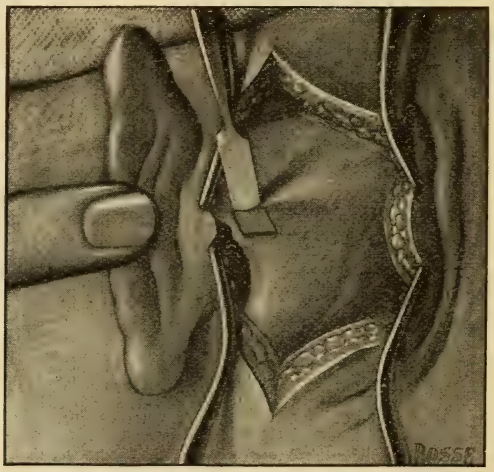

Fig. 143.—Chiseling the antrum cortex.

attachment is more unsightly. Hence the ideal incision should lie comparatively close to the auricle, where the scar almost becomes lost in the auricular mastoid skin fold.

The incision having been completed and the hemorrhage from all severed blood-vessels controlled with artery clamps, the periosteum over the entire area of the mastoid process is rapidly retracted by means of periosteal elevators, and thus the entire cortex is exposed to view. The Langenbeck or Hoe elevator is well adapted for retracting the posterior periosteal covering, and for the main portion of the periosteum which lies anterior to the incision (Fig. 137). The Douglas periosteal elevator (Fig. 138) is serviceable in the areas where gentler manipulation is imperative, especially when forcing the periosteum from the borders of the bony external meatus.

In order to completely denude the outer surface of the mastoid tip, the fibres of attachment of the sternomastoid muscle must be severed over this area by means of a strong curved scissors, or

knife (Fig. 139). The anterior flap, together with the periosteum, is then pushed well forward until the bony outline of the posterior border of the external auditory canal has come well into view, care being exercised, however, not to penetrate the membranous canal or tear it from its attachments. One or two Jansen's self-retaining retractors (Fig. 140) are then introduced and the soft tissues, including the periosteum, widely opened, thus exposing the entire area (Fig. 141). Many operators prefer hand retractors. This unfolds to the operator the landmarks necessary to open the way to the mastoid antrum. These preliminary procedures are the keynote to the proper performance of the mastoid operation, and he who fails to bring to his view the posterosuperior border of the canal, the spine of Henle and the supramastoid fossa before at-

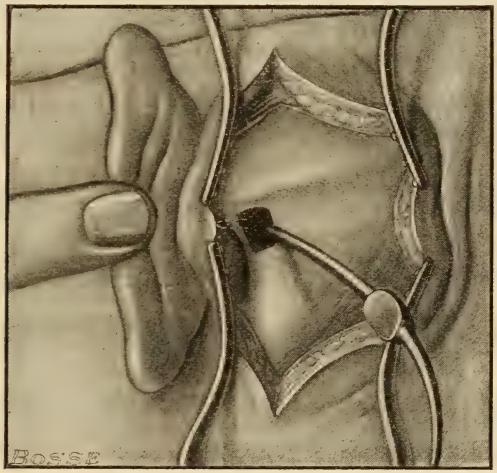

Fig. 144.—The mastoid antrum opened and a curved probe inserted through the aditus.

tempting to enter the antrum, fails thereby in establishing control of the situation.

Whiting and others advise a posterior incision to extend backward at right angles to the first incision in all cases. The posterior incision is necessary and desirable in large pneumatic mastoids in which the disease has encroached upon the posterior cells, and in cases of lateral sinus-thrombosis or cerebellar abscess. Otherwise it is an unnecessary procedure. Besides being unnecessary in all cases, the posterior incision adds to the unsightliness of the scar. It is rarely called for in children and in less than 50 per cent. of adults. The line of the posterior incision should extend from the spine of Henle directly backward toward the occipital protuberance (Fig. 142) to the required distance. This selection is obviously made in order to follow the course of the lateral sinus.

It is never necessary or expedient to make a posterior incision until the operation has progressed to a point where it can be de-

termined that complete excavation cannot well be accomplished without it. In many cases extensive disease becomes apparent upon removing the major portion of the cortex, hence the posterior incision becomes necessary at the beginning of the operation. The cortex is now exposed and the next step in the procedure is the opening of the mastoid antrum. The antrum is entered either by



Fig. 145.—Set of mastoid chisels and gouges.

using the mallet and chisel or gouge, which are the generally accepted instruments for the work. American otologists have generally discarded the trephine for opening the mastoid cortex, and the hand gouge for this procedure has but few advocates.

Selecting a chisel with a blade about ⅜ inch in width (Fig. 143), which is held firmly by the surgeon with some portion of the hand resting upon the patient's skull to insure support, control and

accuracy, by cutting first in an upward and then in a downward direction with the chisel, a few strokes will usually chip off the bone and the blade will pass through the cortex. During this procedure great care should be exercised to prevent the chipping away of the osseous canal wall. In some individuals the cortex is extremely thick and in others it is either thin in conformation or has been undermined by the underlying purulent process.

In pneumatic mastoids with softening, or when pus is present throughout these structures, the chisel may be discarded as soon as the cortex has been cut through, and the operation completed with the curet and rongeur forceps (Fig. 147). The curet is to be preferred to the chisel, the reasons for which are outlined in suc-

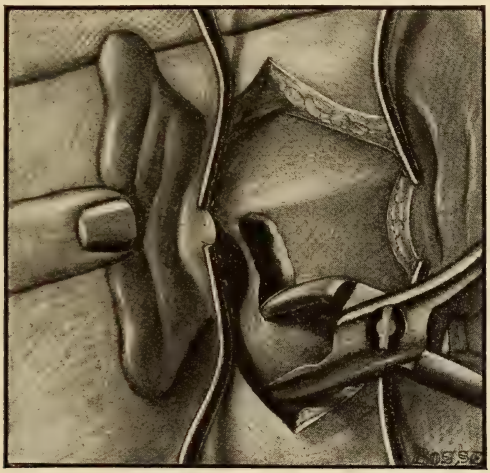

Fig. 146.—Removing the cortex with rongeur forceps.

ceeding paragraphs, providing the tissues are sufficiently soft to yield to its sharp cutting edges. It is of the utmost importance that chisels be of the finest steel and always kept sharp (Fig. 145). Both chisels and curets should be held with great firmness and always with control, in order to prevent serious accidents, the chief of which are wounding the lateral sinus and meninges and injury to the facial nerve. In young children the osseous tissues are extremely soft and a blow upon a chisel which is not sufficiently controlled by the operator may drive it through both tables of the skull with serious consequences.

After entering the mastoid antrum a curved silver probe or Bowman's eye probe sharply curved at the tip may be introduced into the opening and pushed gently forward into the aditus ad antrum (Fig. 144). If the probe freely enters in the manner described one is assured that the antrum has been entered. To operators of wide experience this procedure is rarely necessary. In infants and young children the mastoid antrum lies nearer the surface of the cortex than in adults (Fig. 62).

The antrum is usually found situated just posterior to and above the external auditory canal. That is, taking the posterior canal wall as a guide, it will be found located just behind it and at a few lines elevation above the upper pole of the canal.

This corresponds to the mastoid fossa, located in McEwen's triangle.

A practical guide is to assume the canal walls to be the rim of a clock dial, and at a place representing between one and two o'clock, or eleven and twelve o'clock, depending upon when the side is right or left, a line continued a few millimeters beyond the dial rim will indicate the cortex over the antrum.

Its depth is, generally speaking, a few millimeters beyond the depth of the external auditory canal. The quotation of figures is

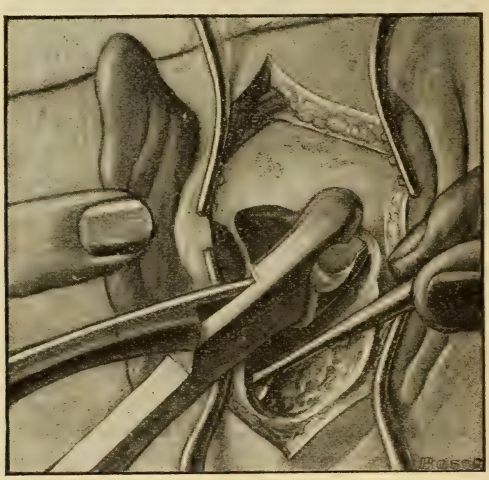

Fig. 147.—Excavating cells and granulations with curet, and the technique of biting the overhanging cortex with the rongeur forceps.

of little use, inasmuch as the distance varies in different individuals, being relative in depth to the depth of the external auditory canal.

The size of the antrum varies according to whether the given mastoid is pneumatic or not, being smallest where eburnation is marked.

After entrance to the antrum has been definitely accomplished, and a portion of the surrounding wall of cortex has been cut away, a careful search is instituted by probes or curets in order to locate the route which the infection has followd. As a rule the probe indicates a track leading toward the mastoid tip, or one leading backward over the knee of the sinus. Occasionally it leads upward and forward into the region of the zygomatic cells. It is well at this point, providing the original opening permits, to do a moderate amount of excavating with a sharp spoon curet, and then with a few bites of strong rongeur forceps to cut away that portion of

the cortex which overhangs the excavation. Then by introducing the forceps after the manner depicted in the illustration (Fig. 146) a furrow of cortex is removed downward to the mastoid tip.

The indiscriminate use of the mallet and chisel in the mastoid operation is to be condemned on account of the shock produced by the blow of the mallet. It is far more desirable to rely upon

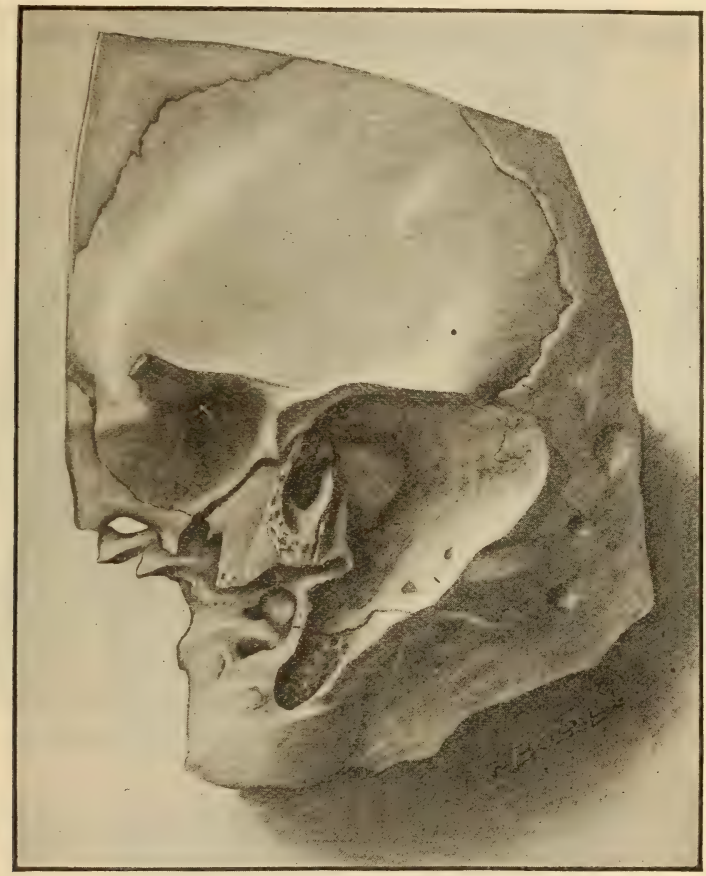

Fig. 148.—The specimen shows a continuation of the mastoid cells into the basilar process of the occipital bone. (From Dr. Wm. M. Dunning's collection.)

the curet or the various forms of rongeur forceps (Fig. 147) for removing the cortex, together with the underlying diseased tissues, because the blow of the mallet upon the chisel, directed always with more or less force toward the patient's brain, produces a certain degree of nervous shock, and, even though the patient is under anesthesia, the effect of the blow upon the brain is more or less harmful.

In this connection it is interesting to note the result of observations made by Grossman, of Berlin, who took sphygmographic tracings of the pulse and blood-pressure during numerous mastoid operations, in an effort to estimate the effect of the chisel and hammer blows. His observations demonstrated that the use of the chisel was a severe shock to the entire system, as evidenced by the rapid and irregular pulse beats during the act of chiseling.

The disagreeable effects of malleting may be demonstrated by a blow with a mallet upon a blunt piece of iron placed against any

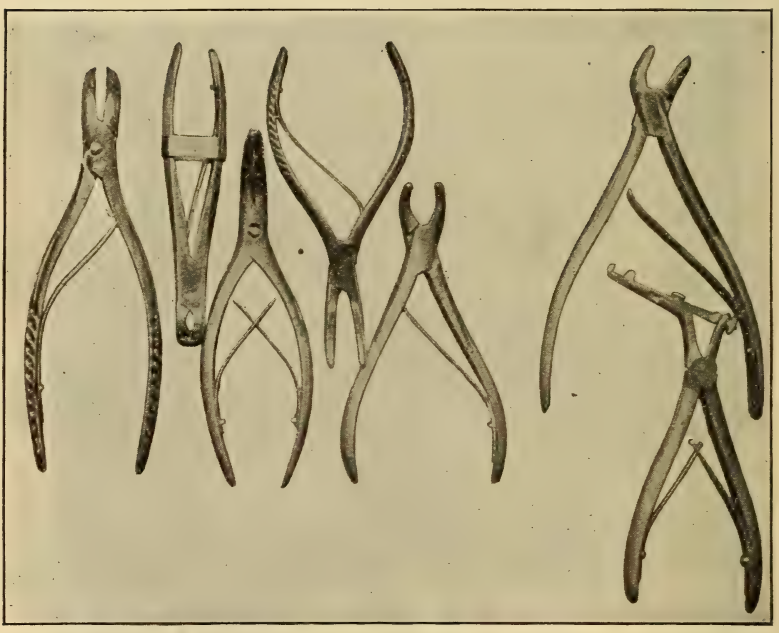

Fig. 149.—A set of rongeur forceps comprising those in common use.

portion of one's own skull. Where possibly a cerebral abscess, meningitis, or a thrombosed lateral sinus is present, serious accidents might occur as a result of the vibrations of the blow from the mallet, and its use should, therefore, be limited as much as possible.

It may be further argued that the rongeur forceps are a much more rapid and precise method for removal of the cortex and diseased bone.

When pus and granulations are encountered in the areas adjacent to the mastoid antrum, it should be the invariable rule to extend the excavations downward to the mastoid tip, using heavy curved rongeur forceps for removing the cortex, and following with a sharp, strong curet until all the tip cells are removed and a smooth surface remains. This procedure often necessitates the exposure of portions of the digastric muscle. The cells of the

mastoid process are occasionally contiguous with the diploic structures of adjacent bones (Fig. 148).

Various strong, well-made rongeur forceps, of different sizes

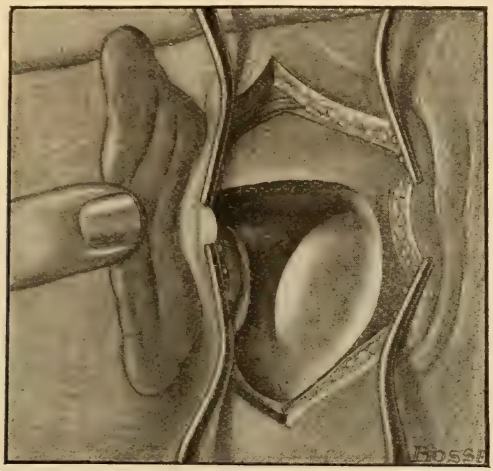

Fig. 150.—A completed simple mastoid operation.

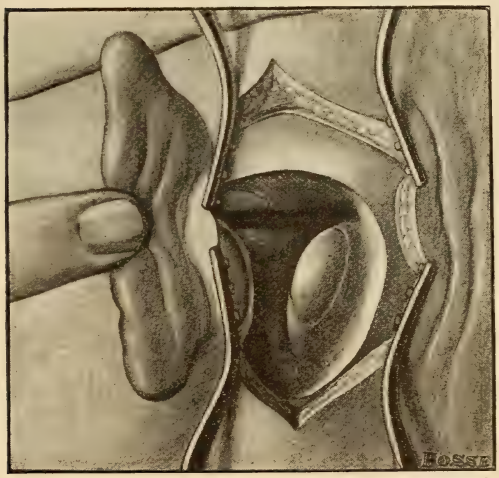

Fig. 151.—Showing (1) exposure of the dura in the region of the antrum and attic tegment, and (2) exposure of the lateral sinus.

and shapes, are necessary in order to skillfully and rapidly accomplish the desired results (Fig. 149).

A mastoid operation usually demands the removal of practically the entire cortex, together with the underlying pneumatic structures, and all the diseased bone found, until at last nothing but a healthy, firm bony area remains. Then all rough edges and

projections are to be scraped away, leaving a smooth surface (Fig. 150). The excavation is irregular in contour, extending from the tegmen above to and through the mastoid tip below and from the posterior border of the osseous canal wall backward, usually to the limit of the pneumatic cells. Only the antral orifice of the aditus should be curetted for fear of dislocating the incus.

It is difficult to positively differentiate between healthy and infected pneumatic cellular tissue; indeed, it is doubtful if all the diseased tissue is ever completely removed. The resulting wide-open space, no longer hampered by overlying diseased bone, gradually becomes covered with healthy granulations and assumes

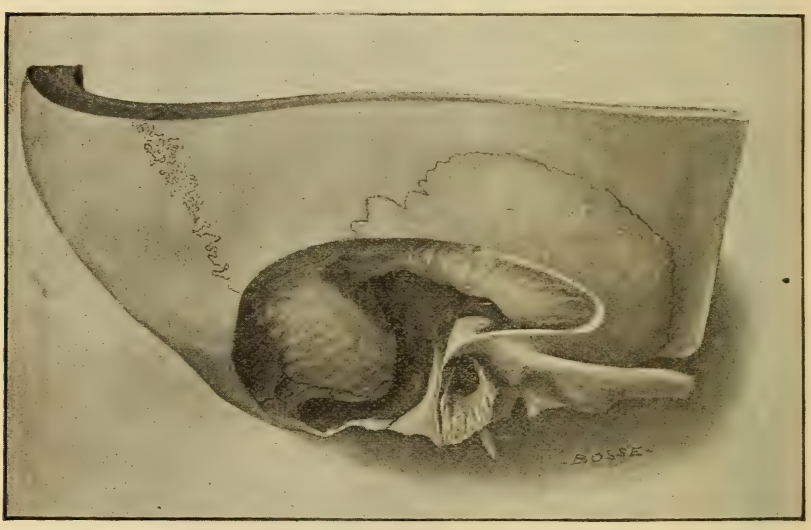

Fig. 152.—Extensive excavation of the mastoid process and the zygomatic cells, and, posteriorly, the diploë of the occipital bone. (From Dr. Wm. M. Dunning's collection.)

a normal, healthy state in response to nature's efforts to eradicate the disease.

It is quite common to find that portions of the inner table have broken down from extension of the disease, thus necessitating the exposure of the lateral sinus or the dura covering the middle cranial fossa (Fig. 151). The cells of the zygoma, being contiguous to those of the antrum and attic, are more extensive than is supposed, and are often involved, both in adults and children.

No mastoid operation is complete without a careful inspection of the cells of the root of the zygoma and the removal of all pathologic tissues found therein (Fig. 152). In broad pneumatic mastoids a comparatively enormous area of cortex is necessarily removed during the mastoid operation, the excavation often extending far forward into the zygoma and posteriorly into the occipital bone.

In an otherwise healthy individual the subject of an infection of the mastoid process following an acute purulent otitis media, the simple mastoid operation meets all the surgical requirements, providing it is not unduly delayed.



Fig. 153.—Author's portable operating table. *A*, In position, showing angles and extension of headrest and footrest. *B*, Folded for inserting into case. Weight, 29 pounds.

THE MASTOID OPERATION ON INFANTS AND YOUNG CHILDREN,

As has already been shown in Fig. 62, there is absence of the osseous meatus and mastoid cells at birth; therefore, the mastoid antrum and the tympanic cavity are nearer to the surface of the skull. Consequently the landmarks which serve as a guide to the mastoid antrum in the adult are somewhat different in the child. Here the lower border of the root of the zygoma may be used as a guide to the upper level of the mastoid antrum. In conformity with the undeveloped mastoid at this age, the emergence of the facial nerve from the skull and its course downward is extremely superficial, which necessitates considerable care in making the

primary incision for the mastoid operation. In all cases the site of the incision should be at least one-fourth of an inch posterior to the auricular attachment. It is important that the pressure upon the knife during the incision should be under perfect control in order to prevent possible injury to the deeper structures, which are sometimes extremely soft. Fortunately, in a large proportion of the cases of acute mastoiditis in infants there is perforation of the external table, from which point the excavating is easily conducted

Fig. 154.—Author's complete sterilized outfit, covering all necessary paraphernalia for the mastoid operation, except instruments. Rubber cap, half sheet, two dozen towels, three gowns, two cotton caps, gauze wipes, absorbent cotton, plain gauze packing, iodoform packing, bandages, green soap, bichlorid tablets, adrenalin, alcohol, ether, collodion, two nailbrushes, pus basin.

by means of a curet or small rongeur forceps. As a rule the small "spongy spot," which in the adult occupies the space immediately posterior to the spine of Henle, is visible.

While there are few or no mastoid cells in very young children, the diseased space usually covers a considerable area, both in depth and width. In infants the mastoid antrum should not be curetted on account of the possible separation and removal of the incus.

The Operative Findings During Simple Mastoidectomy.—In typical cases of acute mastoiditis, upon opening the cortex over

the mastoid antrum, pus will exude, and sometimes under pressure. If the operation is performed at a very early stage, the interior of the mastoid process will appear intensely engorged and hemorrhage will be profuse.

At this stage the disease may not extend far beyond the confines of the antrum. As a rule the freer the drainage through the

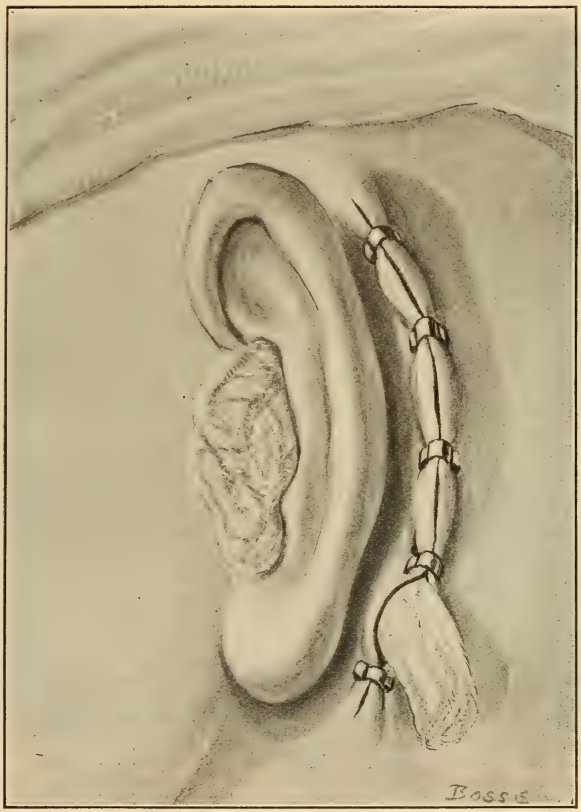

Fig. 155.—The mastoid wound packed with gauze and sutured with Michel clamp sutures.

external auditory canal, the less will be the quantity of pus in the mastoid cells. There are exceptions to this rule in cases where operation has been delayed until the walls of the cells have broken down and coalesced into large cavities, which are then found filled with pus and granulation tissue. When the pus wells up in large quantities, flows copiously and pulsation is observed, strong indication is thereby given that the internal table has broken down, with exposure of the lateral sinus or meninges.

Whiting has emphasized this symptom. So long as the purulent process is confined to the bony structures of the interior of

the mastoid process, even though the inner table has broken down, thereby exposing the lateral sinus or meninges, there is but slight danger of further extension to these structures, provided they have resisted infection up to this time and are further freed from all overlying infected bone. If the exposed surfaces of the meninges or lateral sinus are covered with healthy granulations, these should never be scraped away, as they furnish abundant indication that

Fig. 156.—First step in applying the mastoid bandage.

nature has already thrown out a safety barrier against the further progress of the disease.

The completed surgery of the bone usually reveals the dense surface of the external semicircular canal (Fig. 150). The facial nerve (Fig. 241), which normally lies well within the inner table, is rarely encountered except when the disease has attacked this portion of the bony structure of the mastoid.

In removing diseased bone which lies directly over the digastric muscle considerable care is necessary to avoid injuring the facial nerve at this point.

Cholesteatomata are found in cases of acute mastoiditis only when the acute mastoiditis occurs in conjunction with chronic purulent otitis media.

It is sometimes inexpedient to remove a patient suffering from mastoiditis to a hospital or sanatorium for operation. Under these circumstances it often becomes necessary to improvise an operating table from one or two small tables, which may be protected with sterile sheets. In order to meet emergencies of this kind the author has devised a portable operating table (Fig. 153), which may be folded and placed in a suitable case and transferred in an ordinary cab. He also keeps on hand, and ready for any emer-

Fig. 157.—The completed mastoid bandage.

gency, a sterile outfit of all the necessary materials required during the mastoid operation. They are enumerated in Fig. 154. In addition a small portable sterilizer which can be heated by an alcohol burner is requisite when operating at a patient's home or in a hotel.

Upon the completion of the operation all bleeding vessels should be twisted or tied, and the wound in the soft tissues made smooth by the removal of loose fibres of muscle or periosteum. The entire wound should then be irrigated with hot normal salt solution. Many operators precede the irrigation by filling the wound with peroxide of hydrogen. After irrigation the entire cavity is wiped dry with sterile gauze and lightly packed with 1-inch sterile iodoform gauze, up to the borders of the bone ex-

cavation (Fig. 155). In packing it is important that any exposed areas of dura or lateral sinus be covered with small sections of the gauze before packing the remainder of the wound cavity.

A major portion of the wound should then be stitched from above downwards either by means of Michel clamp sutures (Fig. 155) or silk worm gut. A stay suture may be taken at the extreme lower end of the primary incision, leaving sufficient room only for the subsequent withdrawal of the primary packing. When a posterior incision has been necessary, it should be completely sutured at the completion of the operation.

The dressing is completed by applying gauze wipes, which are

Fig. 158.—The double mastoid bandage.

shaped in a manner to protect both the ear and the wound. Usually one piece is shaped to fit the space posterior to the concha; another is placed in front of the ear, and two or three more are applied over the entire area and the bandage is then applied.

In the first step of applying the mastoid bandage the outside dressings are anchored into position (Fig. 156). Having secured the dressings, the bandaging is carried out somewhat by the figure-of-eight method until the dressings are completely covered, leaving a smooth outer surface which does not become detached (Fig. 157). This method of bandaging the mastoid originated in the Manhattan Eye and Ear Hospital.

In the event of the performance of a double mastoid operation, the bandage is applied over both ears in a manner somewhat similar to that described above for the single operation (Fig. 158).

The Blood-clot Method of After-treatment.—Blake and others have advocated the use of the blood-clot method of closing the

mastoid wound. This consists in allowing the bone cavity of the wound to become filled with fresh blood which has oozed from the exposed blood-vessels therein. The external wound is then completely closed by means of a silver-wire suture subcutaneously applied. The wound is then covered by several sheets of sterile silver foil with a top dressing of several layers of dry sterile gauze, hoping thereby to obtain union by primary intention, and to secure an organized blood-clot within which will not break down or suppurate. Unfortunately the results of this method of closing the mastoid wound have not seemed to warrant its general employ-

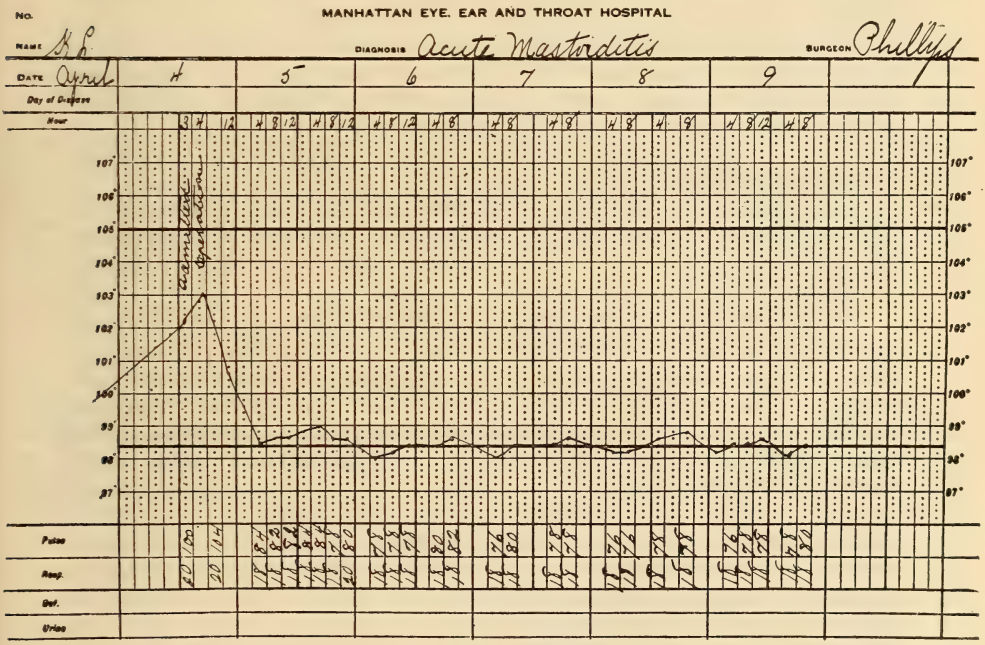

Fig. 159.—Postoperative temperature curve, showing continuous flat temperature.

ment. When successful, the wound should be completely healed and the middle ear dry and free from pus in from seven to fourteen days.

The indications that a retained clot is disintegrated are fever, the appearance of excessive aural discharge, foul odor and oozing of pus between the stitches in the external wound. The advent of these symptoms renders it necessary to open up the external wound, to cleanse its interior, and to complete the treatment of the case by the open method. By closing the postauricular wound with Michel's clamp sutures (Fig. 214), the possible danger of contaminating the wound from stitches is eliminated.

After-treatment of the Mastoid Wound.—The patient having been returned to his bed is given the usual postoperative treatment

in order to combat the effects of shock and aid in the recovery from the anesthetic. A warm bed, hot-water bags to the extremities, and small doses of hot water to relieve nausea are all useful. When the loss of blood is considerable or shock is evident, or in patients who have been weakened by prolonged infection or some general disease, great benefit is obtained from large high enemas of hot normal salt solution. In the absence of complications the first dressing may be permitted to remain in place for four or five days; thereafter it is changed every second day or daily as the case may demand. In uncomplicated cases the wound should not be repacked by gauze or other dressings. It is sufficient to maintain drainage by simply introducing a folded piece of sterile rubber tissue or a cigarette drain. It has been proven that this procedure is sufficient to maintain drainage while the absence of packing permits the tissues to contract and adhere. Whenever a wide exposure of the dura or sinus has taken place it is advisable to keep the mastoid wound wider open for a few days by means of the proper gauze packing.

Excessive granulations are clipped with scissors or checked by applications of silver nitrate; indolent granulations stimulated by the application of balsam of Peru and castor oil in equal parts, or by packing with iodoform gauze.

Postoperative Temperature.—Following the simple mastoid operation for mastoiditis there is usually a sharp rise of temperature. Harris, who made a study of 100 cases of postmastoidal temperature, has shown that this rise is due to absorption from the wound surfaces. The temperature gradually rises as high as it was before operation, but rarely higher. It persists for some days, usually dropping toward the end of the second day after operation. In rare cases it may persist for some days longer. This rise of temperature is usually without significance, but its persistence demands a close supervision to recognize the advent of local or intracranial complications. Figs. 159, 160 and 161 are appended in order to show the usual postoperative temperature curves following the simple mastoid operation. In Fig. 159 the chart shows a continuous flat temperature from the date of the operation. The chart in Fig. 160 represents the more common type of postoperative temperature wherein there is a rise of tempreature the day following the operation, and a gradual daily decline until a flat temperature is reached at the fourth or fifth day. The postoperative temperature curve in Fig. 161 is a more rare occurrence in which a secondary elevation is caused by infection elsewhere, or by some complication. In this case mastoiditis developed in the opposite ear coincident with the second rise of temperature.

Complications of the Mastoid Wound.—Local infections involving the mastoid wound may develop at any time subsequent to the operation.

The chief varieties of wound infection are stitch abscesses, local abscesses in the surrounding tissues, iodoform dermatitis, and erysipelas.

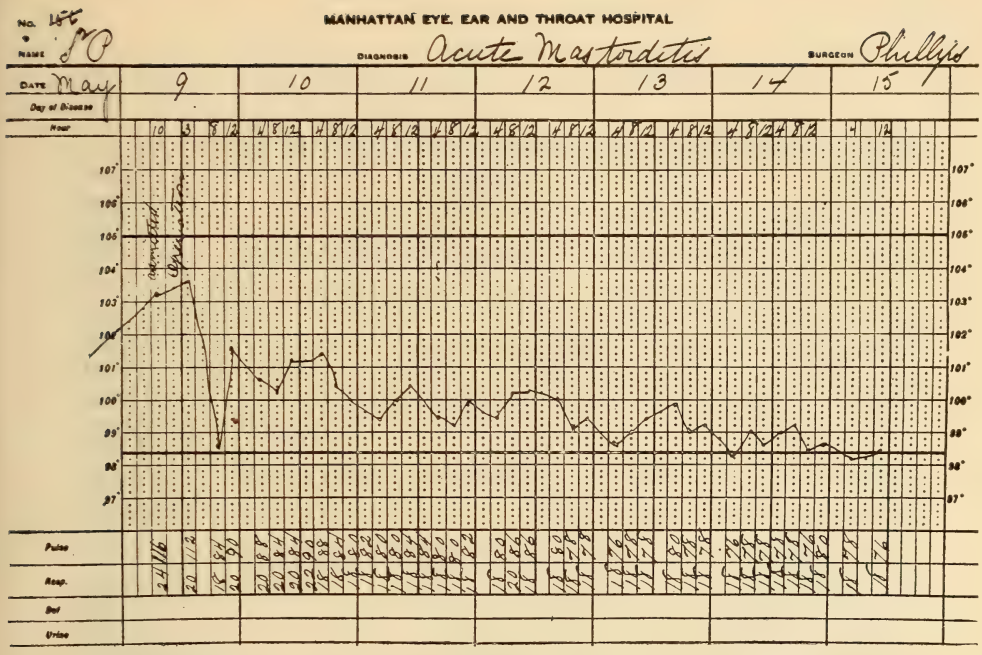

Fig. 160.—Temperature chart, illustrating postoperative elevation of temperature, which gradually declines to normal.

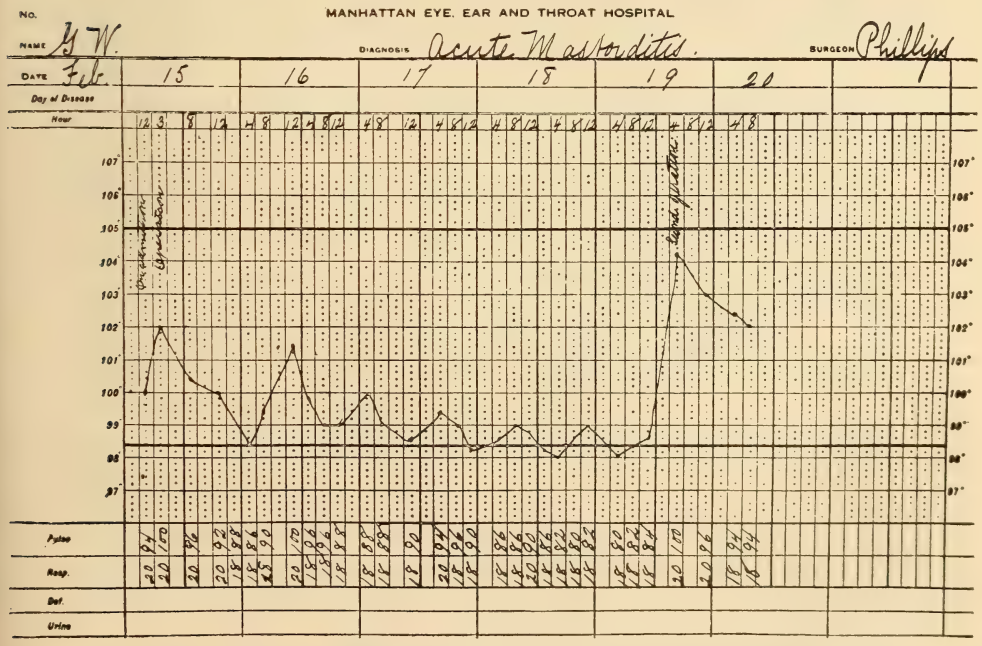

Fig. 161.—Temperature chart, showing the usual postoperative rise in temperature on the day following the operation, with a gradual decline until the fifth day and a sharp rise to 103.4° on the fifth day, the result of an attack of mastoiditis in the opposite ear.

These complications are for the most part due to surface infection from the outflow of pus and the contact of scrapings during the operation upon the bone. Stitches should be immediately removed upon the first appearance of pus, and larger abscesses are to be incised and washed out or treated by swabbing with pure carbolic acid, followed almost immediately by swabbing with absolute alcohol. The latter is employed in order to limit the action of the carbolic acid. Simple dermatitis is best treated by wet bichlorid of mercury dressings, or dressings which are constantly kept moist with Burrows's solution. Erysipelas (see Chapter XXXII) is the most serious of the wound complications.

Results.—The simple mastoid operation when employed in suitable cases, and previous to the advent of serious complications, yields brilliant results and ranks high among the life-saving surgical measures known to medicine. Not only does it cure the disease, but when skillfully performed and with its after-treatment properly carried out, it restores to normal functional activity the affected ear. The mortality from the operation *per se* is so extremely low in comparison with that of the disease when allowed to terminate without operation that one can hardly understand why any opposition to its employment should ever arise. The small percentage of deaths which follow the operation are usually from some complication, intracranial in nature, upon which the operation itself has no bearing, but is of benefit, inasmuch as it affords one step toward their cure.

CHAPTER XXI.

DISEASES OF THE MIDDLE EAR.

(*Continued.*)

CHRONIC PURULENT OTITIS MEDIA.

Synonym.—Chronic suppuration of the middle ear.

Definition.—Chronic purulent otitis media is characterized by a chronic inflammatory process arising from various pathological lesions which involve one or more areas of the mucosa and the bony structures which comprise the middle ear, the most common symptom of which is otorrhea.

Pathology.—There are divers elements to be considered in discussing the pathology of chronic middle-ear suppurations, otitis media purulenta chronica being a general clinical term under which we group the various pathological lesions.

1. Changes in the Mucous Membrane.—The mucous membrane lining the tympanic cavity and its neighboring cells, the aditus, the mastoid antrum and the mastoid cells, primarily undergoes changes which at first present the characteristics usually observed in acute purulent inflammations. At the commencement there is a distinct hyperemia of the mucosa, accompanied by a small round-celled infiltrate. As the disease progresses new connective-tissue elements are added, which serve to establish the chronicity of the disease as far as the mucous membrane is concerned.

The hyperemia now subsides and the membrane assumes a paler or grayish color. The extensions of the disease within the mucosa are marked by the appearance of excrescences at places, and these in turn become true granulations (Fig. 162). The granulations may take upon themselves distinct characteristics so as to become recognized clinically as aural polypi. From their histological aspect Steinbrügge[1] classifies them as (*a*) granulations of mucous or round-cell type; (*b*) fibromata; (*c*) myxomata. They may vary in size from being scarcely perceptible to large masses which completely fill the tympanic cavity and protrude beyond the perforated drumhead into the external auditory meatus, occasionally appearing at its outer orifice.

Since the entire mucous membrane is affected by the pathologic lesion, the site from which polypi may arise is extremely variable. They may spring from any portion of the interior of the tympanic cavity, even from the tegmen or interior of the mastoid process (Figs. 163 and 179). They may spring from the borders of the perforated drum membrane, and more rarely the site of origin is in some portion of the external auditory canal.

[1] Lehrbuch der Ohrenheilkunde, by von Troltsch, 3d edition.

Aural polypi may be single or multiple (Figs. 165 and 179). They vary in consistence from extreme softness to the hardness of a fibroma. Sometimes they are cystic. The surface of the polypus may vary from the oval smooth variety to those which are distinctly lobulated, and microscopically they show all the transient changes from simple epithelium to pavement epithelium. According to Brühl,[2] aural polypi contain more than 78 per cent. of granulation tissue.

In themselves, aural polypi give no symptoms except occasionally when they may cause hemorrhagic discoloration of the aural discharge, or when they have attained sufficient size to impair the hearing or to impede drainage from the middle ear, in which event aural pain may ensue.

The chief significance of aural polypi lies in the fact that they usually indicate a bone lesion in some portion of the middle ear or its adnexa.

The diagnosis of polypi is never difficult. They must be differentiated from congested, bulging drum membranes. The use of the probe, which when skillfully handled can be made to pass around the growth, settles the diagnosis. The motility of the polypi is thus also determined and very often the site of origin defined. On the contrary, an inflamed and bulging membrana tympani, with the accompanying symptoms of an acute middle-ear inflammation—notably the otalgia—help to determine the diagnosis.

Sometimes the inner tympanic wall is mistaken for a polypus, especially when there has been complete destruction of the drumhead and exfoliation of the ossicles. The employment of the probe demonstrates that the suspected area is of bony hardness; furthermore, Eustachian inflation evokes the characteristic auscultatory sound of a large perforation and thereby proves the absence of a large polypus.

Aural polypi are commonly observed in connection with perforations of the drumhead which extend into Shrapnell's membrane, and also in cases which present perforations marginally situated (Fig. 164).

The next element entering into the pathology of otitis media purulenta chronica is the *ingrowth of epithelium* from the derma of the external auditory canal. The drumhead having been perforated, and the continued otorrhea having gradually enlarged this perforation to a variable extent, the epidermis either from the external layer of the drumhead, or, if the latter is nearly destroyed, from the walls of the external auditory meatus, gradually advances inward through the perforation and grows over the mucous membrane of the tympanic cavity. The dermatized areas are often visible. The microscopic examination of the mucous membrane of the tympanic cavity shows at the completion of this stage of the disease the characteristics of the adjacent derma which lines the external meatus. It is due to this process that centrally located perforations of long

---

[2] Archives of Otology, vol. xxx.

standing occasionally become closed, the derma meeting and sealing the perforation. When the drumhead is very much retracted this process is also the factor which causes it to become adherent to the promontory, through the spreading of the derma from the edges of the perforation to the promontory, thus binding the promontory and drum to each other. When the perforation is marginally located the spread of epidermis is directly from the external auditory canal wall and the ingrowth is of greater vitality. Dependent on the site of the perforation, the inward advancing epidermis may enter the epitympanic space or the lower part of the tympanic cavity. From a perforation in Shrapnell's membrane the epidermis may effect entrance to the aditus, eventually reach the mastoid antrum and portions of the mastoid process.

This process has been known clinically as the formation of *cholesteatoma.* The ingrowth does not proceed smoothly, but in many

Fig. 162.—Large granulations involving the intratympanic mucosa.



Fig. 163.—Showing an aural polypus projecting through a perforation in the drum membrane.

Fig. 164. — Polypus protruding from a perforation in Shrapnell's membrane.

places dies off, and the exfoliated epidermis is retained as foreign matter and promotes irritation and aggravates the otorrhea. The retained secretions are prone to putrefy as a result of the admixture of pus, exfoliated epithelium and infection by an endless variety of micro-organisms.

While from a pathological standpoint the ingrowth of epidermis is regarded as a process by which nature attempts to cause healing (Boenninghaus), yet clinically this process, for reasons, some of which are given above, may cause symptoms requiring radical removal of the contents of the tympanic cavity and the mastoid process, in order to establish a wide-open intratympanic space. This especially is true when the newly formed epidermis desquamates to any degree, inasmuch as the admixture of pus from the original site of the disease, and the desquamated epidermis, cause the putrid condition so often found upon operation in cases of cholesteatoma. Furthermore, even when apparently there is free drainage, the pressure exerted by the masses of exfoliated epidermis, and the progressive ingrowth of epithelium, causes absorption of the bony parts upon which this pseudo-new growth is exerting pressure, and the operative findings in some of these cases show great destruction of anatomical structures from this cause.

If the pus foci now become more active within the middle-ear spaces, the dry masses of epidermis gather and gradually take on very large dimensions, and likewise exert pressure and produce bone absorption. This latter condition is designated pseudo-cholesteatoma.

2. Changes in the Bone.—In chronic purulent otitis media the bone lesions observed pathologically, but more especially upon the operating table, are as follows: 1. Caries and necrosis. 2. Sclerosis (eburnation). 3. Pressure atrophy. 4. Rarefaction of the bone.

Necrosis and caries of the ossicles and tympanic walls due to bacterial action and the resultant changes in the mucous membrane, through which the blood-supply of the bone is affected, is frequently observed in cases of chronic purulent otitis media. The same causes, operating to produce changes in the mucous membrane, are factors in the production of the necrosis or caries. Tuberculous and syphilitic infection play a prominent rôle in the production of caries of the ossicles and temporal bone. The nutrient blood-vessels gradually become obliterated and, in turn, the bone dies, while during the entire process of its disintegration the otorrhea continues.

The caries or necrosis may be confined to the ossicular chain, but, as a rule, this process also involves the tympanic ring (annulus tympanicus) and other portions of the tympanic walls (Fig. 165). In the more severe types the necrotic process extends through the aditus, to the mastoid antrum and the mastoid cells. Even the inner cranial table and the labyrinth are not exempt, and herein lies one of the dangers of this disease.

Exfoliation of the necrosed areas of bone usually occurs in the form of minute masses which flow away in the discharge; but occasionally large sequestra from the mastoid, the squamous or petrous portions of the temporal bone separate, but remain as foreign bodies until removed by surgical methods (Fig. 73).

Sclerosis (eburnation).—This process is almost always observed in cases of long-standing otitis media purulenta chronica. The pneumatic cells and the Haversian canals in the bone become replaced by compact osseous tissue, which eventually becomes hard and of the consistency of ivory. According to Körner, the process of eburnation usually begins at the periphery of the mastoid, and in the course of years eventually reaches the interior, even to the mastoid antrum, and thus the entire mastoid process becomes converted into compact, eburnated bone. Sometimes, here and there, throughout this compact mass, there are large or smaller spaces, where the original bony structure is preserved; or, more likely, there are purulent tracts running through the sclerosed bone.

The process of eburnation is regarded by many as a reaction of the healthy bone to the irritants of the disease, and, but for certain factors hereinafter described, would be a process which we would not disturb. But because of the tracts of purulent disease which run in irregular channels through it, and the likelihood of one or other of these being shut off externally by the advance of

eburnation, there is a tendency created to force the purulent foci to advance toward the interior; hence, the process of eburnation introduces a very troublesome factor into the treatment of chronic purulent otitis media.

Furthermore, since observation has verified the fact that eburnation takes place from the cortex of the mastoid process, and since it advances mesially, rarely occurring along the tegmen cellulæ, tegmen tympani or tegmen antri, it is an etiological factor in the invasion of the cranial cavity by the purulent disease originally located in the middle-ear spaces.

Pressure Atrophy.—In the discussion above of the ingrowth of epidermis, we showed how the gradual increase in size of the cholesteatomatous masses within the middle ear, by exerting pressure on the surrounding bony structure, caused the bone to become absorbed.

In examining cases where the process has not been of too long duration, this atrophy or absorption of bone is very evident. Large or smaller holes are observed in the mastoid process, and Boenninghaus claims that in cases of long duration the entire mastoid process and temporal pyramid may become excavated under the cortex. In such cases if the cortex eventually becomes perforated, then the fistulous tract leads to this cavity, which is entirely enclosed by bony walls. An analogy to this process in general pathology is found in cases of aneurism of the aorta when it presses against the posterior bony thoracic wall and causes bony absorption of these walls. (Boenninghaus.)

Rarefaction of Bone.—This process is quite distinct from the bone atrophy and absorption described above. It simulates the lesion usually found in acute mastoiditis and pathologically is a disease of the bone designated *ostitis rareficans simplex.* The lesion is often found in the immediate vicinity of the antrum and tympanic cavity, and is usually surrounded by eburnation. The line of demarkation between the eburnated portion and the rarefied parts is demonstrable. The rarefied bone is extremely soft and usually of a brownish color. Usually all the walls of the antrum are involved, but occasionally this process extends in a definite tract toward the sulcus sigmoideus, or toward the tegmen.

The upper portion of the bony posterior wall of the external auditory canal is a frequent seat of this lesion, and the necrosis or caries of the malleus and incus is generally the result of this pathologic lesion.

3. New Growths.—It is not our purpose in this connection to describe the pathology of neoplasms of the middle ear and mastoid process. The classification of middle-ear lesions which produce otorrhea, and the train of symptoms which we classify as otitis media purulenta, would not be complete were we to overlook the fact that the growth of neoplasms, both benign or malignant, is capable of producing otitis media purulenta chronica.

The development of a carcinoma or a sarcoma within the tympanic cavity or mastoid process would, by its advance, cause

bone absorption and by its desquamation and exfoliated detritus produce otorrhea. The use of the probe, the history of the case and the involvement of the neighboring glands serve to complete the clinical picture of these growths. For a description of neoplasms of the ear the reader is referred to Chapter XIII.

Etiology.—An attack of acute purulent otitis media or a succession of such attacks in which the disease is allowed to progress unaided by the established principles of treatment (see Chapter XVIII) constitutes the chief cause of chronic suppuration of the middle ear.

In otherwise healthy individuals an attack of acute purulent otitis media, even when resulting from some infection of virulent type, should terminate in recovery in from three days to five weeks, providing the patient is the subject of proper care and is skillfully treated according to modern methods, and that purulent mastoiditis does not supervene.

The fact that so large a proportion of all patients who suffer from chronic otorrhea are able to associate its commencement with an attack of diphtheria, measles, scarlet fever, typhoid fever or other grave infections gives emphasis to the etiological relation which these diseases bear to purulent otitis media (see Chapters XXXI and XXXII).

The deleterious effects of general infections upon the ear are due to the virulence of their characteristic micro-organisms (see Chapter V), combined with the physical exhaustion and consequent lowered resisting power which follows such attacks. It is probable that a considerable proportion of all cases of chronic purulent otitis media have been the victims, during the time of the primary attack of a complicating acute mastoiditis, from which recovery has taken place without operation, but with a persistent offensive discharge, loss of hearing and all the dangers which attend a chronic purulent necrotic process in the temporal bone.

In every case of this type a simple mastoid operation (see Chapter XIX), promptly and timely performed, would, in the majority of cases, prevent these serious sequelæ, and preserve the hearing.

Age is no barrier to this disease, but in a large proportion of all cases the disease commences during childhood. General constitutional diseases predispose both to cause and prolong chronic otorrhea.

Thus tuberculosis, syphilis, malignant growths as well as diabetes are factors which tend to prolong middle-ear suppuration and induce chronicity.

It has heretofore been asserted as an invariable rule (Chapter XVIII) that recurrent attacks of otorrhea in children are indicative of the presence of adenoids and hypertrophied tonsils. The same rule applies equally to chronic otorrhea occurring in young children, while in older individuals any form of obstruction to nasal respiration, and especially new growths and purulent affections of

the nasal accessory sinuses show a marked tendency to prolong a purulent otitis media beyond the acute stage.

The exact point of time when an acute purulent otitis media becomes chronic is not clearly definable clinically. The persistence of an otorrhea beyond eight to twelve weeks is by common consent regarded as chronic. In any case wherein, as a result of some constitutional dyscrasia combined with a severe type of infection, the pathologic lesions characteristic of chronic purulent otitis media are quickly produced, it is possible for the disease to show signs of chronicity almost from the beginning. This is especially true in tuberculous and syphilitic patients, and to a less degree in those who suffer from diabetes, or who are ill nourished and anemic from bad hygiene, exposure, serious illness or lack of sufficient oxygen as a result of adenoids and hypertrophied tonsils.

Symptoms and Course.—The various pathologic processes which are the known causative factors of otitis media purulenta chronica are productive of certain symptoms the chief of which are otorrhea, progressive loss of hearing and tinnitus. Such symptoms as pain, vertigo, nausea, nystagmus and facial paralysis are usually indications of complicating lesions and are hereinafter described under appropriate headings.

Otorrhea.—The most persistent symptom associated with chronic purulent otitis media is the aural discharge. It may be continuous and exceedingly profuse or intermittent and scanty. When profuse (otopyorrhea) it flows freely from the external meatus, and if tampons of absorbent cotton are constantly worn the pledgets soon become soaked with the secretion and require changing several times each day. When no absorbent cotton is worn the patient is obliged to wipe out the external canal at frequent intervals.

When scant in quantity the discharge may be perceptible only as moisture in the canal, or not be observed save on otoscopic examination. In this type of otorrhea the minute quantity tends to adhere about the borders of the perforation, and finally to form inspissated masses which may fill the fundus of the canal. The removal of the crusts is usually followed for a short time by a perceptible otorrhea.

This type of the disease is often mistakably described as intermittent otorrhea. It is quite common for the ignorant or neglectful mothers of children who have chronic otorrhea to allow the pus to flow and accumulate about the external ear and remain undisturbed until a dermatitis of the auricle results from the irritation of the discharge.

The secretion from the middle ear may be purulent, mucopurulent or be composed of an admixture of pus, blood, disintegrated bone, epidermis or cerumen. If of long standing, especially when treatment has been neglected, the discharge emits a fetid odor. The latter is characteristic of caries or necrosis of the bone.

Odor also is common in cholesteatomatous otorrhea. The latter is peculiarly offensive but quite unlike the carrion-like odor which is observed when there is an extensive necrosis of the bones. A large

proportion of those who are afflicted with chronic purulent otitis media evince but little anxiety in regard to the gravity of the disease, and look upon it as a trivial though troublesome malady. They seek treatment solely in order to overcome the odor, the necessity for daily cleansing of the meatus, and the wearing of absorbent cotton in the ear. Mucoid discharge is more common when the disease is confined to the Eustachian tube and the portions of the mucosa surrounding its tympanic orifice. In this type of the disease the perforations in the drumhead are usually in the lower quadrant.

The appearance of blood in the aural discharge is indicative of granulations or polypi, the blood-vessels of which are numerous and have thin walls.

The loss of hearing varies with the progress of the disease, and the location of the pathological lesions. There may be extensive

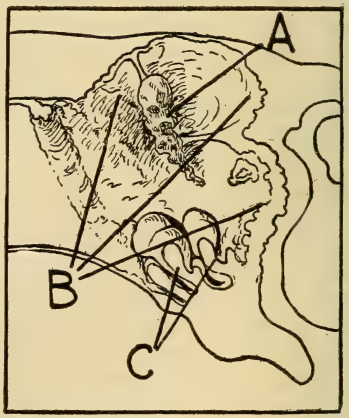

Fig. 165.—Lateral view, partly schematic, with key plate, (*A*) showing extensive caries of the ossicles (*B*) and walls of the tympanum (*C*) and much granulation tissue.

involvement of both the mucosa and bony walls, but so long as the stapes and oval window escape and other labyrinthine complications do not occur the hearing may remain good. The loss of hearing may be imperceptible to the patient for all practical purposes, or it may have reached any intermediate stage, even to a high degree of deafness.

It is quite common for children who have lost the drum membrane, malleus and incus to retain sufficient hearing to enable them to attend school and receive instruction with but little inconvenience. On the other hand, the disease may be so violent and destructive as to destroy the hearing entirely and cause deafmutism. (See Chapter XXVIII.)

The degree of persistence of tinnitus also is variable, some patients not complaining of this symptom at all, while in others it constitutes the most distressing symptom for which they seek relief. Tinnitus is neither so persistent nor distressing as that which occurs in non-suppurative middle-ear and labyrinthine affections. Violent

tinnitus, especially when accompanied by vertigo and nausea, is an indication of labyrinthine involvement.

The three symptoms described above—viz., otorrhea, hardness of hearing and tinnitus—constitute the symptom-complex of otitis media purulenta chronica. The symptoms change upon the advent of complications. Of the occasional symptoms which accompany chronic purulent otitis media pain is the most common. The pain is often caused by a furunculosis of the external auditory canal (Fig. 68); or it may result from pus retention in the middle ear, brought on by the growth of polypi (Fig. 164), or as a result of imperfect drainage from any cause.

Furthermore, pain in otitis media purulenta chronica may result from the swelling of cholesteatomatous masses in the middle ear. It is also a characteristic symptom of eburnation of the cells of the mastoid process.

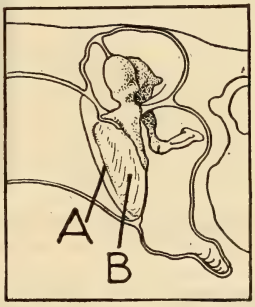

Fig. 166.—Lateral view of the tympanic cavity, with key plate, partly schematic, showing (*A*) the outline of a large perforation in the drum membrane, which has healed by the formation of (*B*) scar tissue.

Finally, when the disease involves the periosteum—that is, causes a periostitis (Fig. 125), or when the intracranial structures become involved, pain becomes a prominent symptom.

Another symptom which becomes prominent when complications threaten is vertigo. Dizziness, as we shall see under the appropriate chapters, is indicative of labyrinthine or intracranial involvement. The symptoms characteristic of acute mastoiditis, sinus-thrombosis and intracranial lesions are likewise appropriately described in the chapters under their respective headings.

Course.—The pathologic lesion causing otitis media purulenta chronica may be terminated surgically or by local treatment or the disease may run its course through the entire life of the patient. When terminated by whatever means, except surgically, the perforation in the drum may become covered by scar tissue (Fig. 166) and the lesion shut off by connective tissue (Fig. 166), or by being covered by epidermis. On the other hand a large perforation in the drumhead may persist and its borders become covered by epidermis or scar tissue, and, furthermore, the exposed mucous membrane of the tympanic cavity may become dermatized and the suppurative

process reach a standstill. Old perforation scars are prone to become the seat of calcareous deposits or plaques (Fig. 113).

The disease may become quiescent for a longer or a shorter time, to start up again, following a "cold," an attack of grippe, or one of the exanthemata. The recurrence of suppuration is especially marked in those with nasal obstruction and adenoid vegetations.

Finally, the disease may persist through life, without mastoid, intracranial or labyrinthine complications; or at any time these lesions may appear with serious consequences.

The most common complication of chronic purulent otitis media is an acute exacerbation of the disease, or an acute purulent mastoiditis superimposed upon the chronic middle-ear suppuration. Other complications are those which result in involvement of the dura mater, the brain or the labyrinth.

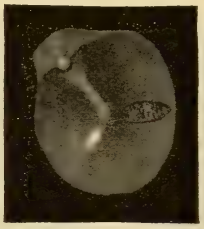

Fig. 167.—Showing perforation in the drum membrane, which has healed over by connective tissue, leaving a permanent scar.

Diagnosis.—*A priori* it may be asserted that a chronic discharge from the ear usually emanates from the middle-ear spaces. Otoscopically, this is manifested more positively when we note the pus flowing from the middle-ear spaces through the perforation in the drumhead. The pulsation sometimes seen in the otoscopic picture is less frequently observed in chronic otorrhea than in the acute form of the disease; yet as a diagnostic sign that the pus emanates from the middle ear this symptom must be remembered.

Exact diagnosis that the chronic otorrhea is due to a suppuration within the tympanic cavity depends upon seeing the perforation in the membrana tympani, and the observation of pus coming through the perforation. Exostosis of the external auditory canal, furunculosis and all other lesions of the external auditory canal must be excluded.

There are certain obstacles which tend to obscure the inspection of the drumhead. Chief among these are exostoses of the external auditory canal walls (Fig. 97), tumors (Fig. 67), or polypi (Fig. 179), which occlude the canal lumen and prevent a distinct view of the drum. The outlines of perforations often become obscured by masses of exfoliated cholesteatoma or inspissated pus. In doubtful cases the use of the Eustachian catheter, whereby the auscultation sound of a perforation is obtainable, helps to clear the mooted point.

Boenninghaus recommends, in cases where there is doubt as to the presence of a perforation even after inflation, that the end of the auscultation tube be immersed in a glass of water and the inflation

repeated. If a perforation emits air which escapes into the auditory canal and thence into the auscultation tube, it will escape through the water and cause bubbles.

The employment of a probe, tipped with cotton, will show moisture in cases where the secretions are scant and scarcely discernible to the eye, and the use of the Siegel otoscope in disturbing the secretions is also of service in rendering a diagnosis.

The diagnosis of the ingrowth of epidermis, or rather the presence of cholesteatomata, depends usually upon obtaining the epidermis scales in the examination of the ear discharge. The pus is usually of a very foul odor, and the flakes are more particularly to be seen in the region of Shrapnell's membrane, from which they may be loosened by the use of a probe or ring curet. The dry or pseudo-cholesteatoma is usually diagnosticated by a

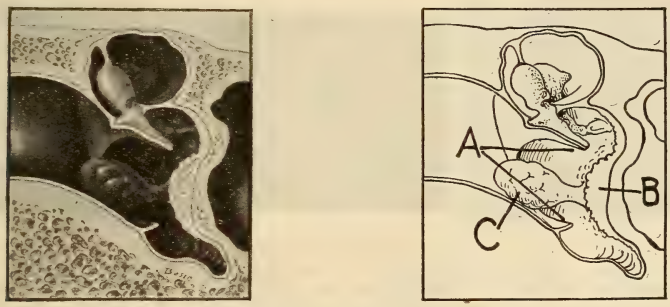

Fig. 168.—Lateral view of tympanic cavity, with key plate, partly schematic view, showing (*A*) large perforation in drumhead, (*B*) necrosis of promontory and (*C*) large polypus protruding into the external auditory canal.

microscopical examination of the scales obtained from the canal. Caries and necrosis of the malleus (Fig. 172), and sometimes a large sequestra lying in the middle-ear space may be visible to the eye, but a positive diagnosis depends upon a skillful use of the probe. The Hartmann probe (Fig. 3), being of small calibre and made of silver, is flexible and, when bent in various short curves and angles, permits the surgeon to explore a considerable area of the tympanum proper and the epitympanic space. When introduced through the perforation and manipulated in various directions, the necrosed ossicles and exposed tympanic walls can be felt as rough areas and even sequestra can both be felt and moved.

The odor from aural necrosis is carrion-like and characteristic. The presence of polypi is significant of bone necrosis (Fig. 168), especially when they recur quickly after being removed, even though the patient is under constant local treatment.

Finally, the location of the perforations in the drumhead is of considerable diagnostic significance in chronic purulent otitis media. Broadly speaking, perforations of small or medium size which are located in the drum membrane proper and which do not

impinge upon the contiguous bony structures at any point (Fig. 169) indicate that the disease is confined to the mucosa of the middle-ear spaces, and that the bone has not yet become affected.

This rule is not invariable, as in a small proportion of centrally located perforations there is found a continuous flow of foul-smelling pus and protruding granulations which bear evidence of bone necrosis.

Another type of perforation observed in cases of chronic purulent otitis media is one which involves the long process of the malleus in varying degrees. A single perforation involving the distal extremity of the malleus handle is shown in Fig. 170, while one of larger size with granular edges, and showing some loss of the malleus handle through necrosis is illustrated in Fig. 171.



Fig. 169.—Perforation of the drum membrane which does not impinge upon the bony structures of the middle ear.



Fig. 170.—Small perforation at the umbo. The distal end of the malleus handle is exposed and necrotic.



Fig. 171.—Perforation of large size in central portion of the drumhead. The edges are granular and the tip end of the malleus handle has sloughed away.

In a third type of perforations the destruction of the drumhead is extensive, with more or less complete loss of the ossicles from necrosis (Figs. 172 and 173). In these cases the visible necrosis usually represents but a small portion of the actual extent of the disease.

A fourth type may be defined as multiple perforations. These may be large (Fig. 174) or small (Fig. 175), and are, as a rule, indicative of tuberculosis or syphilis.

A fifth type, wherein the perforation is located high up within the confines of Shrapnell's membrane (Fig. 176) with destruction or visible necrosis of the ossicles, furnishes presumptive evidence of more or less extensive disease of the bony walls of the attic, aditus and mastoid antrum. These are prone to permit the ingrowth of epithelium from the external auditory canal, in which event there is added the dangers of cholesteatomata. This is considered a dangerous type of perforation on account of the extensive and far-reaching necrosis which usually accompanies it. Furthermore, perforations through Shrapnell's membrane, together with other marginal perforations, to be hereinafter considered, furnish a larger

proportion of cases requiring the radical mastoid operation than those which are centrally located.

A sixth type of perforation is that which is located at the margin of the drum membrane proper (Fig. 177), with or without the presence of protruding granulations (Fig. 163). They vary in extent and may involve any quadrant of the drumhead at its periphery. When accompanied by continuous fetid discharge, this type of perforation gives evidence not only of necrosis of the underlying bone in the immediate vicinity, but of other portions of the middle-ear spaces. The pus in chronic purulent otitis media usually contains a mixed infection, which indicates chronicity. (For the Bacteriology of Middle-ear Discharges see Chapter V.)

In conclusion, the diagnosis of chronic purulent otitis media is based upon:—

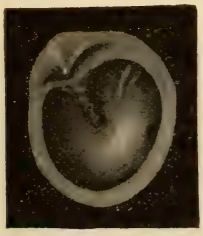

Fig. 172.—Loss of the entire central portion of the drum membrane and small portion of the membrana flaccida. The malleus handle is necrotic and the incus is destroyed.

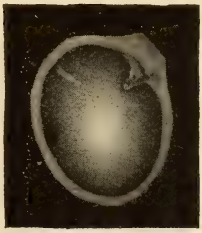

Fig. 173.—Almost entire absence of the drumhead proper and the membrana flaccida. The entire incus and nearly the entire malleus have succumbed to the necrotic process. The stapes remains intact, and the round window is visible.

1. A history of chronic otorrhea.

2. The otoscopic findings: (*a*) Pus in the external auditory canal and tympanum. (*b*) Perforation of the drum membrane. (*c*) Granulations or polypi which spring from the walls of the middle-ear spaces. (*d*) Necrosis of the ossicles and bony walls of the middle ear, which is determined by probing and by the presence of malodorous pus.

Prognosis.—(*a*) Regarding cure of the purulent process. (*b*) Regarding improvement in the hearing. (*c*) Regarding life.

Regarding the Cure of the Lesion.—The much-to-be-desired cure of the otorrhea is always dependent upon the nature and extent of the ulceration and necrosis of the middle-ear cavities. In cases wherein the disease is localized within areas which are accessible to treatment, especially where bone necrosis is slight in extent or absent altogether, a cure of the otorrhea may be expected after a reasonably short season of local treatment. Furthermore, in those cases which have been neglected or indifferently treated, marked improvement usually follows the establishment of the local measures of treatment hereinafter described.

But necrosis, wherever located, becomes a serious obstacle to cure by local measures. When confined to the ossicles and annular ring it is sometimes possible to effect a cure after a prolonged period of local treatment, especially when aided by improved general health and consequent increased bodily resistance. Extensive necrosis with profuse malodorous discharge and proliferating granulations does not usually yield to local measures of treatment, but requires radical surgical intervention in order to eradicate the disease. Otorrhea sometimes persists even after the most skillful and painstaking radical operations, but such cases are exceptions to the general rule.

Regarding the Hearing.—It may be stated that as a general rule chronic purulent otitis media diminishes the hearing function in varying degrees. There are rare exceptions wherein a prolonged suppurative process in and about the middle-ear cavities does not

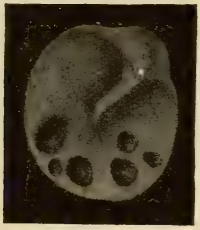

Fig. 174.—Multiple perforations in the drumhead.

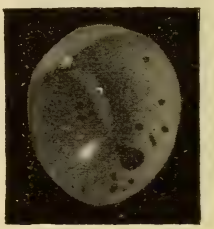

Fig. 175.—Multiple perforations in the drumhead.

result in any perceptible hearing defect. It is strange that in such cases the oval window in its relation to the stapes has entirely escaped the ravages of the disease.

Again, extensive destruction of the drum membrane may take place without loss of hearing. The necrotic process may extend even farther and destroy the malleus, the incus and portions of the annulus tympanicus, but so long as the stapes remains movable in its normal position the hearing may not become seriously impaired.

Unfortunately, the final healing of the purulent process within the middle ear is prone to eventuate in adhesions, especially around the oval and the round windows, and serious impairment of hearing. Furthermore, labyrinthine suppuration, even when recovered from, is usually followed by loss of the hearing function.

It is also true that a considerable proportion of patients who suffer from otorrhea hear better while the discharge persists than they do after the discharge has ceased. This is largely due to the ultimate thickening of the mucosa of the middle ear, to retracting cicatrices and adhesions of the ossicles.

Total deafness as a result of chronic purulent otitis media is rare. The more reliable statistics relative to the results upon the hearing in the radical operation performed for the cure of this

disease are not unfavorable in the main. In 75 cases reported by the author[3] the hearing was improved in 28, unchanged in 25, and impaired in 22.

Regarding the Life.—While the fatalities which result from chronic purulent otitis media are proportionately few in number, they occur with sufficient frequency to necessitate our classifying this disease among those which are hazardous to life. Bone necrosis is the danger signal of chronic purulent otitis media. Fatalities from this cause occur as a result of gradual extension of the necrotic process through the attic or antrum tegmen, through the labyrinth, through that portion of the inner wall of the mastoid process which covers the lateral sinus, through other portions of the mesial or cranial wall, or from softening or absorption of the bony tissues from retained cholesteatomatous masses. In this manner the infection which heretofore has remained localized within

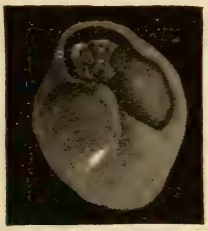

Fig. 176.—Large perforation in Shrapnell's membrane, through which the carious malleus and incus are visible. A portion of the outer wall has been destroyed from necrosis.

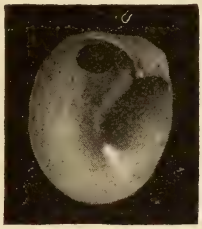

Fig. 177.—The perforation here shown is the upper posterior quadrant at the junction of the drum membrane proper with Shrapnell's membrane.

the middle-ear cavities is permitted to invade the meninges. Death is thereby caused by purulent meningitis, cerebral abscess, cerebellar abscess, or by pyemic thrombosis of the lateral sinus and internal jugular vein. Barring traumatisms and systemic infections like epidemic cerebrospinal meningitis, purulent inflammation of the middle-ear spaces remains the chief source of all intracranial infections.

Finally, as a more detailed statement of prognosis, we find the prognosis to be good, from the clinical standpoint, when the case is not of long standing and is uncomplicated by granulations, when the otorrhea is not fetid, and is mucopurulent in character. The prognosis is worse when the otorrhea is fetid, when complicated by granular excrescences or polypi, when the perforations in the drumhead are marginally situated, and when the epidermis has invaded the tympanic cavity.

Treatment.—The treatment of chronic purulent otitis media

[3] Transactions of the American Laryngological, Rhinological, and Otological Society, 1909.

is properly classified under the following general headings, depending upon the duration of the disease and the location and extent of the pathological lesion: 1. Local therapy. 2. Intratympanic operation (ossiculectomy). 3. The so-called radical mastoid operation.

1. Local Therapy.—Of the three methods the simplest is that known as local treatment. This is applicable to and usually successful in a considerable proportion of cases of chronic otorrhea. The type of cases amenable to local treatment may be defined as the simple variety, wherein the soft tissues only are involved, or where the bone necrosis is localized, and in those where the disease is aggravated by adenoids, hypertrophied tonsils, lack of cleanliness, proper nourishment and hygienic surroundings. Here the removal of diseased tonsils and adenoids (see Chapters XLIII and XLVI), the establishment of right habits and methods of living, internal treatment with tonics and local treatment by modern methods will usually effect a cure. Primarily the local treatment should aim to remove accumulations of pus from the tympanic cavity and external auditory canal and to promote the rapid drainage of pus.

Some writers have recommended the dry treatment. In this, the external auditory canal is cleansed of all removable secretions, the site of the perforation is wiped clean, and as much of the secrtion as is possible to remove is wiped away from the tympanic cavity through the perforation. A sterile strip of plain gauze is then introduced into the canal, pushed up close to the drum and left *in situ* for twenty-four hours, when the entire process is renewed. We have had favorable results with this method in acute cases, but do not recommend it in the chronic ones. In some of the European clinics it has, however, been warmly advocated.

Methods of Douching.[4]—The cleansing of the purulent cavity by means of the douche or syringe is best accomplished by the employment of sterile normal salt solution. If large masses of dried secretion are found clinging to the walls of the cavity their removal is facilitated by previous instillation of a few drops of dilute hydrogen peroxid. If necrosis is present bichlorid of mercury solution, varying in strength according to the age of the patient, may be employed. These solutions should be warm, the temperature varying from 100° to 110° F., and should be employed at least three times a day. From one to two quarts of such solution in a fountain syringe, hung high up in order to give sufficient force to the stream, will serve to wash out the external auditory canal, and, when large perforations are present in the tympanic cavity, a more effective method of douching is that devised by Fowler (see Chapter VIII, Figs. 48, 49 and 50).

It often becomes necessary to irrigate the tympanic cavity and attic and this can be accomplished by using a slender glass or metal attic cannula (Fig. 178), slightly curved upward at the tip and carried through the perforation. The cleansing solution is then gently forced through the cannula by means of a syringe.

[4] For details regarding the ear douche see Chapter VIII.

When the discharge is very fetid the following has been of benefit:—

℞ Formalin ..... ♏ v.
Hydrargyri ..... gr. 1/32.
Alcohol ..... ℥ss.
Aqua dest. .....q. s. ad ℥iij.
M. et Sig.: Gtt. v in ear ten minutes before douching.

After douching there usually remain shreds of mucus or pus and other detritus, which must be carefully wiped away with the cotton-tipped probe. Any needed intratympanic application may now be made. The success of this method of treatment depends largely upon the frequency and thoroughness with which local

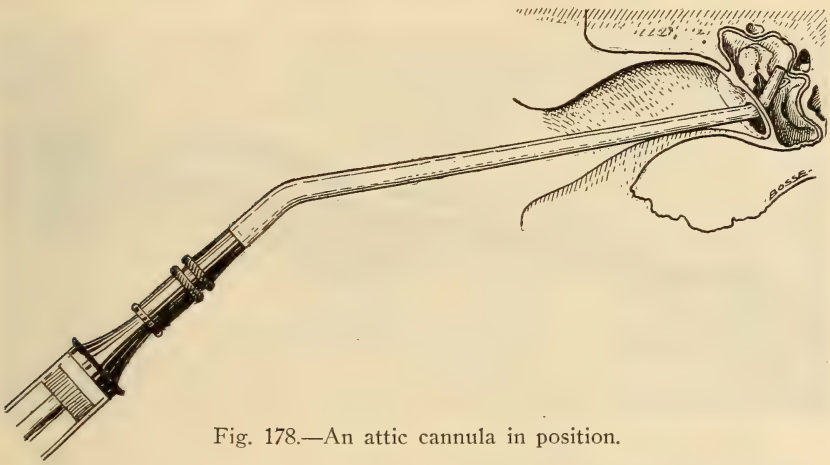

Fig. 178.—An attic cannula in position.

therapeutic measures are employed. This treatment cannot be fully trusted to the mother and rarely even to the nurse, but the physician himself must not only examine the ear, but also personally administer the local treatment almost daily for long periods of time.

If granulations recur applications of absolute alcohol or strong solution of nitrate of silver produce favorable results. Small areas of necrosis should receive frequent applications of nitrate of silver or iodin until the necrotic areas slough away.

In order to facilitate the flow of pus it may become necessary to remove or otherwise destroy exuberant granulations, or to enlarge the perforation.

While insufflations of powders have had the recommendations of Bezold (boric acid), Spira, Passow (xeroform), and others, we believe that the insufflation of powders may cause "caking" when they become mixed with the ear discharge and thus retard the flow of pus. We do not recommend these powders except in the very last stages of suppuration, when the ear is almost dry and any likelihood of "caking" and pus retention has passed, and even then the amount of powder inserted should be small.

Boenninghaus recommends the use of nitrate of silver 6 per cent. solution in alcohol for applying to the ulcerated surfaces. Schwartze employs nitrate of silver in those cases where the mucous membrane is shown to be much swollen and red. He uses solutions beginning with 2 per cent. and ranging as high as 10 per cent. The higher percentages are useful in checking polypoid excrescences of the mucous membrane.

Obstructing polypi or granulations should immediately be removed. When of sufficient size a small snare (Fig. 179) may be employed, otherwise the most effective method is to fuse a small crystal of chromic acid upon the end of a probe and plunge it into the granulation mass.

The common occurrence of aural polypi in conjunction with

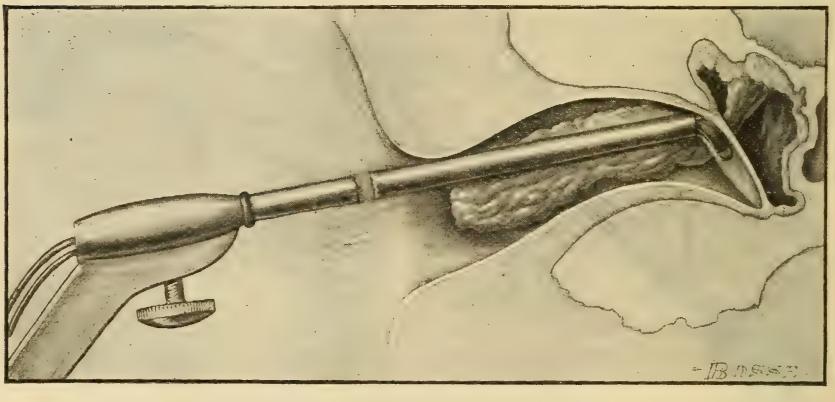

Fig. 179.—The snare has been passed along the polypus, the mass meanwhile being engaged within the wire loop. The pedicle is about to be severed at its exit through the perforation in the membrana tympani.

chronic purulent otitis media renders necessary a brief description of the technique of this useful procedure.

Removal of Aural Polypi.—Coming to the intratympanic operations the most frequent procedure is the removal of polypi or granulation tissue. The presence of polypi or granulation masses in the tympanic cavity and external auditory canal almost invariably indicates a chronic purulent process in the tympanic cavity and its adnexa. The most common attendant symptom is otorrhea.

This tissue is adventitious and should be removed or otherwise destroyed. When accompanied by offensive discharge and by extensive bone necrosis some form of operation must be combined with it which not only will remove the polypi, but obliterate the necrosed tissue as well. A simple method of removing large polypi is by means of a small aural snare (Fig. 179). By this procedure the projecting portion of the mass is easily cut away. The remaining base is then cauterized, preferably with a bead of chromic acid fused upon the end of a probe. The latter alone is usually sufficient

for the destruction of small granulation masses. In this manner the obstructing lesion is removed, but, unfortunately, inasmuch as these growths result from an underlying necrotic process, the proliferations are prone to recur, and recurrence is usually rapid. It is sometimes necessary to limit the action of the chromic acid by douching the ear with salt solution.

Recurrent proliferations of aural polypi, in cases wherein all improved methods of local treatment have been faithfully carried out during the interval, indicate a chronic purulent process with bone necrosis which involves the spaces which are accessory to the tympanic cavity proper, for the cure of which the radical mastoid operation becomes imperative.

It will thus be seen that, while the results of removal by snare or destruction with escharotics are favorable in the simple cases wherein the disease is confined to the borders of the drum membrane perforations or portions of the tympanic walls, the results are unfavorable and almost invariably attended with recurrence when the necrosis is extensive, deep-seated or located in the adnexa, the latter cases always requiring the more radical procedures in order to effect a cure.

It occasionally happens that the large polypoid masses which project into the external auditory canal spring directly from the exposed dura mater or lateral sinus, in which event removal by pulling or tearing is attended with considerable danger to the meninges.

Dench has reported a fatal outcome from the intrameatal removal of polypi. It was found at the autopsy that in the absence of the attic tegmen the polypus had been removed from its attachment to the dura. It is therefore to be borne in mind that the patient should be kept under close observation for some time following the removal of polypi with the snare.

The instillation of alcohol (95 per cent.) is indicated in cases of cholesteatoma. Aqueous solutions cause the cholesteatomatous masses to swell, and add to the discomfort of the patient. The alcohol seems to loosen the masses, and permit their removal.

In the case of polypoid granulations the alcohol also seems to have beneficial action, causing dehydration and shrinkage. The treatment must be continued for weeks to be fully effective. Orthochlorophenol applied to granulations followed by an alcohol instillation has also given excellent results.

At each sitting, in addition to ordinary douching, a careful otoscopic examination should be made and all remains of pus and detritus carefully wiped away. Inflation in chronic cases is often beneficial, the air douche forcing retained secretions from the Eustachian tube into the tympanic cavity. In the majority of cases it is advisable to continue the local measures above described for a considerable period of time, even for months, providing any reasonable measure of improvement warrants delay in operative procedures. The results obtained prove the merits of the method, as considerably more than 50 per cent. of all cases are cured, or at

least sufficiently improved to practically remove the dangers attending the chronic purulent process.

In a case progressing favorably in the course of time the ear becomes dry, the perforations may become cicatrized, and healing is thus effected.

If the perforation margins are thickened and covered with epidermis the perforation will not heal. An application of trichloracetic acid removes the epidermis and the perforation margins may granulate sufficiently to heal the lesion in the drum. The drug is applied every eight days.

Naturally we only hope to close the perforations when they are small and are centrally located. Blake advocates the placing of small disks of paper over the perforations in order to effect healing.

After the cessation of the discharge, the physician's next duty requires him to try to improve the patient's hearing. The cautious use of inflation, and some massage to the ear by stretching the adhesions, accomplishes much. In many cases the hearing is not capable of being improved, and Toynbee, Gruber and others have found it advantageous to employ artificial eardrums in these cases.

In a limited proportion of cases improvement results from the use of the various eardrums or from small pledgets of moistened cotton fitted into the perforation. Their employment for this purpose is always attended with danger of infecting the surrounding tissues.

Unfortunately, the local measures above described prove insufficient when extensive necrosis exists, and some form of operative treatment must be instituted in order to eradicate the disease.

Two general methods of operation are valuable, either one of which must be decided upon according to the exigencies of the case. The first and simpler operation is the intratympanic, which is performed through the external auditory canal. This operation is also termed ossiculectomy. The latter term is objectionable because it relates only to the removal of the ossicles, whereas the actual operation often requires the curetment of areas of necrosis in the attic, annular ring and Eustachian orifice. The second is the so-called radical mastoid operation, which is performed externally by the postauricular route.

2. Intratympanic Operation (Ossiculectomy).—The intratympanic operation or ossiculectomy is simpler in technique, avoids external incision, deformity and prolonged and painful dressings. While it requires much skill and an accurate knowledge of the anatomical surroundings, it is much less formidable than the radical mastoid operation. It is necessarily limited in scope to the membrana tympani, soft tissues of the tympanic cavity proper, the ossicles (malleus and incus only), tympanic ring and walls. Nevertheless, it is worthy of trial in cases where it can be fairly accurately demonstrated that the necrosis is confined to these locations. An ossiculectomy, skillfully performed, with the curettage of all necrosed areas within reach, will in a somewhat limited percentage of cases effect a cure, and even when a complete cure is not effected

the removal of the membrana tympani and ossicles opens a wide channel for the flow of pus from the deeper structures. It is a well-known surgical axiom that large openings into pus cavities materially aid nature's efforts at repair.

The author has repeatedly succeeded in terminating a suppurative process in the middle ear by resorting to this method of treatment. It is somewhat difficult to define the class of cases in which it may be employed with a reasonable hope of success, on account of the obstacles in the way of positively determining whether the necrotic process is confined to areas within reach; and yet the history, the amount and character of the discharge, and the intelligent use of

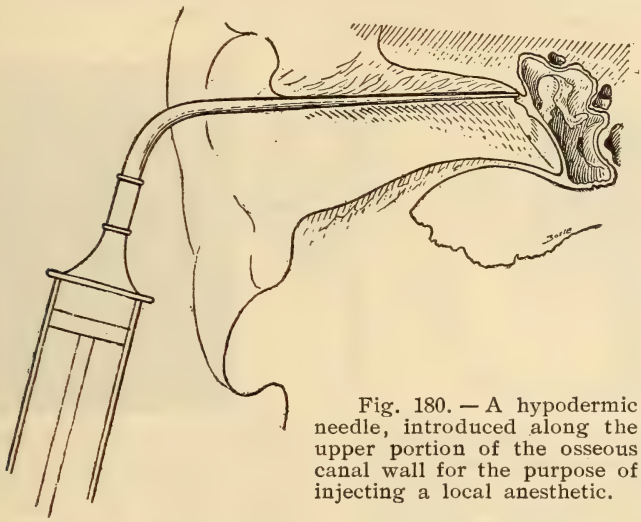

Fig. 180. — A hypodermic needle, introduced along the upper portion of the osseous canal wall for the purpose of injecting a local anesthetic.

the probe become valuable adjuvants in deciding whether or not ossiculectomy is indicated. All patients when advised to submit to this operation should be informed that it may fail to cure and that the more radical operation may subsequently become necessary.

3. The Operation.—Ossiculectomy is an operation by which the remaining portion of the drum membrane and ossicles is removed, together with the curetment of granulations and such diseased portions of the tympanic walls, the attic with its outer wall, and the annular ring, as may be reached through the external meatus. This operation is employed as a means of curing chronic purulent otitis media by the removal of diseased tissue and the promotion of drainage, and for rendering the tympanic walls more accessible to local treatment. It is an intermediary between the non-operative method of treatment and the radical mastoid operation.

Indications.—This operation is indicated: 1. When a purulent inflammatory process in the middle ear does not respond to local measures of treatment in cases wherein the diseased process is

chiefly confined to the drum membrane, ossicles, and the tympanic walls.

2. After recurrence of polypoid proliferations, *unless* such recurrence is associated with evidences of extensive necrosis in the aditus, mastoid antrum, or labyrinth, clinical evidences of which are: continued discharge with foul odor; perforations in Shrapnell's membrane, or along the upper posterior walls of the tympanic membrane; pain in the mastoid region; vertigo, nausea and vomiting.

3. As a preliminary to the radical operation, either on patients who never have given evidences of complicating lesions, and in whom it is hoped that improved drainage and subsequent persistent local treatment will effect a cure of the disease; or in patients who

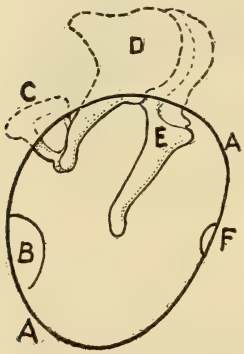

Fig. 181.—A schematic drawing representing the field of the intratympanic operation. *A*, The circle represents the visible field. *B*, The round window. *C*, Footplate of the stapes in the oval window. *D*, The incus. *E*, The malleus. *F*, The Eustachian orifice.

Fig. 182.—Circle *A* represents the outer extremity of the aural speculum, introduced into the external auditory canal. The dotted circle *B* represents the drumhead which is to be incised. The small inner circle *C* indicates that portion of the drum membrane visible to the eye of the operator at one time

demand a preliminary operation rather than submit to the more formidable procedure except as a last resort. Proportionately, the number is not large.

The operation is performed as follows: Douche the ear thoroughly with a 1:3000 solution of bichlorid of mercury. The anesthesia may be either general or local, the latter being quite feasible except in young children and adults of extremely nervous temperament. The local anesthetic must be used by means of the hypodermic needle. A few minims of a solution composed of cocaine, one-half of 1 per cent., and adrenalin 1:5000 and injected into the upper external canal wall at a point close to the drumhead (Fig. 180) will usually produce the required anesthesia. A few minims of a strong solution of cocaine (10 per cent.), when instilled through the perforation into the tympanic cavity twenty minutes before the

injection above mentioned, is of material benefit. An aural speculum of large size is then introduced under bright illumination. The visible operating field is represented by the oval line *A* in the accompanying illustration (Fig. 181). In looking at the operative field through the aural speculum, the operator can see only one segment of the field at a time and is therefore obliged to tilt the speculum at various angles during the operation. One visible field is thus shown by the tissues included in the dark circle in the illustration (Fig. 182).

The first step in the operation consists of severing the entire drum membrane from its peripheral attachment by means of a

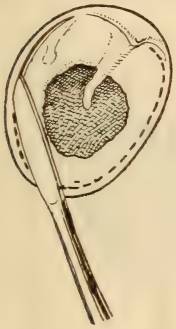

Fig. 183.—The primary incision to sever the drumhead from its peripheral attachments.

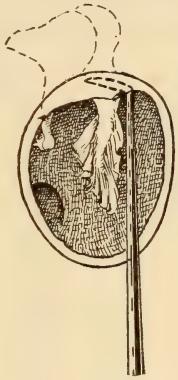

Fig. 184. — The tenotomy knife introduced into the tympanic cavity at a point above the level and behind the short process of the malleus, for the purpose of severing the tendon of the tensor tympani muscle.

Fig. 185.—The position of the tenotomy knife after the tendon of the tensor tympani has been severed.

circular incision (Fig. 183). As a rule the detached drumhead will cling to the malleus handle and may be removed with that body. The incision in the drum is succeeded by the introduction of a small angular tenotomy knife at a point just above and posterior to the level of the short process of the malleus (Fig. 184). The blade is then carried directly downward along the posterior surface of the malleus handle, thus severing the attachment of the tensor tympani muscle (Fig. 185). The body of the malleus is then firmly grasped between the jaws of the extracting forceps (Fig. 186). Traction is then made upon the malleus after the manner followed when using the traction obstetric forceps in child delivery.

It is unnecessary to sever the incudostapedial joint for the reason that, in extracting the incus, the hook is introduced posterior to that body and rotated forward and downward, during which manœuvre its long process separates from the head of the stapes without injury to the latter (Fig. 187).

After removing the ossicles, all necrosed surfaces within reach are curetted by means of straight and curved curets and biting forceps (Fig. 188). The Kerrison or Hartmann chisel-forceps are effective in removing the outer attic wall (Fig. 189).

It is important that any granulations located in the vicinity of the tympanic orifice of the Eustachian tube should be thoroughly curetted. Furthermore if necrosis is discovered underneath these granulations the diseased area of bone should be curetted. Having completed the required operative procedure, the middle-ear cavity should be thoroughly douched with warm normal saline solution, and all fragments of bone or other adventitious tissue washed away. The surfaces are then thoroughly dried and a narrow strip of iodoform gauze is introduced in such a manner that the epitympanic space is filled, and also that the packing presses firmly into the

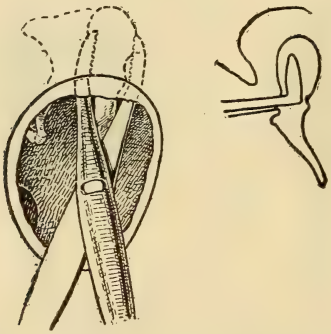

Fig. 186.—The angular extracting forceps have been introduced into the tympanic cavity and are firmly grasping the malleus, preparatory to its removal. The small sketch represents the lateral view of the traction forceps in position.

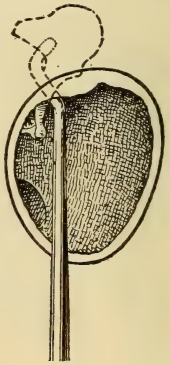

Fig. 187. — The illustration shows the position of the incus hook when introduced for the purpose of rotating the incus downward and forward, preparatory to its removal.

tympanic orifice of the Eustachian tube. The remaining portion of the tympanic cavity is then loosely packed and the external canal lightly packed with plain gauze. A pad is then placed over the entire ear and the ordinary mastoid bandage applied (Fig. 157). This dressing should be allowed to remain *in situ* for forty-eight hours. Dressings applied in this manner insure the freshly denuded areas within the middle ear against any new infection. Furthermore, the drainage of the parts is rapidly absorbed directly into the dressings, and not allowed to accumulate in the irregular cavities of the middle-ear spaces. It is advisable to repeat this form of dressings at the daily visits during the first week, after which time the treatment should be followed in a manner similar to that which has been heretofore advised for chronic purulent otitis media.

It is a favorable indication when the first dressings are found to be free from pus and offensive odor. There is usually more or

less discharge for from one to three weeks, but, if the discharge gradually becomes thinner and less in quantity, a favorable outcome may be expected from the operative procedure.

On the other hand, whenever the discharge continues to be profuse after the intratympanic operative procedure, the continued suppurative process becomes an indication of more extensive and far-reaching disease of the temporal bone, and one which may be expected to yield only to the radical mastoid operation.

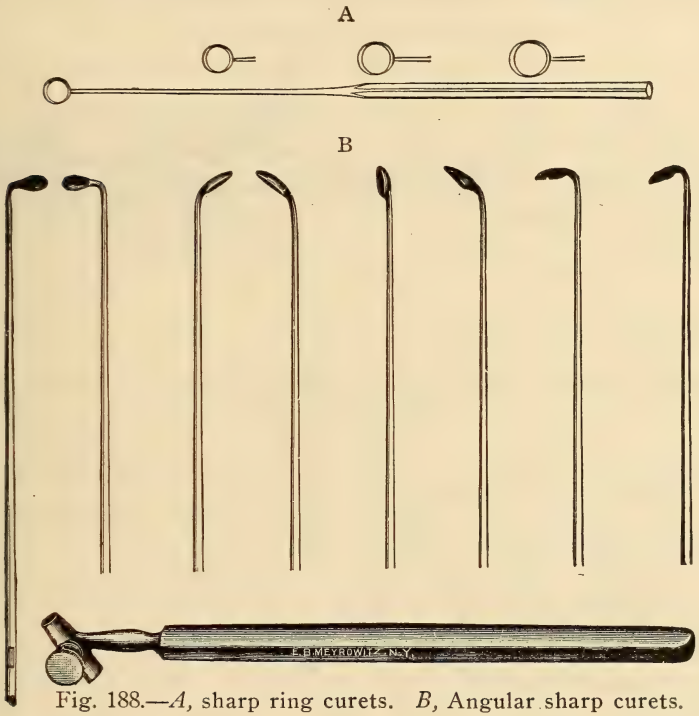

Fig. 188.—*A,* sharp ring curets. *B,* Angular sharp curets.

The intratympanic operation is occasionally followed by small regrowths of granulations, which develop during the process of healing. These should be immediately destroyed, preferably by the application of chromic acid. The complete removal of the drumhead, outlined in the foregoing description of the operation, favors an ingrowth of epithelium from the external canal, which may gradually dermatize the surfaces of the tympanic cavity.

From this time on the middle ear performs its functions without a drumhead. Individuals thus affected are prone to attacks of middle-ear discharge after sea-bathing. They should therefore be warned to pack the external auditory canal before entering the water.

The Results.—In the author's experience the results have been favorable in a considerable proportion of all cases operated upon.

In carefully selected cases of localized chronic otorrhea with large perforations of the drum membrane proper, which furnish no history of recurrent mastoiditis, the results have been good, complete recovery being the rule. By recovery is meant a cessation of otorrhea.

The removal of the tissues above mentioned improves the drainage from the tympanic cavity, attic and the mastoid antrum. Hence, even though the otorrhea may continue, the establishment of drainage tends to lessen the complicating dangers of the disease.

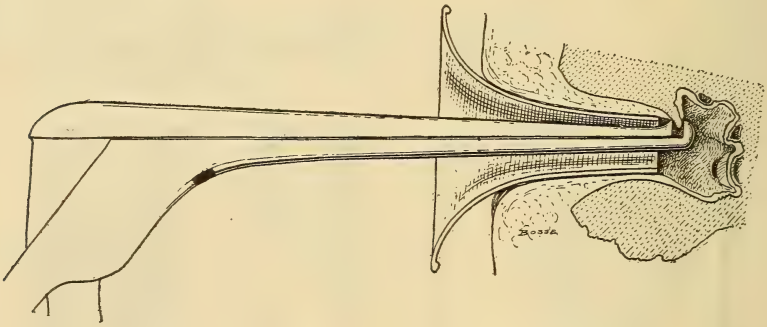

Fig. 189.—Kerrison chisel forceps in position for removing the outer wall of the aditus (attic).

In addition, the operation renders the intratympanic spaces more easily accessible to subsequent treatment.

The operation is not wholly without danger. The facial nerve, denuded of its bony covering in the region of the labyrinthine (mesial) wall of the tympanum, may be injured during the operation, with resultant facial paralysis. Dehiscences over the jugular bulb sometimes lead to injury of the blood-vessels at these points, with serious consequences. Curetment of polypoid proliferations from the parietal surface of the dura, in cases where the tegmen has become destroyed by necrosis, has been known to cause serious meningeal involvement.

The chorda tympani nerve, which runs in the posterior fold of the drum membrane, is often severed, with resultant temporary derangement of taste on the corresponding side of the tongue.

CHAPTER XXII.

DISEASES OF THE MIDDLE EAR.

(*Continued.*)

CHRONIC PURULENT OTITIS MEDIA.

The Radical Mastoid Operation.

Indications.—Briefly stated, the purpose of the radical mastoid operation is to convert the external auditory canal, tympanic cavity, aditus ad antrum, mastoid antrum and mastoid cells, when diseased, into one wide-open cavity; to excavate all granulations and diseased bone, to destroy all membranous and muscular tissue lying within these limits, including the membrana tympani, and to effect dermatization throughout the entire area, in the hope that by so doing the ramifications of the disease will be terminated once and for all.

While the general statement that the radical mastoid operation is performed in order to effect a cure of chronic purulent otitis media is correct, it must be understood that it is not indicated when the disease is confined to the tympanic cavity proper, but it is to be performed only when the typical indications which we are about to define are present.

The operation is a capital one, requiring extensive dissection in the most complicated bone in the human body.

The radical mastoid operation is indicated: 1. When a permanent cessation of the purulent process has not been effected by prolonged local intratympanic treatment, combined if necessary with such minor operations as removal of granulations, enlarging perforations, etc. 2. When a cure has not been effected by the removal of necrosed ossicles and the curettage of the middle ear. 3. When acute symptoms of mastoiditis supervene in otitis media purulenta chronica. 4. When a sudden cessation of the pus discharge is followed by chills, fever, vertigo, pain or other unusual symptoms. 5. The appearance of facial paralysis during the course of chronic purulent otitis media. 6. Attacks of vertigo, nausea and vomiting, indicating that the necrotic process involves the labyrinth. 7. In all cases of complicating intracranial or lateral sinus involvement, the latter being characterized by symptoms of general sepsis, increase of leucocytes and of polynuclear percentage. 8. When there are positive symptoms of cholesteatoma in the mastoid antrum. 9. When there are fistulous openings in the cortex of the mastoid process or in the osseous canal wall. 10. Whenever extreme depression or other symptoms of disturbed mentality accompany the disease.

Contraindications. — The operation is contraindicated: 1. When the purulent process is tuberculous and accompanied by advanced general tuberculosis. 2. In advanced pernicious anemia

or albuminuria, and in cachectic diabetes. 3. It is usually contraindicated in young children. 4. In all cases where the disease is confined to the ossicles and tympanic cavity. 5. In adults who have scanty otorrhea without odor, with improper opening of the drum membrane, behind which are retained masses of secretion. 6. In all cases where it is possible to effect a cure by any of the other methods described.

Technique of the Radical Mastoid Operation.—It was in 1873 that von Tröltsch made the first attempt to modify the Schwartze mastoid operation by removing portions of the posterosuperior canal wall. Later on both Schwartze and Körner described cases in which portions, at least, of the posterior canal wall were removed. Küster, in 1899, outlined in a more definite manner the importance of the operation, and the various steps to be followed in performing it. About the same time von Bergmann defined the simultaneous opening of the mastoid, and the removal of the posterosuperior osseous canal wall of the external auditory canal, and designated the procedure the "radical mastoid operation." Stacke, in 1891, published a description of the operation which has since borne his name, by which the superior canal wall is removed by cutting from the tympanum toward the mastoid antrum. Furthermore, he was the first to suggest the formation of a suitable skin flap, fashioned from the membranous portion of the external auditory canal.

Various operators have from time to time suggested minor modifications, both of the operation upon the bone and in the formation of the meatal skin flap.

The patient is prepared for the operation after the manner described for the simple mastoid operation (page 228), with the exception that, inasmuch as the posterior incision is usually closed at the primary operation, we advise the shaving of the least possible amount of the patient's hair. (For a description of local anesthesia of the mastoid process see Chapter VIII, page 94, and Figs. 52 and 180). In women, and especially those who are obliged to earn their own livelihood, the shaving of a considerable section of the scalp becomes a serious drawback. Furthermore, it is possible by following suggestions given in the chapter on "Acute Mastoiditis" (page 228) to operate successfully with but little sacrifice of hair.

The Incision.—The curvilinear incision is similar to that (Fig. 136) employed for the simple mastoid operation, but in the radical operation it may be located closer to the attachment of the auricle. This is permissible because it rarely becomes necessary to remove extensive portions of the cortex over the posterior portions of the mastoid process. Moreover, it is advisable because the resultant scar thus becomes considerably obscured in the fold which marks the line of attachment of the concha to the temporal bone. The anterior and posterior flaps, including the periosteum, are then rapidly separated from the bone forward and backward by means of the periosteal elevator (Fig. 137), until the cortex is completely

exposed to view (Fig. 141). The anterior flap should be reflected further forward than in the simple mastoid operation, in order to expose the outer posterior margin of the osseous meatus to full view.

Before proceeding with the operation upon the bone, we separate the posterior attachment of the fibrocartilaginous portion of the external auditory canal by sliding a small periosteal elevator (Fig. 138) into the postauricular wound, and inward along the posterior osseous canal wall until complete separation of the soft tissues is effected. This procedure usually separates the drum membrane from its normal attachment. The anterior lip of the wound, including the posterior membranous canal wall, is then retracted either by the employment of a Jansen retractor (Fig. 190) or, following the method employed by most American otologists, a strip of gauze is introduced into the posterior wound and drawn outward through the membranous canal (Fig. 191). In the former method the retractor is held by an assistant during the entire procedure, while, in the latter procedure, a loop is made of the gauze strips, which is grasped by artery forceps, the latter be-

Fig. 190.—Jansen's fibrocartilaginous wall retractor.

ing held in the hand of an assistant. At the same time the entire wound is firmly retracted with Jansen's mastoid retractor (Fig. 140). Ordinary hand retractors may be employed for this purpose, but are less efficacious.

We now proceed to excavate the mastoid antrum and cells after the manner followed in the simple mastoid operation (Figs. 143, 146, 147, and 150). The majority of foreign operators and their followers remove the posterior osseous canal wall simultaneously with the excavation of the mastoid antrum and cells, while most American operators enter the mastoid antrum as a preliminary procedure. The preliminary mastoid operation, whereby the mastoid antrum is thoroughly exposed to view, reveals those anatomical landmarks which outline the external semicircular canal and the location of the facial nerve, thereby lessening the danger of injury to these bodies while the posterosuperior osseous canal wall is being removed. The additional time required in operating by this method is clearly in the interest of the patient, inasmuch as it minimizes the danger of injury to the facial nerve and labyrinth.

The cortex is then removed throughout a sufficient area to enable the operator to fully determine the extent of the disease in the bone. The mastoid tip cells are exposed and every vestige of diseased bone is then removed from the mastoid process.

The removal of the posterosuperior wall of the osseous canal

constitutes the next step in the operation (Fig. 189). This is accomplished by means of mallet and chisel or by the Kerrison chisel forceps. The author often removes the outer portion of the wall with a small pair of rongeur forceps, by introducing one jaw of the forceps into the mastoid wound, and the other into the osseous external canal. The Kerrison chisel forceps, small size, are then employed to complete its removal. With proper caution,

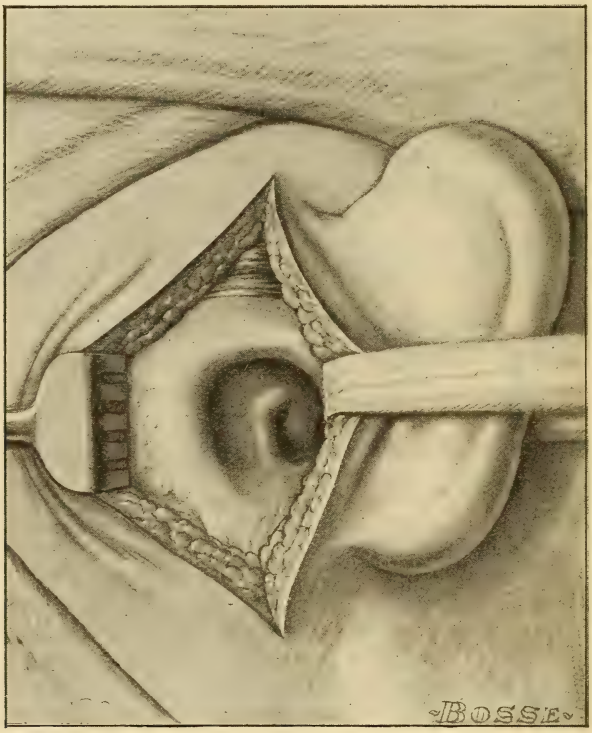

Fig. 191.—A completed tympanomastoid excavation, showing the removal of the ossicles and all the soft tissues from the tympanum, together with the remains of the annulus tympanicus, the cortex and cells of the mastoid, the posterosuperior osseous canal wall, the diseased zygomatic cells, curetment of the tympanic orifice and the Eustachian tube, and the entire surface made smooth and free from rough or overhanging bone.

it is unnecessary to employ the Stacke protector (Fig. 192) in the radical operation. The outer wall of the epitympanum (attic) is then removed, and mainly by means of the Kerrison forceps (Fig. 189), but completed with small chisels and curets. The exploring probe should be introduced into the attic from time to time in order to guard against the removal of unnecessary portions of the overhanging squamous bone and possible exposure of the dura. Furthermore, during the removal of the outer attic wall the

operator should guard against injury to its inner wall, which is in close relation with the facial nerve. The removal of the postero-superior osseous canal wall, together with the outer wall of the epitympanum, reveals the ossicles or such portions of these little bones as may remain, providing they have not already succumbed to the necrotic process. They are usually deeply imbedded and sometimes entirely obscured by granulations.

One assistant should be assigned to the duty of wiping the blood from the operative field and to remove the chips of bone, in order that the important landmarks may not become obscured.

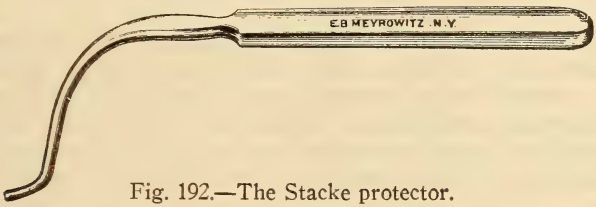

Fig. 192.—The Stacke protector.

At this stage of the operation, the bone cavity having now become exposed to view, the wound should be tightly packed with gauze which has been soaked in a 1 : 5000 solution of adrenalin, the packing to remain for one or two minutes. Upon removing the gauze, the entire wound is free from blood, and hence is visible throughout.

The incus and malleus should then be carefully removed, but, unless the labyrinth is necrotic at some point, the stapes should remain undisturbed. Before proceeding further we carefully examine the entire area with the exploring probe, in order to determine as far as possible the extent of the necrosis.

Fig. 193.—The Richards curet.

Returning to the mastoid portion of the wound, this region should be freed from all overhanging bone and rough areas, and furthermore the entire surface should be made smooth by means of a sharp curet or electric burr.

The completion of the operation calls for (1) a wide open communication between the mastoid region and the tympanic cavity proper. This is chiefly gained by lowering the posterior canal wall. With a small and very sharp chisel the bone in this region is gradually chipped away. At the floor of the aditus the bone should be removed as near as possible to the Fallopian canal, without exposure of the facial nerve at any point; meantime sufficient bone should be left to protect the oval window from injury. The removal of the overhanging portions of the squamous portion will also materially enlarge this space. The Richards curet (Fig. 193)

is well adapted for this purpose. Allport and a few other American otologists strongly advocate the use of the steel burr (Fig. 195), electrically driven, for excavating the interior of the bone cavity, in the radical mastoid operation, claiming it to be "the best, quickest, and safest instrument for cleaning out the interior of the bone." The procedure has not been generally adopted as yet by the otologists of New York, whose work the

Fig. 194.—Eustachian curet. (*Neumann.*)

author is familiar with. Having completed this important step of the operation, the operator's attention is again given to the tympanic cavity, from which every remaining vestige of mucous membrane, granulation tissue and necrosed bone should be curetted. A most important procedure, and one upon which the final success of the operation often depends, is the removal of



Fig. 195.—Allport's mastoid drills.

diseased areas in and about the tympanic orifice of the Eustachian tube. By removing the mucous membrane from about and within the tubal orifice, it is hoped to replace the membrane so removed with granulations which eventually will close off the communication of the Eustachian tube with the middle-ear spaces, and thus prevent further infection from the nasopharynx. It is common to discover diseased bone cells ranged about the tubal orifice, and sometimes these extend a short distance into the tube, especially

in its upper wall. All such diseased areas of bone should be thoroughly removed. The Eustachian orifice curet devised by Neumann (Fig. 194) is well adapted for curetting the Eustachian orifice, and enables the operator to cut away a considerable portion of its lining membrane. The opposite end of the Neumann curet has a file construction suitable for smoothing the denuded bone within the tubal orifice.

The above-described technique is generally practised by American otologists in effecting the removal of the diseased areas in and about the Eustachian orifice. The results are not invariably favorable, but are in the main satisfactory. Upon the subject of closure of the Eustachian tube, Gerber[1] remarks, there is as yet no satisfactory means at hand which gives absolute results. He believes that epidermis transplantation over this orifice is to date the best procedure. With this statement the author cannot agree, unless it is to be understood that the transplantation of epidermis is to be preceded by thorough curettage of the tympanic orfice of the tube, and, even then, skin transplantation is of doubtful benefit. Heine's suggestion, namely, to leave a portion of the membrana tympani *in situ,* and place this by means of tampons over the orifice, seldom succeeds. Moreover paraffin injections into the tubal orifice have not met with success.

The next step in the operation consists of enlarging the external osseous canal, by cutting away a portion of its floor and anterior wall with the Richards curet (Fig. 193) or the electric burr, bearing in mind here, as well as in each step of the operation upon the bone, the precautionary measures hereafter enumerated. The operation upon the bone having now been completed (Fig. 191), the denuded area is thoroughly washed with a normal salt or boric acid solution, thus removing from its surface all blood-clots and residual *débris.*

The Dangers and Accidents Attending the Radical Mastoid Operation.

Precautions.—The intimate relation existing between the tympanic cavity proper, the epitympanum (attic), the mastoid antrum, the mastoid cells, the facial nerve, the labyrinth, the jugular bulb, the internal carotid artery, the sigmoid sinus and the meninges, even when normally located, emphasizes the possible danger of accident attending the radical mastoid operation throughout its entire course.

In detail, the dangers and accidents which may be encountered during or subsequent to the performance of the radical mastoid operation are as follows:

(*a*) Injury to the trunk of the facial nerve.
(*b*) Exposure and injury to the dura.
(*c*) Wounding of the lateral sinus.

---

[1] Arch. f. Ohrenheilkunde, Bd. 70, Heft 3 and 4.

(*d*) Accidental dislodgement of the stapes from its position in the pelvis of the oval window.

(*e*) Injury to the labyrinth.

(*f*) Injury to the jugular bulb through dehiscences in the floor of the osseous external meatus.

(*g*) Injury to the external carotid artery through dehiscences in the floor of the tympanic extremity of the Eustachian tube.

(*h*) Injury to the glenoid fossa.

(*a*) **Injury to the Trunk of the Facial Nerve.**—Injury to the facial nerve occurs either from the careless manipulation of the

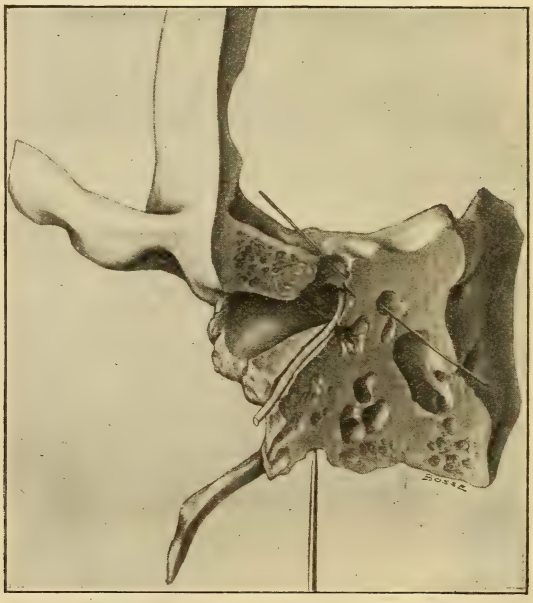

Fig. 196.—Anomalous position of the facial nerve; see key plate. (Specimen loaned by *Dr. T. P. Berens.*)

chisel, curet or rongeur forceps during the excavation of the bone while performing the radical mastoid operation, or because of dehiscences or defects in its bony covering which have resulted from necrosis.

In extensive necrosis of the temporal bone the nerve trunk is prone to become exposed at some point, and this is so especially along the floor or the inner wall of the aditus ad antrum. When thus exposed, unless great care is exercised, the nerve trunk may be severely injured or completely severed during the operation. Furthermore, the nerve may be injured at any point in its course in the Fallopian canal, and, when the excavation of the cells and necrosed bone at the mastoid tip requires the exposure of the digastric muscle, there is considerable danger of injuring the facial nerve at its exit from the Fallopian canal. The latter form of

injury is more liable to occur while operating upon infants and young children. Effusion into the Fallopian canal and undue pressure upon an exposed facial nerve by instruments or packing are less serious, nevertheless they are usually of sufficient severity to induce temporary paralysis of the muscles supplied by this nerve. Anomalies in the course of the facial nerve (Fig. 196) in rare instances are accountable for operation injuries.

Facial paralysis either temporary or permanent is the deplorable result of injury to the facial nerve. The paralysis is temporary when caused by an injury which does not sever or otherwise

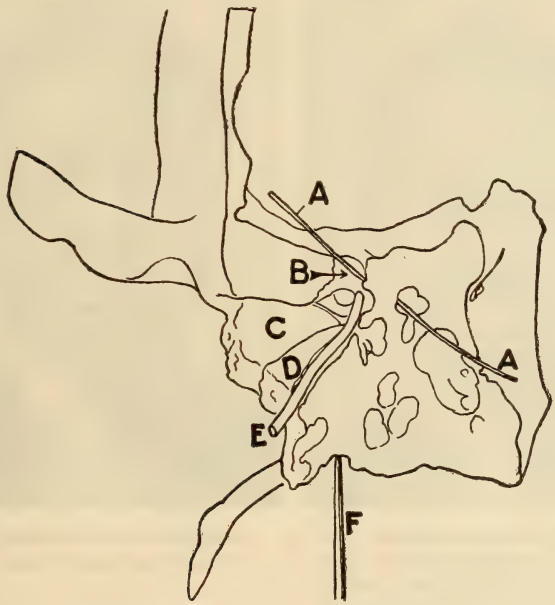

Key plate to Fig. 196.—*A*, Bristle passed through foramen ovale and semicircular canal. *B*, Attic. *C*, External auditory canal. *D*, Posterior wall of canal chiseled away to expose the nerve. This represents the usual bone wound of the posterior wall resulting from the usual Schwartze-Stacke operation. *E*, Facial nerve. *F*, Pin stuck into the sulcus that represents the normal orifice of the stylomastoid foramen.

destroy the nerve trunk, when resulting from pressure upon an exposed section of the nerve, or when due to inflammatory effusion into the Fallopian canal.

Permanent facial paralysis occurs in cases where the nerve trunk has been severed, when a segment has been cut away, or when destroyed at some point by the purulent inflammatory process. In the latter class of cases the facial paralysis is complete, its advent is sudden and sometimes apparent before the patient has completely recovered from the anesthetic.

In case the injury to the facial nerve is slight, the resultant

paralysis is rarely complete, it develops gradually and often it does not appear until some days subsequent to the operation.

It is not an uncommon occurrence for facial paralysis of otitic origin to appear in patients upon whom no operation has been performed, in which event its advent is considered to be of serious import, especially when accompanied by labyrinthine symptoms, or when due to the encroachment of tumors. The extent of the paralysis of the facial muscles is ascertained by requesting the patient to smile (Fig. 197), to close the eyes (Fig. 198) or to whistle.



Fig. 197.—Complete facial paralysis. The patient was suffering from Bell's paralysis, and in the photograph was attempting to smile.

Fig. 198.—Same patient. Taken while attempting to close the eyes.

Cases have been recorded where facial paralysis has disappeared after long periods, even when the nerve trunk has been completely severed, and in a few instances where the nerve has not only been severed, but with more or less destruction to the tissue (Bezold and Pierce). Pierce records one case in which a quarter-inch section of nerve trunk was destroyed, causing complete facial paralysis, which finally was restored after a period of nine months. The prognosis, therefore, so far as it relates to the restoration of function, depends upon the nature, severity and extent of the injury which the nerve trunk has received. If due to temporary pressure upon the nerve trunk, to traumatism without destruction of tissue, or to inflammatory effusion into its sheath, a cure may be expected. Notwithstanding the experiences above recorded facial paralysis, occurring as a result of complete destruction of the nerve trunk at any point, is almost invariably permanent.

Facial paralysis of otitic origin should not be confused with that known as Bell's paralysis, which is not due to pyogenic invasion of the middle-ear spaces.

For a description of the treatment of facial paralysis, the reader is referred to page 311.

(*b*) **Exposure and Injury to the Dura.** (*c*) **Exposure and Injury to the Lateral Sinus.**—Exposure of the cerebral dura covering the temporosphenoidal lobe, or the cerebellar dura over the sigmoid sinus or elsewhere, may occur during a mastoid operation, either by accident or of necessity.

It occurs by accident when it results because of an anomalous position of the tissues involved, or as a result of chiseling or curetting beyond the recognized limits of the operative field. It results from necessity when the necrotic process in the bone has already destroyed the inner (visceral) cranial table at some point.

Mere exposure of the surfaces of these organs is rarely if ever attended by serious symptoms or results, but the wounding of these tissues by infected instruments may result in serious intracranial infection.

Accidental puncture of the wall of the lateral sinus requires special mention because of the violent hemorrhage which follows. Unless controlled immediately the loss of blood produces serious shock to the patient. The hemorrhage is easily controlled by the introduction of small gauze plugs between the overlying bone and the proximal portion of the wounded sinus (Fig. 255). This accident should by no means deter the operator from completing the operation.

The hemorrhage does not usually recur at the time of the first dressing of the wound, but plugs of gauze should be at hand to be introduced in case it does.

(*d*) **Accidental Dislodgment of the Stapes.**—The precautions heretofore recommended for avoiding injury to the facial nerve, while chiseling the posterior portion of the osseous external canal, hold good in preventing injury to the oval window and stapes. Furthermore, during the curetment of the soft tissues of the tympanic cavity, the operator should avoid the oval window. It is feasible to remove coarse, flabby, overhanging granulations about the oval window, but it should be accomplished without molesting the stapes. Dislodgment of the stapes opens the labyrinth to infection and infective labyrinthitis may result. Moreover, serious impairment in the hearing function becomes inevitable.

(*e*) **Injury to the Labyrinth.**—Injury to the labyrinth at any point opens up its interior to infection, with all the train of deplorable results which follow labyrinthine suppuration (Chapter XXIII). This accident should never occur to the experienced operator.

(*f*) **Injury to the Jugular Bulb.**—On account of its location underneath the floor of the osseous external meatus (Fig. 2) the jugular bulb is liable to injury when dehiscences in the bone at this point are present. Such dehiscences are not common, but occa-

sionally are discovered during the operation. Wounding of the bulb is followed by a severe hemorrhage, which is easily controlled by tight packing. Eventual recovery may be expected unless septic thrombi intervene, in which event the case should be treated in the manner described for lateral sinus-thrombosis (Chapter XXIV).

(*g*) **Injury to the Carotid Artery Through Dehiscences in the Floor and Anterior Wall of the Tympanic Extremity of the Eustachian Tube.**—Hemorrhage at this point usually occurs as a result of the wounding of the plexus of veins which surround the carotid artery, and hence is easily controllable. A slight injury to the outer layer of the wall of the artery is not followed by severe hemorrhage, and simple packing with sterile gauze is sufficient to control the bleeding and protect the injured tissue from infection. Alarming hemorrhage follows when the wall of the artery is punctured, and the internal carotid should be ligated without delay.

(*h*) **Injury to the Glenoid Fossa.**—Injury to the glenoid fossa from careless chiseling occasionally occurs. Unless the capsular ligament is torn, no serious results are likely to follow.

The avoidance of the above-described accidents and dangers is of the utmost importance, on account of the complications which are thereby prevented. There are certain essential preliminaries which should be mastered by all otologists, before attempting a surgical procedure which is attended by the possibilities of so many serious accidents and deplorable complications as surround the radical mastoid operation. He should not attempt these surgical procedures without first acquiring an intimate knowledge of the anatomy of the temporal bone and the adjacent structures. He should not only possess a knowledge of the operation *per se,* but of all the complications which are liable to occur in connection therewith. His operations upon the living should be preceded by the acquirement of technical knowledge and skill gained from making numerous sections of the temporal bone, and by the performance of many operations upon the cadaver under competent instruction. Moreover he should further improve his technical knowledge, by witnessing the operations of experienced aural surgeons.

Among the minor though essential precautionary measures, the following may be enumerated as requirements:—

1. A sufficiently long primary incision to permit the necessary exposure of the cortex.

2. Bright illumination of the wound cavity, thus enabling the operator to keep in view not only the landmarks, but also to discover dehiscences of bone, anomalies of anatomy and the ravages of the necrotic process.

3. The control of hemorrhage, and the speedy removal of all chips of bone from the wound cavity.

The latter should be delegated to a trained assistant.

Many of the above-enumerated accidents may be averted by the frequent employment of the exploratory probe throughout the entire operation.

Plastic Surgery of the Fibrocartilaginous External Auditory Meatus.

Having completed the required tympanomastoid excavation, the fibrocartilaginous meatus now claims attention, for from it skin flaps are to be constructed by means of plastic surgery, to be anchored upon the denuded surface of bone in a manner that will best promote rapid dermatization of the whole cavity.

The purposes of the meatal skin flaps are threefold: 1. To circumvent subsequent atresia of the external auditory canal. The incisions required in the formation of the skin flaps, hereinafter described, serve at the same time to widen the fibrocartilaginous meatus sufficiently to prevent atresia of the external auditory canal, which might otherwise occur as a result of the loosening of the fibrocartilaginous attachment from the posterosuperior osseous canal wall during the operation upon the bone. 2. To amplify the external meatus to correspond with the increased size of the bone cavity within. The plastic operation allows a liberal opening for the introduction of dressings and for inspection of the cavity, and permits the proper aëration of the enlarged bone cavity with its large area of dermal lining, but the outer orifice should be symmetrical in contour and free from serious deformity of the auricle. 3. The flaps are constructed and anchored upon the denuded bone surfaces in a manner that will most advantageously permit the desired rapid dermatization of the entire cavity.

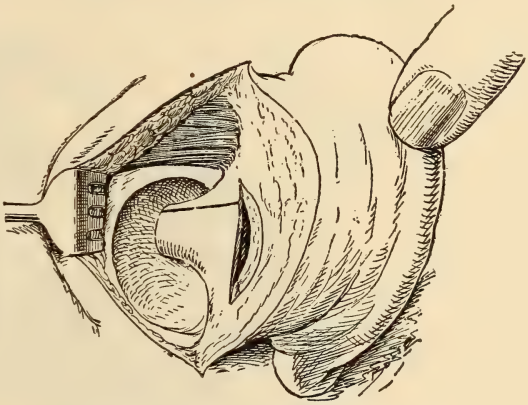

Fig. 199.—The Stacke meatal flap.

From the foregoing it will be seen that the construction and adaptation of a suitable skin flap from the fibrocartilaginous meatus is an essential procedure in all radical mastoid operations. The portion which is available for the purpose of covering the denuded bone cavity is necessarily limited to the posterior half, and even portions of this area are often absent because of sloughing which has resulted from prolonged suppuration and invasion of the underlying bone. Since Stacke first suggested the advisability and importance of dividing the fibrocartilaginous meatus into flaps as a step in the radical mastoid operation, numerous ingenious modifications have been made from time to time, a number of which bear the names of the distinguished aurists who designed them.

The aural surgeon should be familiar with all plastic procedures, inasmuch as in individual cases one form of meatal flap

may excel another. The more important plastic flap operations are described as follows:

(*a*) **The Stacke Flap.**—Stacke was the first to suggest the construction of a plastic flap from the fibrocartilaginous canal. His flap, slightly modified by Jansen, is shown in Fig. 199. The concha is grasped by the left hand of the operator and turned forward sufficiently to fully expose the anterior portion of the postauricular wound cavity. The narrow scalpel is then made to transfix the concha in exactly the opposite direction to that shown in the cut (Fig. 202), and the primary incision is then completed in the manner shown by the line *a, b* (Fig. 199), care meanwhile being exercised not to injure the anterior canal wall with the knifepoint.

The second incision, *c, d,* commences at a point near the upper

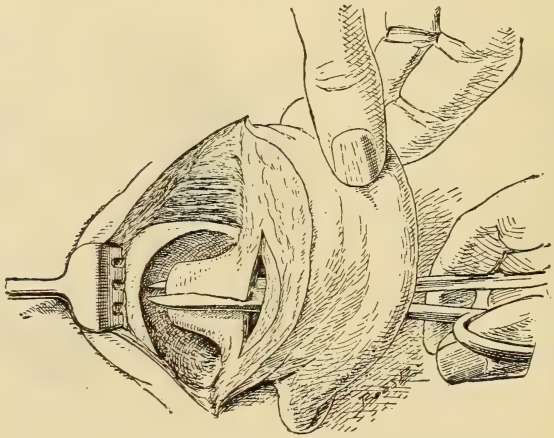

Fig. 200.—The Panze meatal flap.

extremity of the first, and by being extended at right angles to the former it transfixes the fibrocartilaginous canal throughout its longitudinal axis. These incisions result in the formation of a narrow upper and a wider lower flap which when thinned out by removing the cartilage and superfluous soft tissues are turned respectively upward and downward and either sutured or tamponed into position.

(*b*) **The Panze Flap.**—Panze modified the Stacke procedure above described by changing the situation of the second incision. In the Panze procedure the second incision commences at the middle point of the primary incision and is carried directly backward, transfixing the posterior wall of the fibrocartilaginous canal in its median line (Fig. 200). The latter incision is made either with scalpel or slender scissors, preferably the latter. When employing scissors for this purpose the blades are introduced after the manner shown in the illustration (Fig. 200). The lines of incision in the Panze flap form a T, and they result in the construction of two quadrangular flaps of varying dimensions. When

the fibrocartilaginous canal is large and the primary incision is carried well outward into the flaring portion of the meatal orifice, the flaps thus constructed are comparatively large. After being freed of all cartilage and superfluous soft tissues the flaps are turned, one upward and the other downward and adjusted to the denuded walls of the bone cavity. The entire cavity is then firmly reinforced with gauze which is introduced through the enlarged meatal orifice, with the result that the wounded area within is protected and at the same time the flaps are held in place. Many operators prefer to suture the flaps (Fig. 204).

The merits of the Panze flap are summed up as follows: It is not difficult to construct; it insures a wide-open external meatal orifice, and it is especially adapted to children.

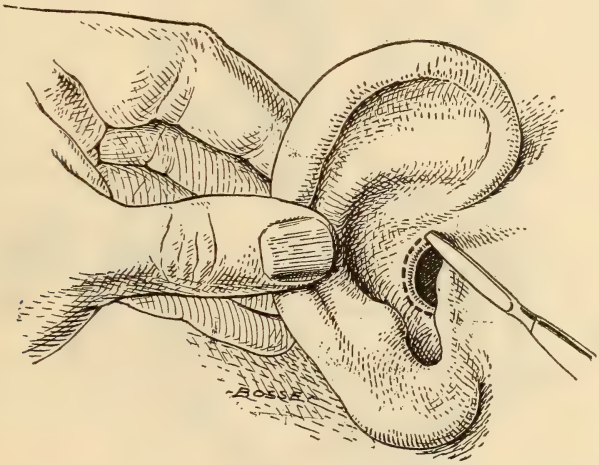

Fig. 201.—The dotted line indicates the location of the primary incision to be followed in constructing the Stacke, the Panze and other modifications of the Stacke skin-flap.

A further modification of the Stacke flap, one which for several years has been employed by the author in suitable cases, was formerly described by Whiting[2] as an "abundant meatal flap." Jansen also has recommended a similar procedure. In its construction a primary semicircular incision is made to transfix the auricle along the meatoconchal junction (Fig. 201), carrying the incision a sufficient distance into the concha to materially amplify the meatal orifice, and at the same time to afford a large area of skin for transplantation. Upon the reverse side the primary incision is made to sever the posterior attachment of the fibrocartilaginous canal from its conchal attachment (Fig. 202). Upon completion of the primary incision the scalpel is withdrawn and reintroduced from the postauricular side of the wound. The final incision is then extended in a backward direction, at right angles to the

[2] The Laryngoscope, August, 1909.

primary, throughout the entire length of the canal, as near its floor as possible (Fig. 203). The flap thus formed is oblong and of considerable dimensions. Its posterior surface should now be denuded of redundant cartilage and soft tissues, after which it may be grasped by suitable forceps and swung upward and backward and thus made to cover a considerable area of the posterosuperior portion of the osseous wound cavity.

The flap may be anchored either by means of a stitch uniting its edge to that of the fascia or periosteum above (Fig. 204) and further held in contact with the surface of denuded bone by tam-

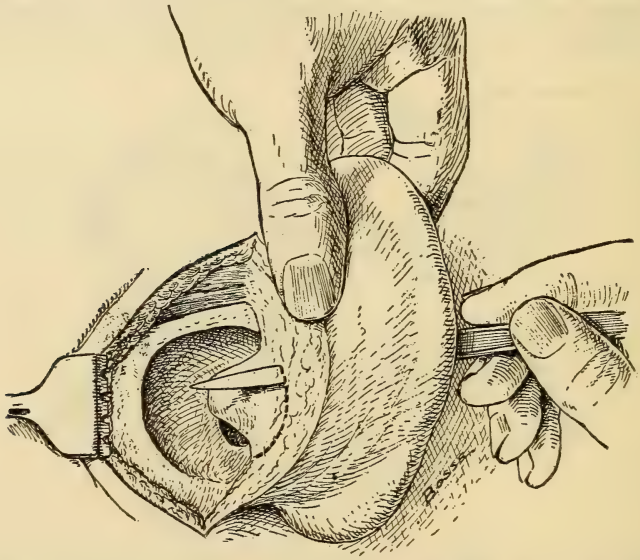

Fig. 202.—A posterior view of the primary incision. (Diagrammatic.)

poning with gauze packing introduced through the enlarged meatal orifice.

The Körner Flap.—The Körner flap differs materially in form from all others, inasmuch as by means of two parallel incisions the posterior half of the fibrocartilaginous meatus is separated from the anterior, the incisions being extended from the tympanic end outward to and slightly beyond the meatal border of the concha. The incisions, according to Körner, should be from 10 to 12 mm. apart. The completed incisions release a somewhat oblong or tongue-shaped flap from the fibrocartilaginous canal with its base of attachment at the concha (Fig. 205).

The incisions are followed by free hemorrhage from small vessels, often requiring ligatures or torsion.

Before placing the flap in position it should be drawn forward through the aperture in the canal, and thence outward into the external meatal orifice, where, under ample illumination, it is

divested of superfluous soft tissue and cartilage. The flap which is now composed of integument only is returned to the posterior wound space to be anchored in its proper place upon the denuded bone.

In the author's judgment the Körner flap never should be sutured because it can more advantageously be spread upon the denuded bone when no sutures are employed.

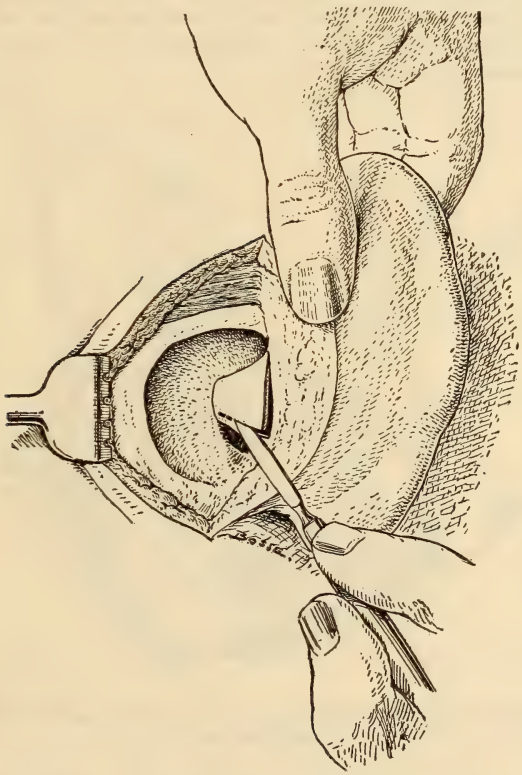

Fig. 203.—The final incision in the modified Stacke meatal flap. (Diagrammatic.)

After the postauricular wound has been closed the operator, by introducing an aural speculum of large size, under bright illumination, is enabled to grasp the flap with a slender pair of thumb forceps and locate it in the bone cavity to the best advantage. Furthermore, before withdrawing the speculum the initial gauze packing should properly be adjusted.

Viewed from the plastic standpoint, the advantage of the Körner flap lies in the fact that it occupies a rather central position upon the denuded bone, where from its borders spring epithelium which extends in all directions to meet the outgrowth from the more remote integument.

The Siebenmann Flap.—In the Siebenmann modification the primary incision is made to extend through the middle posterior portion of the fibrocartilaginous canal from its tympanic end following the line of the second incision in the Panze procedure, except that before invading the conchal extremity of the canal it is met by two short converging incisions which extend well outward beyond the conchomeatal juncture. As completed, the incisions result in a Y-shaped aperture, which furnishes three meatal flaps, two of which are oblong and made up of the posterior canal wall, the third being a short triangular flap constructed largely from the tissue of the concha.

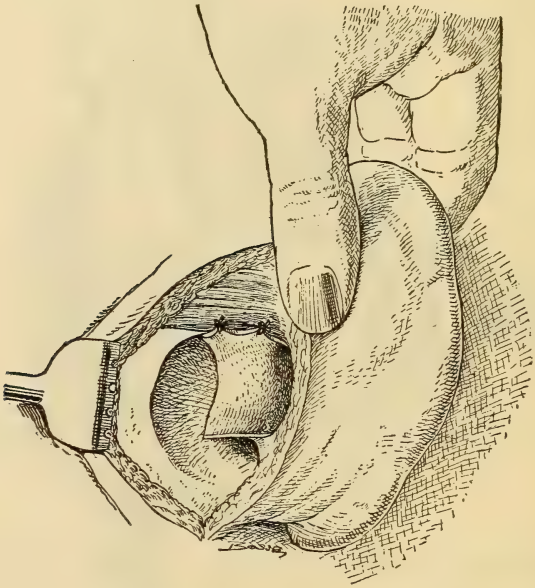

Fig. 204.—The meatal skin-flap stitched to the temporal fascia above. (Diagrammatic.)

Neumann has suggested a modification in the construction of the Siebenmann flap which is a distinct improvement. The modification consists in shortening the primary incision in the posterior canal wall, and is made up as follows: The auricle is grasped in the operator's left hand and lifted directly outward in order that the slender scalpel may be introduced through the outer meatal orifice to the full depth of the fibrocartilaginous canal. The incision is then carried from the tympanic extremity of the fibrocartilaginous canal forward through the centre line of the posterior wall throughout about two-thirds of its length (Fig. 206). The knife is then withdrawn and the operator's index finger is introduced into the outer meatal orifice. Retaining the finger in its position and by means of scissors two final incisions are made to diverge in the direction indicated by the dotted lines (Fig. 206),

one in an upward direction through the conchal orifice at the upper border of the meatus, and a similar one to the lower. Both should be extended a sufficient distance into the concha to permit the operator's finger to pass freely through the outer meatal opening (Fig. 207). The three flaps should now be divested of redundant soft tissue and cartilage and the V-shaped conchal flap anchored to the fleshy portion of the anterior lip of the mastoid wound (Fig. 208) and the upper and lower flaps adjusted to the denuded bony area in the wound. These may be retained in position by suitably adjusted sutures or gauze packing. The improved flap thus described offers a considerable distribution of integumental covering for the osseous wound cavity, and at the same time the cosmetic results are highly satisfactory and free from serious deformity.

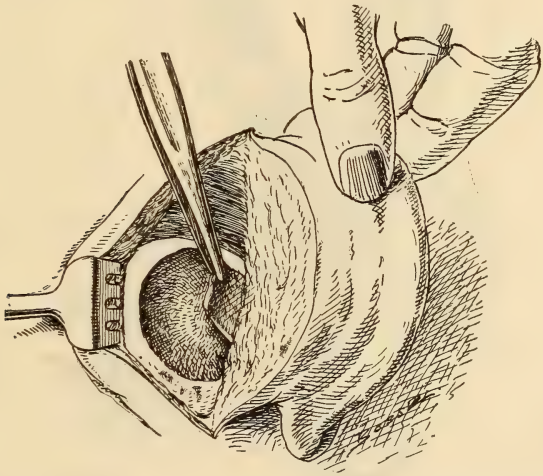

Fig. 205.—The Körner meatal skin-flap. (Diagrammatic.)

The Ballance Flap.—The technique to be followed in constructing the flap designated by Ballance differs somewhat from the forms heretofore described. The line of incision to be followed is depicted in Fig. 209, and is often referred to as the shepherd's crook incision. Ballance lays stress upon the importance of removing all redundant muscular and fibrous tissue from the posterior surface of the fibrocartilaginous canal and from the adjoining portions of the concha lying in the immediate vicinity as a preliminary measure, after which the incision is made in the form shown in the illustration. With slender-bladed scissors or scalpel the incision is carried through the median portion of the posterior canal wall to within a short distance of the attachment to the concha. From this point a semicircular incision is made downward, outward and upward into the tissue of the choncha. The circular portion together with the upper half of the entire canal wall is then drawn in an upward direction and anchored to the muscular or fibrous tissues of the external wound by means of stitches. The construc-

tion of the Ballance flap is attended with considerable difficulty, much of which may be obviated by making the latter or curved portion of the incision with the knife introduced from the anterior surface of the auricle.

Precautionary Measures.—It should be the invariable rule in all radical mastoid operations which are uncomplicated to construct the plastic skin-flap from the fibrocartilaginous canal wall and to close the posterior wound, as the final step. In case any considerable portion of the dural covering of the brain or the lateral sinus becomes exposed during the operation upon the bone, the closure

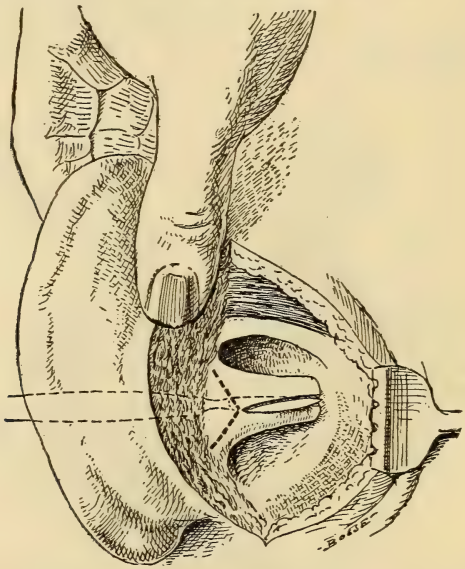

Fig. 206.—The primary incision in the construction of the Neumann modification of the Siebenmann meatal flap.

of the postauricular wound and the construction of the plastic flap should be delayed until all danger of complications has passed, a period ranging from eight to fifteen days.

All incisions into the cartilage of the auricle in connection with the construction of the skin-flaps should be clean cut and under strict asepsis, in order to avoid subsequent perichondritis. A few cases of perichondritis from this source have been reported wherein extensive and prolonged infiltration and suppuration ensued, and all terminated in extensive and deplorable external deformity.

Thiersch's Skin Grafts.

The extensive excavation of bone required by the radical mastoid operation leaves a considerable area of denuded bone surface. A portion of this surface we cover with the plastic flaps constructed from

the fibrocartilaginous canal wall, in the manner heretofore described. The dermatization of the remainder of the wound may be accomplished either by the gradual outgrowth of epithelium from the borders of the plastic flaps or by the transplantation of Thiersch's skin grafts.

Authorities are divided in opinion as to the results to be obtained from the transplantation of Thiersch's grafts into the radical mastoid wound cavity. The author believes that the average results obtained from carefully constructed plastic meatal flaps, when anchored in the most favorable location within the wound cavity, are fully equal to those obtained by the employment of skin grafts. It is true that occasionally brilliant results follow the successful transplantation of Thiersch's grafts, but, unfortunately, the proportion of such successes is inconsiderable.

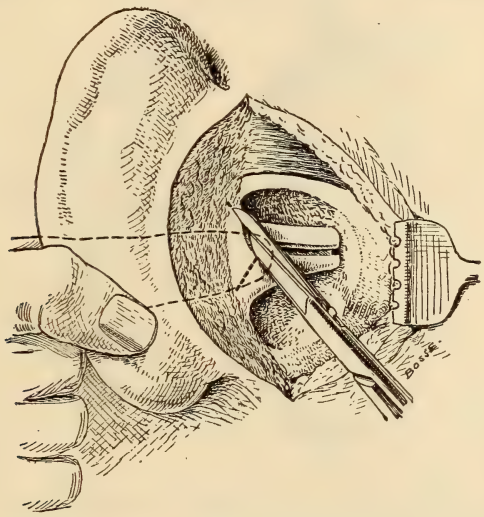

Fig. 207.—Completing the incision for the Neumann modification of the Siebenmann meatal flap with scissors. The position of the operator's finger in the external meatus is indicated by the dotted line.

Technique.—A section of the patient's arm or thigh, preferably the latter, should be surgically prepared for the removal of epidermis by being scrubbed and protected by a sterile bichlorid of mercury dressing.

A large razor, one surface of which is flat (Fig. 210), is most adaptable for the purpose of removing the epidermal graft. The razor should be dipped in warm normal saline solution and the surface of skin made flat and tense by the surgeon's hand drawing in one direction, and the hand of an assistant making similar traction in the opposite. Placing the edge of the razor upon the skin it is made to penetrate the epidermal layer. The blade is then laid flat upon the surface of the patient's skin and made, by a series of lateral sawing motions, to sever a section of epidermis of sufficient size to line the denuded bone cavity. By dropping warm saline solution

upon the razor while cutting the epidermal graft, the latter is kept floating and hence the edges do not curl.

The Ballance set of instruments, having been sterilized, are then employed for the purpose of transplanting the graft. By teasing the graft from the razor to the surface of the spatula (the size to be gauged by the dimensions of the graft), it becomes comparatively a simple process now to introduce it into the wound, where by employing the teasing probe it is gradually spread upon the denuded bone, there to be pressed securely and firmly in position.

The spreading of the graft usually requires considerable manipulation. Should blood accumulate underneath the graft it should be sucked out with a small glass pipette. In the same manner the accumulation of air bubbles may be removed.

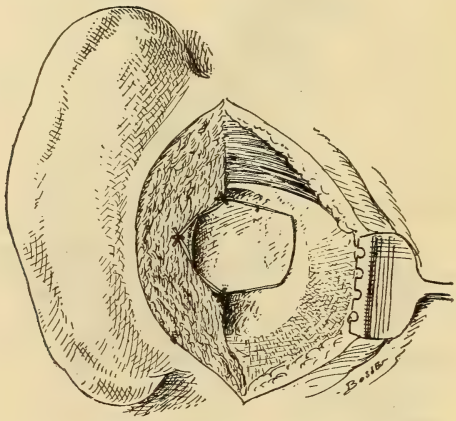

Fig. 208.—The Neumann modified flap completed. The V-shaped central flap is stitched to the soft tissues of the anterior lip of the post-auricular wound. (Diagrammatic.)

The grafts are maintained in position by means of sterile gauze packing, which must be carefully introduced. Unless symptoms arise which necessitate an examination of the wound cavity, the primary dressings should be allowed to remain undisturbed for from five to eight days. Aural surgeons are not in accord in regard to the most favorable time for introducing a Thiersch skin graft into the osseous mastoid wound.

Dench favors applying the graft at the primary operation. Ballance delays it for ten days. It seems incredible to expect an epithelial graft, when applied to a freshly denuded surface of bone, to "take." Nevertheless, according to Dench and others, such grafts do sometimes "take" seemingly without the intervention of granulations. It is probable that after an interval of eight to ten days from the primary operation the conditions are more favorable for skin grafting. It is both possible and feasible to introduce skin grafts through the enlarged external auditory meatus, into the wound cavity.

Closure of the Postauricular Meatal Wound.

Contrary to the rule followed in the simple mastoid operation, wherein the postauricular wound cavity is permitted to remain open and to heal by granulation from the bottom, in the radical mastoid operation, on account of the wide open drainage of all the middle-ear spaces into the external meatus, made possible by the extensive

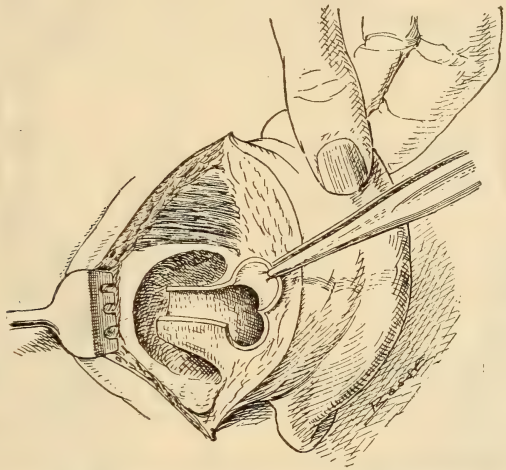

Fig. 209.—The Ballance meatal skin-flap.

removal of bone, the postauricular wound, with few exceptions, may advantageously be closed at the primary operation. The exceptions to this rule are described above under the heading "Precautionary Measures."

When the wound edges approximate without tension, ordinary catgut or silkworm gut sutures may be employed in closing the post-



Fig. 210.—A razor, with one flat surface, which is especially applicable for removing Thiersch's skin grafts.

auricular wound. Unfortunately, however, the approximation of the wound edges requires considerable tension, especially in patients who have submitted to previous simple or radical operations, and in whom much scar tissue is intermingled in the tissues about the former mastoid incisions. Hence some form of traction sutures should be employed for suturing this class of wounds in order to insure primary healing. To this end the so-called mattress suture (Fig. 211) has

been advocated by J. J. Thomson of the author's staff in the ear service of the Manhattan Eye, Ear and Throat Hospital. The mattress suture accomplishes the double purpose of producing traction upon the lips of the wound, and, by causing the wound

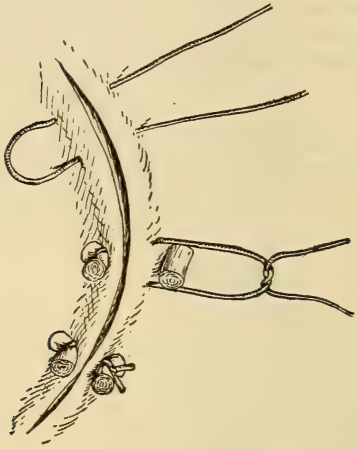

Fig. 211.—The mattress suture employed for closure of the post-auricular mastoid wound.

Fig. 212.—A mastoid wound closed by mattress sutures and re-inforced by interrupted sutures.

edges to protrude, a considerable area of the underlying denuded soft tissues upon either side are also brought into apposition, thus enhancing the probability of final healing throughout the wound.

Three mattress sutures, when re-enforced by a few interrupted sutures (Fig. 212), usually suffice to effectually close a post-auricular mastoid wound.

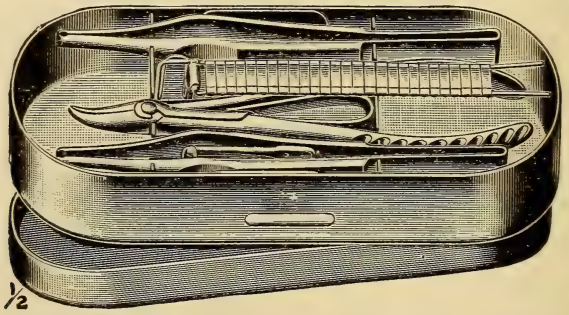

Fig. 213.—The Michel metal clamp suture outfit.

The same purpose is accomplished by employing the Michel metal clamp sutures (Fig. 213). When properly adjusted the metal clamp sutures succeed in producing considerable protrusion of the lips of the wound, and hence a wider area for final union is obtained (Fig. 214).

After having sutured the postauricular wound it is advisable to readjust the gauze packing. Hence, the primary packing of gauze is withdrawn through the enlarged meatal orifice. Under bright illumination the surgeon should then wipe away all blood-clots from the bone cavity, readjust the meatal skin-flaps if necessary, and repack the wound in its entirety. As a final step outer dressings and a retaining bandage should be applied, after the manner advised for dressing the simple mastoid wound (Figs. 156 and 157). The outer dressings may be discarded upon the healing of the postauricular wound and the removal of the stitches.

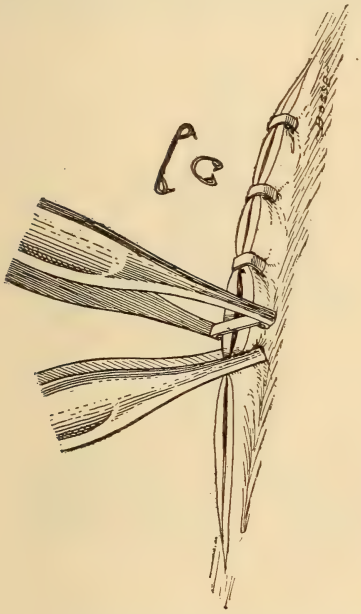

Fig. 214.—The technique of applying the Michel clamp suture to the postauricular mastoid wound.

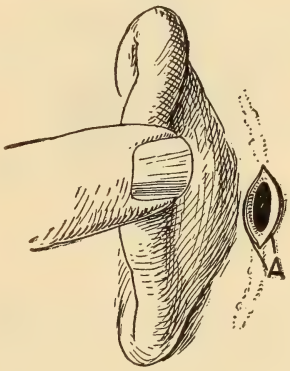

Fig. 215.—The first step in the closure of a postauricular fistula. The dark line *A* indicates the line of incision. (Passow-Trautmann method.)

Closure of Persistent Postauricular Openings.

Various plastic operative procedures have been devised for closing postauricular fistulous openings which communicate with the middle-ear spaces.

The Passow-Trautmann Method.—The steps of the operation are as follows:—

(*a*) A circular incision penetrating to the bone posteriorly and to the perichondrium anteriorly is extended around the outer marginal border of the fistulous opening (Fig. 215).

(*b*) The skin included within the incised area, including the periosteum, is then freely released from the bone and the margins are inverted sufficiently to bring the opposing free borders together with the dermal layer facing the middle-ear space.

(*c*) The opposing edges are then united by catgut sutures. Following the advice of Trautman the periosteal flap is closed by four sutures, two threads being inserted into each side (Fig. 216).

(*d*) Finally, the edges of the outer circle of the wound are freely elevated, then approximated and closed either with interrupted sutures or the Michel meatal clamp sutures (Fig. 214).

The Mosetig-Moorhof Method.—The Mosetig-Moorhof plastic flap is adaptable to the closure of small postauricular fistulous openings. The steps of the operation are:

(*a*) A U-shaped skin-flap is formed, similar to but larger in outline than the mouth of the fistula, and with its base or hinge at

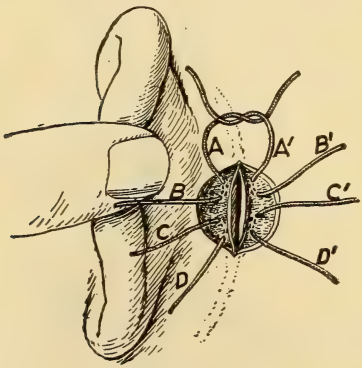

Fig. 216.—The second step in the Passow-Trautmann operation for closure of a postauricular fistula. The sutures *A, B,* and *C, D,* in the posterior lip of periosteal flap are to be united to the corresponding sutures upon the opposite side.

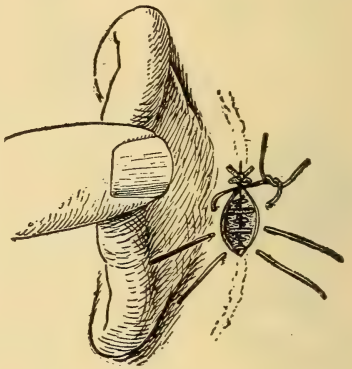

Fig. 217.—The first row of sutures have been tied, the knots being still visible. The outer row of sutures,—one tied, one ready to tie, and two remain untied.

the periphery of the fistulous opening (Fig. 218). This flap may be formed from behind or above the fistulous opening if necessary.

(*b*) An incision is then extended around the rim of the postauricular opening, except at the point which marks the pedicle of the skin-flap (Fig. 219). The outer edges of this incision are freely elevated from the bone.

(*c*) The oval or U-shaped skin-flap is then turned upward and laid over the fistulous opening with the dermal surface facing the middle-ear spaces. The edges are then approximated to the freshly denuded and loosened rim of the fistulous opening and retained in place with sutures (Fig. 220).

(*d*) Finally the skin wound from which the flap has been formed is closed by sutures (Fig. 221).

The Results of the Radical Mastoid Operation.

The results obtained by the complete radical mastoid operation, assuming that the treatment, both operative and postoperative, is up to the recognized standards, are favorable as a whole, but are influenced by the kind and nature of the pathological findings.

For instance, in tuberculous and syphilitic necrosis the results are less favorable than would otherwise be obtained, on account of the underlying constitutional dyscrasia.

At the Eastern Section Meeting of the American Laryngological, Rhinological and Otological Society, held in Philadelphia on January

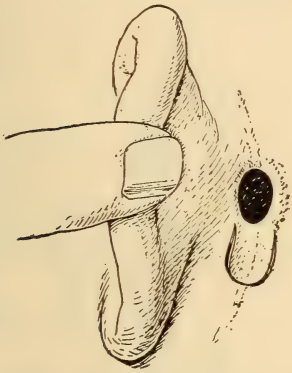

Fig. 218.—The incision shows the U-shaped skin-flap cut from the inferior margin of the post-auricular opening. (Mosetig-Moorhof method.)

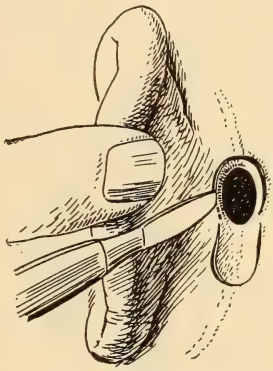

Fig. 219.—The second incision which releases the skin around the border of the postauricular opening. (Mosetig-Moorhof method.)

9, 1909, the author reported the results on the otorrhea, hearing and life from 123 radical mastoid operations as follows:—

The cases here reported do not cover any definite period of time, but are selected as a series which may fairly well represent the results of the complete operation.

In some instances the records are incomplete for certain of the results:—

1. The results on otorrhea.
2. The results on hearing.
3. The results on life.

On the otorrhea the results are recorded in 103 of the 123 cases.

Of the 103 recorded results there were 84 cures, and in 18 the discharge either persisted, became intermittent, or appeared in connection with occasional exfoliations of epidermis or cholesteatoma.

On the hearing the results are recorded in 75 out of the 125 cases.

Of these 75 cases the hearing was improved in 28, it was unchanged in 25, and it was impaired in 22.

On life out of 123 cases there were 7 deaths from complicating lesions. In none of the fatal cases save 4 did the operation hasten

the fatal issue, and in nearly all the radical procedure was but an incident in operating for the relief of complicating lesions, sinus-thrombosis, brain abscesses, and meningitis.

In one case, hereinafter reported (page 378), I discovered at the time of the radical operation a large abscess of the temporosphenoidal lobe, which never had given localizing symptoms or interfered with the usual duties of the patient.

Five of the 6 cases included in this list are of recent date, and the results are still uncertain.

On the Otorrhea.—The purulent discharge is cured whenever healthy dermatization of the entire cavity is complete. This is not possible in every case, inasmuch as in a limited proportion of cases the surgeon has to contend with impaired general health, con-

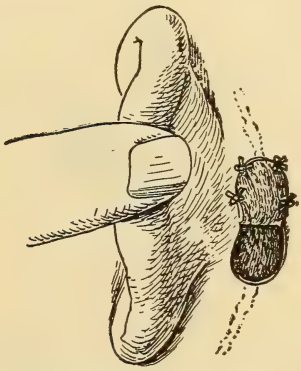

Fig. 220.—The third step. The skin-flap is turned upward and laid on the fistulous opening, where it is retained by sutures. (Mosetig-Moorhof method.)

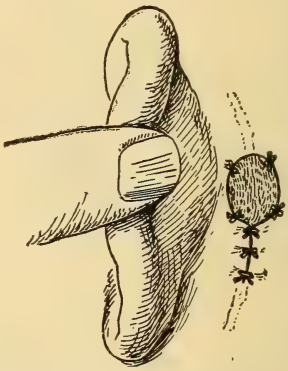

Fig. 221.—The final step in the Mosetig-Moorhof operation, consisting of the closure of the skin wound from which the skin-flap was constructed.

stitutional dyscrasias, and deep-seated disease of the more remote areas of the ear, especially the Eustachian tube.

Even though a slight postoperative discharge persists, the operation accomplishes the removal of large areas of the necrosed bone and granulations, and opens up the entire field to inspection and local treatment. Any remaining discharge is usually without danger to the patient's life.

On Life.—Inasmuch as this operation upon the temporal bone serves to eradicate an infective necrotic process from an area which is in close proximity to the cerebrum, cerebellum, lateral sinus, labyrinth and facial nerve, it becomes, when timely performed, a life-saving measure. Clinical experience furnishes abundant proof of this assertion.

On Hearing.—The operation never is performed in the interests of the hearing function, and a statement to that effect should be made to the patient before operating. Nevertheless, the hearing results are of much interest and importance. Providing the laby-

rinth is intact and no inflammatory adhesions exist, the hearing either remains the same or is improved by the operation. It is made worse in but a very small percentage of cases.

Finally, regarding the effect upon the hearing function, the operation accomplishes the removal of adventitious tissue of a dangerous type from the temporal bone and middle ear, and converts the membranous linings into epithelium free from necrotic foci.

The results herein enumerated do not materially differ from those reported by Grünert, Trautmann, Grossman, Stacke, Dench and others.

In the above remarks I have referred only to the complete radical operation. Attempts have been made from time to time, first by Körner, and later by Heath, in England, and Bryant and Ballenger, in America, to modify the operation by leaving the ossicles and membrana tympani intact, in the hope of bettering the hearing results. They are all incomplete operations, inasmuch as the annular ring, the outer wall of the attic and the ossicles, three of the chief centres of necrosis in this disease, are necessarily left untouched. The author is extremely skeptical regarding favorable results from any incomplete operation in cases of extensive necrosis of the tympanic wall, ossicles, aditus, and mastoid antrum.

The Postoperative Treatment of the Radical Mastoid Operation.

Proper after-treatment of the radical mastoid wound is essential to the final success of the operation—in fact, the surgeon must possess the same measure of knowledge and skill in the technique of the post-operative treatment of the wound as for the operation itself, inasmuch as many failures are directly due to careless or unskillful after-treatment. Therefore, no surgeon should undertake the management of a case requiring the radical operation unless either he or a competent substitute is prepared to bestow the required time and skill until final healing has taken place. The period covered by the after-treatment varies from one to three months. The primary gauze packing in the operative cavity under usual circumstances should not be changed until about the seventh day. The external dressings should be renewed daily and the postauricular wound inspected until the latter is healed, which is usually from five to six days. The object of the daily change of outer dressings is to discover stitch infections and to keep the wound dry. As soon as firm union has taken place the sutures should promptly be removed, and should any single suture become infected its early removal is advised. The outer dressings may be discarded as soon as the postauricular incision is healed.

Care must be exercised in removing the primary packing from the osseous wound cavity in order not to disturb or displace the meatal flaps or give the patient unnecessary pain. Some difference of opinion exists as to the pressure with which the gauze should be packed into the cavity after the first few dressings. Two general views obtain at the present time. There are those who prefer very tight packing and

those who do not tampon the cavity at all, each claiming good results. Between these extreme views all grades of pressure have their advocates. Formerly, it was the opinion of the majority of authorities that tight packing was essential for the control of the granulations and to hasten epidermization. Better results have been obtained by the author when the middle-ear spaces have been snugly packed at each dressing, inasmuch as he has thereby been enabled to prevent the osseous wound cavity from becoming completely filled with granulations.

The posterior or mastoid portion of the cavity should be very lightly packed, thus allowing granulations to fill the deeper areas. By so doing the surface requiring dermatization is proportionately lessened and without detriment. The granulations must be carefully watched and not allowed to become exuberant and flabby, inasmuch as granulations of this type offer a serious barrier to the line of epidermatization

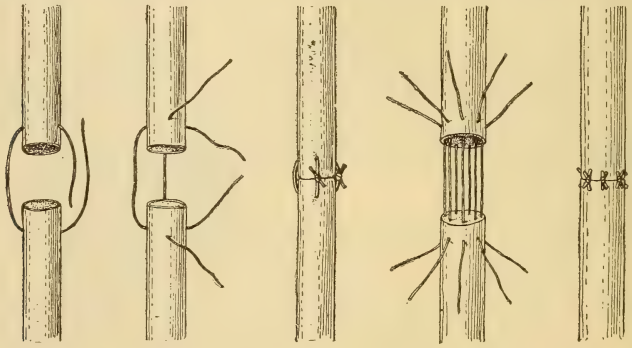

Fig. 222.—The methods of suturing to be followed in the end-to-end anastomosis of nerve trunks. (Schematic.)

that should extend in all directions from the flap margins. Excessive secretions, by bathing the granulating surfaces, render them soft and flabby and macerate the epithelial surfaces. On this account the cavity should be kept as dry as possible, daily dressings frequently being necessary for this purpose. In some instances it may become necessary to apply caustics to exuberant granulations. Silver nitrate or orthochlorophenol applications are effective in subduing excessive granulations. It very rarely becomes necessary to stimulate the granulations, but if so balsam of Peru aplied to the sluggish areas, or the substitution of iodoform gauze for the plain gauze packing, usually produces the desired results. In stubborn cases the author obtains excellent results, both in subduing unhealthy granulations and in promoting epidermization, by packing the granular surfaces with tampons covered with a 20 per cent. scarlet-red ointment.

With the diminution of the secretion the surface of the cavity should be covered with boric acid powder or aristol, or a mixture of these, before replacing the tampon. Under the most favorable circumstances six to eight weeks usually elapse before epidermization is complete, and a much longer time is often necessary, but the tampons are rarely of service after the third or fourth week.

The Medicinal, Mechanical and Surgical Treatment of Facial Paralysis of Otitic Origin.

Medicinal.—Drugs are of but little avail in the treatment of this type of facial paralysis. Such remedial measures as tend to stimulate the digestive functions and correct faulty nutrition should be employed. For this purpose the moderate use of salines and the internal administration of iron and strychnia or the iodin compounds are recommended. Meanwhile, advantage should be taken of all opportunities for improved hygiene and nutritious diet. Mechanical massage of the paralyzed muscles and the employment of the faradic current have long been advocated as remedial measures in cases of injury without destruction of the nerve trunk. These measures may

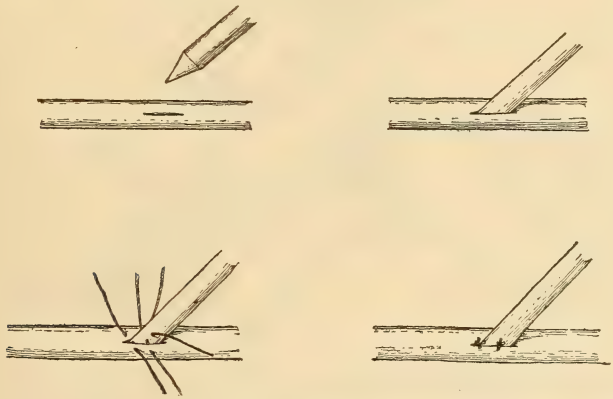

Fig. 223.—Schematic illustration of the lateral implantation method of anastomosis of nerves.

hasten the recovery of function, and, even when the nerve trunk has been severed, aid in preventing muscular atrophy during the period in which the hope of final recovery may be entertained. An individual of ordinary intelligence may be taught both to apply massage and the interrupted current to his own face.

Surgical Treatment.—Attempts have been made, and apparently with some degree of success, to restore the function of the nerve by grafting the distal end of the severed facial nerve into the trunk of either the hypoglossal or spinal accessory nerve of the corresponding side, preferably the hypoglossal. The splicing of nerves after this manner produces an interchange of function; hence the functional disturbance will be less noticeable when the facial nerve is spliced to the hypoglossal than when joined to the spinal accessory. Taylor, Frazier and others have reported successful cases, especially when the operation of anastomosis has not been too long delayed. Knowing that restoration of function, in many cases of injury to the facial nerve, occurs even after a considerable lapse of time, it becomes somewhat difficult to decide upon the exact time when the anastomosis operation should be performed. Positive knowledge that the nerve trunk has

been completely destroyed throughout a considerable portion of its course warrants immediate resort to operative procedures.

There are two general methods of uniting nerve trunks for the purpose of anastomosis: (*a*) by end-to-end anastomosis; (*b*) by lateral implantation.

(*a*) End-to-end Anastomosis.—Of the two methods, that known as end-to-end anastomosis is simpler in technique and therefore requires less surgical skill, but it possesses the disadvantage that it requires complete severing of the healthy nerve, which invariably is followed by paralysis of the muscles which it supplies.

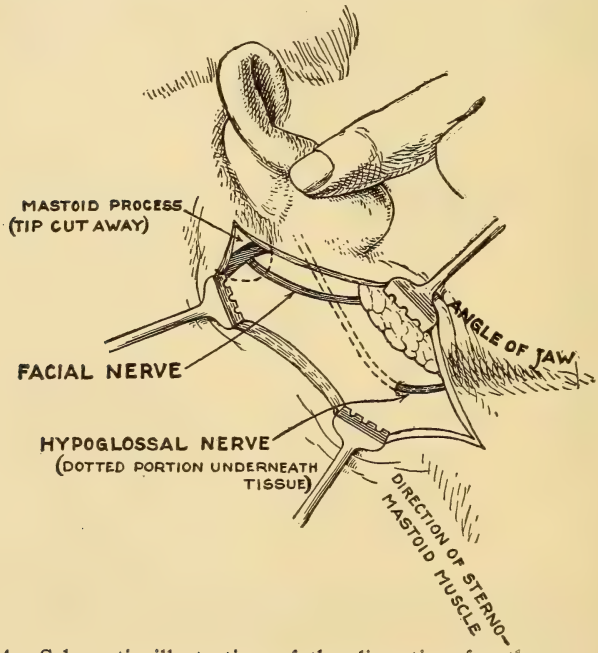

Fig. 224.—Schematic illustration of the dissection for the anastomosis of the facial nerve with the hypoglossal nerve.

Inasmuch as equally good results are obtained by following the second (lateral implantation) method, and without permanent loss of muscular power, the end-to-end method is now rarely employed. If end-to-end anastomosis of the facial nerve is desired, it should be united with the hypoglossal nerve, both nerves being exposed in the manner hereinafter described for lateral implantation.

The paralyzed segment of the facial nerve is dissected from a point slightly within the mastoid tip, where it is joined to the central segment of the severed hypoglossal nerve (Fig. 222).

(*b*) Lateral Implantation.—The favored method of lateral implantation is accomplished by implanting or grafting the paralyzed segment of the facial nerve into the body of the hypoglossal nerve through a longitudinal slit (Fig. 223).

The Technique of Faciohypoglossal Anastomosis.—An incision is made along the anterior border of the sternocleidomastoid muscle, from its attachment to the tip of the mastoid process to the end of the cricoid cartilage. After dividing the skin, superficial fascia, and platysma myoides, by separating the lips of the wound the sternocleidomastoid muscle is revealed. This muscle is then retracted posteriorly and the parotid gland is exposed and turned forward. The deep fascia is then freely incised and retracted, thus revealing the posterior belly of the digastric muscle. This muscle, together with the occipital artery at its junction with the carotid artery, serves to guide the operator to the hypoglossal nerve. The nerve is sought at this point by means of a blunt dissector. When found it should gently be raised from its bed and drawn forward to a convenient site for the anastomosis procedure.

Since Duel and Frazier advocated the removal of a small section of the mastoid tip for the purpose of securing a longer portion of the nerve trunk, this point rather than its point of entry into the parotid gland is favored for locating the facial nerve.

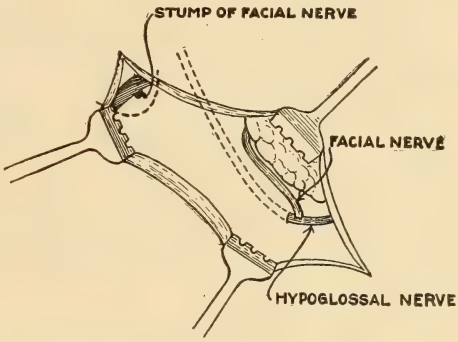

Fig. 225.—Schematic representation of the anastomosis of the severed end of the facial nerve with the hypoglossal nerve by lateral implantation.

In his later operations Taylor has adopted this method and considers it to be the quickest and surest method of securing a sufficient length of the trunk of the facial nerve for anastomosis. The facial nerve trunk is then gently raised from its bed and severed as high up as possible in the Fallopian canal (Fig. 224). The distal section of the nerve is then turned downward. A small portion of the sheath of its proximal end should then be removed, in order that its axis cylinders, when grafted into hypoglossal, may come into direct contact with those of the latter nerve.

A longitudinal slit is then made into the sheath of the hypoglossal nerve, into which the proximal stump of the facial nerve is inserted, care being exercised to ingratiate its fibres into the fibres composing the hypoglossal nerve trunk, but directed toward its proximal end. The grafted end of the facial nerve is then anchored into its position by means of fine-silk sutures, introduced by small, round, curved needles (Fig. 225). Taylor contends that wrapping the junction of the two nerves with Cargile membrane tends "to prevent the ingrowth of connective tissue into the field of the anastomosis."

The deep tissues are then as nearly as possible replaced into normal position and the external wound united by sutures. The postoperative treatment consists in the continuation of the medicinal and mechanical measures advocated in foregoing paragraphs, to the end that "returning nerve power may find good muscle to work on." (Taylor.)

CHAPTER XXIII.

COMPLICATING LESIONS OF PURULENT OTITIS MEDIA.

PURULENT LABYRINTHITIS.

SECTION I—INTRODUCTORY.

(*a*) **Explanatory Note.**—Before considering in detail the question of labyrinthine suppuration, Section I of the present chapter describes the experimental methods devised for investigating the irritability of the vestibular apparatus. The information presented is in the main the elaboration of notes of the lectures delivered by Neumann, of Vienna, during his visit (1910) to America.[1]

In the rotation tests he describes the two horizontal canals as acting simultaneously and, when the head is flexed either forward or backward, the two superior canals as acting simultaneously. The posterior canals are ignored on the ground that, although they may be excited by rotation with the head down on either shoulder, we are unable to determine from which ampulla the centre is stimulated, as both are occupying the same relative position.

He further affirms that excitation of a centre from a horizontal canal produces horizontal nystagmus, and from a superior canal rotatory nystagmus.

This is evidently faulty from the anatomical standpoint, as it has been demonstrated that the plane of the superior canal on one side corresponds to the plane of the posterior canal on the other, and *vice versâ*. It would therefore seem to follow that the rotatory nystagmus produced by turning with the head bent forward or backward is the resultant of the action of a superior and posterior canal, and not the effect of stimulation or inhibition through a single superior canal.

Nevertheless the information is submitted for the reason that it offers a practical and useful method of arriving at a definite conclusion with regard to the irritability or non-irritability of the vestibular apparatus.

(*b*) **Symptoms Referable to Interference with the Function of the Vestibular Apparatus.**—There are three principal symptoms directly referable to interference with the function of the vestibular apparatus. They are: 1, vertigo; 2, nystagmus; 3, disturbances of equilibrium.

It should be noted that these symptoms are in the first place due to irritation of the vestibular apparatus on the diseased side, and that the direction of the nystagmus, the apparent motion of surrounding objects, and the direction in which the patient tends

---

[1] The author is indebted to his colleague, Dr. John B. Rae, for extending his notes of these lectures to form Section I of this chapter.

to fall can be determined as being the result of stimulation of the centre on that side. Later, mainly within a very short period of time in acute diffuse cases, the spontaneous nystagmus and the disturbances of equilibrium are found to be the result of stimulation of the centre on the sound side. This is not, however, a real stimulation of that centre, but is rather to be explained on the ground that, the end organs of the vestibular nerve on the diseased side having been destroyed and no stimuli therefore reaching that centre, the centre on the sound side overbalances the other, and the later nystagmus and disturbances of equilibrium result. These symptoms rapidly disappear as the centres accommodate themselves to altered conditions, and will not be observed at all unless the patient is seen at an early stage of labyrinthine involvement.

The diagnosis of destruction of the labyrinth is therefore usually to be made on the *induced* rather than on the *spontaneous* symptoms.

Vertigo.—Vertigo is the subjective sensation which a patient experiences when one or other of the tracts governing equilibrium is suddenly disturbed. These tracts are three in number: 1, the vestibulo-ocular; 2, the vestibulo-spinal; 3, the vestibulo-central.

The vestibulo-ocular tract is connected through Deiters's nucleus and the fasciculus longus with oculo motor nuclei.

The vestibulo-spinal tract connects with the cord and has to do with the maintenance of muscle tone necessary for equilibrium.

The vestibulo-central tract connects with the higher centres in the cerebrum.

Destruction of any one of these tracts will result in vertigo and disturbances of equilibrium. By training, the remaining two tracts will accustom themselves to altered conditions and equilibrium will be restored.

The commonly experienced tendency to fall on looking from an unaccustomed height is explained by disturbance of the vestibulo-ocular and vestibulo-spinal tracts.

In cases exhibiting spontaneous vestibular vertigo and nystagmus, the apparent motion of surrounding objects and the direction in which the patient tends to fall follow certain definite laws which can best be remembered with relation to the nystagmus.

The rule is that surrounding objects apparently move in the direction of the quick component of the nystagmus, and the patient tends to fall in a direction opposite to that of the quick component of the nystagmus. This direction of falling can be altered by changing the position of the patient's head.

For example: If the patient have nystagmus to the left—that is, the quick component of the nystagmus motion is to the left—he will tend to fall to the right. If now the patient's chin be turned toward the left shoulder, he will tend to fall forward, and, if the chin be turned toward the right shoulder, he will tend to fall backward.

This change of the direction of falling is characteristic of disturbances of equilibrium of peripheral vestibular origin, and in this manner such disturbances of equilibrium can be differentiated from those due to other causes.

The tendency for the body to fall following vestibular stimulation has a counterpart in the deviation of the extremities. Both the tendency to fall and the deviation of the extremities occur in the plane or the planes of those semi-circular canals in which the stimulation is aroused. The phenomenon of falling and deviation are known as the reaction movements.

In addition to the nystagmus, vertigo, nausea and vomiting we formerly believed that the so-called reaction movements followed stimulation of the labyrinthine end organs as a reflex. Because of the uniformity of the nystagmus the direction of the reaction movements was expressed in terms of the former; thus we said that the reaction movements of the body and of the extremities were always in the direction of the slow component of the nystagmus.

It was understood that there was no direct connection between the nystagmus and the reaction movements. From more recent work on the physiology of the labyrinth it appears that our conception of the reaction movements as a reflex originating in the cerebellum, and influenced by the cerebrum, is erroneous. The reaction movements are the objective expression of the vertigo and in all probability are cerebral in origin.

The vertigo of vestibular origin is frequently associated with nausea and vomiting.

Nystagmus.—Nystagmus may be defined as oscillation of the eyeball. It varies in degree and may be easy or difficult of detection. It may be elicited in any position of the eye, or only in extreme abduction, according to the amount present. Its origin may be vestibular, ocular or central.

Ocular nystagmus is undulatory and is to observed in any position of the eye. The excursion of the globe in one direction is equal to that in the other, both as regards extent and rapidity. Vestibular nystagmus is rhythmic and consists of two components—a slow vestibular component, and a rapid cortical movement in the opposite direction. The nystagmus is named from the direction of the quick component, and not from the slow vestibular component as might be expected.

The eyeball is in equilibrium when the impulses from the vestibulo-ocular apparatus on both sides are exactly balanced by the impulses from the cortical apparatus. Nystagmus results when one center in the vestibulo-ocular apparatus does not balance the other. When great in amount vestibular nystagmus can be observed in any position of the eye, but when small in amount it can only be elicited in extreme abduction in the direction of the quick component. In a certain proportion of normal cases a small amount of nystagmus can be obtained on extreme abduction to the right and to the left. This is equal in amount on both sides, and is physiological.

(*c*) **Induced or Experimental Evidence of Labyrinthine Involvement.**—It should be clearly understood that the tests to be briefly described below are employed to distinguish between an irritable or functionating vestibular apparatus and a non-irritable or destroyed labyrinth.

In dealing with these experimental tests there are certain fundamental laws which must clearly be borne in mind before the tests can rightly be applied and correct deductions from their results made.

Ewald's Experiment.—It will be enough to state that Ewald demonstrated that the endolymph movements in the different canals, either in the direction of the utricle or toward the non-ampullated ends, resulted in definite movements of the head, with corresponding eye movements.

His method was to open a canal and by a suitable plug to occlude completely the membranous portion. At a position nearer the ampulla a second opening was made through the bony wall of the canal and a small piston introduced. This piston was in communication with a bulb, so that by compression or aspiration the endolymph could be moved at will, either toward or away from the ampulla.

Hoegye's Law.—Hoegye demonstrated that, when the centre of one side was stimulated from the vestibular apparatus, the adductor ocular muscles on the same side, and the abductor muscles on the opposite side contracted, resulting in a slow conjugate movement of the eyes in a direction away from the stimulated centre. Thus, stimulation of the right centre brings about a slow movement to the left and *vice versâ*.

This is a very important law, and it should be noted, remembering that nystagmus is named from the quick cortical movement, opposite in direction to the slow vestibular component, that nystagmus to the right is the result of stimulation of the right centre, and nystagmus to the left, the result of stimulation of the left centre. If now to these two fundamental laws be added the results of endolymph movements in different directions in the different canals, we shall have data from which to draw deductions when the experimental tests are applied.

Movement of the endolymph in a given canal is either toward or away from the utricle. The moving endolymph will change the direction of the ampullary cilia, which will either be directed toward the utricle or toward the non-ampullated end of the canal. In the case of the *horizontal canal,* movement of the cilia in the *direction of the utricle* will result in *stimulation of the vestibular centre on that side,* while movement of the cilia *toward the non-ampullated end* will result in *inhibition* of that centre.

With the *superior canal,* conditions are exactly opposite. Ciliary movement *toward the non-ampullated end* will give rise to *stimulation* of the centre on the same side, while ciliary movement *toward the utricle* will determine *inhibition.*

It is here again repeated that our knowledge of this intricate subject is as yet so restricted that these laws are submitted, only at their true value as offering a fairly reliable working method toward determining the condition of the vestibular apparatus.

Briefly to recapitulate, it should be borne in mind that, in the horizontal canal, movement of the endolymph and cilia toward the utricle stimulates the center on the same side. In the case of the superior canal that movement of the endolymph and cilia toward the non-ampullated end stimulates the centre on the same side, and that stimulation of a

centre brings about contraction of the adductor ocular muscles on the same side and of the abductor ocular muscles on the opposite side.

Experimental Tests.—The methods by which the vestibular apparatus may be experimentally stimulated are four in number and are known as the Rotation, Caloric, Fistula and Galvanic tests.

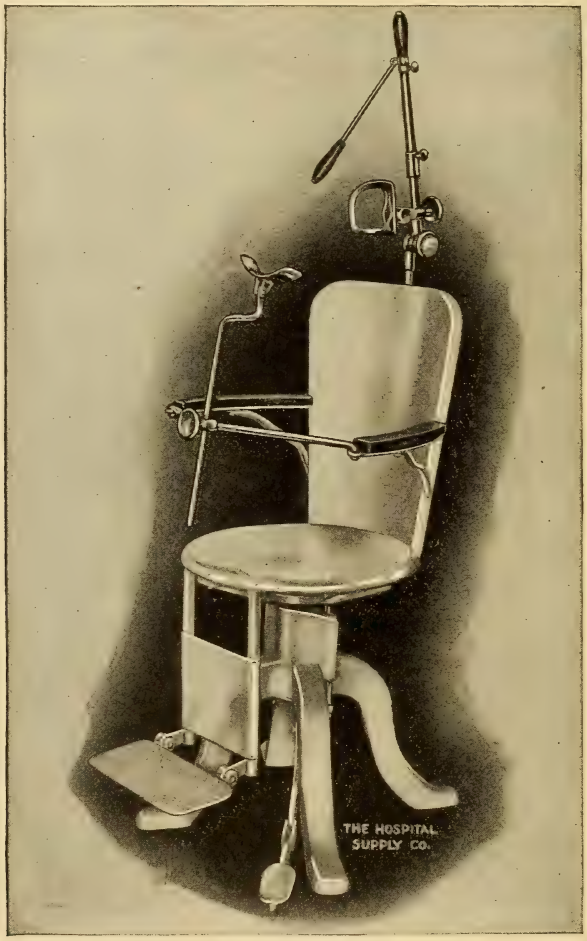

Fig. 226.—The Phillips-Friesner improved Barany-Jones revolving chair with (*a*) special irrigating attachment. Ease of rotation is secured by means of the horizontal whirling handle. Both head-rests are adjustable.

The first three depend for their recognition upon the ciliary movements, and the laws described above must be applied in estimating their results.

Rotation Tests.—If a vessel containing water be rotated on an axis at right angles to the surface of the fluid, the water is at

first left behind, gradually acquires the speed of the rotating container and, on rotation being suddenly stopped, continues moving in the direction of the rotation. This is the principle applied in the rotation tests. It will therefore be observed that the first effect of rotation will be that the endolymph in the canals affected will be left behind, and the ampullary cilia will have their direction altered accordingly. Nystagmus will result but will not be noted on account of the continuance of rotation. When rotation ceases and the endolymph continues in motion, the direction of the cilia will again be altered, and nystagmus will again result. This *can* be observed, and it is this so-called "after-nystagmus" alone which proves of value in our observations.

It is evident that the *primary nystagmus* will always be in the direction opposite to that of the *after-nystagmus.* It is also evident that *those canals alone will be affected by rotation whose planes are at right angles to ths axis of rotation.*

If, then, a patient is seated in a suitable revolving chair (Fig. 226), head erect, and is rotated to the right ten times, the horizontal canals, whose planes are now at right angles to the axis of rotation, will be affected. On rotation ceasing, the endolymph in the left canal will have a motion in the direction of the utricle, while that in the right canal will have a motion in the direction of the non-ampullated end. If we now apply our laws, we reason that the left centre is stimulated while the right centre is inhibited. The left centre being stimulated, Hoegye's law reminds us that the adductor muscles of the left eye and the abductors of the right contract, giving rise to a slow, vestibular movement to the right. This is corrected by a quick cortical movement in the opposite direction, and the repetition of these movements results in a prolonged nystagmus to the left. This is diagrammatically represented in Fig. 227.

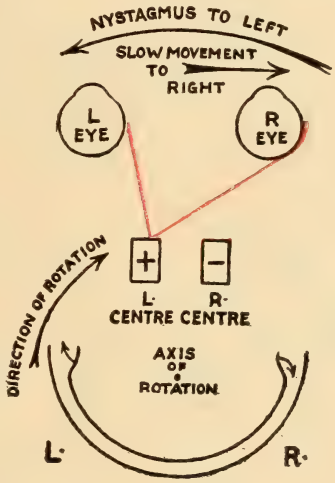

Fig. 227.

It will be noted that the two canals, for diagrammatic purposes, are joined together, so that the drawing shows both ampullated ends, the non-ampullated ends being united. The arrows in the ampullæ indicate the direction of the cilia after rotation. The left centre being stimulated, the red lines show the adductor muscles of the same side and the abductors of the opposite side in contraction.

Rotation of the patient to the left will produce a nystagmus to the right of equal duration. This can be diagrammatically expressed in a manner similar to that for rotation to the right.

The plane of the superior canals may be brought at right angles to the axis of rotation by bending the head of the patient either forward or backward, at an angle of 90°. The result of rotation can be reasoned out as before. Thus, with the head bent forward, the united superior canals can diagrammatically be represented as a semicircle with the ampullated ends opening backward. If the patient be now rotated ten times to the right and stopped, the after-flow of the endolymph will carry the cilia on the left side in the direction of the non-ampullated end, and on the right side toward

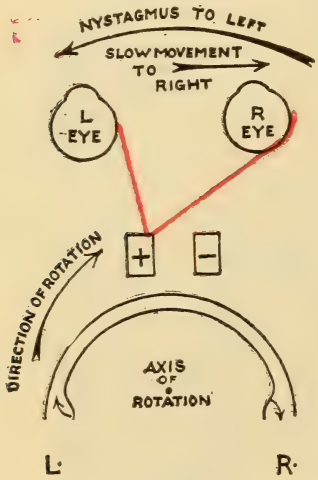

Fig. 228.

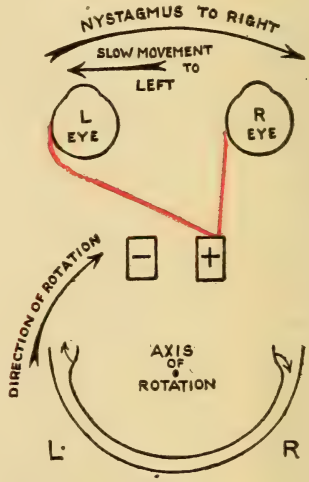

Fig. 229.

the utricle. Applying the rule, we find the left centre to be stimulated and the right centre to be inhibited.

Following Hoegye's law, we will have slow vestibular movements of the eyes to the right, with quick cortical corrections to the left, resulting in a prolonged rotatory nystagmus to the left. This is diagrammatically represented in Fig. 228.

Rotation to the left with the head bent forward will in a similar manner give a prolonged rotatory nystagmus to the right.

With the head bent backward, the united superior canals form a semicircle open in front. After rotation to the right in this position, the ampullary cilia on the left side will be directed toward the utricle, and those on the right toward the non-ampullated end. Again applying the rule, we find the right centre to be stimulated and the left inhibited. There accordingly ensues a series of slow vestibular movements of the eyes to the left, with quick cortical corrections to the right, resulting in a prolonged rotatory nystagmus to the right. This is diagrammatically represented in Fig. 229.

Rotation to the left with the head backward will give a prolonged rotatory nystagmus to the left and can be reasoned out and represented as before.

Before applying these tests the patient should be examined for physiological nystagmus, and taught to follow the movements of the finger in front of the eye.

Immediately after turning, the upper lid of the eye on the side of the expected nystagmus should be elevated, and reflected light from a head-mirror thrown on the globe. The duration of the nystagmus from the cessation of turning until the disappearance of the nystagmus should be carefully noted for each direction of rotation. Just after rotation the nystagmus will be evident in all posi-

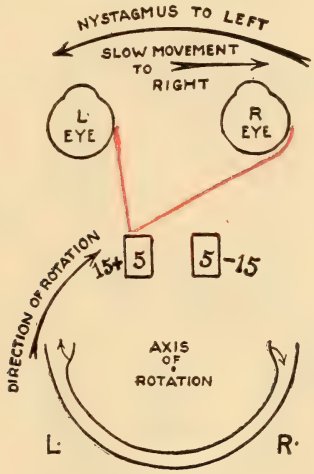

Fig. 230.

tions of the eye, but, as the intensity diminishes, the eye should be abducted in the direction of the quick component.

As a rule it will be sufficient to test for rotation reactions with the head erect. But, inasmuch as the horizontal canals are most frequently employed in our everyday movements, they may be difficult of excitation, and a comparison of the results of rotation to right and left may be unsatisfactory and undecisive. In such a case one of the other positions must be resorted to, and, while both are disagreeable to the patient, that with the head bent forward is less so, and is therefore to be selected in preference to the other.

Before considering the difference in the duration of the after-nystagmus when one vestibular apparatus is not functionating, the following diagram is inserted to show how the duration of nystagmus may be expressed in terms of quantity. In this diagram the normal tonus of each centre is represented by the numeral 5, and the amount of stimulation or inhibition reaching the centre from the peripheral apparatus by the numeral 15.

Let the patient be rotated to the right, head erect (Fig. 230).

Before rotation the two centres balance each other with a normal tonus of 5.

After rotation, the left centre receives an added stimulus of 15, so that it is now raised to the value of 20.

The right centre is inhibited to the extent of 15, so that its value is now equal to zero.

Left centre before rotation = 5
Right centre before rotation = 5
Left centre after rotation = 20
Right centre after rotation = 0

The balance between the centres is very evidently disturbed in favor of the left and there must result a prolonged nystagmus to the left.

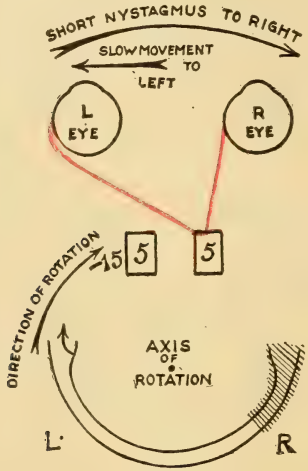

Fig. 231.

With the quantitative method understood it is comparatively a simple matter to reason out what must happen when one vestibular apparatus is not functionating, and the patient is submitted to rotation to right and left with head erect or bent forward or backward.

The two following diagrams will be sufficient to show how this is done. We will suppose the right labyrinth to be destroyed and the patient rotated first to the right and then to the left with the head bent backward, at 90°, thus bringing the plane of the superior canals at right angles to the axis of rotation.

Rotation of patient to the right, head bent backward, right vestibular apparatus destroyed (Fig. 231).

Before rotation right centre = 5
Before rotation left centre = 5

After rotation the right centre remains as before, no stimulus reaching it from the destroyed vestibular apparatus, $\therefore = 5$.

After rotation left centre is completely inhibited, $\therefore = 0$.

The balance between the centres is disturbed but only to a small extent, with the result that we expect a *short* rotatory nystagmus to the right.

Rotation of patient to the left, head bent backward, right vestibular apparatus destroyed (Fig. 232).

Before rotation the right centre..... = 5
Before rotation the left centre..... = 5
After rotation the right centre remains unaffected..... = 5
Left centre receives added stimulus of 15 and therefore equals 5 + 15 = 20

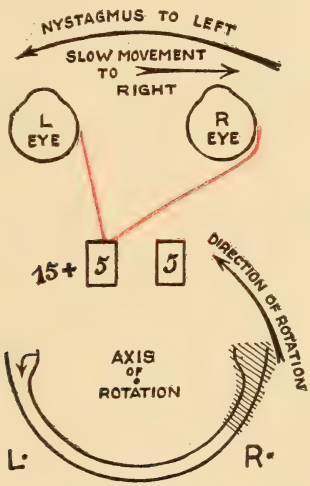

Fig. 232.

The balance between the centres is again disturbed, but now to a marked degree, resulting in a *prolonged* rotatory nystagmus to the left.

It will now be understood that even with one vestibular apparatus completely destroyed there will be nystagmus on rotation in both directions. As previously stated, nystagmus to the right is from overbalance of the right centre, and nystagmus to the left from overbalance of the left centre. But a glance at the first of these two diagrams will show that the overbalance of the right centre is not due to added stimulus of that centre but to complete inhibition of the other. Hence it follows that, whatever be the position of the head, the patient must be rotated to the right, the duration of the nystagmus noted, and then rotated to the left and a similar observation made. Our deduction is to be made from a comparison of these two figures. There is considerable room for error, because our methods are not mathematically exact and due allowance for this must be made. If the duration of nystagmus on

one side is half the duration of the other, it is not safe to conclude that the vestibular apparatus on the side of the shorter duration is destroyed. Other tests must be employed. But, if the duration of nystagmus on one side is one-third or less than one-third that of the other, it is strong presumptive evidence of the destruction of one vestibular apparatus.

To take a concrete example: Suppose that after rotation to the right in the erect position a patient exhibits nystagmus to the left for thirty-five seconds and after rotation to the left he exhibits nystagmus to the right for eight seconds.

It is evident that the same amount of stimulation is not reaching each centre from its corresponding vestibular apparatus on rotation, and, remembering that nystagmus to the right is the result of stimulation of the right centre, it is easy to conclude that the right vestibular apparatus is not functionating.

Caloric Reactions.—The caloric reactions are due to endolymph movements as are the *rotation reactions,* but are obtained by the application of heat or cold to the outer labyrinthine wall. It is a well-known physical law that, if heat be applied to a vessel containing fluid, a current in the fluid will be set up in a direction upward from the point of application of the heat. Conversely, if cold be applied, the current in the fluid will be in a downward direction. If we consider the canal system as a vessel containing fluid and direct a stream of water above the body temperature through the external meatus against the outer labyrinthine wall, there will result a slight movement of the endolymph vertically upward in all the canals. But it is evident that only in that particular canal whose ampulla occupies a vertical direction—that is, whose long axis is at right angles in a vertical direction to the stream of hot water, will there be a corresponding change of direction of the ampullary cilia. Thus, with the head erect, injection of hot or cold water will alter the direction of the cilia in the superior canal alone. With the head bent forward or backward at an angle of 90° the change of direction of cilia will occur in the horizontal canal.

If we remember Hoegye's law, and also the rule that, in the external semicircular canal, movement of the cilia toward the utricle causes stimulation, and that, in the superior canal, movement in the direction of the non-ampullated end causes stimulation, we are ready to reason out the results of the application of heat or cold in the different positions of the head.

The following diagram illustrates the effect of syringing the right ear with water above the temperature of the endolymph, the head being erect (Fig. 233):—

It will be noted that after sufficient irrigation the cilia in the ampulla of the superior canal will have a direction toward the non-ampullated end. This is the direction of stimulation, and, accordingly, applying the law of Hoegye, there will result slow vestibular movements of the eyes to the left, each corrected by a quick cortical movement to the right—in short, there will be evident a nystagmus to the right.

If cold water be used the cilia will be directed toward the utricle. This being the position of inhibition, the left centre overbalances the right and there accordingly results a series of slow vestibular movements to the right with quick corrections to the left, or, in brief, nystagmus to the left.

The following diagram illustrates the effect of syringing the left ear with cold water, the head being bent forward at an angle of 90°. We are now, therefore, dealing with the horizontal canal (Fig. 234) :—

After irrigation, the cilia will be directed toward the utricle, which is the position of stimulation. The left centre being the more active,

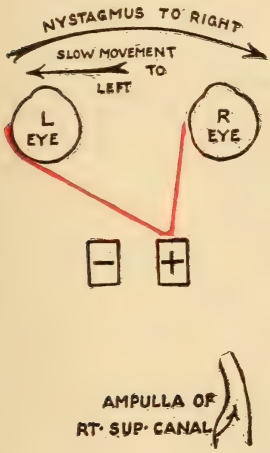

Fig. 233.

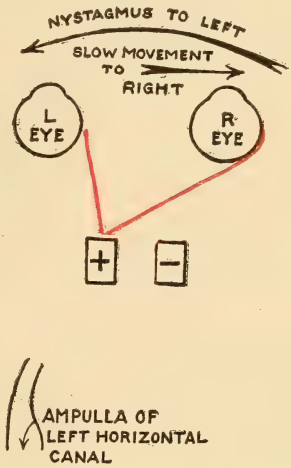

Fig. 234.

the slow vestibular movements are to the right, with the rapid cortical corrections to the left. There results nystagmus to the left.

If hot water be used the after-position of the cilia will be toward the non-ampullated end. This being the position of inhibition the right centre becomes the more active, with a resulting nystagmus to the right.

With the head bent backward at an angle of 90° the results can be reasoned out in a precisely similar manner.

The caloric tests are applied to distinguish between a functionating and a non-functionating vestibular apparatus. Even with a functionating apparatus they may fail because of our inability to raise or lower the temperature of the endolymph in the presence of polypi, excessive granulation or cholesteatomatous masses. Coagulation of the endolymph may also on certain occasions be the cause of failure of the caloric reactions.

In applying the tests a graduated irrigator should be employed so that the exact amount of water necessary to begin the nystagmus may be accurately noted. The temperature of the water should also be exactly determined by the use of a thermometer. The examiner should raise the upper lid of the eye and throw reflected light upon the globe.

It is to be remembered that this test depends entirely upon the physical laws governing the application of heat or cold. The stream of fluid must be applied without force, and the height of the irrigator be such as to eliminate any suspicion of mechanical disturbance of intra-labyrinthine pressure.

The cold-water test is intensely disagreeable to the patient who has a functionating vestibular apparatus and should be discontinued upon the first sensation of dizziness.

As a general rule, water warmer than the body temperature will excite hot-water nystagmus and *vice versâ*. It is therefore essential to know the body temperature at the time of making the tests. The temperature of the patient may be considerably over normal, and, should no provision be made for this, we may obtain the cold-water reaction when we are attempting to elicit the hot-water nystagmus.

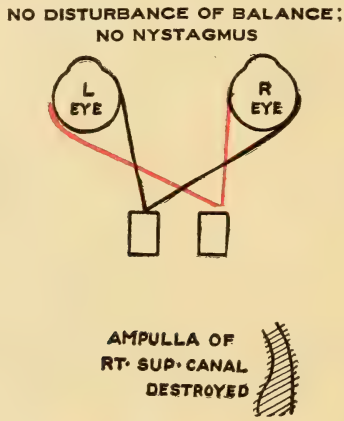

Fig. 235.

It is also worthy of note that the local temperature of the endolymph may be above the body temperature in inflammatory conditions about the labyrinth, and due allowance must be made for this.

Cold reactions can be obtained in normal cases with the water at a temperature of about 68° F. In inflammatory conditions, spoken of above, they may be elicited with water at a temperature of 86° F.

It may become of the utmost import in the course of a radical operation to determine whether or not the vestibular apparatus is functionating. The caloric tests can be applied, but on account of the anesthesia there will be no cortical corrections. So that, instead of the usual nystagmus, we will only obtain a slow vestibular movement of the eyes, in the direction determined by the position of the head and ear involved. The eyes will remain in this position until the cilia resume their normal direction.

The results of making caloric tests in all the examples which have been given have had reference to cases in which the vestibular apparatus has been functionating. Where the vestibular apparatus is not functionating, the result must be negative, as will readily be understood

from the following diagram, in which hot-water irrigation is made in the right ear, presupposing destruction of the right labyrinth, head erect (Fig. 235).

After irrigation, the vestibular nerve being destroyed, neither stimulation nor inhibition will affect the right centre. There will be *no disturbance of balance* of the centres, and no nystagmus.

Fistula Test.—As its name implies, this test is only to be elicited in those cases in which there is a pathological opening in the outer wall of the labyrinth. When the reaction is obtained, it will be evidence not only of the presence of a fistula, but also of a functionating vestibular apparatus, and for that reason may very well be the first test used in chronic discharging cases with vestibular symptoms. As with the caloric reactions, this test may fail because of the presence of granulation or cholesteatomatous masses.

The test is also known from the method of application as the compression and aspiration test.

The results here, as in the rotation and caloric tests, are obtained by movements of the endolymph, and Hoegye's law and the other laws with reference to the positions of stimulation and inhibition also apply.

Experience has shown that fistulæ occur most commonly in the external horizontal canal because of its position on the floor of the aditus and exposure to carious processes. The next most common site of fistula is in the neighborhood of the oval window, after which the promontory is most likely to be involved.

It would seem at first glance, when a fistula is present and the reaction can be obtained, that it would be a simple matter to determine from the ocular movement the exact position of the carious opening. But, when we consider that endolymph may be moved into all the ampullæ when the breach in the outer labyrinthine wall is near the oval window, it will immediately be apparent that the question may become very complicated. Accordingly, in the light of our present knowledge, it is sufficient to say that, when compression brings about a certain movement of the eyeballs and when aspiration causes a movement in the opposite direction, we can make the diagnosis of a fistulous opening in the outer wall of the labyrinth. Should this opening, on operation, not be found in the horizontal canal, it should be sought for either about the oval window or on the promontory.

Failure to obtain the reaction on compression and aspiration will not positively exclude the presence of a fistula.

Method of Making the Test.—A Politzer bag is used with a piece of rubber tubing and an appropriate olive tip to fit snugly into the external meatus. To make compression the olive tip is placed correctly in the ear and the bulb squeezed. To make aspiration the bag is first emptied of air, the olive tip fitted into the meatus and the bag allowed to expand.

Fallacies.—It has already been mentioned that the reaction may not be obtained even in the presence of a fistula when the opening is blocked by granulations or a cholesteatoma. In certain subjects the entrance of cold air into the meatus may give rise to the symptoms of a cold-water reaction. This will not be difficult of differential diagnosis, as will be shown later, but should be borne in mind.

When the Eustachian tube is wide open there may be such a rapid escape of air by this means that sufficient condensation is not allowed to produce the reaction. In adults the condition of the tube can be determined beforehand by the use of the catheter, and the employment of Valsalva's method at the time of practising compression should eliminate this source of error.

Results of Compression and Aspiration.—When a fistula is present and accessible, and compression is made, a true nystagmus does not result. There is instead a slow conjugate deviation of both eyes in a direction depending upon the canal involved and the direction of the endolymph movement in that particular canal. The eyes will slowly resume the normal position. Upon aspiration there will be a slow conjugate deviation of the eyes in the opposite direction. Remembering what has been said above with regard to the limitations of the

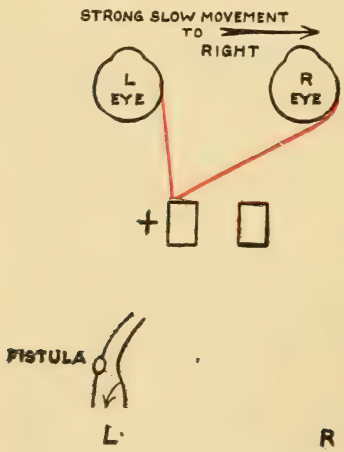

Fig. 236.

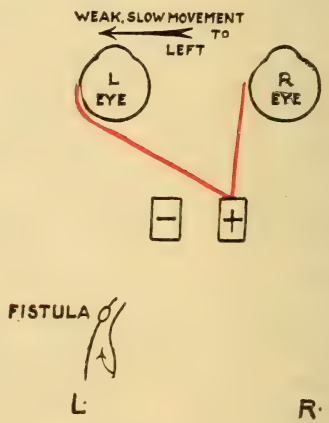

Fig. 237.

conclusions that can be drawn from the results of these tests, the following diagram shows the theoretical effect of compression when a fistula is present in the left horizontal canal (Fig. 236) :—

On compression the cilia will be directed toward the utricle, which in the horizontal canal is the direction of stimulation. The left centre is therefore the more active and there results a strong slow movement of both eyes to the right.

The following diagram shows the result of aspiration of the same canal (Fig. 237) :—

After aspiration the cilia will be directed toward the non-ampullated end, which in the horizontal canal is the direction of inhibition. The left centre being inhibited, the right overbalances and becomes weakly positive. The result is therefore a weak, slow movement to the left.

When the fistula is in the superior canal, the results of compression and aspiration can be reasoned out as above. As mentioned

before, the effect of compression and aspiration, when the fistula is in the neighborhood of the oval window, is more complicated, and the eye movements will depend upon whether the superior or horizontal canal is affected.

Galvanic Tests.—In the rotation, caloric and fistula tests nystagmus results from stimulation or inhibition of one of the centres by change of position of the ampullary cilia. In the galvanic tests no such change of direction of cilia follows, but nystagmus results from altered electrical tension of one or other of the centres by conduction along the vestibular nerve. If one electrode be held in the hand and the other applied in front of the tragus, nystagmus and vertigo will be produced.

Living tissue, muscle, nerve centre, etc., is in a state of catelectrotonus. In making the tests the ordinary wall cabinet with milliampère-

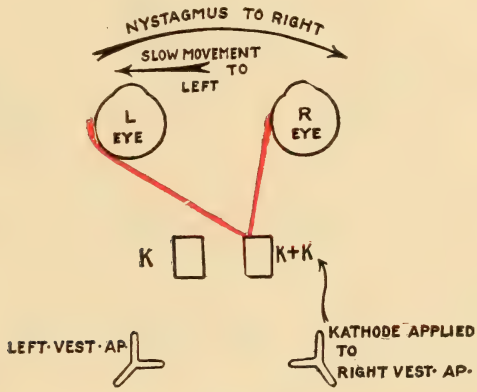

Fig. 238.

meter and pole switch is employed. One electrode is held in the hand and the other is applied in front of the tragus. The sponges, the hand and the area in front of the ear must be thoroughly moistened with normal salt solution.

The examiner as in the other tests must throw the light from his head-mirror on the eye, must raise the upper lid and be on the watch for the first appearance of the nystagmus. The current is turned on and gradually increased until nystagmus appears. The reading of the meter is noted as well as the direction of the nystagmus. The poles are then reversed and the same procedure followed. The other ear is then investigated in exactly the same way. Whichever pole is applied in front of the tragus, the nystagmus will always be to the cathode. Remembering that the centres are in a state of catelectrotonus, this is diagrammatically represented for both poles in Fig. 238.

Before the current is turned on, both centres are equally balanced in a state of catelectrotonus. The cathode is now applied to the right ear. There results a disturbance of balance in favor of the right centre. Applying Hoegye's law, there follows a series of slow move-

ments to the left, with cortical corrections to the right, or rotatory nystagmus to the right, or nystagmus to the cathode. Application of the anode to the right ear is shown in Fig. 239.

On the application of the anode to the right ear the catelectrotonus of the right centre is diminished and a disturbance of balance between the centres results, in favor, however, of the left. The slow movement is therefore to the right and the nystagmus to the left. The anode having been applied to the right ear, the nystagmus is away from the anode—that is, it is as before, to the cathode.

In normal cases nystagmus will be brought about on the application of the cathode by an equal amount of current on each side, and on the application of the anode by an equal amount on each side.

Six milliampères is the average amount necessary to produce

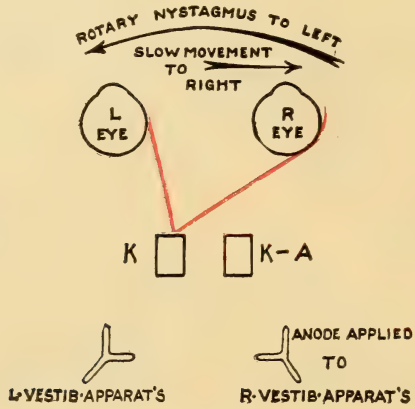

Fig. 239.

nystagmus when the cathode is applied, and 8 or 9 milliampères the average amount when the anode is applied. The cathodal and anodal amounts on one side should exactly balance the cathodal and anodal amounts on the other.

In the early period of a labyrinthine suppuration, galvanic reactions may be obtained even when the rotation and caloric reactions are negative. Later, however, degeneration of the vestibular nerve follows destruction of its end organ, and when this has occurred the galvanic reactions will not be elicited. If a vestibular apparatus be destroyed the centre on that side either is weakly catelectrotonic or anelectrotonic. With one labyrinth destroyed the average milliampèrage necessary to produce nystagmus is for the cathode 10 and for the anode 4. With one labyrinth hyperesthetic the average milliampèrage is for the cathode 1 and for the anode 11 or 12.

The electrode which is applied in front of the tragus should be fitted with a "make and break" mechanism.

The following tables, devised by Dr. George W. Mackenzie, show the comparison of the cathodal and anodal opening and closing nystagmus:—

1. Normal nerve:—

K C N > K O N
A O N > A C N

2. Vestibular apparatus destroyed:—

K O N > K C N
A C N > A O N

SECTION II.

General Remarks.—The labyrinthine capsule is composed of dense, hard ivory bone, part of which—the outer (lateral) wall—forms the mesial wall of the tympanic cavity. The labyrinth is the

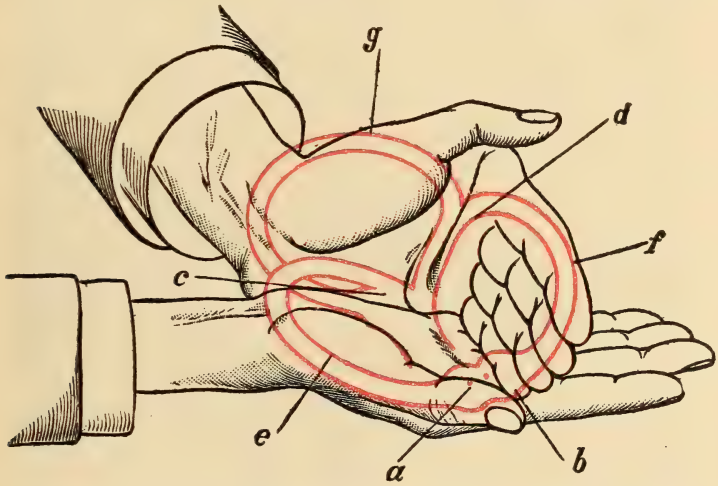

Fig. 240.—Mnemonic diagram of the canalicular system of the right side. *a,* The ampulla of the horizontal semicircular canal. *b,* The ampulla of the anterior vertical (superior) canal. *c,* The ampulla of the posterior vertical (posterior) canal. *d,* The confluence of the two vertical canals. *e,* The convexity of the horizontal canal. *f,* The convexity of the anterior vertical canal. *g,* The convexity of the posterior vertical canal. (From Bárány's "Physiologie und Pathologie des Bogengang-Apparates Beim Menschen," with permission.)

wonderful organ of equilibrium and also of sound perception. The hardness of the capsule and its anatomical structures seem to be so arranged by nature that they form an unusually strong barrier against invasion by purulent processes. It is estimated by Bezold that the labyrinth becomes involved in the necrotic process only once in 500 cases of chronic purulent otitis media. Friedrich and Hinsberg, on the other hand, estimate its occurrence once in 100 cases. Many cases occur during the first ten years of life and pass unrecognized (Lafayette Page).

The most vulnerable points in the labyrinthine wall are the horizontal semicircular canal, the fenestra ovalis, the fenestra

rotunda, the promontory, and from the cranial side the internal auditory meatus.

The mnemonic diagram of the canalicular system of the right side devised by Bárány (Fig. 240) is a valuable aid to the proper understanding of the relation of these important structures. The

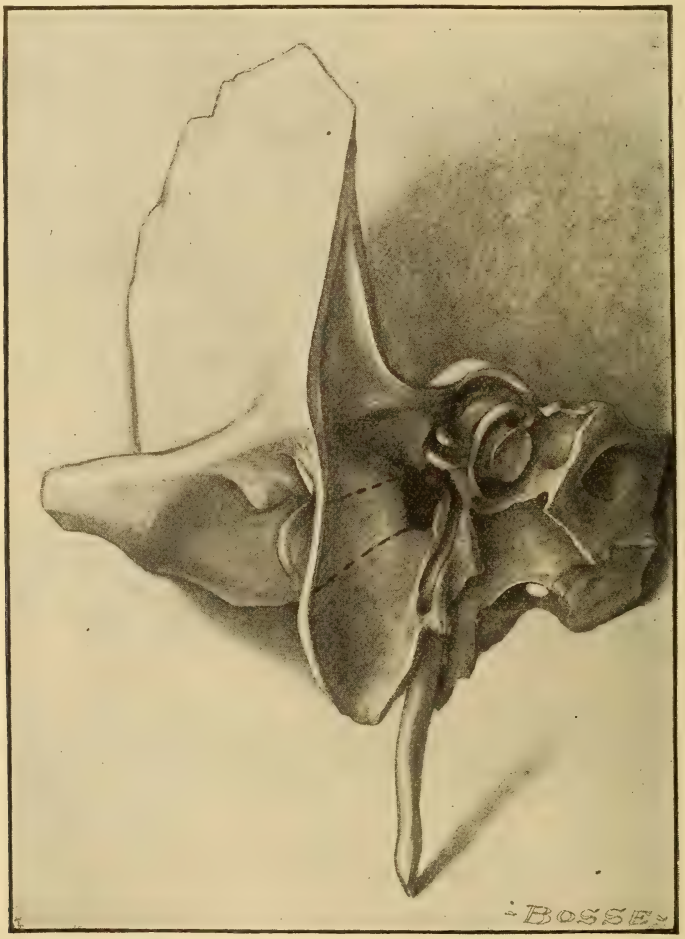

Fig. 241.—Dissection of the temporal bone, with key plate, in which the mastoid and zygomatic cells have been entirely excavated, the Fallopian canal opened, the semicircular canals uncapped, and a portion of the petrous portion cut away, depicting the relation of the canalicular system to the facial nerve, the mastoid antrum, the internal auditory meatus and the carotid canal. (From Dr. William M. Dunning's collection of temporal bones.)

relation of the semicircular canals to the facial nerve, the mastoid antrum, the carotid canal and the internal auditory meatus is shown in the accompanying dissection of the temporal bone (Fig. 241).

The relation of the semicircular canals to the middle cranial fossa, to the sigmoid sinus, to the facial nerve, and to the oval window is depicted in the dissection shown in Fig. 242.

MECHANICS AND MODE OF INVASION, WITH RELATIVE PATHOLOGIC NOTES.

The labyrinth may be invaded by a purulent process from three sources: (*a*) from the tympanic cavity; (*b*) from the blood-currents within the labyrinth; (*c*) from the meninges.

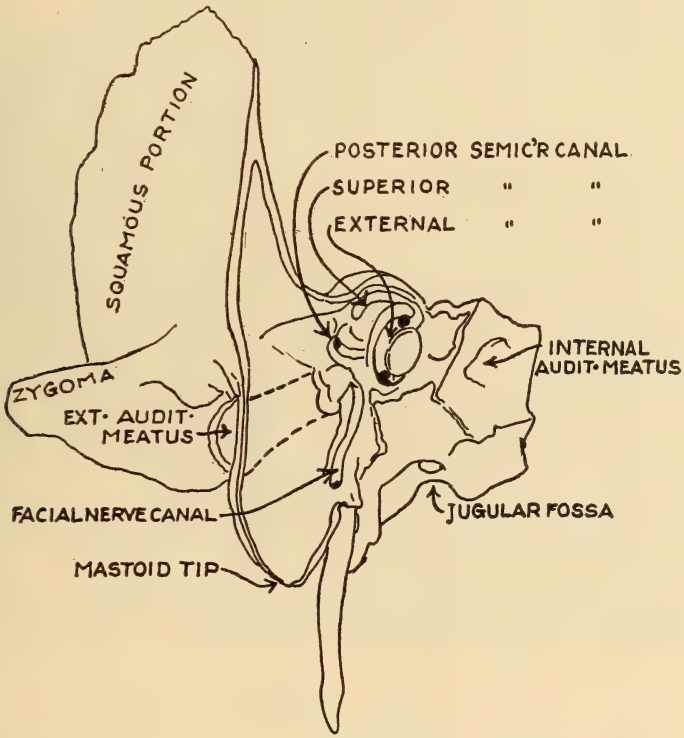

Key plate for Fig. 241.

(*a*) **Invasion from the Tympanic Cavity.**—When the middle-ear spaces are the seat of a purulent lesion, it is possible that the labyrinth may become involved through what Boenninghaus calls a "collateral hyperemia." The majority of all cases, however, do not originate in this manner, the most common origin being that found in cases where a chronic middle-ear suppuration advances and during its progress attacks the labyrinthine wall and finally invades the delicate structures within the labyrinthine capsule. This type of labyrinthitis is observed with greater frequency among those cases of chronic purulent otitis media in which cholesteatoma

is the dominant factor in the middle-ear lesion. Tuberculous and postscarlatinal chronic purulent otitis media also produce many cases of this type of purulent labyrinthitis.

Finally, when the chronic otorrhea is the clinical manifestation of chronic suppuration of the mucous membrane only, the labyrinth is rarely invaded.

Fig. 242.—Deep dissection of the temporal bone, with key plate. The Fallopian canals have been uncapped, depicting the relation of the latter to the middle cranial fossa, the sigmoid sinus, the facial nerve, the jugular bulb and the oval window. (Author's collection.)

(*b*) **Invasion from the Blood-vessels.**—The intimate vascular connection between the lateral sinus and the petrosal sinuses and the labyrinthine vessels renders very possible infection of the labyrinth along these venous channels by metastasis and without the production of fistulous openings in the labyrinthine capsule.[1] However, such an invasion through the blood-stream is rare and when it does occur usually it is found among those affected by

[1] Page, Transactions of the American Laryngological, Rhinological and Otological Society, 1909.

syphilis. Among the cases occurring in persons in the secondary stage of syphilis the symptoms show a distinct nerve deafness, which may or may not be accompanied by vertigo. Boenninghaus deems it doubtful whether or not this type of labyrinthitis is a true labyrinthitis or simply a neuritis of the auditory and vestibular nerves. On the other hand, in the tertiary stages of syphilis Downie found the labyrinth filled in with bone deposits, and

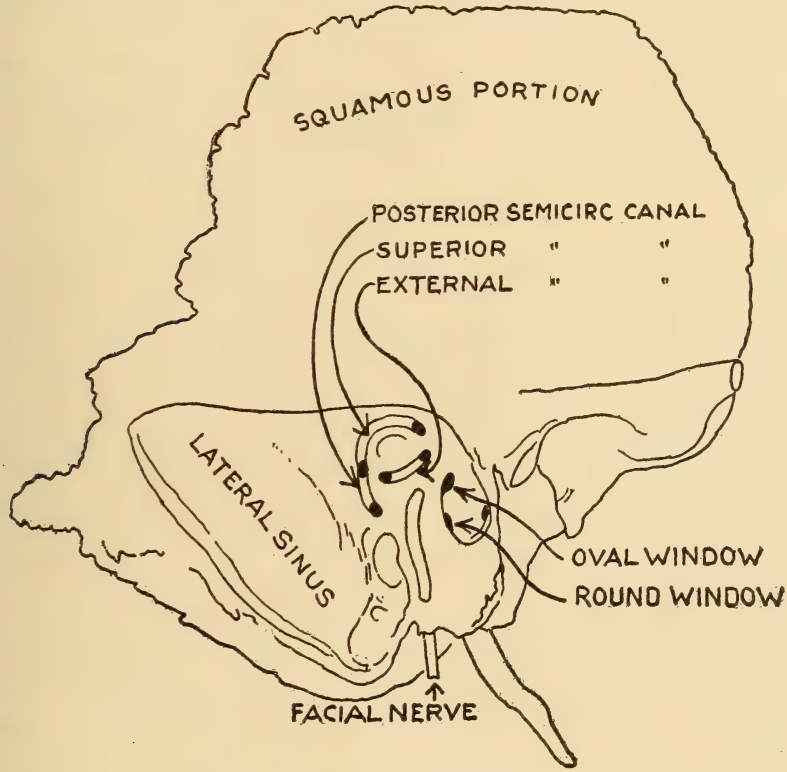

Key plate for Fig. 242.

Manasse observed new connective-tissue formation within the perilymphatic spaces in addition to a neuritis of the acoustic nerve.

The cases of labyrinthitis which accompany hereditary syphilis usually are non-purulent; both ears are involved, and the patients exhibit Hutchinson teeth, and also significant scars and ulcers within the nares and the mouth, and additionally show characteristic signs upon the skin. In doubtful cases the Wassermann or the Noguchi blood test (see page 435) furnishes additional data.

(*s*) **Invasion from the Meninges.**—This type of labyrinthine invasion, if it occurs in early childhood, may result in deafmutism. Deafmutes of this type have suffered from an acute infection of the meninges, either in the form of meningitis purulenta or epidemic

cerebrospinal meningitis, from which they have emerged with more or less impairment of the labyrinthine function.

According to the observation of Habermann, the infection invades the aquæductus cochleæ and progressively involves the lymph channels and the acoustic nerve, thereby producing primary infection of the endolymph spaces, or primarily involving the perilymphatic spaces.

The loss of labyrinthine function is immediate, but, because for the most part the victims are children, the destructive lesion in the labyrinth is not immediately recognized.

The cases, however, which mostly interest us here are those in which the purulent process progresses from the middle-ear spaces into the labyrinth. Deafmutism and the non-purulent diseases of the labyrinth are elsewhere discussed (Chapter XXVIII).

GENERAL PATHOLOGY.

Purulent labyrinthitis presents, pathologically, a destruction of part of the labyrinthine capsule, and a total or partial destruction—according to the stage at which the lesion is examined—of the structures of the membranous labyrinth. The principal lesion may be located at one or at both of the labyrinthine windows, from whose recesses pus exudes. Where the oval window is the seat of the lesion the annular ligament and footplate of the stapes may be entirely destroyed; or there may be a defect through which pus exudes and around which granulation tissue may be massed. These structures may all be destroyed and an opening left, through which purulent secretions pass freely from the middle ear into the vestibule of the labyrinth. There is every reason to suspect, logically—although from its more hidden position it is less likely to exhibit evidence of its existence—that the round window commonly plays a part as the entrance seat of the invasion.

The continuity of the labyrinthine capsule is often broken at the most prominent portion of the horizontal semicircular canal. These lesions are of varying sizes, from small perforations to large defects.

The promontory rarely presents a fistulous opening, according to Friedrich (1909). Where such a fistula is found granulation tissue usually surrounds the opening, and through the masses of granulations the pus oozes into the tympanum.

Among the cases wherein the labyrinth becomes invaded from the cranial side, we find, pathologically, that there is a marked enlargement of the labyrinthine spaces, and the fistulous openings break from within the labyrinth outward.

Again, when necrosis is the predominating lesion in the disease of the tympanic cavity, the labyrinth is often found to be destroyed, to a greater or less extent. When this is the pathological finding the case is designated as one of "panotitis."

The purulent process in the labyrinth may either be diffuse or circumscribed,—in other words, it may affect the whole mem-

branous labyrinth, or involve only a part of this structure. When the latter condition is present it is not unusual to find the remainder of the labyrinth walled off from the infection. This latter finding is the rule whenever the lesion involves the horizontal semicircular canal. In the majority of cases the purulent process is barred from the cranium, through adhesive processes in the perineural and perivascular lymph spaces. In such cases the brain and meninges are cut off from intercommunication with the labyrinthine fluid, and, finally, as shown in the syphilitic cases, new connective-tissue deposits and also new bone formation may occur, which circumscribe the purulent process and act as barriers against its advance toward the cranium.

In another group of cases the process has been so acute that nature has not been permitted to establish barriers to the advance of the infection. Not only does diffuse labyrinthitis result, but the meninges and cerebellum are liable to become infected, with a resulting meningitis or cerebellar abscess.

COURSE OF THE DISEASE.

It is not to be expected that the functionating labyrinth once destroyed can ever be restored. However, the cessation of the purulent process not only is possible, but often does occur even without surgical intervention. Hinsberg holds that postscarlatinal labyrinthine suppuration tends to heal, an observation substantiated by Boenninghaus in the study of deafmutes in the Breslau Deafmute Asylum.

When cholesteatoma is the predominating factor, spontaneous healing—that is, cure without resort to surgery, is less probable.

In cases of diffuse labyrinthitis—that is, where no encapsulation takes place, and prompt relief is not obtained through surgical means, death may ensue from meningitis or brain abscess. This is frequently the rule in cases of acute labyrinthitis which are induced by acute purulent otitis media. Where encapsulation takes place (circumscribed labyrinthitis) any operative procedure on the middle ear, the necessary employment of the chisel during the technique of the radical mastoid operation where extensive eburnization is present, the injudicious use of the probe during examinations or at the operating table, all these are factors which by destroying protective barriers and breaking down adhesions may arouse into activity the encapsulated process and thus convert the circumscribed labyrinthitis into one of the diffuse type precisely as the latent and encapsulated brain abscess through similar measures is aroused into activity. Zeroni reported having collected 40 cases of labyrinthitis, in 75 per cent. of which their activity was thus aroused.

The eighth nerve (nervus acusticus), formerly considered one nerve, is now recognized as two distinct entities: (*a*) the cochlear nerve and (*b*) the vestibular nerve. The former, distributed finally to Corti's organ, is the nerve of hearing, and the latter, distributed

to the vestibule and semicircular canals, is concerned with the functions of orientation and equilibrium.

Purulent invasion of the labyrinth disturbs or destroys the functional activity of the nerve. In the early stages of the disease the symptoms are the direct result of irritation to the organs controlling equilibrium and orientation, and also disturbance of the auditory function. Later, the symptoms are due to complete destruction of the end organs of both cochlear and vestibular branches on the affected side, or to the unbalanced action of the vestibular component of the labyrinth on the opposite or unaffected side of the head. The symptoms which are evoked by interference with the vestibular apparatus and the experimental (diagnostic) tests of the labyrinthine functions are described in Section I of this chapter.

The student should here note that nystagmus, vertigo and disturbances of equilibrium are either *spontaneous* or *induced.* When they are the result of disease and are exhibited by the patient when he presents himself for examination, they are *spontaneous.* When we elicit them by the application of our rotation, caloric or other tests, they are *induced* or *experimental.*

THE CLINICAL PICTURE.

The details of the clinical picture may be grouped as: (*a*) *general symptoms,* such as fever, headache, nausea, and vomiting, and (*b*) *special symptoms,* such as tinnitus, deafness, co-ordination disturbances, facial paralysis, and the objective signs obtained, as described, by the rotation, caloric, fistula, and galvanic tests.

General Symptoms. 1. *Fever.*—There is no characteristic temperature curve in purulent labyrinthitis. Neither is there in individual cases any relation between the temperature curve and the extent of the purulent invasion of the labyrinth. At some time during the progress of the disease, providing the temperature is regularly recorded, some rise of temperature will be found. On the other hand, subnormal temperatures are recorded at varying periods. The temperature curve, therefore, is not a distinctive symptom of purulent labyrinthitis.

2. *Pain.*—Dull headache which is referred to the region of the diseased temporal bone, but not of marked severity or constancy, usually is present—at least at some time during the progress of purulent labyrinthitis. According to several observers, violent, lancinating pain is experienced by patients during the period required for sequestration of a necrosed labyrinth.

3. *Nausea and Vomiting.*—Attacks of nausea and vomiting are almost invariably observed as early symptoms of purulent labyrinthitis. According to Bezold, vertigo and nausea usually occur as symptoms of the early stage of necrosis of the labyrinth; hence, when occurring in cases of prolonged chronic suppuration of the middle ear, they may be considered as suggestive of incipient labyrinthitis.

As the disease in the labyrinth progresses and the terminal

nerve fibres in the ampullæ become destroyed, the tendency to nausea and vomiting is lessened.

Special Symptoms. 1. *Tinnitus Aurium.*—Contrary to the importance which tinnitus aurium assumes in non-purulent affections of the labyrinth, this symptom is neither always present nor constant in the purulent form. In Bezold's record of 41 cases but 3 complained of tinnitus, the absence of which has been explained by Friedrich upon the assumption that, "with the gradual development of the clinical symptoms of labyrinthitis, supplementary ear noises do appear in the beginning as 'irritation symptoms,' which later on disappear with the destruction of the nervous apparatus."

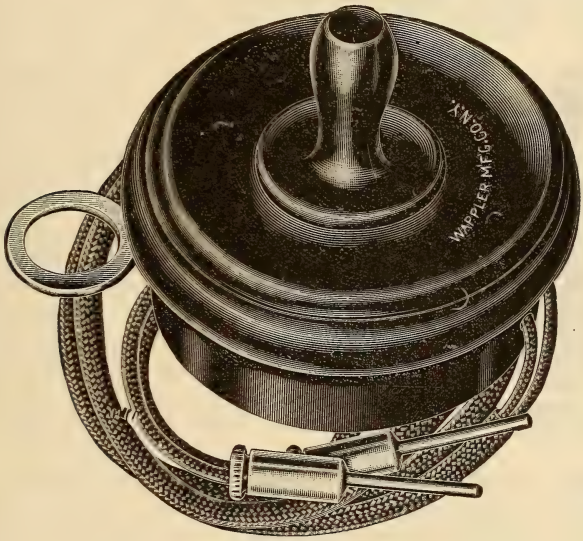

Fig. 243.—Author's noise producer. The box (which is not shown in the cut) contains an ordinary telephone appliance connected up with a dry-cell battery and faradic coil. From the receiver a section of soft-rubber tubing conducts the sound to a hollow glass ear piece. By inserting a ⟩— into the main section of the rubber tubing the sound may be conducted to both ears simultaneously.

2. *Impairment of the Hearing Function.*—Here we have a symptom which almost invariably is present whenever the labyrinth becomes the seat of purulent inflammation. In the majority of instances the hearing function in the affected ear not only is seriously impaired but completely destroyed, depending upon whether the labyrinthitis is circumscribed or diffuse. In Gerber's record of 67 tabulated cases 43 showed complete loss of the hearing function, and in the remaining 22 cases only a remnant of the hearing function survived. The tests show impairment or loss of bone conduction on the affected side, and Weber toward the opposite ear. Whenever the purulent invasion is confined to the semicircular canals the impairment of the hearing function is

partial, but deafness becomes complete when the cochlea is totally destroyed.

In determining the total loss of the hearing function in an ear which is the seat of labyrinthitis, it is necessary to eliminate the hearing function of the opposite (normal) ear by means of a noise producer (Figs. 243 and 244).

3. *Disturbances of Co-ordination.*—These are vertigo, nystagmus and ataxia. Authorities differ as to the constancy of vertigo, nystagmus and nausea when regarded as symptoms of purulent labyrinthitis. Bezold believes that they are present in the majority of all cases during some stage. Gradenigo, on the contrary, contends that these symptoms are by no means constant. He furthermore observes that, when the lesion is confined to the cochlea, nystagmus, vertigo and nausea usually are absent. In other words, the disturbances of co-ordination are present when the purulent disease is located in the semicircular canals or vestibule. Friedrich substantiates the views of Bezold and believes that, barring impairment of the hearing function, disturbances of co-ordination are the most prominent and constant of the symptoms of purulent labyrinthitis. Jansen found vertigo in 72 per cent., Lucae in 60 per cent., and Hinsberg in 86 per cent. of their cases of purulent labyrinthitis. The various diagnostic tests are fully elaborated in Section I of this chapter.

Fig. 244.—Bárány's noise producer.

4. *Facial Paralysis.*—The advent of facial paralysis in connection with a long-standing purulent otitis media is not necessarily to be considered as indicative of labyrinthine involvement. Nevertheless, occasionally it does occur in connection therewith. In 27 cases of labyrinthine suppuration reported by Friedrich facial paralysis occurred three times. It therefore possesses diagnostic significance only when associated with the more common symptoms of the affection.

Finally, the operative findings during the course of the radical mastoid operation often furnish a guide to the diagnosis of purulent disease of the labyrinth.

PROGNOSIS.

According to Hinsberg, the mortality of purulent labyrinthitis is from 15 to 20 per cent. The great majority of those who die succumb to meningitis.

The prognosis in cases of circumscribed labyrinthitis is more favorable. According to Scheibe, the mortality of labyrinthitis caused by tuberculosis also is less than that reported by Hinsberg.

TREATMENT.

The treatment of purulent labyrinthitis is mainly surgical. The nature of the surgical procedure varies with the lesion present. Many competent observers consider it unnecessary to open the labyrinth, except in markedly severe cases. These authorities content themselves with the performance of the radical mastoid operation, and from such a procedure alone they have reported excellent and satisfactory results.

Heine[2] believes the operation on the labyrinth should be limited to those cases wherein we are positive of the presence of pus. Furthermore, Heine limits his procedure to the curetment of defects in the semicircular canals, and even Jansen saw but one death in 121 cases thus treated from 1889 to 1896.

Indications for Opening the Labyrinth.—The following, together with the explanatory notes, outlines the indications and contraindications for operating upon the labyrinth. The plus signs show presence of hearing and vestibular irritability, and a positive fistula test. The minus sign denotes their absence.

NEUMANN'S CHART.

	Cochlea	Vestibular Apparatus	Fistula	Spontaneous Nystagmus	Operation
I	+	+	+	+	None
				–	None
II	–	+	+	+	If necessary
				–	None
III	+	–	+	+	Operation
				–	If necessary
IV	+	–	–	+	Operation
				–	If necessary
V	–	–	+	+	Operation
				–	Operation
VI	–	–	–	+	Operation
				–	Operation
VII	–	+	–	+	None
				–	None

I. This is very evidently circumscribed, whether spontaneous nystagmus be present or absent, and the radical mastoid operation alone is indicated.

II. If no spontaneous nystagmus is present and the vestibular apparatus is functionating, the disturbing process is circumscribed and confined to the cochlea and no labyrinth operation is indicated. The occurrence of spon-

[2] Operationen am Ohr.

taneous nystagmus may be the evidence of the involvement of the vestibular apparatus and the indication for the labyrinth operation.

III. The hearing remains, the vestibular apparatus is not functionating and a fistula is present. This is evidently circumscribed and confined to the vestibular apparatus and no labyrinth operation is necessary unless evidence of extension supervenes.

IV. The hearing remains, the vestibular apparatus is not functionating, the fistula test is negative. This is also circumscribed and no labyrinth operation is indicated. If spontaneous nystagmus be present it is evidently due to overbalance of the centre on the sound side, and would not of itself determine operation. Evidence of extension: *i.e.,* complete loss of hearing would be the operation indication.

V. Hearing lost, vestibular apparatus destroyed, fistula positive. Operation indicated with or without spontaneous nystagmus.

VI. Hearing lost, vestibular apparatus not functionating, the labyrinth operation is indicated.

VII. The hearing lost, but the vestibular apparatus is functionating, and there is no fistula; hence the labyrinthine operation is not indicated.

In the absence of symptoms more serious than functional defects in the labyrinth, several considerations must be taken into account when deciding upon the necessity for the labyrinth operation. We should endeavor to differentiate between circumscribed and diffuse labyrinthitis. The mode of onset of the deafness, whether sudden or gradual, is also of importance in determining the necessity for operation. Total deafness of long duration may be the result of pressure from cholesteatoma or secondary to changes in the bony capsule, and not necessarily the result of acute infection of the cochlea. If the vestibule is irritable and spontaneous nystagmus is toward the affected side, the labyrinth operation should not be performed, but the radical mastoid operation is indicated to prevent extension of an evident perilabyrinthitis to the labyrinth itself. On the other hand, if the hearing is completely destroyed by an acute invasion, operation is imperative if the vestibule is not irritable. If the spontaneous nystagmus is toward the affected side and the hearing remains, operation may be deferred until the spontaneous nystagmus changes or loss of hearing indicates complete involvement of the labyrinth.

Operations on the Labyrinth.—The operations on the labyrinth have for their purpose similar objects—the opening of the labyrinthine channels and the establishment of drainage therefrom.

The operations of Jansen and Neumann are very similar. That of Hinsberg is slightly different in the method of approaching the operative field. Richards enters the vestibule from behind but does not remove the section of bone (Trautmann's triangle) lying between the sigmoid sinus and the labyrinth.

Briefly described, the Hinsberg operation consists of the following technical steps:—

1. The thorough performance of the modern radical mastoid operation.

2. The procedures on the labyrinth proper. They are as follows: The bone between the oval and the round windows is removed by the use of a small burr or a small hollow gouge (2 mm.). This opens the lowest turn of the cochlea. The space thus

Fig. 245.—Extensive excavation of bone preliminary to the operation upon the labyrinth. *(Richards,* with permission.)

Fig. 246.—The semicircular canals have been uncapped. A probe has been introduced into the superior canal and the tip protrudes from the oval window. *(Richards,* with permission.)

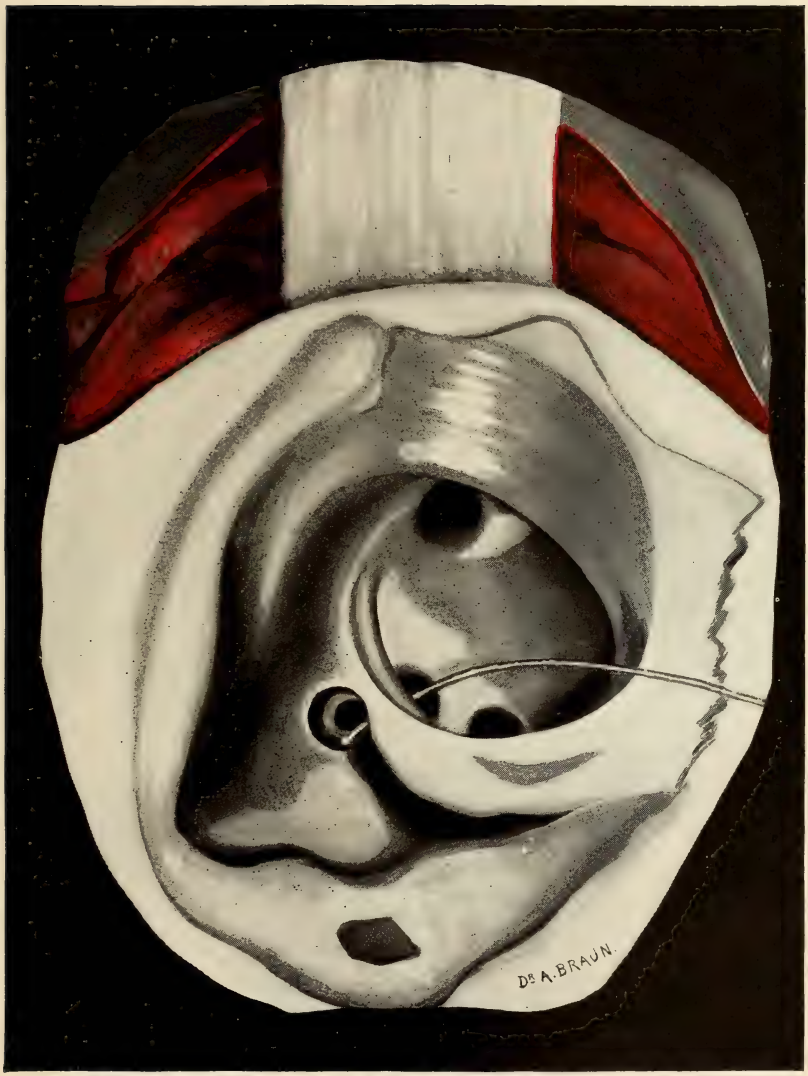

Fig. 247.—The vestibule has been opened through the solid angle of the semicircular canals and the Fallopian canals. *(Richards,* with permission.)

Fig. 248.—The anterior inferior wall of the vestibule has been removed by chiseling the section of bone which separates the oval and round windows. The roof of the first whorl of the cochlea also has been removed. *(Richards,* with permission.)

Fig. 249.—Extensive excavation of the cochlea shell.
(Richards, with permission.)

gained is widened by taking away bone until the crest containing the facial nerve is reached above. Toward the front the bone is carefully removed until the region of the carotid artery is impinged upon. Additionally, a second opening is made, entering the exposed ampullæ of the superior and horizontal semicircular canals and removing the roof of the vestibule. The canals are opened as extensively as is consistent with the structure. A bridge of bone is left between the horizontal semicircular canal and the oval window as a guard for the facial nerve, although injury to the nerve is rather common in this method of operating.

The Jansen-Neumann technique comprises measures which begin by the removal of that portion of the mastoid process which lies between the anterior margin of the sigmoid sinus and the horizontal semicircular canal (the Trautmann triangle). Working from below, the posterior semicircular canal is first attacked. The position of this canal is detected by the appearance of two small openings which diverge as more bone is removed. Proceeding upward the crus commune and horizontal canal are found and the vestibule opened under the aqueduct.

By this means of operating the semicircular canals are successively removed and the labyrinth is opened at the vestibule from behind. Furthermore, the cells which are deeply situated between the cerebellum and the semicircular canals (Trautmann's triangle) are fully exposed and removed.

In the following personal communication (translated), Neumann states his more recent views concerning the technique of the labyrinthine operation:—

"The labyrinth operations may be divided into, 1, those in which the vestibule is opened through the prominence of the horizontal semicircular canal and the promontory is opened up through the tympanic cavity, and, 2, those in which the labyrinth is opened from the posterior surface of the pyramid."

The later method practised by Neumann is accomplished as follows: *"After exposing the dura of the posterior cranial fossa* in front of the sinus, the posterior surface of the pyramid is ablated in layers, the chisel held parallel with the posterior semicircular canal, which is recognized by the two circular transverse sections of the same. Now more of the pyramid substance is ablated and so a third opening appears between the other two. This third opening is the non-ampullated end of the horizontal semicircular canal.

"By exploration with a sound one can easily be convinced that a cavity is reached through the opening and this cavity is the vestibule. With gentle taps on the chisel this opening is gradually widened until the vestibule is opened up sufficiently. By also chiseling away the bony projection situated toward the median line, we reach the dura which dips into the inner auditory canal. By ablating the promontory below the facial, the cochlea is widely opened and a bent probe entering the vestibule will appear in the tympanic cavity.

"This technique evolved itself gradually, and only recently did

I feel myself compelled to expose the dura of the posterior cranial fossa in front of the sinus in all cases, although in a great number of cases I had been successful in opening the vestibule without exposing the dura at the internal auditory meatus, according to the method described above.

"The circumstance that justifies the new operation is that it is more radical and less dangerous both for the facial nerve and the dura, even though the latter is exposed.

"The after-treatment is an open one until the retrolabyrinthine cavity is entirely filled with granulations, and now the wound may be closed by secondary sutures."

Care must be exercised in carrying out this procedure or the superior petrosal sinus may be injured, and also in breaking away the rear border of the petrosal pyramid, for when the dome of the jugular bulb lies high this structure may accidentally be injured.

The Jansen-Neumann operation is indicated more particularly

Fig. 250.—The modiolus. The base of the modiolus is excavated by the internal auditory meatus and in consequence is extremely liable to fracture as a result of injudicious chiseling about the cochlea shell.

when the symptoms furnish evidence of meningitis or deeply situated extradural or cerebellar abscess, since its technique lays bare the cranial structures which are involved in these lesions.

Boenninghaus admonishes against curetment of the opened labyrinth, inasmuch as it is conceivable that such a procedure might destroy adhesions which are acting as a barrier to the advance of the purulent invasion toward the cranium.

The technique described by Richards[3] comprises the following steps illustrated from the paper referred to:—

1. Complete the radical mastoid operation (Fig. 191). In addition to the usual procedure, the hypotympanum and lower level of the external canal floor are planed off to expose to its utmost the outer wall of the vestibule and the dome of the jugular bulb. Likewise, the orifice of the Eustachian tube must be fully exposed, and wherever possible the arches of the semicircular canals outlined (Fig. 245).

2. The prominence of the horizontal semicircular canal is now removed, using a very small narrow chisel for this purpose. The point of election is usually well above the Fallopian canal and just

[3] Transactions of the American Laryngological, Rhinological and Otological Society, 1907.

below the summit of the semicircular canal wall. A few light taps of the chisel uncap the semicircular canal.

3. The other canals are then uncapped (Fig. 246).

4. The vestibule of the labyrinth is now entered through the solid angle (Fig. 247). This opening is gradually enlarged by using a chisel held perpendicular to the line of cleavage. The bridge of bone which forms the covering of the facial nerve at this point is left untouched.

5. The vestibule open, its inner wall is searched for fistulæ.

6. The cochlea is now exposed, using a gouge whose width equals the distance between the oval and the round windows. The opening thus made is enlarged until the first turn of the cochlea is fully exposed (Fig. 248).

7. The roof of the first turn is now removed to a point just short of the carotid eminence, and further exploration of the cochlear shell follows.

8. The point selected to effect an entrance in this step is taken on an estimate as to where the apex of the cochlea is supposed to be. The bone is gradually shaved down until the interior is seen through the thinned bony covering, when, by means of a chisel stroke delivered from above downward and forward, the opening is effected. Occasionally the extent of the necrosis requires more extensive removal of the cochlear shell (Fig. 249). During the removal of the first cochlear whorl it is important that the modiolus (Fig. 250) shall not be punctured at its base.

This completes the operation. Having completed the procedure, the labyrinthine wound should be lightly packed with gauze, and the remainder of the mastoid wound packed similarly to that described under the dressing of the mastoid wound (page 247).

CHAPTER XXIV.

COMPLICATING LESIONS OF PURULENT OTITIS MEDIA.

(Continued.)

THE INTRACRANIAL COMPLICATIONS OF PURULENT OTITIS MEDIA.

PHLEBITIS AND THROMBOSIS OF THE BLOOD-VESSELS.

(Lateral Sinus-thrombosis.)

Preliminary Considerations.

In the preceding chapters relating to purulent otitis media we have traced the course of the infective process from the tympanic cavity into the pneumatic cells of the mastoid process and other portions of the temporal bone.

In addition, we have shown that the ravages of the infection within the bone, whether of the acute or chronic form, may usually be terminated by timely operative interference upon the part of the aural surgeon.

Furthermore, the surgical procedures whereby the ravages of the infection within the bone, whether in the acute or chronic form, can usually be terminated have been illustrated and defined.

There remans a small percentage of cases of aural suppuration wherein the infection penetrates the inner (visceral) cranial table and subsequently invades the lateral sinus (Fig. 255), meninges or brain (Fig. 263).

In view of the comparative thinness of the inner (cranial) table of the temporal bone, areas of which are often bathed with pus for long periods of time, one marvels that, proportionately, so few intracranial complications occur.

During recent years a distinct advance has been made in our knowledge of the etiology, diagnosis and treatment of the intracranial complications of purulent otitis media, and the investigations connected therewith have clearly demonstrated that, barring traumatism, epidemic cerebrospinal and tuberculous meningitis, the majority of all cases of intracranial infections originate in the ear. The nasal accessory sinuses also furnish a small percentage of meningeal infections. The treatment of these complications therefore very properly comes within the domain of the aural surgeon.

Erosions of the inner (visceral) table of the temporal bone may occur at any point, but they are more commonly found in the tegmen and about the knee of the sigmoid sinus.

Necrosis of the inner table, even when considerable areas of the dura are exposed to the purulent processes which invade the mastoid process, is not invariably followed by grave intracranial infection. Erosions of the inner table with exposure of the dura

are discovered with comparative frequency during the progress of mastoid operations, with no subsequent sequelæ pertaining to intracranial infections, showing that the dura in many instances seems to possess considerable resistance to the contact of infection.

The Relative Frequency of the Intracranial Complications of Otitic Origin.

The following statistics pertaining to the relative frequency of intracranial complications of otitic origin are worthy of consideration:—

Hassler compiled the intracranial complications from a total of 81,684 cases of diseases of the ear, from which number there were 116 deaths from intracranial extension, classified as follows:—

Meningitis	40
Sinus-thrombosis	48
Cerebral abscess	28

Körner compiled the results of 115 autopsies where death had been due to otitic infection of the meninges, and found

Meningitis in	31
Sinus-thrombosis in	41
Brain abscess in	43

Pitts's report covering 9000 consecutive autopsies at Guy's Hospital, London, between 1869 and 1887, shows 67 cases wherein death was due to intracranial disease of otitic origin—that is, 1 in every 158 autopsies.

Gruber investigated the findings reported upon 40,073 autopsies covering deaths from all causes. Death was due to aural suppuration in 232 cases, or 1 in every 173.

Burkner, out of 33,017 cases of aural disease of all kinds, reports 104 deaths from the effects of aural suppuration, or 1 in every 317.

Randall, out of 5000 cases of aural disease, reports 15 deaths due to aural suppuration, or 1 in 333. Dench investigated the reports of the New York Eye and Ear Infirmary for a period of eight years, during which time 64,858 cases of aural disease were treated, and found that out of this number there were 218 cases of serious intracranial (not all fatal) complications, or 1 in every 296.

The author compiled the statistics of the Manhattan Eye, Ear and Throat Hospital covering a period of seven years, during which 29,223 cases of aural disease were treated. Of this number there were 118 cases (not all fatal) of serious intracranial complications, or 1 in every 248.

The reports of the Manhattan Eye, Ear and Throat Hospital from 1895 to 1905 record 12,744 cases of purulent otitis media aside from other ear diseases, with 60 cases of intracranial complications.

Meningitis	30
Sinus-thrombosis	23
Brain abscess	7

The time of life most liable to the development of serious lesions in chronic otorrhea, according to Körner in an account of 100 cases, shows the following: 14 occurred under ten years of age: 22 between ten and twenty; 29 between twenty and thirty; 14 between thirty and forty, and 12 over forty years of age, thus showing that dangerous complications occur more frequently in the earlier stages of life, especially between twenty and thirty years of age.

Sinus-thrombosis.

Anatomy.—The cranial sinuses are venous blood-vessels running in the layers of the dura mater for the purpose of collecting and conveying the return flow of the blood from the brain. The

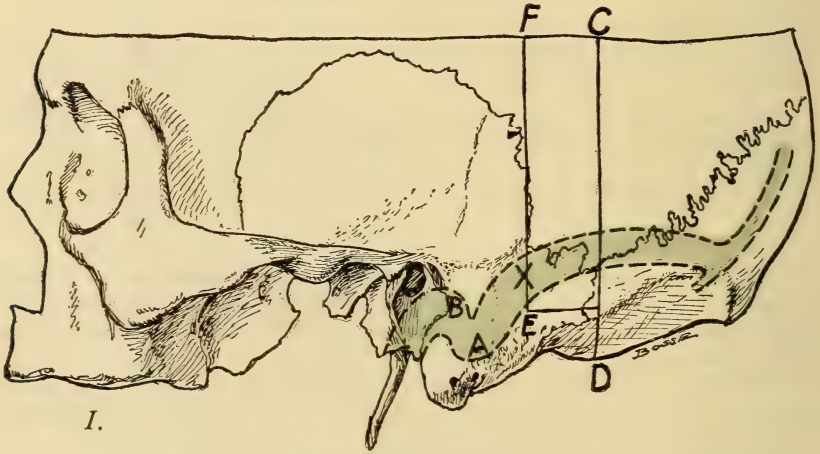

Fig. 251.—Sinus bone specimen. *X* corresponds to point where sigmoid sinus is nearest to surface. The right side of Fig. II has been cut on the level of line *C-D* in Fig. I. The left side of Fig. II has been cut on the level of line *F-E* in Fig. I. The vertical cut *C-D* was made so as to just clear the most posterior point of the temporal bone. The vertical cut *F-E* was made so as to pass throu h the thinnest portion of bone wall of the sigmoid sinus, as ascertained by means of calipers.

cranial sinuses and the cerebral veins are without valves and are not accompanied by corresponding arteries.

Among the largest of these sinuses is the sinus transversus or sinus lateralis, which on account of its course along the inner table of the temporal bone (Fig. 251) is the venous structure which most concerns the otologist.

Anatomy of the Sinus Lateralis.—The sinus lateralis, or transversus, begins at the torcular Herophili (sinus confluens) and ends at the bulb of the jugular vein. The sinus has two anatomical divisions, taking names from the direction in space which they respectively occupy. That is, it is divided into a vertical and a horizontal portion (Fig. 252), the vertical section being termed the

sigmoid portion of the lateral sinus, or, more commonly, the sigmoid sinus. The place where the horizontal segment joins that of the sigmoid presents a rather angular turn, which is often termed the "knee" of the sigmoid sinus. During its course from the torcular Herophili to the jugular bulb, where it merges into the internal jugular vein, it traverses and grooves portions of the occipital, parietal, and the mastoid portion of the temporal bone, and meanwhile receives the superior petrosal sinus, the mastoid emissary vein, and the inferior petrosal sinus, the latter entering at the jugular bulb.

The exact course of the sigmoid sinus varies in its relation to the cortex and to its approach to the suprameatal spine, and,

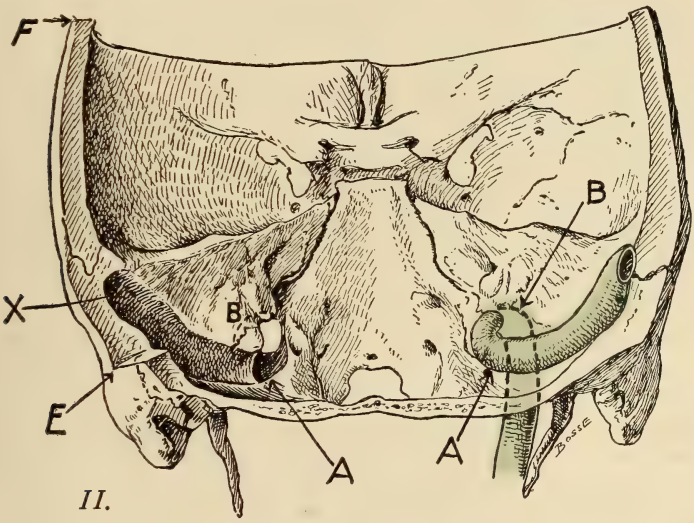

Fig. 252.—Sinus bone specimen. (See legend under Fig. 251.)

furthermore, according to Körner, the sinus extends farther forward on the right side than it does upon the left.

The average distance from the anterior surface of the knee of the sinus to the spine of Henle in 463 adult temporal bones measured by Held was 12 mm. In one of his cases the sinus impinged upon the posterior meatal wall. The author has observed one similar case during operation.

The radiograph (Fig. 253) usually shows the outline of the lateral and sigmoid portion of the sinus. Topographically the pathway followed by the transverse sinus to the knee follows a line drawn from the occipital protuberance to the spine of Henle (Fig. 2).

Etiology.—Thrombosis of the lateral sinus is induced either by means of (*a*) extension of the infective process within the temporal bone through the smaller veins, whereby the latter become involved with septic thrombi, which gradually extend to and infect the sinus, or (*b*) because the infection in the bone extends by contiguity, directly

through its internal table to the walls of the blood-vessel, where its farther advance is characterized by infection of the sinus walls, and thence into the blood-stream with resultant thrombosis.

Furthermore, according to Boenninghaus, thrombosis may occur from infection located within the labyrinth. In these cases the sinus is usually affected below the knee, or through involvement of the superior or the inferior petrosal sinuses. In another group of cases the infection proceeds from a labyrinthine infection directly toward the bulb, through involvement of the lymph spaces of the middle ear, or through the extension of a thrombus from the internal auditory vein.

From the tympanic cavity proper a thrombosis of the jugular bulb may take place from direct infection through dehiscences in the floor of the tympanum. McKernon and others have reported cases of primary jugular-bulb thrombosis. Boenninghaus, Körner and others report cases wherein the infection entered the jugular bulb from the tympanic cavity proper through involvement of the carotid plexus, along the anterior wall of the tympanic cavity.[1] We conclude, therefore, that phlebitis and thrombosis of any part of the lateral sinus and internal jugular vein take place as follows:—

1. Through anatomical dehiscences in the bone tissue which covers its parietal surface, thus affording easy access to the pathologic process.

2. Through the direct extension into its walls of the active purulent lesion in the bone.

3. Through involvement of the smaller veins in the diseased bone, or through the involvement of intermediate anastomotic veins in the thrombotic area.

Pathology.—When the walls of the sinus become the seat of an inflammatory lesion, and when the inflammation has penetrated to the inner endothelial lining of the blood-vessel, it causes a deposit of fibrin in the lumen of the sinus, as a result of the inflammation, the fibrin being derived from the blood-current.

This deposit is attached to the vessel wall at the site of the lesion. Pathologically, there results what is designated as a "white-wall thrombus" (Heine, Boenninghaus).

In the course of time this wall thrombosis grows larger and narrows the lumen of the vein until finally it becomes completely occluded. The fibrin then becomes mixed with coagulated blood, and assumes the form of a "red obstructive thrombosis," which may occlude the vessel's course for a variable distance.

The extent of the thrombus in a backward direction may involve the superior petrosal sinus, the mastoid emissary vein, the torcular Herophili, the longitudinal sinus, and even the lateral sinus of the opposite side, while in the opposite direction it may involve the inferior petrosal and cavernous sinuses, the ophthalmic vein, and after traversing the jugular bulb continue throughout the jugular vein and its tributaries.

---

[1] See Körner, Otitischen Erkrunkinger des Herins, der Hirnhaute und die Blutleiter, 1902.

Fig. 253.—The patient whose mastoid is illustrated in the above radiograph was in charge of Dr. John B. Rae at the Manhattan Eye, Ear, and Throat Hospital. This radiograph was taken by Dr. F. M. Law subsequent to the mastoid operation. The typical symptoms of sinus involvement appeared later and a diagnosis of sinus thrombosis was made. The radiograph was made just before the secondary operation, and it will be noted that it distinctly shows, in the area below the knee in which the dots appear, an entirely different shading from that of the upper posterior portions of the sinus. This upon operation proved to be the area of infection, but it was a pus invasion rather than an organized clot. So far as the author knows, this is the only radiograph in existence which shows distinct involvement of the lateral sinus. 1, external auditory canal; 2, placed in two locations, indicates the outlines of the lateral sinus; 5, the maxillary joint.

Thrombi, both of the wall type and the obstructive type, may either be of infectious or non-infectious character, the latter occurrence being more rare.

If the thrombus is not infected it becomes organized through the advent of connective tissue. On the other hand, if it becomes infected, it eventually breaks down, spreading the infection along the sinus walls, and finally destroys these walls to a variable extent.

If parts of the broken-down thrombus are carried off into the blood-stream, then septic emboli result. These may find lodgment in the lungs or other parts of the body, setting up inflammatory lesions at their points of lodgment.

Symptoms.—The symptoms of lateral sinus-thrombosis are fairly constant, and for convenience of description are divided into: 1, those due to the infection of the general system, and, 2, those manifested locally.

General Symptoms.—Of the more general symptoms of sinus-thrombosis the most important in typical cases is *fever*. Fever is almost a constant symptom of sinus-thrombosis, only occasionally is it absent. The fever is the result of the invasion of the general system, probably through the blood-streams, by bacteria. During the early stage of the attack the fever is characteristically pyemic. Usually the patient has a distinct chill, during which the temperature suddenly rises to 103° to 105°, but after a short time it recedes to normal or subnormal, only to rise again upon the advent of a subsequent chill, the fluctuations not being marked by any period of regularity (Fig. 254). As the temperature falls the patient sweats profusely. In the last stages sweating may be constant. In atypical cases the patient may complain of feeling chilly, and then the temperature rises to 103°, 104°, or as high as 106°, where it remains with slight variations only. This is the rarer type and is generally significant of secondary metastatic involvement. Vomiting of a projectile type may accompany the chills, but it is not a constant symptom, and, furthermore, it may occur in all the forms of intracranial complications of otitic origin.

The next most important symptom to that of fever is the clinical picture produced by varying metastatic lesions. According to Brüger, these take place in 42 per cent. of the cases. The most common secondary lesion is that involving the lungs. This is indicated by pain in the chest and the advent of coughing. The lung lesion is often a bronchopneumonia. A rarer lesion is abscess of the lung. Then hemorrhagic sputum of foulest odor is noted. The infarct may lodge in the pleura, causing a pleurisy, pyopneumothorax, or the joints may become involved. The periarticular structures may be involved, and finally lesions may take place in the heart, the kidneys, or the brain, each organ portraying distinctive symptoms.

Headache usually is present during some period of the disease, and is located about the mastoid, parietal and occipital regions of the affected side. Swelling of the spleen also is commonly noted,

particularly in children. The mentality of the patient may vary from being absolutely unaffected during the early stages to coma just preceding death. In general, the patients feel very sick, have no appetite, show a coated tongue, gradually lose weight and assume the appearance of typhoid-fever patients. Occasionally choke disc occurs.

Finally, the color of the skin and conjunctiva changes to a yellowish tinge, and the clinical picture of meningitis or brain abscess is intensified, which continues, unless relieved surgically, to the death of the patient.

Usually the disease runs its course in from eight to fourteen days. Cases of primary jugular-bulb thrombosis when occurring in infants and young children present atypical symptoms, inasmuch as no disease of the mastoid process is present, and, furthermore, the symptoms are similar to those which accompany pneumonia, malaria, typhoid fever, and affections of the digestive tract. In infants and young children the chief symptom of thrombosis of the jugular bulb is a sudden and rapid rise of temperature to above 104°, followed by an equally precipitous decline. Thereafter the temperature curve fluctuates after the manner of the first rise, during which time the variations in the pulse rate follow the temperature. There is no chill, the hands and feet may be cold when the temperature rises; meanwhile during the earlier remissions the child appears quite normal, playing with its mates and taking liberal nourishment.

Later on, prostration ensues and all the symptoms of sepsis become apparent, to be followed by a fatal issue unless an early diagnosis is made and prompt surgical treatment intervenes.

Local Symptoms.—Patients having sinus-thrombosis occasionally present a swelling behind the mastoid process (the Griesinger sign). This swelling or edema of the region behind the mastoid process usually is painful to the touch, especially at the mouth of the mastoid emissary vein. It seems to indicate at least a perisinus abscess, or a phlebitis of the mastoid emissary vein. This symptom is not to be considered as invariably characteristic of lateral sinus-thrombosis.

Boenninghaus has noted thickening of the vena mastoidea as indicative of sigmoid sinus-thrombosis, and, finally, the finding of a rather thick strand which is painful upon pressure, or to the touch, along the upper portion of the jugular vein, when accompanied by other symptoms of the disease, is indicative of a thrombosis in this vein.

Rarer findings of a local nature have been noted in pain along the back of the neck. This was presented in a case where the thrombosis extended to the condyloid emissary veins. Edema and swelling in the skin of the scalp have been observed in connection with thrombosis of the lateral sinus. A thrombosis which extends to and involves the cavernous sinus induces edema of the eyelids, associated with chemosis and exophthalmos. Kümmell found paralysis in the larynx and of the muscles of deglutition, without local

cause, in thrombosis of the jugular bulb. Unilateral laryngeal paralysis with retarded pulse has been noted in rare cases where the thrombus exerted pressure on the ninth, tenth, and eleventh cranial nerves in the foramen lacerum posticum (Boenninghaus).

In 1898 Voss stated that the bruit of the blood in the sinus ceases in cases of thrombosis. This local sign Körner (1899) substantiated in personal observation. The bruit is listened for with a stethoscope, and comparison is made with the sounds heard in the healthy side.

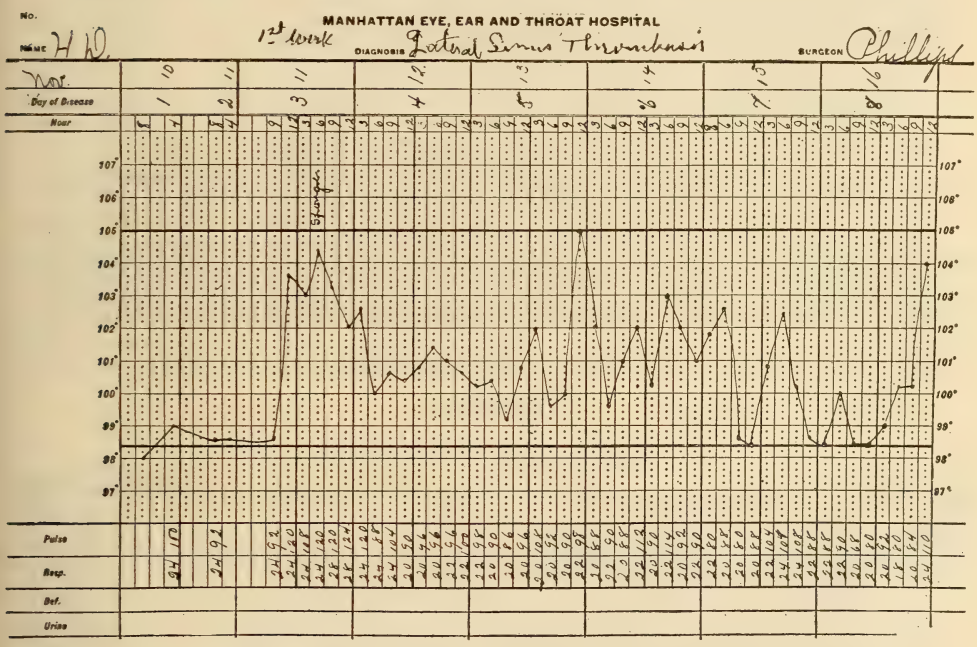

Fig. 254.—Sections from temperature chart of a case of O. M. P. C., complicated with sinus-thrombosis with symptoms of typhoid fever, viz., Widal reaction positive, and characteristic rash. A thrombus extended from the torcular to an indeterminable point below the clavicle. The patient succumbed to meningitis and septicemia five weeks after admission to the hospital. (Case fully reported in the Transactions of the American Laryngological, Rhinological and Otological Society, 1909.)

Finally, Libman, of the Mt. Sinai Hospital, New York, has published observations in which he holds that the finding of streptococcus in the blood-stream, when all other possible sources of origin of the bacteremia are eliminated, indicates a sinus-thrombosis. In all of his published cases the positive findings of streptococci in the blood, by culturing the blood (after withdrawal from a vein), were substantiated at the operation by finding the sinus thrombotic.

Diagnosis.—Boenninghaus lays down the four following propositions regarding the diagnosis of sinus-thrombosis:—

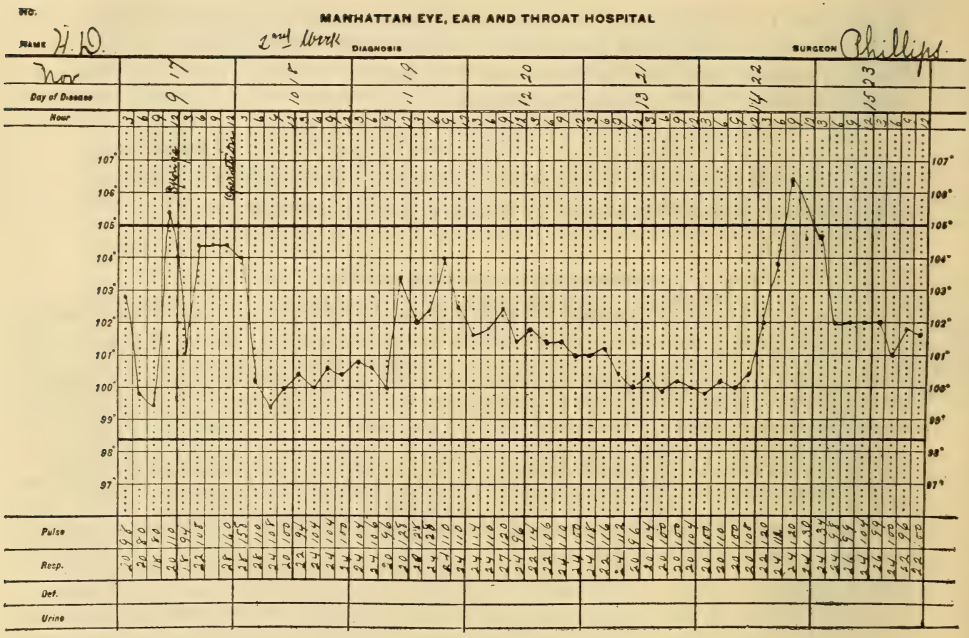

Fig. 254.—*b*.

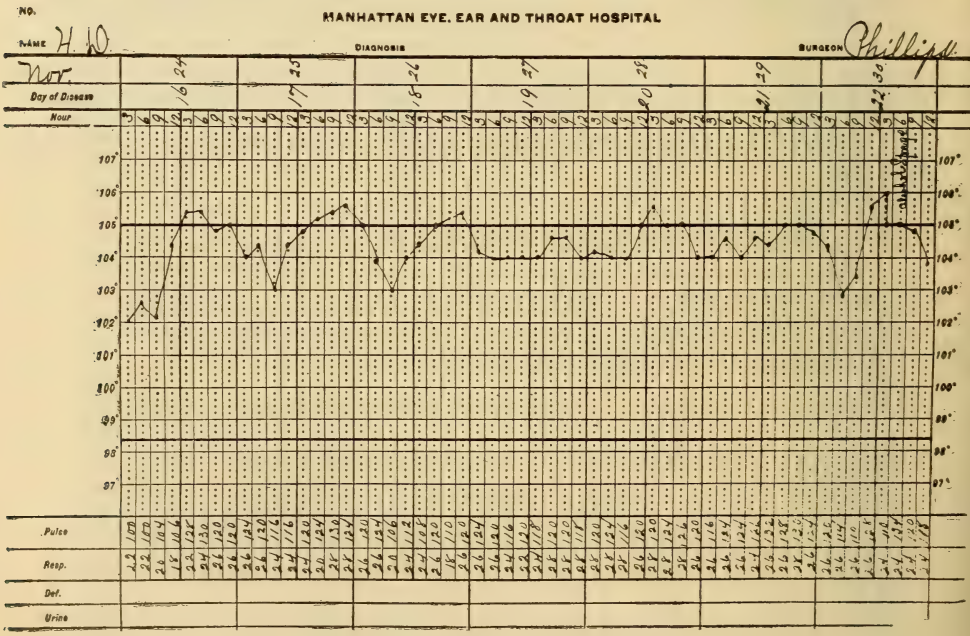

Fig. 254.—*c*.

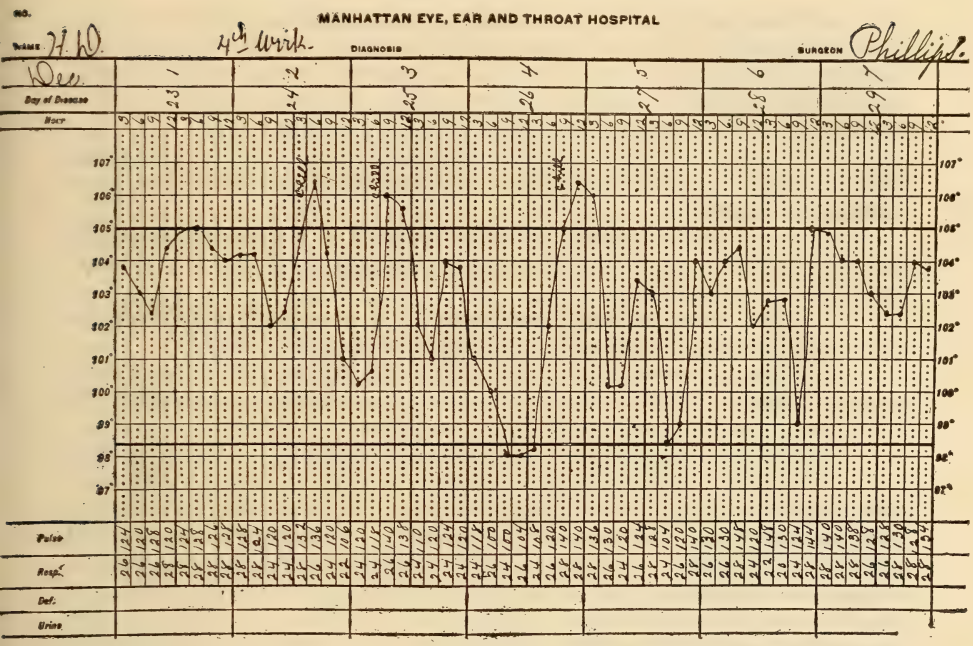

Fig. 254.—*d*.

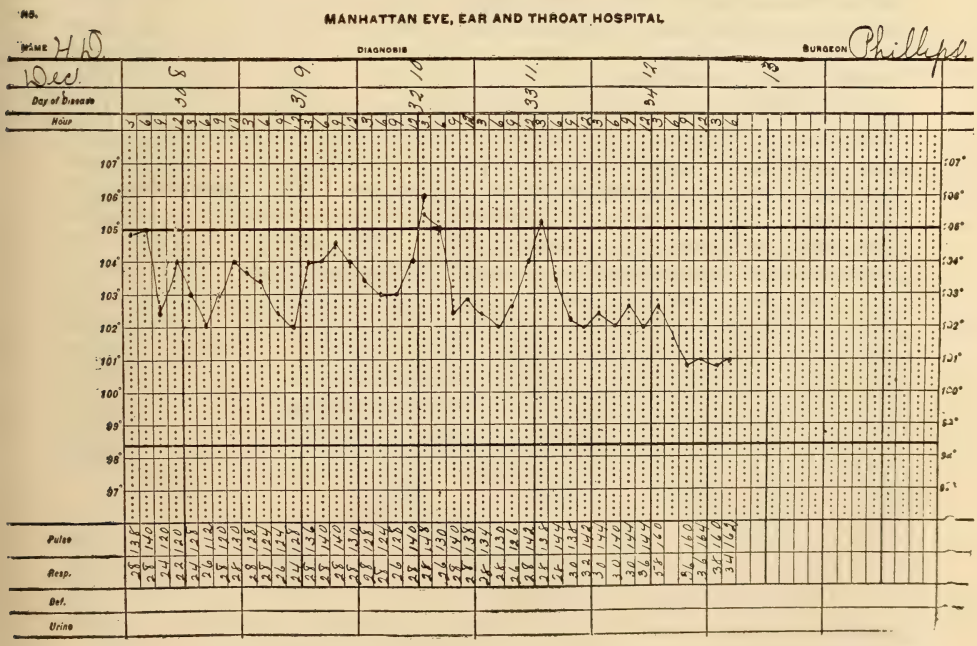

Fig. 254.—*e*.

1. *When, after an acute middle-ear and mastoid involvement, in spite of adequate drainage (surgical treatment) the fever recurs after having dropped, then we should be suspicious of sinus-thrombosis. Especially is this true if the temperature elevations persist over a number of days, and become higher as succeeding days pass.*

That fever often persists for some days after mastoid operation, and is especially prone to persist in the case of children, has been shown by Harris.[3]

2. *If the fever reappears after an interval of normal temperature, which has followed the procuring of adequate middle-ear drainage* (mastoid operation, etc.).

3. *When fever suddenly reappears after a case of middle-ear infection apparently has been cured for some interval of time.*

4. *When, in cases of chronic middle-ear suppuration having marginally situated drum perforations, there is a sudden appearance of fever, then sinus-thrombosis is to be suspected.*

Regarding Boenninghaus's diagnosis based upon the time and advent of fever, it must be borne in mind that all other sources of the fever first must be eliminated in order to make his four propositions hold true. Of especial significance is this observation when dealing with cases occurring among children and also in cases of erysipelas following the mastoid operation. Erysipelas with delayed local manifestations is occasionally observed. In one such case occurring in the author's practice, there occurred three sudden rises of temperature ranging from 105° to 105⅗° on succeeding days with chills, nausea and other symptoms of sinus thrombosis in a patient who had been operated a few days previously for acute mastoiditis. The sinus was then opened and found normal, but upon changing the wet dressing six hours later the local symptoms, redness, swelling, etc., had appeared. This case made a good recovery. In one's anxiety to operate early, the possibility of incipient erysipelas should be eliminated. Another somewhat rare postoperative condition may be defined as an extensive non-erysipelas cellulitis of the scalp. This is invariably ushered in with a sudden rise of temperature, chill and sometimes nausea. This may be mistaken for sinus thrombosis unless the wound area and scalp are examined.

In a more detailed consideration of the diagnostic points, it is found that in typical cases which present the entire category of signs and symptoms lateral sinus-thrombosis is not difficult to recognize. The characteristic temperature cure, the chills, the sweating, the vomiting, the localized pain over the sinus walls, the leucocytosis, the high polynuclear percentage, the bacteremia, together with the history of purulent otitis media and mastoiditis, furnish an unerring clinical picture of this affection. Unfortunately, in a large percentage of even the so-called typical cases, one or more of the above-named symptoms are absent, in which event it becomes more difficult to render a diagnosis. (For radiography see Fig. 253).

In atypical cases the diagnosis always is difficult and requires an exhaustive consideration of the entire chain of symptoms, mean-

[3] Annals of Otology, 1902.

while taking advantage of blood-culture, blood examinations and all known methods whereby other diseases may be eliminated. A high temperature continuing several days after a mastoid operation, especially when the operative findings have disclosed areas of necrosis of the bony covering of the lateral sinus, and examination of the blood shows bacteremia, leucocytosis and a high polynuclear percentage, is indicative at least of an infective process of sufficient severity to constitute sinus-thrombosis, and the sinus should be examined.

The diagnosis of primary jugular-bulb thrombosis must largely depend upon the sudden rise in the temperature range, and the subsequent fluctuations from normal or subnormal to 104°, 105° or 106°. Usually occurring in infants and young children, and often without intercurrent mastoid infection, the early diagnosis is most difficult and must be made only after eliminating other diseases, such as pneumonia, malaria, typhoid fever, and digestive disturbances. Blood examinations also furnish reliable data.

The operative findings, both when the sinus is exposed for purposes of diagnosis and when necrotic areas of its bony covering are discovered during the progress of the mastoid operation, are of considerable diagnostic value, as occasionally a thrombus in the sigmoid region is discovered only at the time of operation. Whenever an exposed area of the sinus is covered with healthy granulations, its interior should not be disturbed unless other signs and symptoms of thrombosis are present. When, after removing a necrotic area of the bony covering of the sinus, should the sinus wall at one or more points present necrotic or sloughing spots and much epidural pus instead of the smooth, slightly shining blue surface of a normal sinus wall, then there is a strong probability that the infection has already invaded the blood-current within. Palpation of the sinus wall is an uncertain diagnostic measure, inasmuch as pulsation still may continue after a clot of considerable size has formed. If pulsation is absent and the pressure sensation is doughy, a thrombus may be expected.

An occluding thrombus occupying the lateral or sigmoid sinus may exist without producing any symptoms referable to the internal jugular vein. The local diagnostic signs of thrombosis of the internal jugular vein—and they are by no means constant—are pain and tenderness extending along the pathway of the vein, the absence of venous bruit, swelling of the cervical glands, a cord-like sensation evoked by palpation along the thrombosed vein, the fixed position of the patient's head, which bends toward the affected side, and finally reflex phenomena from compression of regional nerve trunks.

Reverting to the diagnosis of lateral sinus-thrombosis in general, emphasis should be placed upon the importance of early diagnosis, inasmuch as the mortality in cases surgically treated is in direct proportion to the duration and extent of the disease.

Prognosis.—The prognosis of lateral sinus-thrombosis depends upon the duration and extent of the disease, and upon the stage at which further progress is checked by surgical interference. The

earlier the operation the lower the mortality. A localized thrombus of short duration, when located in the region of the sigmoid, and therefore unaccompanied by involvement of the petrosal sinuses or jugular bulb, when operated upon promptly usually results in recovery; whereas, during the later stages, after the thrombus has invaded the contributing branches, the torcular, the bulb or jugular vein, the prognosis is less favorable and the mortality is high. After metastatic abscesses have formed in the lungs, brain, spleen, bowels, etc., the mortality is extremely high.

There is considerable evidence in published reports to warrant the opinion that certain individuals possess sufficient resistance to the infection to enable them to counteract its effects without the formation of thrombi. Once formed, however, a thrombus is prone to suppurate and break down, often with a partial or total destruction of the sinus wall and subsequent purulent inflammation of the surrounding tissues. The author has, during the process of operations upon the mastoid process, found the sinus walls enormously thickened and its lumen nearly or quite obliterated, and still without any visible clot.

Treatment.—The treatment of sinus-thrombosis of otitic origin is entirely surgical, and for convenience it is herein considered under two heads: (*a*) Cases in which there have been no previous objective or subjective symptoms of sinus-thrombosis; nevertheless, at the time of an operation on the mastoid process the infection of the sinus is discovered. (*b*) Cases in which the sinus infection either is suspected previous to the operation upon the mastoid process, or it develops subsequent to the operation.

In type (*a*) if a perisinus abscess is discovered during the course of a mastoid operation, and if it has existed for a considerable time, the portions of the wall thus exposed to the infection will be covered with granulations. But if the purulent process has been of shorter duration the exposed area of the sinus appears inflamed and thickened without the usual granulations. On the other hand an accidental exposure of the sinus during a mastoid operation, when no perisinus abscess exists, occasionally reveals an appearance of the sinus walls which is almost identical with those above described. In the absence of the classical symptoms of infection or thrombosis of the sinus prior to the operation, even though a perisinus abscess is discovered, it is inadvisable to explore it either by incision or by puncture unless its walls are necrotic or gangrenous. Even if the surgeon is convinced that a clot is present if no symptoms of infective thrombosis have appeared, it is inadvisable to interfere surgically with the sinus. The author is firmly convinced that non-infective thrombi may develop in the lumen of a venous sinus, which eventually become organized into connective tissue. To operate upon cases of this type and thereby brave the danger of infecting the sterile thrombus is a questionable procedure.

In every case of perisinus abscess the entire diseased area of sinus wall should be exposed to view, but the granulations upon the surface of the sinus should not be disturbed, inasmuch as they represent the efforts of nature to limit the progress of the infection. Patients in whom the operative findings above described are present should remain

in bed. Meantime both a blood-count and blood-culture (see Chapter VII) should be made, the temperature taken every two hours, and further developments awaited. Should the usual symptoms of infective sinus-thrombosis subsequently develop, then the sinus should be explored without delay, following the technique hereinafter described.

In type (*b*), namely, those in which sinus infection or thrombosis is suspected prior to the mastoid operation, or in which a sinus-thrombosis develops at some period subsequent to such an operation, the operative technique is as follows: In case the mastoid process is still intact a preliminary mastoid operation becomes necessary. After ex-

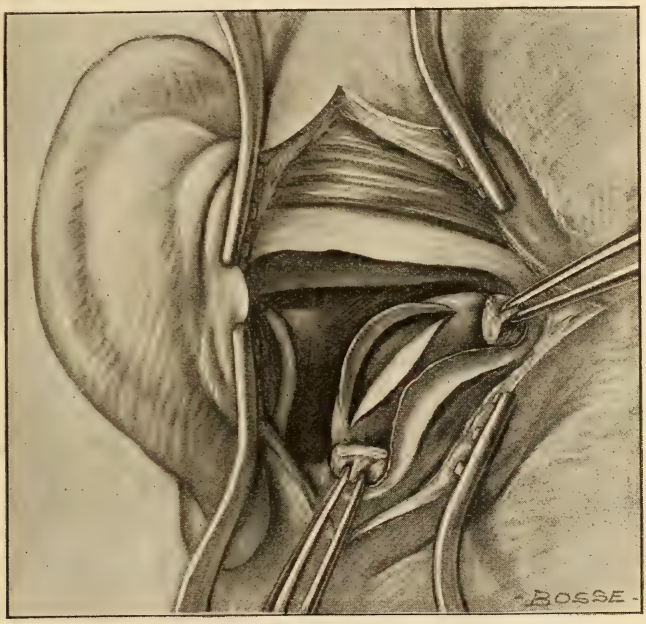

Fig. 255.—The osseous covering (inner cranial table) of the lateral sinus has been excavated from the level of the jugular bulb upward and backward toward the torcular. The gauze controlling plugs are inserted and a linear incision has been extended through the outer wall of the sinus.

cavating all diseased areas of bone the visceral (cranial) table covering the sigmoid sinus should be exposed at some point unless a perisinus abscess has already brought about such an exposure (Fig. 151). In any event it is necessary to enlarge the area of exposure by removing the osseous covering of the sinus downward to the level of the bulb and backward for a considerable distance toward the torcular (Fig. 255). In effecting this exposure great care should be exercised not to make pressure on the sinus wall or otherwise disturb its contents. Hence the removal of the necessary bony covering of the sigmoid calls for the skillful manipulation of instruments. The sharp curet and the rongeur forceps are the favorite instruments for removing this bone. After a small exposure is made, either by means of a chisel or curet, a slender-

bladed rongeur forceps (Fig. 149), one blade of which is inserted between the sinus wall and the opposing blade adjusted upon the adjacent bone is made to cut and lift the bone piece by piece until the desired exposure is obtained. During this and all subsequent manipulations upon the sinus it is well to have an assistant make pressure over the corresponding jugular vein in order to arrest any detached blood-clots which may flow from the region of the sinus above.

Having obtained the positive signs and symptoms of sinus-thrombosis, such as a septic temperature, increased leucocytosis, with a high polymorphonuclear percentage, bacteremia, nausea and vomiting, the lateral sinus should in every instance be explored, even though its walls may appear normal. In fact the external appearance of the sinus in no wise is an invariable guide to a diagnosis of infection within its lumen. The sinus wall may appear perfectly normal, palpation may not reveal anything of importance, pulsation may be present or absent, and still the lateral sinus may harbor a mural clot. In such a case, after free exposure of the sinus, the assistant should hold two plugs of iodoform gauze, one over the torcular end of the exposure and the other over the cardiac end but not in contact with it, in order to be prepared to stop hemorrhage as rapidly as possible.

The surgeon should now make a free incision in the sinus wall to the extent of about one inch (Fig. 255). If free hemorrhage results the assistant is directed to make pressure by inserting the plug into position over the torcular end of the sinus (Fig. 255). Pressure is first made on this end for the reason that if the cardiac end of the sinus contains a clot it is not so liable to be forced into the general circulation. After controlling the hemorrhage from the torcular end, should there be a free return flow from below, then a controlling plug should be introduced into the cardiac end (Fig. 255) and meantime the plug over the torcular end is removed. In case the hemorrhage from the torcular end then recurs after the removal of the pressure plug, it may be assumed that the sinus does not contain a clot, barring the possibility that a small clot may have escaped with the rush of blood from the incision. A careful examination of the interior of that portion of the sinus which is situated between the two plugs is then made. If no clot is found the outer wall of the sinus should be cut away with curved scissors and the plugs left in position. By so doing the sinus finally becomes obliterated. On the other hand, if it is found that after placing the pressure plug in position on the cardiac end of the sigmoid sinus and releasing the plug on the torcular end no hemorrhage results, it may be assumed that a clot occupies the lumen of the torcular end. This retained clot should be drawn out through the incision by means of a small ring curet. The clot usually comes out *en masse,* but occasionally it separates and is drawn out piece by piece. It is sometimes necessary to introduce the curet nearly to the torcular in order to succeed in withdrawing the entire clot. Upon the final removal of the clot from the torcular end of the lateral sinus a gush of blood ensues and a pressure plug must immediately

be introduced to control it. This completes the surgery which pertains to the treatment of the torcular end of the sinus.

Should an infective thrombus exist in the lower segment of the sinus and extend to or beyond the jugular bulb, the evidences of this either would be found in a slight return flow or no hemorrhage at all from the bulbar end, upon removing the pressure plug. In

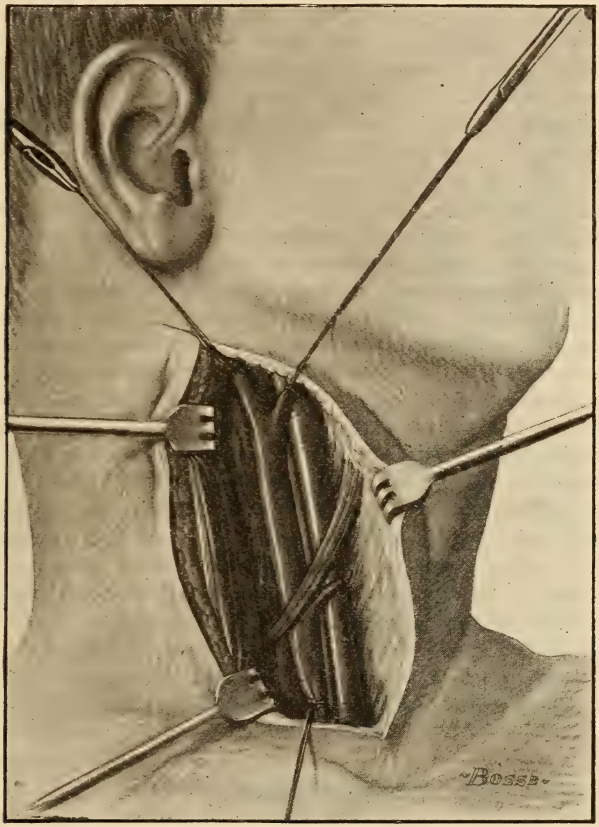

Fig. 256.—Resection of the jugular vein.

rare instances a clot may be in a state of disintegration and thus become an exception to the above rule.

The clot located in the descending portion of the sigmoid sinus and jugular bulb also is removed by the ring curet, which should be manipulated with great caution owing to the danger which follows when fragments of clots escape into the general circulation.

If the removal of the clot is followed by free return hemorrhage, it may be assumed it has not extended below the jugular bulb, and that any remnants will be washed into the mastoid wound by the flow from the inferior petrosal sinus. Free hemorrhage from the wound in the sinus at this stage is corroborative evidence

that the entire clot has been removed, and that it is unnecessary to resect the internal jugular vein or proceed farther. Hence a pressure plug should be inserted below the incision in the sinus to control hemorrhage, and, after trimming off its outer wall in the manner described in the previous paragraph, the usual mastoid dressings should be applied.

In case no return flow can be obtained after reasonable efforts to remove the clot from the region of the jugular bulb, or should the clot be undergoing disintegration, or the patient's previous symptoms indicate profound sepsis, then the internal jugular vein should be resected. The same procedure would also be indicated upon the appearance of marked tenderness and infiltration along the course of the jugular vein, with enlargement of the adjacent cervical glands, or a sensation upon palpation of a cord-like infiltration along the vein.

Technique of Jugular Resection.—In every instance in which lateral sinus-thrombosis is suspected the neck of the patient should be antiseptically prepared prior to the operation upon the mastoid process, as the saving of time is an important element in the combined mastoid and jugular resection operations. After determining that the internal jugular vein must be resected, its removal should take precedence, and manipulation of the sinus should temporarily be abandoned, inasmuch as the resection procedure acts as a dam to the escape of fragments of broken-down blood-clots from above which otherwise might enter the general circulation.

Hence the mastoid wound should be lightly packed and covered with sterile gauze and the neck exposed for operation. The skin incision should extend from one inch below the mastoid tip to the insertion of the anterior division of the sternocleidomastoid muscle to the clavicle and sternum, and along the anterior border of this muscle. The primary incision should penetrate the skin, the superficial fascia and the platysma myoides inward to the external layers of the deep fascia. During this incision the external jugular vein will be exposed, and to avoid troublesome hemorrhage it should be picked up and tied at two points about one-half inch apart and then incised between the two. The deep fascia should be picked up along the anterior border of the sternocleidomastoid muscle with two pairs of mouse-tooth forceps and incised between them, thus exposing the anterior border of this muscle. The latter incision should then be extended throughout the long axis of the wound. From now on it is much safer to use the handle of the knife and proceed by blunt dissection down to the sheath which encloses the internal jugular vein, the carotid artery and the vagus nerve. These vessels lie under the anterior border of the sternocleidomastoid muscle, and the sheath is more easily reached in the area which lies below the anterior belly of the omohyoid muscle.

After exposure of the sheath of the vessels, an opening is made and extended in both directions along the course of the vein.

The internal jugular vein and the common carotid artery now come into view, the former occupying the external position (Fig. 256).

The next step in the operation consists in isolating the vein from its surroundings. A double ligature is then passed around it, as near to the clavicle as possible, thus to guard against the dangers arising from dislodged blood-clots. The vein is then incised between the two ligatures and dissected upward beneath the omohyoid, it being unnecessary in most cases to sacrifice this muscle. The various branches of the vein should be ligated and cut at a considerable distance from their junctions with the jugular vein, as they are encountered (Fig. 256).

The insertion of these veins into the internal jugular is rather irregular, the thyroid branches sometimes entering by separate trunks, but usually by a single trunk. The lingual and facial veins usually enter by a single trunk, although this arrangement is not constant. The dissection of the vein should continue well beyond the entrance of the facial branch and as close to the mastoid tip as is convenient. Another double ligature should here be applied and the vein excised between them (Fig. 256), after which it may be lifted from the wound. Care must be exercised while passing the ligatures not to include the vagus nerve. Should the glands along the course of the vein be enlarged they should be removed. After flushing the wound with saline or bichlorid solution, the incision in the neck may be closed with sutures and a cigarette drain inserted which should extend from the upper end of the wound to its lowest portion. Sterile gauze compresses are then applied.

Returning to the mastoid wound, the temporary packing is removed.

All remaining clots are removed from the sinus, especially from the region of the jugular bulb. While it is impossible to curet the bulb without an extensive removal of bone, it usually is possible to remove a large portion of the mass and permit the flow from the inferior petrosal sinus to flush the balance. Pressure tampons are then introduced and the mastoid wound is dressed in the usual manner.

Difficulties of Jugular Resection.—Aside from the difficulties which are induced by faulty technique, the operation may be complicated by the presence of numerous enlarged and suppurating glands which adds greatly to the difficulties of the procedure; or, as the author has seen in one case, the vein may be placed in the centre of a large abscess cavity with almost total destruction of its wall. Furthermore, instead of occupying its usual prominent position it may present the appearance of a small cord-like structure and thus be difficult to identify.

After-treatment.—In cases where it is unnecessary to ligate the jugular vein, the mastoid dressings together with the pressure plugs usually remain *in situ* for from two to five days, depending upon the general condition and temperature variations exhibited by the patient. The removal of the plugs at the end of five days is not usually followed by a return of hemorrhage, and the subse-

quent dressings are conducted along lines similar to those employed for the simple mastoid operation.

The wound in the neck should be dressed on the second day after operation and the cigarette drain partially removed through the lower end of the incision. The neck wound should be dressed at least every other day and a small portion of the drain removed at each dressing until the wound is entirely free. Should the sutures in the neck become infected, it becomes necessary to remove them and thereafter treat the wound as an open one. But at each dressing the edges of the wound should be approximated as closely as possible by means of adhesive straps. Following the operation, it may be necessary, owing to loss of blood, to employ saline enemata and general stimulation. A liberal saline enema should be administered upon the completion of the operation in order to counteract the shock and loss of blood.

CHAPTER XXV.

COMPLICATING LESIONS OF PURULENT OTITIS MEDIA. (INTRACRANIAL COMPLICATIONS.)

(*Continued.*)

OTITIC DISEASES OF THE MENINGES.

Method of Invasion.

THE dura mater and other meninges are invaded by infections of otitic origin, either by the direct or the indirect route. In the first or direct variety, which is by far the most usual form of involvement, the dura becomes diseased through direct contact with the disease in the neighboring temporal bone, the latter having gradually succumbed to the infectious process, until some portion of its inner (visceral) table has become necrosed and broken down with resulting epidural abscess.

In the indirect type of invasion the most careful examination often fails to show any direct communication between the diseased bone and the affected meninges. Boenninghaus is of the opinion that the indirect method of invasion is one that takes place through the small veins which arise in the lining membrane of the pneumatic mastoid cells and which anastomose with veins about the dural portion of the lateral sinus.

Regarding the relationship between the otitis media and the meningitis in the given instance, we find that the meningitis may accompany the middle-ear disease, or it may follow after the disease in the middle-ear spaces has entirely subsided. The latter, however, is the rarer finding.

Very rarely, but still to be mentioned, is the finding of a meningeal involvement without a suppuration having been present at all in the middle ear, Leutert (1896) having seen a diplococcus meningitis follow a catarrhal involvement of the middle ear. These cases are similar to those in which a purulent mastoiditis takes place accompanied simply by a catarrhal involvement of the tympanic cavity, and when there is no actual purulent disease of the tympanic cavity present.

Pachymeningitis Externa.

Localized pachymeningitis affecting the parietal layer of the dura is the most common of all infections involving the intracranial tissues as a result of purulent otitis media. It has been observed more frequently in men than in women, and recorded histories show that the right side is more often involved than the left. As a rule the portion of dura contiguous to the antrum tegmen or attic tegmen (Fig. 260) is the site of the disease, although

the necrotic process may approach the dura from other portions of the mastoid or petrous portions of the bone, and even the cerebellar dura may become the site of the affection. It is quite possible that a small external involvement of the dura in otitic cases may remain unrecognized, such symptoms as headache, slight rise of temperature, etc., being at the time referable to the middle ear.

Pathology.—The diseased area of dura may be hyperemic only, or it may be deep red, covered with granulations or the formation of new connective tissue. The visceral surface of the dura is much less often involved than the parietal, which is the primary seat of the infectious process.

In cases of purulent otitis media with cholesteatomata which have produced absorption and exposure of the dura, we usually find the latter of a greenish color and sometimes partly destroyed. Accumulations of pus between the dura and the necrosed and broken-down bone are designated as *extradural abscess.* The communication between the extradural abscess and the diseased middle ear may be very small, or it may become entirely occluded. Pathologically, we therefore differentiate an *open extradural abscess,* that is, one freely communicating with the middle-ear spaces, and the *closed extradural abscess,* wherein the fistula is either exceedingly small or entirely obliterated between the pus accumulation in the meninges and the disease in the bone.

Situation of the Extradural Abscess. — The accumulations of pus are more commonly found over the tegmen, usually choosing the space slightly in the rear of the tegmen antri; they also occur in the region of the sigmoid sinus, where they are termed perisinus extradural abscesses. More rarely extradural abscesses form on the posterior side of the temporal pyramid, and still more rarely upon the anterior surface of this pyramid. That they sometimes do occur in this locality the published reports of Grunert (1897), Sheppard (1898), Grunert, Zeroni (1899), Much (1909), and others show. The abscesses occurring on the anterior surface of the pyramid arise from direct involvement of the veins in the pneumatic cells of the tip of the temporal pyramid in acute cases of middle-ear suppuration.

Those which develop on the posterior surface of the pyramid result from chronic suppuration of the middle ear, in which the labyrinth also is involved. The exact route travelled by the infection from the labyrinth to the dura is as yet unsettled.

Symptoms.—As already stated, in the simpler forms of pachymeningitis externa the symptoms are practically unrecognizable. As a rule the diagnosis cannot be made until after complete exposure of the dura by the removal of the portions of necrosed bone which lay directly upon it. After removing the necrotic fragments of the inner (cranial) table the evidences of the disease will be seen either as a localized inflammatory area of dura, or the exposed dural surface will be covered with granulations. The latter probably develop somewhat later, and they serve as protective barriers to the further progress of the infective process. The

symptoms of pain and fever are neither characteristic nor to be differentiated from those of the accompanying purulent otitis and mastoiditis.

The **diagnosis,** therefore, is based upon the above-described appearance of the dura as exposed during the progress of a mastoid operation.

The **prognosis** is favorable when no extension of the disease occurs.

The following remarks upon the treatment of pachymeningitis externa are entirely applicable also to extradural abscess.

Treatment.—Removal of all diseased bone from the mastoid cells and exposure of the infected area of dura constitutes the first step in the treatment of this affection. The curetment of the bone should extend over the entire diseased area of dura. When the disease is located in the region of the tegmen the cells of the zygoma must be excavated in order to uncover the dura lying over the epitympanum. Hence the chief step in the operative treatment is the removal of all diseased bone from the affected dura. Healthy granulations upon the dura should not be interfered with, inasmuch as they serve to protect the deeper structures. Subsequently, the treatment consists in carefully protecting the meningeal surface with sterile dressings. The management of the entire wound is then carried out as in the case of simple mastoiditis. At each subsequent dressing as a precautionary measure, the exposed dural surface should be covered with sterile gauze before packing the mastoid wound.

After having discovered the disease during operation it is desirable to avoid jars or concussion during the further excavation of bone. Even the concussion incident to a slight blow in chiseling tends to cause extension of the inflammation beyond the circumscribed area by breaking down the protecting granular adhesions. This observation has been made by Urbantschitsch, and but emphasizes my own opinion that in all mastoid operations the chisel never should be used except when the bone is not removable by other and less dangerous methods.

Pachymeningitis Interna.

When the inflammation spreads through the dura to its inner, visceral side, there is presented a condition designated *pachymeningitis interna.* The disease may not progress beyond the limitations of a localized infection of the subdural spaces, in which event it remains more or less circumscribed in its character; or the process may spread until the infection invades the *subarachnoidal spaces.* The diffuse purulent inflammatory process which then arises is designated as a *leptomeningitis.* It is not always possible to trace the exact course traversed by otitic infection from the middle-ear spaces to the subarachnoidal space. Many observers have found the subdural space to be free from evidence of disease, even when the infection is known to have passed from the external surface of the dura to the subarachnoidal spaces.

Finally, adhesive inflammatory processes occur in some cases between the dura and arachnoid, and in the meshes of these adhesions small abscesses may form, such abscess formations being termed *subdural abscess.* This is an observation substantiated by Heine.[1]

In a small proportion of cases of subdural abscess the brain surface forms its inner wall (Körner).

Course.—Both the pachymeningitis externa and the pachymeningitis interna may exist for a considerable period of time without producing serious symptoms or grave pathological lesions. The pus accumulation must eventually break into some neighboring structure, and quite commonly these abscesses empty themselves into the middle-ear spaces. A perisinus abscess can become evacuated by draining into the middle ear, by perforating the mastoid cortex, or by spreading along the mastoid emissary vein and thus reaching the skull surface. Boenninghaus contends that even an extradural abscess, when deeply situated on the anterior pyramidal surface, may eventually reach the surface by breaking into the pharynx through the foramen lacerum anterior, forming a *retropharyngeal* abscess. These modes of evacuation are, however, not the common course of the abscess. More frequently, after the lapse of time, the abscesses infect the contents of the cranium, producing either diffuse meningitis or brain abscess.

The **treatment** of subdural abscess is essentially surgical, the requirements being the exposure and opening of the dura for the purpose of evacuating the diseased products, and also if possible to prevent the development of purulent otitic leptomeningitis.

Otitic Leptomeningitis.

Invasion.—The invasion of the meninges by infection from the middle ear takes place either in a direct manner by contact with the localized area of diseased dura or through a sinus-thrombosis; or, the infection may reach the meninges by way of the veins or lymph channels. Regarding the latter mode of invasion it is the opinion of many observers that the infection traverses the lymph spaces which surround the nerves and arteries, and thus directly establishes communication between the middle ear and the subarachnoidal lymph spaces.

Pathology.—We classify otitic meningitis as follows, according to Boenninghaus:—

Meningitis { Meningitis serosa maligna;
Meningitis purulenta;
Meningitis serosa benigna.

Of these forms meningitis purulenta is by far the most common. In this type of meningitis accumulations of pus are to be found in the subarachnoidal lymph spaces, in the interstices of

[1] Operationen am Ohr, 1904.

the brain convolutions, in the spinal canal, and, finally, in the ventricles of the brain. It is contended that the brain substance itself is often involved in the purulent process (Ziemmssen and Hess, 1866). *Meningitis serosa benigna* and *maligna* are less well known pathologic forms of meningitis. From both the pathologic and the clinical standpoint the purulent type of meningitis seems to stand in a midway relationship to both. On the one hand, the so-called "maligna" type is the most virulent infection of the meninges with which we have to deal. According to Dietl, the course of infection is so extremely rapid that we rarely find pus accumulations in the meninges. The meninges are found to be filled with a serous fluid, the brain surface appears softened. This disease according to Billroth is significant of general sepsis, and is, *per se,* septic in nature.

The other type of serous meningitis (meningitis serosa benigna) is usually designated simply as meningitis serosa. The brain substance generally is not involved. The infected area of brain substance seems to be sharply circumscribed. When death does occur the end seems to be due to a compression of the brain by the excessive serous exudate.

An exact knowledge of the pathologic condition present in these lesions determines the surgical therapeusis indicated. From Boenninghaus's work in 1897 the following facts regarding the lesions are obtained:—

The diseased process in meningitis serosa benigna begins on the outer surface of the brain, usually at the convexity, or at the base, taking the form of a meningitis serosa externa, and spreads eventually through the lymph channels in the ventricular space to form a meningitis serosa interna seroventricularis. The ventricles become distended with exudate; the natural communications between them become closed by pressure; the brain surface becomes compressed between the fluid on the outside and that within the ventricles, and finally death results, as already mentioned, from pressure on the brain substance. Pathologically, the picture presented is that of hydrocephalus internus and edema cerebri.

Course.—Because the course, symptomatology and pathology are similar in these conditions, we will consider them together when discussing these characteristics of the various forms of otitic meningitis.

The course of otitic meningitis varies with the type of infection in the meninges. When dealing with the fulminating type severe symptoms of meningeal involvement appear at an early stage and often cause death in a few days. These cases usually die before a definite diagnosis is made clinically, and but few autopsies are recorded of this condition.

It is a mooted question whether or not a meningitis purulenta has sufficient time to proceed to the fatal outcome in this type of the disease. The more common course of the disease shows a symptom-complex which develops within the course of a week. Death usually ensues during the second week, but may be delayed until the fourth week. Heine finds this form of purulent meningitis

is the common complication to both acute and chronic middle-ear suppuration.

There is another type which runs a longer course before death supervenes. It usually complicates chronic middle-ear suppuration with labyrinthine involvement. There may be remissions in the symptoms, and Briezer states that intervals of months and years have been observed in these cases. Finally, an attack comes on which terminates in death.

The course of the disease when recovery takes place is somewhat different. Either because of operative intervention, or spontaneously, all the symptoms disappear.

Symptoms.—The classical symptoms of otitic leptomeningitis are headache, fever and loss of consciousness. Vomiting is frequently present; spinal rigidity is generally present late in the disease (Heine, Schulze).

In detail, the symptoms which may be observed during an attack of leptomeningitis are headache, disturbed mentality, aphasia, delirium, loss of consciousness, spinal rigidity, variations of pulse rate, nausea and vomiting, extreme sensitiveness to noise, and photophobia, unequal pupils with diplopia, choked disk and retracted abdomen. Leucocytosis is sometimes present; not, however, constant. The list of symptoms above enumerated are rarely, if ever, all present in any individual case. The most common of all the symptoms is headache, which comes on at the very commencement of the disease and persists during the entire course. It is of a neuralgic type and is usually diffuse. There is usually a moderate daily rise in temperature, which, during the first few days, is often difficult to differentiate from that of typhoid fever in that the curve rises in the afternoon and evening to fall several degrees during the morning hours, rarely, however, to normal. During the periods of high temperature the headache is more severe, with extreme restlessness, often rigidity of the neck, and photophobia.

Diagnosis.—The diagnosis of diffuse leptomeningitis in typical cases wherein there is a history of persistent diffuse headache, rise of temperature followed by photophobia, rigidity of the neck, delirium, and, finally, unconsciousness, is not difficult. In atypical cases it becomes necessary to resort to lumbar puncture in order to determine the nature of the disease. The symptoms of pachymeningitis interna are quite similar but less profound. Leptomeningitis, when complicating purulent labyrinthitis, presents a series of complicating symptoms referable to the labyrinthine involvement; hence, the diagnosis is more difficult to render.

In all doubtful cases lumbar puncture (see page 73) offers the best aid toward clearing up the diagnosis. Concerning the diagnostic value of lumbar puncture there are many conflicting opinions, and a voluminous literature is extant both on the findings and on the results of these findings when compared with the findings from autopsy reports. One salient feature, however, stands out from all these reports, viz., if the spinal fluid as drawn from the spinal column is cloudy and contains polynuclear leucocytes, or is found

to be clear with a tendency to coagulate, these symptoms may be interpreted as definite evidence that the patient is suffering from meningitis, because normal spinal fluid is as clear as distilled water, contains few if any leucocytes, and when the latter are present they are of the mononuclear variety, and, finally, the normal fluid does not coagulate.

The absence of bacteria in the spinal fluid does not preclude meningeal invasion; neither does lumbar puncture positively differentiate between purulent and serous meningitis. This form of meningitis is entirely separate and distinct from epidemic cerebrospinal meningitis, mention of which is made in Chapter XXXII.

The mortality from otitic leptomeningitis: formerly a recovery was a rare exception, but with the advent of a definite surgical treatment and a gradually improving technique recoveries are more common.

Prognosis.—Cases have been reported wherein the lumbar puncture gave clouded cerebrospinal fluid, containing either streptococci, pneumococci, or staphylococci, and still they have yielded to surgical treatment. In 1906 Hasslauer gathered 14 recoveries from literature; MacEwen claimed 6 recoveries out of 12 cases operated upon. Successful cases also have been reported by Körner, McKernon, Held, Kopetzky and others.

Therapy.—The treatment is surgical and consists of drainage of the meninges and repeated lumbar punctures (see Chapter VII).

Operation on the Meninges.—The steps of the operation are as follows: As a preliminary measure the mastoid cells together with all areas of bone contiguous to the middle ear should be explored and every vestige of diseased bone eradicated. Following this procedure the dura should be explored at the point decided upon as the most available for drainage. This is usually the space at and above the tegmen (Fig. 257). The incisions are then made for the purpose of establishing drainage of the accumulated and diseased cerebrospinal fluid. Furthermore, it is proper to incise the brain substances if brain abscess is suspected. Ventricular puncture is sometimes indicated late in the disease in order to relieve the ventricles of pressure and of infection.

Exposure of the Dura.—It is essential that the dura be exposed over a sufficient area to afford ample working room. Occasionally the dura is diseased at the point of entry of the infection. Again, the dissection and removal of necrosis of the tegmen antri or the tegmen tympani or tegmen cellulæ often reveal the route followed by the purulent invasion, and at the same time makes the most favorable site for incising the dura, for the purpose of relieving the intracranial pressure by drainage.

The quantity of fluid which escapes depends upon the location of the incisions and the degree of intradural pressure at the time the opening is made.

When the posterior cranial fossa is opened a large quantity of fluid usually escapes. A single incision through the dura, whether cerebral or cerebellar, of sufficient length to permit free

drainage is liable to take the form of a gaping wound, and in consequence there is considerable loss of brain substance. Therefore, we advocate a series of short parallel incisions (Fig. 257) into and through the dura. These incisions, being shorter, prevent both the loss of brain tissue and subsequent brain hernia, and at the same time afford ample drainage.

Drainage of the cerebral cavity is accomplished by two approved methods. 1. By removing the tegmen together with a segment of the squamous portion of the temporal bone of sufficient size to expose an ample surface of the dura over the temporosphenoidal lobe to permit the necessary incisions (Figs. 151 and

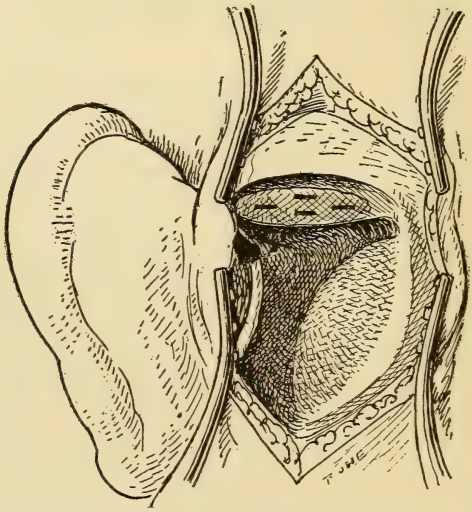

Fig. 257.—Showing the method advised for incising the dura for the purpose of drainage.

257). 2. By trephining through the lateral cranial wall about 1¼ inches above the upper margin of the osseous external auditory canal wall (Fig. 258). Opinions are divided as to the preference of these two sites.

The first-mentioned method is favored by the author, inasmuch as the exposure of the dura is quickly and easily attained by extending the mastoid bone wound upward to the level of the temporosphenoidal lobe, where the exposure is to commence, then, by removing the tegmen and a segment of the squamous portion with cutting rongeur forceps, the necessary area becomes exposed and ready for the incisions to be made. Furthermore, on account of the incisions being made in a more dependent portion of the dura, the drainage is better.

The trephine operation is made by extending the mastoid incision in an upward direction in a line perpendicular to the external auditory canal, then retracting the soft tissues so that a button of

bone may be trephined at the point above named, or the soft tissues may be incised in the form of a flap.

An oval flap is available for the purpose of approaching the meninges above the level of the linea temporalis, either for the purpose of draining the meninges or for evacuating a temporosphenoidal abscess. The method is as follows: The flap is cut out with the concha as its base (Fig. 259) (Barnhill). The incision is circular and carried down to the bone, and after separation is turned downward and forward over the pinna. The skull is then opened with a trephine of ¾ inch diameter, at a point located 1¼ inches above Reid's base line, and on a perpendicular raised from the external auditory meatus. The button of bone, thus removed, is placed in normal salt solution during the subsequent procedures in order to maintain its availability for replacement in case the wound is closed immediately.

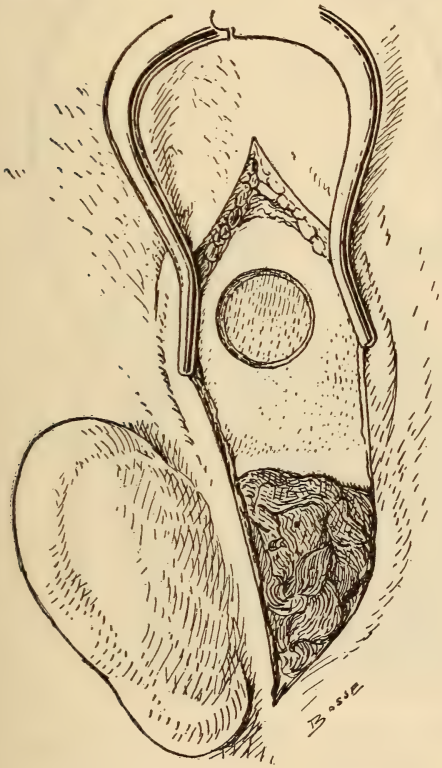

Fig. 258.—The trephine operation upon the temporosphenoidal lobe. The soft tissues are incised by extending the primary mastoid incision upward sufficiently to permit the employment of the trephine.

The dura, thus exposed, is examined and incised, and where necessary the brain itself explored. Ventricular puncture may also be performed through this opening.

Gauze drains are now placed in the dural cavity (in the brain itself if conditions present demand it), and the wound in the meninges dressed separately from the mastoid wound.

Occasionally, where a skin flap has been cut, it may be replaced and sutured immediately after the meningeal surgery is finished, thus constituting a modified decompression operation. In the majority of cases, however, those reacting promptly, it is found that the flaps can be replaced at the end of from ten to fifteen days.

When the lesion is in the cerebellar meninges and is very extensive, it is sometimes of advantage to open the skull, by means of trephine in the area posterior to the mastoid wound and the sigmoid sinus.

The bone is exposed by carrying the incision backward from the mastoid opening through the soft parts, thus exposing the desired area of bone. The periosteum is then retracted, the wound lips turned upward and downward respectively, and held apart by retractors. Then, by employing either a circular saw or a small gouge or a strong cutting rongeur forceps, a section of the occipital bone of sufficient size to expose ample surface of dura for subsequent incisions and drainage is removed.

The after-treatment of the mastoid wound is continued as if no complication had ensued.

Result of Operative Interference of the Meninges.—The successful cases recently published have established the fact that meningeal drainage will save many of these cases which otherwise would terminate fatally.

From the case reports above mentioned we can say that, in the present state of our knowledge, the purulent diseases of the meninges are amenable to surgical treatment; more especially is this true when the route of intracranial invasion is through the tegmen or the inner table of the mastoid. When the disease spreads through the labyrinth the results are not so good, unless the disease in the labyrinth is first eradicated.

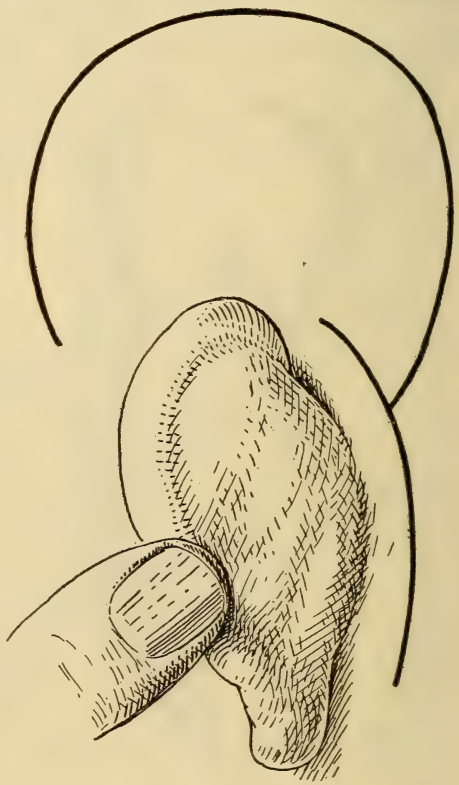

Fig. 259.—Circular flap over the squama for the purpose of trephining the skull.

Finally, it is the opinion of the author that, even in apparently hopeless cases, surgical intervention is justified on the ground that the evacuation of accumulated pus from the intradural spaces, and, eventually, from the ventricles, together with the relief of tension offered by lumbar puncture, will occasionally result in the recovery of cases which otherwise would terminate fatally.

CHAPTER XXVI.

COMPLICATING LESIONS OF PURULENT OTITIS MEDIA. (INTRACRANIAL COMPLICATIONS.)

(Continued.)

BRAIN ABSCESS OF OTITIC ORIGIN.

Etiology.—Abscesses in the brain, when of otitic origin, are the result of an invasion into the brain substance by infection which has traversed the intervening tissues from the middle-ear spaces (Fig. 260).

Fig. 260.—Section of the temporal bone in which the thinness of the inner (cranial) table and the region of the tegmen is depicted. (Author's specimen.)

The granulations which spring up from the surrounding surface of the brain finally form adhesions around the locality infected, which act as a retaining wall or partition. The collection of pus usually forms in the subarachnoidal space, from which the arteries, veins and lymphatics which enter the brain surface become the carriers of the infection.

Incidentally, these arteries and veins, by becoming thrombotic while carrying the invading organism, fail to give further blood-supply to the corresponding sections of brain tissue; hence the parts of the brain supplied by these vessels become gangrenous, according to Preysing, who designated the lesion from the pathological standpoint as being "encephalitis gangrenosa." On the other hand, destruction of the brain substance may go on much more slowly, and a condition described by Boenninghaus as "encephalitis purulenta" may ensue.

Intracranial abscesses are almost invariably the result of chronic middle-ear suppuration. The suppuration in the brain, according to Körner and others, is usually in close juxtaposition to the disease in the temporal bone.

Intracranial abscesses occur mostly between the ages of 10 and 30 years. Hunter Tod found in 100 cases of intracranial abscesses among children under 10 years of age that the temporosphenoidal abscesses occurred in 87 per cent. and the cerebellar abscess only in 13 per cent. of cases. Among adults, on the other hand, he reports that the cerebral abscess occurred in 65 per cent. and the cerebellar in 35 per cent. of cases. Cerebral and cerebellar abscesses occurring together were found only in 5 per cent. of cases.

Intracranial abscesses may be single or multiple. Multiple abscesses are rare and generally occur in cases of pyemia. The

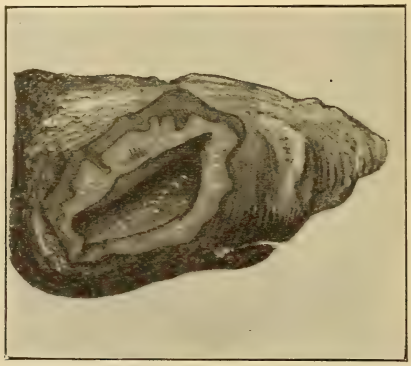

Fig. 261.—Retouched photograph of encapsulated brain abscess. Natural size. The cavity of the abscess has been laid open by removing a portion of the outer part of the wall. The size of the abscess cavity is shown and the thickness of the abscess wall. *(Harris P. Mosher,* with permission.)

abscesses may either be encapsulated (Fig. 261) or may not have any retaining wall. The walls of encapsulated abscesses are oval and regular or irregular and indefinite. The chronic type of abscess usually presents a distinct capsule with walls of varying thickness. Otitic necrosis of the temporal bone, when located in the antrum tegmen or the tympanic tegmen, tends to cause abscesses in the temporosphenoidal lobe, the most common site, while necrosis in the posterior group of mastoid cells and in the labyrinth tends to produce cerebellar abscess. The cerebellar abscess complicating labyrinthine suppuration usually is found located at or near the internal auditory meatus.

Pathology.—The majority of intracranial abscesses are of the encapsulated variety, the walls of which are primarily granulations. According to Ziegler, the granulations gradually become indurated and changed into thick, cicatricial tissue, the latter retaining a lining of granulations. The walls surrounding an encapsulated brain abscess

sometimes reach a thickness of three-eighths of an inch (Fig. 261) and the thickness of the walls bears some relation to the duration of the abscess.

The unencapsulated abscesses usually contain a thin, very foul smelling pus, mixed with broken-down brain substance. It is quite common to find both varieties in the same patient (Fig. 262), the unencapsulated abscess being the result of rupture of the wall of the neighboring encapsulated abscess, or from a re-invasion of infection from the temporal bone.

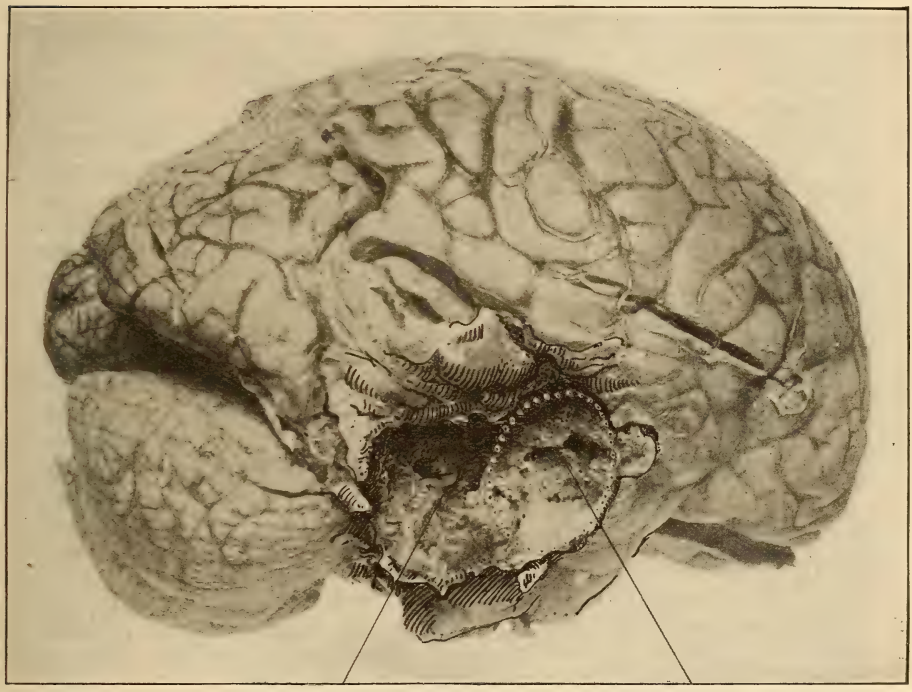

Fig. 262.—Brain showing the lesion produced by an abscess in the temporosphenoidal lobe. In this case both an encapsulated and an unencapsulated abscess were present. The encapsulated abscess lay over the roof of the middle ear; the unencapsulated abscess over the roof of the mastoid antrum. *(Harris P. Mosher,* with permission.)

The brain substance is but slightly affected in the case of the encapsulated abscess, while in the unencapsulated variety there is a destruction of brain substance of varying degree, usually to a considerable extent, and often the entire hemisphere is softened and swollen and punctured by hemorrhagic points. (Boenninghaus.)

Symptoms and Course.—The course followed by brain abscesses has been divided into four stages (MacEwen classifies the symptoms in three stages) in order to facilitate the study of the clinical signs.

(*a*) *The Initial Stage.*—This stage marks the course often followed by chronic abscesses and rarely by acute abscesses, in which the symptoms are quite definite but not sufficiently severe to arouse suspicion of the real condition. The symptoms consist of some rise of temperature, moderate or severe headache and vomiting. These symptoms are of a short period of duration and usually arouse no suspicion of meningeal infection. The symptoms of the initial stage are more severe and the disease runs a more rapid course when a sudden cessation of the otorrhea immediately antedates the appearance of the symptoms of brain abscess.

(*b*) *The Latent Stage.*—This is the period where, in a very considerable portion of brain abscesses, there are no very definite symptoms. The patient attends to his usual occupation and at most complains only of moderate headache or intracranial pressure upon prolonged exertion of body or mind. When the abscess remains intact within its capsule and with no increase in size, no other symptoms may appear for months.

One of the author's cases of this type serves to illustrate the latent period. X, male, student, about 19 years of age. A clinic patient at the New York Post-graduate Hospital. He was of athletic build, nearly 6 feet in height, and weighed 190 pounds. For several years he had had a profuse discharge of pus from his ears but complained of no other symptoms. He received the usual local treatment for a period of three months without signs of cessation of the discharge, in the meantime pursuing his studies in the High School. The pus was thick, creamy and malodorous. The granulations did not protrude through the perforations in the drumhead. At no time during the three months of tri-weekly local treatment at the clinic did he complain of headache or any other symptoms of pain or discomfort, although he did seem anxious to be relieved of the offensive discharge. He was finally advised to submit to the radical mastoid operation.

Upon admission to the hospital his temperature was normal, pulse 78, and otherwise his condition was good. The operation revealed extensive necrosis of the tegmen. Upon removing the softened tympanic tegmen, a large encapsulated temporosphenoidal abscess was discovered and evacuated. A day or two subsequent to the operation, upon questioning him in detail concerning his previous symptoms, it was ascertained that for four or five months he had complained of moderately severe headache after several hours of close application in the preparation of his lessons, aside from which no other sign of brain lesion had been experienced.

Whenever the disease progresses from any cause the headache becomes severe and more or less localized upon the diseased side. Occasionally the pain becomes intense at the site of the pus collection. In cases of cerebellar abscess the patient often complains during the early stage of frontal as well as of occipital headache.

Körner, Boenninghaus and others emphasize the significance of pain, more or less localized at the site of the abscess, upon percussion of the head. They hold this to be a sign of great importance. In progressive brain abscess the patient at this stage begins to feel ill, to

be unable to work, or to endure mental strain. He experiences periods of general depression, alternating with states of excitement. Loss of appetite and loss of weight ensue and he becomes pale and in general presents the evidence of the prodromal period of a severe illness. Attacks of nausea may appear, the tongue becomes coated, and vertigo may occur. Usually there is moderate acceleration of the pulse rate and a slight rise in temperature. Finally, to these clinical signs there are added distinct symptoms referable to the brain, upon the appearance of which the chief stage begins.

(*c*) *The Manifest Stage.*—During this stage, because of the activity and growth of the lesion, it presents positive evidences of its existence through two groups of symptoms, divided for convenience into a group of *general symptoms* and into a group of symptoms which are the result of *intracranial pressure.*

The general symptoms pertain to septic absorption. The symptoms depicted above as moderate during the latent period of the disease now become unduly severe. The signs of intracranial pressure are headache, which may be general or localized, and vomiting which occurs without relationship to the partaking of food. Other pressure symptoms are induced by the encroachment of the lesion upon neighboring areas of the brain and upon the various cranial nerves. Of the latter optic neuritis is an important sign. (Hunter Tod.) It usually affects both eyes, although more marked upon the affected side. As the intracranial pressure increases the temperature falls below normal and rarely rises above normal, the pulse becomes slow and bounding, ranging from 50 to 60 per minute, and the respirations are slow and regular.

Impairment of mentality now appears and is marked by the various forms of aphasia. There is marked impairment of appetite, constipation is the rule, and emaciation and prostration ensue.

The later symptoms of mental impairment are periods of apathy and semisomnolence, alternating with periods of intense excitability and even delirium, the latter gradually being superseded by drowsiness and a tendency to curl up in bed with the extremities flexed.

When the cerebellum is the seat of the abscess, the patient's gait is often characteristic (cerebellar ataxia). There may also be spontaneous nystagmus often directed to the side of the lesion. When the cerebellar abscess complicates a necrosed labyrinth this nystagmus, *i.e.*, directed to the side of the dead labyrinth, is extremely suggestive of cerebellar lesion.

The pressure on the cranial nerves results in both sensory and motor paralysis, depending upon the individual nerves that are encroached upon by the lesion. Oculomotor paralysis (mydriasis ptosis), facial paralysis, abducens paralysis, etc. Rigidity of the neck is a late symptom of cerebellar abscess.

(*d*) *The Terminal Stage.*—Having reached this stage, brain abscesses, unless relieved, terminate in death. Spontaneous recoveries exceptionally occur through rupture of the abscess into the middle-ear spaces. Otherwise, surgical interference is the only remaining means for saving life. In temporosphenoidal abscesses, when the terminal stage progresses, death usually occurs from increased intracranial pressure, which causes general and gradual paralysis of the cerebral func-

tions. The cerebellar abscess terminates by exerting pressure on the respiratory centres, the respirations at first becoming very irregular, often of a Cheyne-Stokes character. Again, death may occur suddenly by cessation of respiration. Very often death is hastened by the rupture of the abscess into a neighboring ventricle, or to intercurrent involvement of the meninges, the latter complication being accompanied by high temperature, rapid pulse, vomiting, spasms or convulsions.

Conclusions.—The tendency to encapsulation as a part of the history of brain abscesses, especially when the temporosphenoidal lobe is involved, probably accounts for the comparatively large number of cases which seem to go on almost indefinitely without causing serious symptoms. In all such cases there undoubtedly has been a period during which the patient has suffered from headache, with possibly vomiting and temperature variations, but not of sufficient severity to point to the actual intracranial disease. Consequently, as the abscess gradually has become encapsulated the more acute symptoms have subsided and the brain has accommodated itself to the newer condition with a period of apparent remission from the severe symptoms. Pain is the most prominent and persistent symptom of abscess of the brain.

A sudden cessation of chronic otorrhea usually proves to be an unfavorable symptom, inasmuch as it becomes an indication that the tide of the pus flow has turned into the meninges, where the infection immediately induces one of the serious forms of intracranial complications. Spontaneous recovery occasionally occurs in the temporosphenoidal abscesses which are encapsulated throughout, with the exception of a minute aperture, which communicates with the necrosed area of the tegmen, through which a continuous leakage takes place into the middle-ear spaces.

Abscesses involving the temporosphenoidal lobe—and these are by far the most common of those arising from purulent otitis media—may exist without the manifestation of local symptoms. Cerebellar abscess is sometimes associated with or the result of sigmoid sinus-thrombosis. The author has reported one such case in which the abscess in the cerebellum opened spontaneously through the inner (visceral) wall of the sinus, from which a large blood-clot had been removed a few days previously. The opening was therefore enlarged and drained without further surgical procedure.

Duration.—The duration of brain abscess varies, and depends upon the site, size and whether it becomes encapsulated. The disease generally runs its course in from two to three weeks, but it may remain latent a year or more. Generally speaking, the average duration is from one to three months.

Prognosis.—Barring the small proportion of spontaneous recoveries above described, brain abscesses terminate fatally unless relieved by surgical operation. For statistics see Results of Operation. The results upon life are more favorable when the operation is performed during the earlier stages of the disease, before the advent of meningeal infection, extensive encephalitis, or the group of symptoms which are attributable to intracranial pressure. From the literature obtainable at this time it is evident that in cases operated upon

about 50 per cent. recover. Cerebellar abscess is proportionately more fatal than is cerebral.

Treatment.—Exploration of the cranial cavity becomes a necessary procedure as soon as positive symptoms of otitic abscess are ascertained, and the indications have been formulated by McKernon as follows:—

1. That a chronic otorrhea is or has been present.
2. Persistent headaches, general or otherwise.
3. Restlessness and irritation of temper.
4. Tenderness of the affected side on percussion.
5. Nausea, vomiting, vertigo.
6. An almost persistent low temperature.
7. A slow pulse, later stupor. Optic neuritis may or may not be present, but when present it may aid materially in rendering a diagnosis, as may also aphasia and motor disturbances.

The treatment of otitic brain abscess is, therefore, essentially surgical, and for convenience of description will be defined under the general headings:—

(*a*) The operative treatment of cerebral abscess;
(*b*) The operative treatment of cerebellar abscess.

(*a*) **The Operative Treatment of Otitic Cerebral Abscess.**—The technique followed in operating on otitic brain abscesses when located in the cerebrum must of necessity vary with the seat of the pus accumulation. For the purpose of describing the operative technique, we will give the steps in the various procedures as employed when the abscess is located in the temporosphenoidal lobe, the technique being modified to meet the demands when the site of the abscess is elsewhere in the cerebrum.

The old mastoid wound is cleansed and freshened, and its deeper parts are lightly packed with sterile gauze. With light taps of the chisel an opening is made in the tegmen. When a fistulous opening already exists the beak of a rongeur forceps is introduced between the cranial table and the dura, and the osseous opening is thus gradually enlarged, especially in an outward and upward direction until a sufficient area of dura is exposed to permit ample space for exploring the neighboring brain substance. Having thus exposed the dura of the middle cranial fossa to view (Fig. 263), its color is now noted and also its tension. When the dura is discolored and bulges into the mastoid wound, an abscess in the temporosphenoidal region may be suspected. Likewise, from increased tension, pulsations of the brain and dura are absent.

With a small, narrow-bladed knife the dura is now incised and entered by plunging the knife directly through and then into the suspected area of brain substance; or, a crossed incision may be made after the manner recommended by Hunter Tod and others.

The former method is usually ample. The dural flaps are then reflected to expose the brain substance.

The brain is now explored either by inserting a very narrow bladed knife, a grooved director, or a pair of sharp-pointed thumb forceps. The individuality of the surgeon has much to do with the choice of the instrument employed for exploring the brain, but the slender, narrow-bladed knife above described possesses the distinct advantage that it produces a clean-cut wound in the brain tissue, the smooth tract of which is less liable to absorb infection, and, furthermore, subsequent healing is quicker.

The above-described method of opening cerebral abscesses is

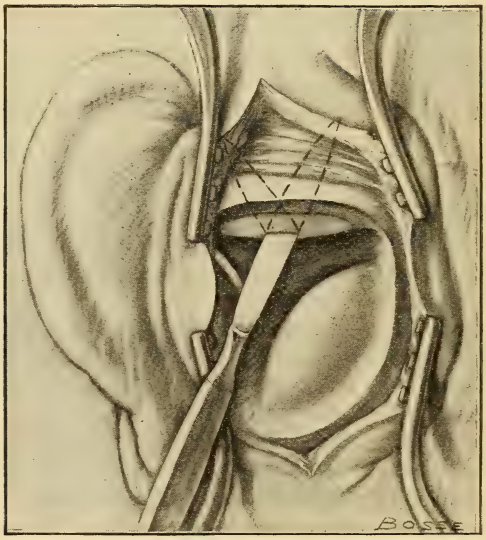

Fig. 263.—Exposure of the dura of the middle cranial fossa by the removal of the attic and antrum tegmen. The dotted lines illustrate the method of making a succession of incisions into the brain while searching for a brain abscess through a single incision through the dura.

usually efficacious. Authors differ regarding the invariable employment of this method, some contending that better results are obtained by trephining the skull in the region of the squamous portion of the temporal bone. If, on account of the large size of the abscess cavity, or if for any reason it is deemed inadvisable to attempt the drainage of the abscess cavity through the tegmen, the latter operation may be employed. The incision through the soft tissues may be effected either by extending the primary mastoid incision directly upward in a line perpendicular to the centre of the external osseous meatus or by means of a circular incision to be extended after the manner already depicted in Fig. 259.

The resulting flap is then turned downward and a button of bone trephined from the skull at a point one and one-half inches per-

pendicular to the centre of the osseous external auditory canal. Upon its removal the button of bone should be preserved in warm, sterile salt solution in case it should be deemed advisable to replace it. The search for the abscess cavity through the trephined bone should be similar to that already described when exploring the brain through the tegmen. In rare instances a counteropening through the squama as above described is considered a necessary procedure. In case the abscess cavity has already been located through the tegmen, the counteropening should be carried directly toward its known location.

Having selected the instrument it is plunged into the brain substance in an upward and forward direction (Fig. 263) for about one and one-half inches, or until it reaches the abscess cavity. The sensation of having entered a pus cavity in the brain is often felt by the operator. Since the abscess is usually situated superficially in the location above described, the knife thrust generally will reach the pus, which, in turn, begins to flow out along the shaft of the instrument. When the first puncture fails to reveal the abscess the knife is withdrawn and another attempt made, thrusting it forward, backward or more inward. When the abscess is reached the instrument introduced is kept *in situ* until the pus has drained away, or at least until it has been replaced by some more convenient guide to the cavity and, having gained access to the abscess cavity, the route through the intervening brain tissue should be carefully maintained, and the operator should not withdraw an instrument from the cavity without first having used said instrument for a guide for the one to follow, and so on until the drainage dressing is finally inserted.

The primary drainage of the abscess cavity is an important step in the operation. Should an unencapsulated abscess be encountered, it is important to remove not only the retained pus, but also to remove any necrotic areas of brain tissue. For this reason the incision should be sufficiently large to permit the operator to accomplish this object. In case a counteropening has been made through the squama it is feasible to wash the abscess cavity with a warm normal salt solution, providing a temporary drainage tube permits a sufficient outflow to circumvent the advent of intracranial pressure from the fluid.

While the prognosis in the unencapsulated variety of brain abscess is less favorable, the healing is more rapid in favorable cases than in the encapsulated variety, the advantage being due to the absence of the abscess capsule, the latter requiring healing by the granulation process.

When the abscess is surrounded by retaining walls it is rarely necessary to employ the douche for the purpose of evacuation. By spreading the lips of the wound it is usually possible to drain the abscess cavity and its contents. Any remaining pus may be wiped away by means of a cotton-tipped probe. Should it be deemed necessary to wash the cavity of its contents two tubes should be introduced into its lumen, one for the purpose of conducting the fluid into the cavity, and the other for the purpose of evacuating the fluid thus introduced. The permanent drainage of the cavity is best effected by means of the cigarette or gauze drain. In introducing the drain it is important that it be inserted to the full depth of the abscess cavity.

When the abscess cavity is of large size better drainage is secured by the introduction of a second cigarette drain. During the entire procedure the brain substance should be handled as little as possible. Care should be taken to protect the wound in the dura and other portions of the exposed intracranial tissues from infection. This is accomplished by the free use of powdered boric acid dusted over these surfaces and light packing with sterile gauze. The outer end of the cigarette drain should be buried in a mass of loose gauze packing, and the whole protected by the usual mastoid bandage.

The outer dressings are then applied.

(*b*) **Operative Technique of Cerebellar Abscess.**—Since the cerebellar abscesses may be situated either superficially or deeply, the technique is devised to meet these conditions.

The abscesses which are situated superficially, usually the result of disease in the posterior mastoid cells, generally are found to lie close to the outer surface of the lateral lobe, just beneath the tentorium.

The deeply situated abscesses, usually the result of internal-ear involvement, are mostly found to lie close to the internal auditory meatus. With the superficially lying abscesses we generally start our exploration from behind the lateral sinus, and with the deeply located abscess we begin, in front of the sinus, to explore the cerebellum.

1. *Cerebellar Exploration from Behind the Sinus.*—The bone is removed either by means of trephine or by means of the primary mastoid dissection for an area of a square inch behind the sigmoid groove, the posterior margin of the sigmoid sinus being the anterior and upper boundary of our field of exploration. The dura is incised behind the sinus, and the knife puncture is made introducing the instrument forward and inward. If the abscess is not tapped repeated attempts are made in different directions.

2. *Cerebellar Exploration from in Front of the Sinus.*—The bone is removed deeply from Trautmann's triangle which lies between the anterior border of the sigmoid sinus and the semicircular canals (Fig. 242), the latter being the anterior boundary of the exploration. This exposes a triangular area of dura covering the surface of the cerebellum, which lies behind and below the internal auditory meatus.

The placing of the drainage tubes, the counteropening from the skull surface, etc., are similar to the steps taken for the cerebral abscess. In the case of the cerebellar abscess, when a counteropening from the skull surface is to be made, an osteoplastic flap may be tried, but it has not generally been a success.

After-treatment.—Subsequent to an operation which involves so serious a procedure as evacuation of an abscess of the brain, it becomes imperative to sustain the patient by proper nourishment and to relieve the condition of surgical shock. Concerning the latter, it has been the author's experience that no remedy has been so efficacious as the introduction of high enemas of normal salt solution, repeated at intervals of three or four hours. Patients

revive quickly under its benign influence, the pulse becomes stronger and steadier and the respirations normal.

It is extremely important that patients should retain the reclining position and live in the most quiet manner until all serious symptoms have subsided. Mental worry or excitement and physical exertion tend to disturb the conditions within the brain and are prone to excite an extension of the pathological process. It is sometimes necessary to administer cardiac stimulants in the form of strychnia or whiskey, for a few days. The diet should be bland and nourishing, and water should be drunk freely.

The time for changing the primary dressings is gauged by the subsequent symptoms, which if entirely favorable in every particular, the inner dressings may remain undisturbed for a period of five or eight days. The outer dressings, after the second day, usually become stained from the free discharge from the pus cavity, in which event they should be changed. Thereafter the outer dressings may be changed daily. In case a rubber drainage tube has been introduced into the abscess cavity, it is advisable to withdraw it a short distance at each dressing, in order that the abscess cavity may freely granulate without the interference of the tube.

Cerebral hernia sometimes complicates the healing of the bone aperture. When of small dimensions usually they disappear without special treatment; but whenever they do not subside pressure should be applied by means of a series of gauze pads so arranged that pressure will be exerted upon the protruding mass when the mastoid bandage is snugly applied. Whenever the protruding mass, which mostly is made up of granulations, is intractable, it should be excised with the scalpel or scissors.

Results of Operation.—Immediate effects are apparent upon the successful evacuation of a brain abscess. The pulse and the temperature either become normal or, after a short period of elevation, they gradually drop to the normal. This is especially marked where, prior to evacuation, the pulse and the temperature have been subnormal. The sensorium promptly clears, and the patient emerges from the comatose state. Paralysis, when of short duration, speedily disappears, and nourishment is asked for and retained. Finally, cerebration becomes alert.

The results of operation as reported by Macewen show 8 recoveries in 9 cases of temporosphenoidal abscess. Of cerebellar abscess he reports 4 cases, all of which recovered. Körner reports 66.6 per cent. cures in the cerebellar cases, and 84.6 per cent. cures in cerebral cases from those he was able to collect in the literature. Finally, Räpke, examining the literature to determine the permanence of cures thus effected, finds that 40.4 per cent. of the recoveries reported remain permanent.

SECTION IV.

Diseases of the Perceptive Apparatus and Miscellaneous Diseases and Conditions.

CHAPTER XXVII.

DISEASES OF THE PERCEPTIVE APPARATUS.

OTOSCLEROSIS.

UNDER our general classification of diseases of the middle ear we include a third type, otosclerosis, which we designate as having a constitutional basis. It is characterized by progressive deafness which is not due either to a catarrhal or a bacterial process. Likewise, it is distinct from disease of the auditory nerve. Its actual nature is still somewhat in doubt. The disease was first described by L. Katz (1890), and has since been verified microscopically and clinically by many observers. (Denker.[1])

Pathology.—The lesion is a spongification of the bone of the labyrinthine capsule. The process begins as a change from the normal consistency of the bone to that of compact bone. This is later replaced rather irregularly by the spongy deposits. The spongification takes place particularly in the labyrinthine capsule and around the oval window, eventuating in an involvement of the annular ligament, and finally in an ankylosis of the footplate of the stapes (Fig. 264).

Etiology.—Boenninghaus questions whether otosclerosis is to be regarded as a primary disease in the bone or whether it is a secondary affection, the sequela of a pathological change in the middle-ear mucosa.

Formerly it was a general belief among otologists that the changes were secondary to changes in the mucous membrane of the middle-ear spaces, and according to the observations of Haberman the deposits follow the course of the nutrient arteries in the bone. Shambough, however, has shown that these arteries from the mucosa of the middle ear only penetrate to the most externally placed layers of bone, and the nutrient arteries from the labyrinthine spaces nourish the deeper bony layers. He further demonstrated that the communications between these two systems of arterial supply was unimportant (he used the ears of calves for his demonstrations, and in these the communications were established).

If the deposits were to follow the route of the arteries they should be found located superficially, in the immediate neighbor-

[1] Die Otosclerosa, 1904.

hood of the mucosa (Boenninghaus). On the other hand, the observations of Politzer and Siebenmann show that the lesion develops in the central part of the capsule, and spreads from this locality to the surface. Furthermore, Boenninghaus and other observers have found the tympanic cavity to be normal in many of these cases, and only relatively few gave evidence of the remains of a former active pathological process in the tympanic cavity. All these factors tend to strengthen the belief that otosclerosis is a primary disease of the labyrinthine capsule. We as yet have no positive knowledge of what it is that calls into activity this lesion in the bone. Hence it is vain to ascribe the disease to constitutional causes, chronic rheumatism, scrofula, gout, arteriosclerosis, syphilis, etc. It is to be noted, however, as significant, that otosclerosis occurs in families through succeeding generations. For

Fig. 264.—Spongification of the labyrinthine capsule (*Katz*). (Loaned by *Dr. H. J. Hartz.*)

Fig. 265.—Spongification of the labyrinthine capsule (*Siebenmann*). (Loaned by *Dr. H. J. Hartz.*)

this reason Siebenmann regards the etiological factor to be a postembryonal one, due to elements already present in the embryo. He does not regard the disease in any way as an inflammatory process.

The disease seems to be hereditary in certain families. This constitutes at least 52 per cent. of all the cases of otosclerosis recorded by Boenninghaus. Bezold places it as occurring in 89 per cent. of all cases of hardness of hearing in which both ears are attacked simultaneously, and of these 60 per cent. occur in women.

Relative to all ear diseases otosclerosis occurs in about 7 per cent. of the cases.

Course.—The first stage of otosclerosis may be designated the *latent stage*. This lasts just as long as the lesion remains confined within the central parts of the bony capsule.

The *manifest stage* commences when the spongification reaches a functionally active part of the internal ear, usually the footplate of the stapes. This seldom occurs before puberty or after forty years of age. It is a disease of young adult life. The symptoms develop very gradually, although exceptionally a rapid development has been noted. Intercurrent constitutional diseases or conditions seem to predispose to a more rapid development. Among such diseases we may mention pregnancy, lactation, and debilitating

diseases, such as typhoid fever. Finally, exposure to intense cold is believed to cause a rapid development of the lesion.

The disease runs a varied course. Sometimes the disease becomes exceedingly marked in a very short time, and, on the other hand, it may progress slowly for many years, and not become seriously marked until it interferes with audition. Usually the course seems to be distinctively progressive, until with the advent of total fixation of the footplate of the stapes it culminates in a high degree of deafness. The disease in some individuals is further characterized by periods of quiescence, when no advancement in the loss of hearing is appreciable. The above-mentioned periods of quiescence vary, in different individuals, from a few months to one or two years, after which the symptoms again become active and the disease progresses. It is only in very rare instances that the lesion involves the labyrinth proper, with resultant total deafness combined with disturbances of equilibrium.

Symptoms.—Hardness of hearing and tinnitus are the principal symptoms. Progressive loss of hearing is a constant subjective symptom. This may develop so gradually that it is hardly noticeable to the patient at first. Nevertheless, during each year the impairment progresses until the human voice and other familiar tones are heard with difficulty or become lost entirely. So long as the labyrinth remains unaffected, high tones like those of the singing voice or musical instruments may be heard. Likewise the hearing is often quite good when the patient is in a noisy place (paracusis Willisii).

Tinnitus is severe, persistent and prolonged, and is rarely absent at any stage of the disease. In patients who are not conscious of having lost some of their hearing faculty, the tinnitus will often become so severe that they are led to seek the otologist for relief. The tinnitus generally is of a deep tone, but varies individually both in tone, character and intensity. In nervous subjects severe and prolonged tinnitus often leads to profound neurasthenia. The intensity of the tinnitus is no indication of the degree of loss of hearing (see Chapter IV). The explanation of the tinnitus is still *sub judice*. In typical cases upon inspection the drumhead shows little if any thickening or opacity, it is not retracted and the light reflex remains visible. The Eustachian tube is patent throughout. Vertigo is rarely present in otosclerosis.

Diagnosis.—There is only one positive objective sign upon which a diagnosis may be based, and this according to most authorities is not invariably determinable. It is termed the "Schwartze symptome" and is characterized by isolated areas of hyperemia in the mucosa covering the promontory, as seen through an atrophied, transparent drumhead.

When in a case of chronic, progressive loss of hearing we are able to exclude middle-ear inflammation and also labyrinthine disease, then the finding of isolated areas of hyperemia on the mucosa covering the promontory, as seen through the normal drum-

head, confirms the diagnosis of ankylosis of the stapes—otosclerosis. (Boenninghaus.)

Middle-ear inflammations may be excluded on account of the characteristic otoscopic picture and the use of the catheter. Labyrinth diseases are excluded through functional tests of the mobility of the stapes (Gellé's test). Disease of the conducting apparatus is evidenced by the fork test (prolonged bone conduction), normal or only slight loss of the upper notes of the scale, and decided loss of the lower notes in the scale, that is, the low-tone limit becomes markedly raised.

Uncomplicated cases of otosclerosis are the most easily diagnosticated. When complicated by other lesions the diagnosis becomes a most difficult and sometimes an impossible problem. Generally speaking, the bone conduction may be almost normal, only slightly shortened, especially for the fork C^2. It is found somewhat lengthened for the C fork—the upper-tone limits are sharply lowered and the lower-tone limit decidedly raised.

As the disease progresses in the labyrinth proper the symptoms from the ankylosed stapes become completely masked, and the hardness of hearing approaches complete deafness, the upper-tone limit gradually becoming lower and lower until the entire scale is lost.

Between chronic middle-ear catarrh in its advanced stage and otosclerosis differentiation is almost impossible. In chronic middle-ear catarrh the hearing power is influenced by inflation when continued for some time; in otosclerosis the hearing remains absolutely uninfluenced. Finally, in all doubtful cases a family history of otosclerosis should be given great weight.

Prognosis.—So far as arresting the disease is concerned the prognosis is very bad. On the other hand, regarding total eventual deafness, otosclerosis gives a better prognosis, as it is not usual for the spongification to involve the labyrinth structures proper.

Where the last-named lesion does occur, the prognosis is poor, and, although a high degree of deafness will eventually ensue, it takes years to develop.

Treatment.—When a diagnosis of otosclerosis is positive, or even when ankylosis of the stapes is definitely established, there is but slight hope of influencing the disease by any system of treatment. When the ankylosis of the stapes is partial but sufficient to mechanically impede the propagation of sound impulses, then efforts to break up the ankylosis are to be considered in mapping out a course of treatment for these patients.

The simplest way to accomplish this purpose is through *ear massage* (see Chapter VIII). A Siegel otoscope attached to a pump worked by an electric motor best serves our purpose (motor, Fig. 3; Siegel otoscope, Fig. 29). A simpler apparatus is the Delstanche masseur. It acts similarly to the Siegel otoscope and motor pump. Its advantage lies in its comparative cheapness.

Lucae has devised a simple apparatus whereby he attempts to break up the ankylosis by water massage. The Lucae pneumohydromassage is given by means of an instrument which consists

of a glass ear speculum somewhat longer than the ordinary speculum, so as to fit snugly in the external auditory meatus. Usually it is capped with rubber so as to make it watertight in the ear canal. At the other end of the "T" there is a diaphragm so arranged as to hold the water which is placed in the stem of the T-shaped tube. This rubber end fits into another glass tube snugly and to this another tube is attached, which is connected with a pump worked by an electric motor. The T tube is filled with water.

The impulse transmitted by the pump goes through the tube and impinges upon the rubber diaphragm, where it is taken up by the water, and this transmits the impulse to the ear drum and drives it inward, acting on the ossicles and moving them.

Lucae also devised a spring pressure sound for the purpose of breaking up ankylosis of the ossicles. This consists of a probe the end of which is fitted to a small cup. The other end is attached to a handle, around which a spring works, so that, when the cup is placed upon the processus brevis and the instrument pressed inward, the spring gives resistance and thus graduates the amount of force used. The handle is so constructed that the pressure can be changed to varying degrees. The use of this instrument entails much pain, and requires a skillful operator lest injury to the eardrum result.

Extraction of the stapes has been tried by Kessel and others. The operation entails danger, through infection, and is unsuccessful, because during the operation the stapes usually fractures and the head and its crura come away, leaving the footplate *in situ*. The object of the operation is thus defeated, and, because of the danger of an infection of the labyrinthine channels, the operation of removing the stapes is no more attempted.

The results of massage vary. In rare instances some improvement in hearing is secured and the tinnitus is relieved, at least to some extent. One meets cases which are unfavorably influenced by the massage treatment. In these the prognosis is bad. Neither is local treatment of avail in arresting the advance of the disease. The majority of patients suffering from otosclerosis lose courage and float around from one otologist to another, or cease treatment altogether. Unless warned in season they afford a rich harvest for quacks and charlatans.

Meanwhile, general treatment should be given to the patient and his habits and diet should be regulated. All excesses should be interdicted, and especially should alcohol and tobacco be debarred. Cold-water baths and sea bathing are harmful. The evil effects of anemia, plethora, constipation, excessive work and worry should be combated. The patient should not wear constricting clothing about the neck or anything which raises the blood-pressure in the head—pressure at stool, tight corsets, collars, etc. Warm baths are recommended, and resort to mountain heights in the summer season is beneficial.

Medicinally, various drugs have been employed. The drug which apparently has the most influence in affecting the bone

deposits on the labyrinthine capsule is phosphorus. This was first recommended by Siebenmann in 1898. The use of this drug is based upon experimental work of Mirva and Stötzner during clinical observations upon its effects in cases of rachitis. Siebenmann claims that in 50 per cent. of the cases he at least arrested the progress of the disease by using phosphorus. The following formula has found favor and is convenient to administer:—

℞ Phosphori 0.03
Olei jecoris aselli
or
Olei olivarum .....q. s. ad 300.0
M. Sig.: ʒij twice daily.

It may also be advantageously administered as follows:—

℞ Phosphori 0.03
Olei amygd. 30.0
Gum arab. 30.0
Aqua dest. 300.0
M. et ft. emulsio.
Sig.: ʒij twice daily.

The iodin preparations also have been found efficacious for relieving tinnitus. Potassium iodid in increasing doses is given.

All of these medicinal preparations must be continued for long periods.

MISCELLANEOUS LESIONS OF THE PERCEPTIVE APPARATUS.

Hemorrhage and Emboli in the Labyrinth.—Hemorrhage into the labyrinth channels occurs occasionally under a variety of conditions, the most important of which we will briefly discuss.

Alexander (1903) and also Schwabach (1897) report cases of hemorrhage into the labyrinth in leukemia. Besides the blood, a large number of lymphocytes are found in the labyrinth. These hemorrhages cause compression and result in degeneration of the nerve, the ganglion cells and the organ of Corti.

The labyrinthine symptoms develop either gradually and slowly or they develop rapidly and become evident only prior to death.

Habermann (1890) reported a case with labyrinthine hemorrhage, as a complication of *pernicious anemia.*

Sugai (1900) and Citelli (1906) observed labyrinthine symptoms and diagnosticated labyrinthine hemorrhage in cases of *purpura hæmorrhagica;* while Morf (1897) contends that hemorrhages into the labyrinth accompany both *acute* and *chronic* nephritis. Boenninghaus, however, believes that the hardness of hearing and the other ear symptoms observed in the course of nephritis are the direct result of the uremia rather than of hemorrhage into the labyrinth.

Caisson Workers' Disease.—This condition is also classed by many as a lesion due to hemorrhage into the labyrinth.

These workmen labor in chambers wherein air pressure is much increased over the ordinary atmospheric pressure. As they leave these chambers, and return to the normal air pressure, they undergo a series of symptoms known in the trade as "bends," which consist of an apoplectic seizure lasting from a few minutes to hours. During this attack they develop the Ménière symptom-complex. The dizziness may gradually disappear, but the hardness of hearing remains for a much longer time. According to Alt (1897), the labyrinthine capillaries are plugged with gas emboli, and at spots with extravasations of blood.

Acoustic Neuritis.—Nerve deafness may originate from any conditions which would cause a neuritis in other parts of the body.

According to Wittmaack (1903), in acoustic neuritis the disease is confined almost exclusively to the nervus cochlearis, affecting mostly the peripheral neuron, the ganglion spirale, and the hair cells of the organ of Corti.

Regeneration of the nerve is believed to be possible as long as the ganglion cells are not destroyed completely.

Diagnosis.—Absolute diagnosis is not possible, but in some it is possible to differentiate acoustic neuritis from other labyrinthine affections. Nerve deafness usually presents no symptoms of dizziness and no Ménière symptom-complex. The etiology gives additional diagnostic data; the ingestion of toxic substances, quinine, salicylate of soda, excessive use of tobacco, etc., tend to induce nerve deafness, while meningitis and otitis media purulenta are more likely to result in labyrinthine disease. The diagnosis is one of elimination.

Clinically we differentiate two types of acoustic neuritis. The first type, due to explosion of cannon or other sudden, loud noises, gun fire in military life, etc., and the second type, the more common, caused by certain trades like that of boilermakers or other factory workers whose ears are continuously exposed to loud noises.

These cases present distinct loss in bone conduction, and they do not hear the whispered voice.

Pathologically, they are victims of atrophy of the nervus cochlearis.

Finally, cases of nerve deafness may be grouped, according to their causative factors, as follows:—

1. Those caused by poisons. Under this heading are placed quinine, salicylate of sodium, tobacco, alcohol, lead poison, phosphorus, etc.

2. Cases caused by toxins. Bacterial toxins in the blood are accountable for most of this group. The toxins of typhoid, typhus, tuberculosis, measles, scarlatina, diphtheria and the mumps are examples of this group.

3. Cases caused by constitutional disease. The most important in this group are those caused by *diabetes*. The next most impor-

tant are those caused by syphilis. Finally, the disease may be caused by autointoxication (Stucky), or by the rheumatic diathesis.

Primary Atrophy of the Acoustic Nerve.—This condition is not necessarily the result of a prior inflammation of the nerve. It is found in *old age* and in those with *premature arteriosclerosis.*

In the cases of senile atrophy neither dizziness nor tinnitus are experienced, whereas in the cases of premature arteriosclerosis these symptoms are usually present (Stein).

In cases of tabes (Chapter XXXII), according to Friedrich, 10 per cent. suffer from nerve deafness due to degeneration of the nerve.

The ear symptoms may precede all other signs. The deafness is rapidly progressive, and soon other signs of tabes become established and the diagnosis is made.

Finally all these obscure cases of hardness of hearing should be thoroughly examined physically, the status of their arteries determined, the blood-pressure estimated, the urine examined, and the reflexes particularly looked into, in order to furnish additional diagnostic data.

CHAPTER XXVIII.

MISCELLANEOUS OTITIC CONDITIONS.

HYPEREMIA OF THE MENINGES INDUCED BY INFECTION IN THE MIDDLE EAR.

SIMPLE hyperemia of the meninges incited by the pressure of pus in the middle ear undoubtedly occurs with comparative frequency. It is believed that portions of the dura adjacent to the middle-ear structures become congested and hyperemic, but, unfortunately, postmortem examinations of this condition are extremely rare, inasmuch as recovery usually takes place and the hyperemia terminates in resolution. Occasionally the disease progresses and the local inflammatory areas result in thickening, bony adhesions and even cerebral softening. Unless the primary etiological factor is removed the disease may terminate in serous meningitis.

EMBOLI IN THE BRAIN FOLLOWING THROMBI IN THE CAROTIDS.

While thrombosis is more common in the large venous meningeal vessels, arterial emboli of carotid origin are occasionally observed. The thrombus as a rule is transmitted into the area supplied by the artery of the Sylvian fissure of the same side. Körner has reported several of these cases wherein thrombi in the carotids had been discovered.

OTITIC PYEMIA.

Pyemic infection of the meninges and brain is one of the deplorable complications of both acute and chronic purulent otitis media. The disease never remains entirely local and extends more or less rapidly to other organs of the body. Otitic pyemia occurs oftener in connection with chronic than in the acute form of purulent otitis media, and furthermore it is often confounded with purulent meningitis, from which a differential diagnosis is difficult to establish. If an absolute diagnosis of otitic pyemia could invariably be rendered, then many cases now classed as purulent meningitis would properly be classified under the former heading.

Pyemic infection is believed to migrate chiefly through the lymph vessels, but to a lesser degree the infection may be carried by blood-vessels through inflammatory exudation of the vascular walls and rapid formation of thrombi. When pneumonia bacilli prevail in the middle-ear discharge a complicating pyemia is more prone to ensue, and lateral sinus involvement may or may not be present.

Metastases in various organs may be produced by the bacteria which circulate in the blood, when it is the seat of bacteriemia. Körner differentiates two types of otitic pyemia, one in which it is associated with sinus phlebitis, and in the other there is no complication. The former is more commonly combined with chronic purulent otitis media, and the latter with acute purulent otitis media by means of absorption of pus from the primary focus in the temporal bone.

Primary otitic pyemia, in acute as well as chronic otorrhea, sometimes originates by direct infection through the floor of the tympanum. The pathway of infection may be (*a*) through dehiscences in the tympanic floor; (*b*) through openings in the floor which have resulted from necrosis; (*c*) through the normal foramina in the tympanic floor. The infection in the above-described cases invades the dome of the jugular bulb.

Diagnosis.—The diagnosis is based upon the clinical evidences of sepsis and the presence of bacteria in the blood.

Prognosis.—The prognosis is grave and unfavorably influenced when associated with sinus phlebitis. Timely surgical interference influences the prognosis favorably.

Treatment.—The treatment must first be directed against the original pathological focus in the temporal bone, and all diseased tissue in this region should be radically extirpated. Occasionally, when accompanying acute purulent otitis media, the symptoms will rapidly subside after the confined pus has been evacuated by paracentesis. If the pyemic manifestations are not arrested as a result of this procedure the mastoid process should be surgically entered, all diseased tissues removed, and the lateral sinus sufficiently exposed to admit of proper inspection. Where the sinus is found to be diseased or thrombosed it should be operated upon after the manner described in Chapter XXIV, page 358.

Finally, the vaccine treatment may be given a trial.

OTITIC SEPTICEMIA.

Septicemia of otitic origin is characterized by violent symptoms and an extremely rapid course. The prominent symptoms are chills, profuse sweating, remittent fever, with irregular respirative curve, great prostration and delirium. The infection travels by way of the lymphatic channels, and, according to Körner, there usually is a septic involvement of the retina, heart and kidneys, and hemorrhage into the muscular tissues. Metastatic abscesses are usually absent. The disease often proves fatal within a few days.

Diagnosis.—That of general septicemia.

Prognosis.—Unfavorable.

Treatment.—The same as for general sepsis. Stimulants and attention to the kidneys, bowels and skin.

DISTURBANCES OF THE HEARING FUNCTION OF INTRACRANIAL ORIGIN.

Acute meningeal inflammations, intracranial, gummatous and tubercular deposits have already been referred to (Chapters XXIV, XXV, XXVI, XXIX and XXX) as causes of tinnitus, vertigo and deafness. Other cerebral causes are those originating either in the roots, nuclei or trunk of the auditory nerve. Still more common and important are: cerebral hemorrhage, embolism, chronic sclerosis, acute and chronic hydrocephalus, and new growths. Severe and persistent tinnitus is often a prodromic symptom of an impending apoplectic attack, and, when occurring in elderly individuals with sclerosed arteries or cardiac diseases, this symptom should be looked upon with suspicion.

DEAF-MUTISM.

The acquisition of speech is dependent upon audition. In congenital deafness, or when the sense of hearing has been lost during the first years of life, the individual has been bereft of the strongest impetus to the acquirement of speech, and as a result it is either never acquired or is progressively lost until the deaf child has become a deaf-mute. It is rarely possible to determine whether deafness is absolutely congenital or whether the perceptive function has been destroyed by disease.

Etiology.—Deaf-mutism is usually the result of some disease of early infancy which has produced either destruction of or severe injury to the perceptive mechanism, a condition which may remain unnoticed even by parents until long after the usual time when the child should commence to interpret sound vibrations. That heredity plays an important rôle there can be no question, inasmuch as statistics clearly show that deaf-mutism is more or less clearly influenced by consanguinity in parentage, and to some extent by direct transmission, although the children of deaf-mute parentage usually are found to possess good hearing. Inherited diseases, like syphilis, are believed to possess some indirect influence along this line. Intra-uterine disturbances have also been mentioned as causative factors. By far the larger percentage, however, of deaf-mutism results from those infantile diseases which tend to destroy the perceptive function. Among these the acute infectious diseases, intracranial inflammations, notably epidemic cerebrospinal meningitis, adenoid vegetations, inasmuch as they indirectly incite intratympanic and labyrinthine inflammations—in fact, any inflammatory condition which tends to affect the sense of hearing in early childhood will be found to seriously interfere with the acquisition of speech. In a considerable percentage of cases the chief causative factor is the congenital absence of some portion of the perceptive or conductive mechanism, such as meatal atresia, intratympanic malformations, occlusions of either the oval or round window, or defect in the trunk or distribution of the auditory nerve.

Total deafness for all sounds in deaf-mutes is rare, the majority exhibiting defective perception for the highest and lowest sounds, or a limitation of the auditory field sufficient to materially interfere with the acquisition of speech. Often there is an unequal perception of individual sounds. It is important to differentiate between the actual perception of speech and the intellectual appreciation of the spoken word (psychical deafness).

The first symptom usually observed is that the child is passing by the age when articulate speech should develop. At this period parents usually make use of other means to determine whether the auditory function is present, often submitting the ears to examination either by the family physician or the otologist. In the more severe cases the failure to respond to questioning, together with noticeable failure to give any form of evidence of the perception of very loud sounds, gives clear indication of mutism. When due to purulent or intracranial inflammations in children who have already learned speech, there will be noted a gradual loss of vocabulary and finally failure to respond to all sounds.

Diagnosis.—The diagnosis of mutism must be based upon the failure of the individual to acquire speech during that period of life when this function may be expected to develop, an age which varies considerably. It should be noted that normally the development of this sense is often much delayed. A previous history of severe aural attacks is of considerable aid in determining the state of the perceptive function. Tuning forks, loud jars or noises are also to be employed, although in very young children they do not invariably furnish conclusive evidence. Loud clapping of the hands just posterior to the occiput by an assistant unseen by the patient furnishes valuable evidence, inasmuch as the facial expression will usually clearly indicate whether the child has heard or not. In children of sufficient age and intelligence the tuning fork and Galton whistle should always be employed, inasmuch as aërial and bone conduction in mutism will be found partially or wholly destroyed.

Prognosis.—The prognosis is always grave, both for audition and the acquisition of speech. Politzer[1] contends that a better prognosis may be expected in the congenital cases.

Treatment.—The treatment is twofold: (*a*) to overcome the deafness, and (*b*) to develop speech. The former, in addition to the required local means, the technique of which is described in the chapters relating thereto, includes the treatment of any middle-ear lesion which may complicate the deaf-mutism; meanwhile the affections of the nose and nasopharynx, especially diseased adenoid tissue, and hypertrophied tonsils should receive appropriate treatment. The development of speech in these cases is largely educational; methodical hearing exercises are of supreme importance, especially when it can be demonstrated that even a small proportion of the hearing function remains. These may be carried out by

---

[1] Diseases of the Ear.

directing the patient's attention to auditory impressions and developing his appreciation of spoken words, musical sounds, and various noises, much time being given to stimulating and strengthening these impressions. The systematic use of hearing exercises whenever possible should be carried out by a teacher whose training and intelligence, patience and perseverance have specially fitted him for this important work. This method should not be too soon abandoned, even under discouraging circumstances, since the possibility of success exists even in mutes heretofore considered hopelessly deaf. Urbantschitsch points out in this connection that a further development of the auditory sense becomes possible as a result of the awakening of the first vestige of hearing. Independent exercises with musical sounds or with speaking tubes may be conducted by the patients themselves. The early efforts are largely expended to overcome the patient's diffidence and seeming lack of interest; hence, it often requires persistent training for months, and they do not usually attempt speech until they have actually acquired considerable proficiency. The influence exerted by methodical hearing exercises upon the hearing sense stimulates the individual to further development and lays the foundation for appreciative comprehension of auditory impressions. The signs of improvement in audition are characterized by a gradual differentiation of various sound impressions, together with a fuller comprehension of the significance of spoken words. Methodical hearing exercises should be continued, throughout the period during which ordinary sound waves do not suffice to raise the sensation of hearing beyond the mere threshold of perception, until the more ordinary sounds are perceived and comprehended by the strengthened auditory sense.

The results of the hearing exercises depend upon the character and duration of the training, the condition of the function and the personal equation of the patient. It cannot be too strongly emphasized that individual teaching is practically essential in order to procure the best results. When this is impossible mutes should be placed in the very best obtainable schools where the same methods are carried out, even though with less individual instruction.

In several of the large cities of America, including New York City, the school boards have established schools devoted exclusively to the education of children with defective hearing. Here they not only receive instruction in articulate speech and the acquirement of knowledge through books, but are taught the art of manual training which fits them for self-support and positions of trust and responsibility.

Lip Reading.—It is well known that the loss of one special sense is partially recompensed by added acuteness of those which remain. Individuals who are partially deaf invariably watch the movements of the lips and facial expression of those who address them and are thus better able to understand conversation. Lip reading has, therefore, been placed upon a scientific basis, and is

taught privately and in schools with marked success. The student of lip reading succeeds only by the most continuous and painstaking personal effort, both upon his part and that of the teacher, and special individual instruction is imperative. The otologist is usually consulted in regard to the employment of instructors, and should recommend only those who are capable and free from charlatanism.

SOCIAL SERVICE AND COMMUNITY CENTERS FOR THE DEAFENED.

During recent years the necessity for various types of social service help for deafened people has become sufficiently evident to result in the formation of organizations in several of the larger cities of the country, the object of which is to improve the condition and relieve the misfortunes of persons whose hearing has been lost or impaired. These local organizations aim to attain this object through encouragement of research into the causes and treatment of deafness, the development of special methods of instruction, the establishment of scholarships in lip reading, assistance in procuring and retaining employment, furnishing of voluntary relief in destitute cases, club house opportunities for social enjoyment and for the development and exchange of ideas. These organizations aim to bring into association lip reading teachers, otologists and deafened individuals. The author commends this work both for its wonderful results upon deafened people and for the aid which he receives in being able to tell his deafened patients that while there may be no hope for improvement in the fast fading hearing function, he may hold out the hand of hope that through lip reading education, congenial occupation, social pleasures and sympathetic companionship received directly through the above type of organization, this most difficult problem is largely solved. So rapidly has this work grown during the past five years that a national organization has come into existence, known as the American Federation of Organizations for the Hard of Hearing.

THE RELATION OF EAR DISEASES TO LIFE INSURANCE.

The majority of life-insurance companies refuse to insure applicants who suffer from purulent otitis, and make no attempt to discriminate as to the variety, extent, character or severity of the infectious process. The author has taken considerable pains to gather statistics in an attempt to formulate some rules which might bear directly upon the question of actual risk to life in the various types of aural disease. In a paper published in the Transactions of the American Laryngological, Rhinological and Otological Society, 1903, he states that Schwartze's records show that about 13 per cent. of all aural diseases are of the chronic purulent variety. A study of Guy's Hospital Reports by Pitt[2] shows that, of 9000 consecutive autopsies at Guy's Hospital, between 1869 and

[2] British Medical Journal, 1890, vol. i, p. 643.

1887, there were 57 cases of death due to aural suppuration, or 1 in every 158 autopsies. Gruber,[3] in the report of 40,073 autopsies held at Vienna General Hospital between 1873 and 1894, says death was due to aural suppuration in 232 cases, or 1 in every 173. Poulson,[4] out of 14,580 autopsies at the hospital in Copenhagen, from 1870 to 1895, in 48 cases, or 1 in every 303, says death was due to aural suppuration. Barker[5] reports that out of 8028 autopsies in three London hospitals death was due to aural diseases in 45, or 1 in every 178. By totaling these figures it will be seen that out of 71,681 autopsies there were 382 deaths resulting from aural suppuration, or 1 in every 187. A comparison of these autopsy reports with the statistics covering work done in the treatment of aural diseases in hospitals and clinics furnishes considerable valuable information. Birkner[6] states that out of 33,017 cases of aural diseases of all kinds there were 104 deaths from the effects of aural suppuration, or 1 in every 17. Randall,[7] out of 5000 cases of aural disease of all kinds, reports 15 deaths due to middle-ear suppuration, or 1 in every 333. Dench found that out of 64,858 cases of aural disease treated at the New York Eye and Ear Infirmary there were 218 cases of serious intracranial complications, or 1 in every 296. Of these there were 20 cases of cerebral abscess, 46 cases of sinus-thrombosis, 7 of cerebellar abscess, 2 of otitic meningitis, and 119 of epidural abscess. It should be noted that these were not all fatal cases. He also noted that of the total number there were 4836 of acute purulent otitis media, 14,487 of chronic purulent otitis media. Making these the basis of calculation, intracranial complications occurred in 1 out of every 88.

The author's statistics, based upon the records of the Manhattan Eye and Ear Hospital, show that out of 29,223 cases of aural diseases recorded there were 118 cases of serious intracranial complications, or 1 in every 248. Of these there were 32 cases of involvement of the lateral sinus, 16 of otitic meningitis, 12 of brain abscess, and 58 of extradural abscess. Of the total number there were 7614 cases of purulent otitis media, of which 2436 were acute and 5178 chronic. Making the purulent cases alone the basis of calculation, there was 1 serious complication in every 65. Not all of these were fatal and many are restored to health by timely operation.

From these statistics it will be seen that the fatalities arising from aural diseases are chiefly those of purulent origin. An occasional fatality follows traumatism and hemorrhage.

Partial deafness, whether catarrhal or the result of former purulent disease, does not materially vitiate the individual as a risk for life insurance. Profound deafness adds simply the moderate risk of death or injury arising from the individual's inability to

---

[3] Monatsch. für Ohrenheilkunde, 1896, p. 311.
[4] Archiv für klin. Chirurgie, vol. lii, Section 2.
[5] Hunterian Lectures, Illustrated Medical News, London, 1889.
[6] Archiv für Ohrenheilkunde, vol. xx, p. 81.
[7] Transactions of the American Otological Society, vol. v, No. 1, p. 101.

give heed to those warnings which are symbolized by sound signals. Considering aural affections as a whole, it becomes obvious that the chief dangers to life resulting therefrom arise from the complications of purulent invasion of the middle ear and especially the chronic type of this troublesome disease.

The most dangerous complication of purulent otitis is osseous necrosis, whereby infection extends to the venous sinuses, the labyrinth, and the meninges. These complications are prone to occur at any time, but are more prevalent between the ages of sixteen and thirty years. Individuals who suffer from chronic purulent otitis are slightly more susceptible to other forms of chronic disease, notably tuberculosis.

A careful study of the rules followed by a large number of life-insurance companies indicates that but little discrimination is exercised by their medical departments in classifying the different degrees of purulent aural disease, the tendency being to penalize all such applicants by insuring them as substandard risks or by adding materially to the premium rate. The majority of companies are inclined to overestimate the danger to life attendant upon middle-ear diseases. Furthermore, with a more careful discrimination as to the variety, character and extent of the disease, many prospective insurers, now rejected or penalized, might safely be accepted at the usual premium rates.

It is also important to record the relation which the radical mastoid operation performed for the cure of chronic purulent otitis media bears to life insurance. Thorough eradication of the entire area of necrosis, both of bony and soft tissues, with all surfaces finally healed and covered with healthy skin, practically places the ear in a condition whereby it no longer becomes a menace to life. From a life-insurance standpoint, therefore, it would seem that this operation, when successfully performed upon a person otherwise insurable, should render him safely insurable without penalty or prolonged postponement.

The following suggestions are ventured for guidance in classifying those with defective audition or disease of the auditory apparatus:—

Simple catarrhal otitis, with or without deafness, aside from the possible danger of accidents, does not meance life. Chronic, non-purulent disease of the labyrinth, while more serious than catarrhal otitis media, does not materially tend to shorten life. Acute purulent otitis media, in an otherwise healthy individual, should not debar him as a safe risk beyond the time necessary for complete recovery, a period usually of from one to six weeks. Recurrent purulent middle-ear inflammation, especially in early life, usually results from some form of intranasal infection, and is commonly associated with adenoid growths in the vault of the pharynx or hypertrophied tonsils, and subsides promptly and permanently as soon as these have been removed, after which time such applicants should be considered safely insurable. A large proportion of the serious intracranial complications of middle-ear

suppuration occurs in chronic purulent otitis media, and the statistics above mentioned clearly prove that such complications occur with sufficient frequency to render the victims of this type of ear disease less favorable as life-insurance risks. Chronic purulent otitis media attended with continuous discharge, with foul odor, especially when accompanied with excessive granulations, indicates necrosis, and therefore becomes the most serious type of ear disease. Such applicants should be considered bad risks under all circumstances until a cure has been effected either by local treatment or radical operative interference. Large perforations and free drainage, while militating in favor of the applicant, should not be considered a positive guarantee against extension of the necrotic process to deeper structures.

The radical operation successfully performed in an otherwise healthy individual should, after a reasonable time, render him safely insurable.

Malignant neoplasms involving any portion of the auditory apparatus menace the individual's life to the same degree as when occurring in other portions of the body. Aural syphilis, tuberculosis, lupus and cholesteatoma are likewise inimical to longevity. All pathological conditions, whether associated with purulency or not, need to be accorded full consideration. Non-malignant types of aural disease, which are classified as sebaceous cysts, hematomata, perichondritis, frostbite and eczema, do not exert any material effect upon longevity.

In important cases, especially where large amounts are desired, the opinion of an expert otologist should be of value in deciding the degree of danger in the individual case.

AURAL SYMPTOMS OF NEURASTHENIA.

Functional aural disturbances are occasionally observed in connection with the neurasthenic state. Inability of the patient to endure any form of prolonged nervous or mental strain, which is characteristic of neurasthenia, is sometimes evidenced by marked disturbance of the hearing function.

Symptoms.—Tinnitus is the most frequent symptom of neurasthenic aural disturbances. The character of the tinnitus is variable, the noises changing from time to time, and it is aggravated by fatigue, anger and emotions. Pain is another prominent symptom of neurasthenia, and it frequently occurs in association with the tinnitus.

During the morning, after complete rest, all disturbing symptoms are usually absent, only to return after even moderately prolonged effort to carry on conversation or to concentrate the auditory function, with marked depression which often amounts to hypochondriasis, or even mild insanity. A roaring tinnitus is usually present, which is always aggravated by fatigue. There is a sense of fullness or irritation in the region of the Eustachian tube, and an apparent tendency to rapid fluctuations in the hearing power.

Diagnosis.—The diagnosis is not usually difficult, especially when the general neurasthenic condition is marked. The drum membrane is usually normal in appearance, and unless fatigued the hearing is good. Neurasthenics are prone to exaggerate all symptoms, and to give undue prominence to the slightest abnormality. Hyperacusis is usually present.

Prognosis.—When not accompanied by organic changes in the auditory apparatus the prognosis is good in those who finally recover from the underlying neurosis.

Treatment.—From the nature of the affection it is obvious that the aural treatment is secondary to that of the general health. These patients should be given the most optimistic statements as to prognosis, and be encouraged to make every effort to cease from worry about their hearing. Internal medication in the form of strychnia and bromids may occasionally be of some service, but is not to be relied upon. A complete change of scene and mode of life, with rather strenuous, healthful exercise and plain diet, give the best results.

MALINGERING (SIMULATED DEAFNESS).

Among the neuroses there are various types of malingering which are difficult to differentiate from actual disease. The underlying motives are either of a hysterical nature or are dishonest attempts to feign deafness for the purpose of avoiding service in various capacities, work in general, or blackmail to collect damages.

Simulated deafness may be recognized by various methods. It is important that the otologist, who is often called upon to determine the true facts, be able by a series of tests to determine the true status of each individual case. A preliminary examination of the auricle, external meatus, drumhead and Eustachian tube, should be made. If no lesion or pathological changes are discovered and no objective signs of ear disease are present the tests may be continued. Many of these individuals have given considerable study to the subjective symptoms of middle-ear and labyrinthine deafness, and are peculiarly shrewd in carrying out their attempts to deceive. They usually simulate unilateral deafness.

It is important to make all tests with the eyes of the patient bandaged, in order to prevent him from making use of his visual judgment of distances. After tightly plugging the normal ear, if he shows a tendency to vary the distance at which he hears the voice or acoumetre, it may be assumed that he is malingering. In this manner the Chimani-Moos test is carried out.

A large-sized vibrating tuning fork, $C,^2$ is held alternately at an equal distance from each ear. In this manner it becomes self-evident that the tone is beard better in the ear which is claimed to be sound. The vibrating tuning fork is then placed on the median line of the vertex, or against the incisor teeth, and the patient asked to indicate in which ear the tone is better perceived. The patient with true aural disease affecting the sound-conducting apparatus will state without hesitation that he hears the tone much

louder in the diseased ear, while the malingerer, after hesitating for a moment, inasmuch as he is really unable to distinguish any difference of perception in the two ears, thinks he is answering correctly by stating that he hears the tone in the normal ear. If, then, the external meatus of the normal ear is tightly closed and the vibrating fork is again placed upon the vertex or incisor teeth, the individual, if really deaf, will now say that he hears the tone better in the closed normal ear; or, he may no longer be able to distinguish on which side he perceives the tone. The malingerer, with the normal ear tightly closed, will state that he does not hear the tuning fork placed upon the vertex or incisor teeth at all.

Erhard's Test.—If the external meatus of a normal ear is tightly packed it will still conduct the sound waves to a limited extent, a loud-ticking watch being heard at a distance of 2 or 3 m. Erhard places the malingerer in the middle of a large room, closes the ear which is said to be deaf, and then brings a loud-ticking watch gradually toward the normal ear and orders the patient to count the beats. The normal ear is then tightly closed and the supposed diseased ear examined. If the malingerer claims that he does not hear the watch-tick at a distance of 1 or 2 m. (the distance at which the tick should be heard in the closed normal ear), simulation should be suspected.

It is sometimes possible to detect simulated unilateral deafness by means of an ordinary stethoscope by plugging one of the tubes. Here the closed tube of the stethscope should be placed in the normal ear and the open tube in the suspected ear. The patient should then be directed to repeat the words spoken by the examiner into the bell of the stethoscope. After removing the instrument the patient's normal ear should be tightly closed and the same words repeated to him. If he now says he cannot hear the words which he has already repeated when the normal ear was tightly closed with the plugged earpiece of the stethoscope, he will have furnished sufficient evidence of malingering. The author's noise producer (Fig. 243) is also a valuable aid.

To these tests must be added the importance of the experience and trained eye of the examiner, who will often be able to forge a chain of evidence from a succession of minor evidences of deception, made up of contradictions recorded from repeated examinations, and overzealous statements as to the nature and cause of the affection. Chimani lays much stress upon the general appearance of the individual, his temperament, peculiarities of facial expression and speech.

The more extreme procedures, such as testing the hearing capacity of a person who has just awakened from sound sleep, or who has recovered from narcosis, are hardly necessary. Boisseau suggests, in bilateral deafness, the making of insulting remarks concerning the patient in his presence, during which a close observation of his face will sometimes betray by flushing or changes of expression which indicate the existence of auditory perception.

REQUIREMENTS OF THE UNITED STATES ARMY AND NAVY IN REGARD TO THE HEARING OF APPLICANTS FOR ENLISTMENT.

The following rules are from the manual for examination of recruits:—

1. For admission to the army. "Tumors or growths in the passage to the external ear may be at once discovered, and are causes for rejection."

"The discharge of 'matter' from the ear is generally an evidence of diseased condition of the parts within, which is very likely to lead to permanent deafness, and is, therefore, a cause for rejection."

"Deafness of either ear constitutes an absolute cause of rejection."

"As the distance at which the natural tone of voice may be heard in a closed room, when both ears are normal, is about 50 feet, the distance at which the applicant is to stand from the examiner must be as great as the apartments will allow, not to exceed 50 feet."

"The applicant will stand with his back to the examiner, who is to address him in a natural tone of voice. When the distance is less than 40 feet, it should be specified on the examination form, and the tone of voice will be lowered. Failure of the applicant to respond to the address of the examiner will demonstrate a defect."

"The personal attention of the recruiting officer or sergeant must be given to closing the entrance to each ear separately, by pressing with the thumb the small lobe (tragus) situated in front of the opening to the inner ear."

"Advantage should be taken of the absence of other sounds to make the examination. Recruiting officers should remember that a man may be totally deaf in one ear, and yet may hear all ordinary conversation perfectly if the sound ear is not completely stopped. Deafness of one ear is a bar to enlistment, but in ordinary occupations it might not be observed."

"Deafness may be caused by an accumulation of hardened wax; therefore an otherwise desirable recruit should have his ears well cleansed before final action is taken in his case."

"All men enlisted for the artillery arm of the service at a military post or assigned to that arm from a depôt shall, before such enlistment or assignment, besides undergoing the ordinary examination, be examined especially with a view to establishing the fact of the patency of the Eustachian tubes and the integrity of the tympanic membranes, in default of which the men are unfit for that arm."

"In time of war deafness of one ear is not cause for rejection. It should be borne in mind that defects in hearing are easily feigned; therefore, when they are alleged by conscripts, the examination should be made by a medical officer. Genuine deafness cannot be concealed."

2. For admission to the navy. "In the physical examination of recruits for the naval service the ears are examined for

polypi, otorrhea, perforation of the tympanic membranes, and dullness of hearing, and, should one or more of these conditions be found, the candidate is rejected. Polypi of the nose and chronic nasal catarrh are also causes for rejection. The hearing is tested by the voice, and, if necessary, by the ticking of the watch, as in all cases for admission to the Naval Academy, Annapolis, Md."

HYSTERIA OF THE EAR.

The otologist is occasionally consulted in relation to unusual aural manifestations which can only be accounted for as hysterical phenomena. Aural hysteria may occur in hysterical patients in whom there are no evidences of pathological changes in the auditory apparatus. In another class there are indications of pathological changes sufficient to produce tinnitus and loss of hearing, and in a third variety the patients have undergone operations upon the ear and are able to simulate the true symptoms of the disease. A fourth and unusual type of hysteria is found in patients who exhibit self-inflicted injuries in order to excite sympathy and secure gratuities. In all varieties it is evident that psychical influences no less than physical conditions are clearly in evidence.

The most common variety is among patients in whom are found moderate pathological changes in the auditory apparatus, but which are still insufficient to evoke the symptoms complained of. All aural surgeons of large experience are repeatedly importuned to perform mastoid operations upon those who feign mastoiditis.

The diagnosis of aural hysteria is often attended with great difficulty, and in many instances is accomplished only by process of elimination, hence it is incumbent upon the surgeon in the interests of humanity to avoid designating a real sufferer as a hysteric.

Christian Holmes[8] has presented an exhaustive essay upon hysteria of the ear, wherein he advises that all cases of hysteria, whether in a normal or pathological ear, should receive treatment from a neurologist; that no operation should be undertaken merely to satisfy their minds, and that every possible encouragement and psychical influence should be brought to bear upon the patient.

Prognosis.—The prognosis, while not always positively good, is favorable, especially among patients who are tractable, and who are able, by a change in their mode of life, to derive the full benefits of travel, proper exercise and diet.

Autosuggestion, if intelligently employed, is often of great benefit.

---

[8] Transactions of the American Laryngological, Rhinological and Otological Society, 1907, p. 107.

PART II.

The Influence of General Diseases upon the Ear, Nose and Throat.

CHAPTER XXIX.

INTRODUCTION.

A COMPREHENSIVE knowledge of the deleterious effects which general diseases and local organic affections may produce upon the ear, nose and throat is indispensable in determining the diagnosis, prognosis, and treatment of the local manifestations within these organs. It will thus be seen that when such etiological factors as are typified by scarlatina, tuberculosis and syphilis are productive of lesions in the ear, nose and throat, the prognosis must differ widely from that which obtains when the ear lesion is idiopathic.

Local congestions and inflammations involving these organs are often only the effect of some general dyscrasia or pathological condition. Therefore, a just conception of any local abnormal condition in the ear, nose or throat, barring those of idiopathic origin, cannot be attained by merely considering these organs alone.

General diseases are the causation of pathological changes in the ear, nose and throat in one or more of the following ways:—

1. By lowering the general and local vitality of the tissues as a result of the introduction of poisons into the blood, thus increasing the vulnerability of the cells to the point where the ever-present bacteria can begin to thrive.
2. By abnormal deposits (gouty, rheumatic).
3. By venous stasis, which is brought about by cardiac failure of compensation, or some interference with the return circulation.
4. By direct inoculation of pathogenic bacteria or protozoa.
5. By infectious metastasis through the blood lymphatics.
6. By local nerve paralysis, thereby causing interference with the normal physiology of the part. For example—paralysis of the soft palate prevents proper ventilation of the middle ear and thus tends to incite catarrhal otitis media; paralysis of the recurrent laryngeal nerves interferes with phonation and respiration. Paralysis of the nerves of special sense causes loss of these functions.
7. By excessive use and abuse of the organs; pharyngitis resulting from emesis in cases of gastritis, or the excessive coughing of pertussis, etc.
8. By hemorrhage from general diseases, examples of which are found in labyrinthine deafness of hemorrhagic origin, nasal hemorrhage from cirrhosis and purpura hæmorrhagica.

9. By deformities from deep ulcerations. Those in the nasopharynx sometimes interfere with nasal breathing or cause stricture of the Eustachian orifices, with the production of chronic catarrhal otitis media; those in the larynx cause aphonia, dyspnea and dysphagia; those in the middle or internal ear cause tinnitus and deafness.

10. By improper nourishment of the nerves of special sense.

11. Cerebral, instances of which are deafness in uremia and paralysis in apoplexy.

12. Inflammation (posterior poliomyelitis) of the cranial ganglia, said to produce herpetic attacks about the face and auricle.

13. Reflex causes, uterine, puberty, etc.

TUBERCULOSIS OF THE EAR, NOSE AND THROAT.

General Remarks.—Tuberculosis of the ear, nose and throat occurs in two forms: the acute form, or that which complicates general tuberculosis, and the chronic form (lupus), which is a local lesion. Grünwald divides the lesions into the endogenous (the infection reaching the part through the lymph or blood-stream), and exogenous (which is purely local and due to direct inoculation). Lupus is tuberculosis produced by non-virulent, attenuated tubercle bacilli. It is probable that in a majority of cases of lupus the primary lesion is in the mucosa of the upper respiratory tract, notably that of the nasal septum, the lesions of the skin about the face being secondary. The initial lesion is a miliary tubercle modified by the virulence of the infection, the tissue resistance, the depth of the inoculation, and the character of the tissue wherein the process starts. The tubercle here, as elsewhere in the body, consists of clumps of epithelioid cells produced by proliferation of the endothelial and connective-tissue cells, with or without the production of giant cells, and it is usually distributed in the subepithelial region.

The vast majority of tuberculous lesions in the ear, nose and throat, barring the local lesions induced by lupus, are secondary to pulmonary involvement. Notwithstanding the lack of physical signs of tuberculosis in the lungs in many cases, it is usually possible to find the tubercle bacillus in the sputum, and to obtain subsequent confirmatory evidence of the disease. The paths of infection are either by direct inoculation through the bacillus-laden sputum, by means of the respired air, by the ingestion of infected food, by the fingers, by instrumentation, or by the blood or lymph streams.

The tubercle bacillus (Fig. 266) gains access to the lymph spaces through the ducts of the glands or through abrasions. They are found in the lymphatic channels, and the changes commence as cell proliferations around these vessels (Jobson Horne).

This explains the clinical fact that in the larynx the disease shows a predilection to attack the portions which are most abundantly supplied with lymphatics—the arytenoids, the interarytenoid

space and the epiglottis. The bovine type of tubercle bacillus is depicted in Fig. 267.

The proportion of tubercle bacilli varies. When the disease is acute, they are, as a rule, numerous; when chronic, few and difficult to find. The course of the tubercle tends to central caseation and necrosis, with exfoliation of the overlying mucosa as a result of thrombosis of its terminal blood-vessels. In rare instances the tubercle terminates in fibroid encapsulation. Tuberculous complications of the upper respiratory tract are commoner in men than in women. They are more frequent during the decade from 20 to 30 years. The severity of the primary pulmonary lesion has no apparent relation to the local complication.

The prognosis as to life and ultimate health depends, as a rule, upon the condition of the lungs. When the process is advancing

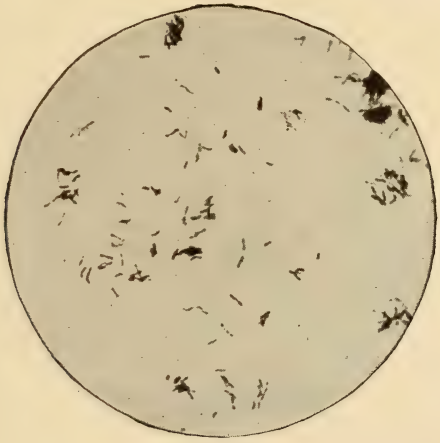

Fig. 266.—Tubercle bacillus. (Human type.)

in the latter, the local lesion progresses whether situated in the ear, the nose or the throat; on the other hand, when the condition is stationary in the lungs, the disease is quiescent elsewhere. Therefore, in all secondary cases the general treatment must aim chiefly to conserve the vital forces and increase nutrition. The essentials of treatment are proper diet, proper air, proper rest and proper environment.

Much effort is put forth at present to determine the value of specific toxin tests in the diagnosis of tuberculosis. Hypodermic injections of various tuberculins, their instillation into the conjunctival sac (Calmette ophthalmic reaction), and the epidermal vaccination as advised by Pirquet are no longer in the experimental stage. The value of some of these toxins (tuberculins) and antitoxins (Maragliano, Marmorek and others) is yet to be determined.

Very little has been accomplished as yet with radium and X-ray therapy in the treatment of tuberculosis. In lupus the X-ray has produced more favorable results.

The determination of the opsonic indices (see Chapter VIII) also promises to be of value in the diagnosis, prognosis and treatment. The deleterious effects of pregnancy upon laryngeal tuberculosis have been repeatedly demonstrated.

TUBERCULOSIS OF THE EAR.

Etiology.—Tuberculosis of the ear occurs in two forms, the acute and the chronic (or lupus).

Primary acute tuberculosis of the ear is rare. It is generally secondary to that of the lungs, and the most common pathway of infection is by the Eustachian tube, either extending by contiguity of the submucous tissues of the tube or, more often, through the lumen; rarely the path is through an existing perforation in the

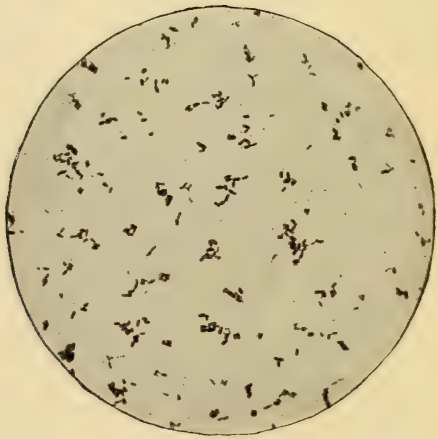

Fig. 267.—Tubercle bacillus. (Bovine type.)

membrana tympani. In miliary tuberculosis the advance is through the blood-vessels.

A bilateral lesion occurs more frequently in tuberculosis than in all other forms of inflammatory conditions of the ear, 32.3 per cent. of bilateral inflammations of the middle ear being tuberculous, according to Bezold.

A. Bordes estimates that 65 per cent. of all discharging ears in children are tuberculous in origin. Fowler subjected 50 patients suffering with purulent otitis media to the Calmette test, the diagnostic value of which is open to considerable doubt. Of that number there were 29 chronic cases with 27 positive reactions. Fifteen were acute with 4 positive reactions and 6 had acute mastoiditis with 2 positive reactions. In children aural tuberculosis may occur in what is apparently fair health and without evidences of tuberculosis elsewhere. In adults the disease usually is secondary.

Symptoms.—The initial symptoms of tuberculous inflamma-

tion of the middle ear differ from those of an ordinary acute purulent process. Often the first symptom noticed is a slight discharge without any pain preceding it. Blake and Buck contend that infiltration and perforation of the posterosuperior quadrant of the drum membrane developing without pain is quite characteristic of middle-ear tuberculosis. Previous to the onset of symptoms the drum membrane appears hyperemic and dotted at one or two points with pearl-gray circumscribed spots. Multiple perforations (Fig. 175) and rapid formation of granulations or the advent of facial paralysis point to a tuberculous origin. Ordinarily, the discharge is the first symptom noticed, and the accompanying perforations enlarge rapidly. A similar rapid necrosis attacks the ossicles and neighboring bony structures. There seems to be almost no reaction of the tissues microscopically to the destroying influence, and tubercle bacilli are rarely found, even in serious cases.

In no other form of otitis media purulenta chronica is complete deafness so liable to occur. In fatal cases among children tuberculous meningitis is the usual cause of death. The discharge from the ear is usually thin and fetid. Bezold describes an exudate from the middle ear found about the promontory, with nearly total destruction of the membrana tympani, in which the tubercle bacilli are present in pure culture.

Pathology.—The primary involvement of the membrana tympani and the soft tissues of the tympanum is followed by necrosis of the promontory, the ossicles, the annular ring, and the attic. The process may extend in all directions even to the mastoid process, facial and carotid canals, and the labyrinth, with destruction of their contents. Intracranial complications are less frequent than in other acute infectious diseases; the necrotic process may progress until the dura or sigmoid sinus is uncovered and thickened, with granulations, and yet gives no symptoms. Tuberculous granulations in the middle ear are pale and usually surrounded by fatty secretion. The perforations in the membrana tympani are large, owing to the tuberculous inflammation, and the mucous membrane of the tympanum is denuded in places, leaving bare exposed necrotic bone. The bony areas are necrotic to all degrees, with exfoliation in spots. Erosion of the internal carotid artery occasionally occurs in tuberculous individuals, and occasionally the entire petrous segment becomes necrosed, separates, and is removed *en masse*.

Diagnosis.—A chronic purulent otitis media, when occurring in a tuberculous individual, is attended with rapid destruction of the membrana tympani, double or multiple perforations, and absence of pain as an initial symptom. Furthermore large exposed areas of denuded bone in the tympanic cavity are strongly suggestive of a tuberculous process. The finding of tubercle bacilli in the discharge, or their demonstration by inoculation of guinea-pigs, renders the diagnosis positive.

Prognosis.—The disease is very rarely cured except in cases

where the general tuberculous process subsides. The fatal issue is usually the result of the disease in the lungs.

Tuberculous meningitis, brain abscess, or sinus-thrombosis are rare but dangerous sequelæ. The prognosis is especially bad in acute cases which rapidly invade the labyrinth and facial nerve, and also where the tubercle bacilli are abundant, except in those rare fibroid cases, mentioned by Bezold, in which, although tubercle bacilli are present in pure culture, the process seems to be very

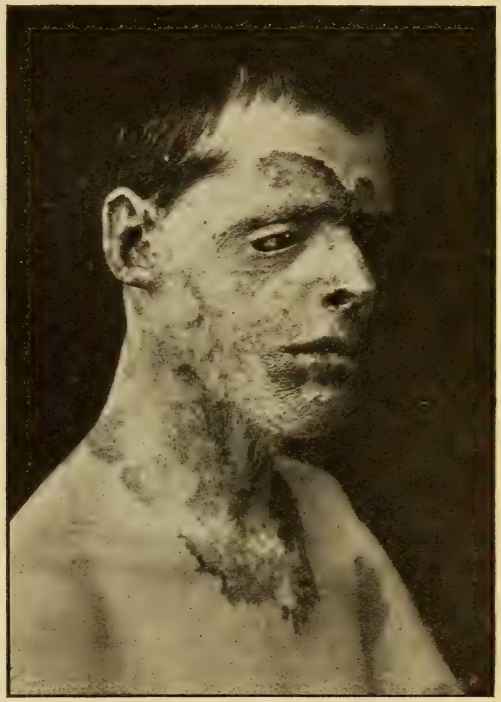

Fig. 268.—Extensive lupus vulgaris of the face, nose, mouth, ears and neck. (From collection of *Dr. John A. Fordyce.*)

mild and amenable to treatment. The prognosis of tuberculous mastoiditis in infants is unfavorable.

Local Treatment.—The external auditory canal and tympanic cavity should be kept clean by frequent douching, and all *débris* and discharge wiped away in order that good drainage may be maintained.

The advent of severe pain with persistent profuse secretion, and the appearance of granulations in the meatus and large areas of denuded bone indicate with great certainty the presence of large sequestra, which should be removed regardless of how far the general disease has progressed. In advanced cases it may not be

possible to remove all diseased tissue, but the curetment should be sufficient to relieve the pain and establish drainage.

The radical mastoid operation provides the only means for eradicating the diseased bone when the aditus, mastoid antrum, and mastoid cells are involved. Whether or not it should be performed depends upon the general condition of the patient. If the disease in the lungs is quiescent and there is no wasting or hectic fever, the operation may be attempted with safety and with considerable hope of a successful outcome. In advanced tuberculosis it is dangerous and, therefore, contraindicated. In the primary form of tuberculous mastoiditis occurring in children the radical operation is feasible and recovery is the rule.

Lupus (Chronic Tuberculosis) of the Auricle.

All forms of lupus vulgaris are found upon the auricle, and almost invariably the disease is associated with extensive lupus of the face (Fig. 268), from which it has extended to the ear. It develops in the form of lupus maculosus, exulcerans, hypertrophicus, and papillaris. The disease here, as elsewhere, is prone to change from one form to another, commencing with small, brownish, scaly tubercles in groups, and gradually changing into those which involve the deep subcutaneous tissue. Ulceration sometimes follows or the tubercles may gradually shrink, and in process of involution they produce cicatrices, which have the appearance of keloid scars, and, while there is destruction of normal tissue, a mass of cicatricial tissue of irregular size and shape is left behind.

Lupus Exulcerans.

The ulcerative form sometimes spreads from the cheek to the auricle, causing ulceration. The ulcers vary in size, are usually located upon the anterior portion of the auricle, and the ulcerating tubercles are covered with thick crusts, while their bases appear spongy and granular. In neglected cases there is more or less destruction of cartilage. The edges of the ulcers are often punched out, and, frequently, typical nodules are scattered in the cutis.

Lupus Hypertrophicus.

This is an obstinate and grave type which generally develops from a neglected ulcerative form. Papillary granulations spring from the bases of the ulcers, which are spongy, bleed easily, and continue to separate at different points, producing marked involvement and destruction of the cartilage, with deformity from the resultant necroses and contraction.

Gradenigo has reported a case where the primary disease in the pharynx extended through the Eustachian tube into the middle and inner ear.

Treatment.—Lupus, wherever located, is an intractable disease. Many dermatologists favor curetment of the skin lesions, combined with the Finsen phototherapy and the X-ray, the latter having many advocates.

Deep-seated lupus of the auricle often necessitates excision of the entire diseased area. The actual cautery is effective in destroying lupus; but, unfortunately, produces an excessive amount of scar tissue. A paste of arsenious acid 20 per cent. in gum acacia is efficacious in some cases. Curetment is always indicated for the removal of ulcers and granulations. Radium is of questionable value, and injections with tuberculin preparations for tuberculosis of the skin have so far been disappointing.

Lupus Erythematosus.

This affection, which is a "chronic non-tuberculous disease of the skin, marked by disc-like patches with raised reddish edges and depressed centres, is covered with scales, which fall off, leaving dull, white cicatrices."[1]

The patches do not ulcerate, no deformity results, and the cicatrices tend to atrophy. It may appear upon the nose, face, ear, and mucous membranes.

Trautman in analysis of 30 cases found involvement of the lips in 43 per cent., the mucous membrane of the cheeks in 40 per cent., the palate in 33 per cent., the tongue, tonsils, gums, the nasal, conjunctival, and laryngeal membranes in a small percentage of cases.

Some authors claim a relationship of lupus erythematosus to lupus hypertrophicus. With this theory the author does not agree, inasmuch as the underlying pathological changes differ so widely.

TUBERCULOSIS OF THE NOSE.

Etiology and Pathology.—The nose is the least liable to acute tuberculous invasion of any portion of the respiratory tract, and its occurrence is seldom of primary origin. The chronic form—lupus—is more common. Tubercle bacilli gain lodgment in the nose in two ways: 1, through the air current, or by direct inoculation; 2, through the blood or lymphatics. The disease occurs in two forms, the acute miliary, which is secondary to pulmonary tuberculosis, and the chronic, which is usually designated as lupus. The acute miliary form is extremely rare and does not invade the bony structures of the nose. The ulceration begins as small granules about the size of a millet seed, separated by areas of healthy mucous membrane, and is located upon the anterior part of the septum or floor of the nose. The ulcers are grayish in color, with edges of irregular outline. Millard and Hajek report having seen cases in this stage, but the ulceration is so rapid that the process is not, as a rule, discerned until the first stage is passed. Tubercle bacilli in large numbers are found in the discharge. The later manifesta-

[1] The American Illustrated Medical Dictionary.

tions are deep ulceration and the edges of the ulcers are undermined and surrounded by an area of miliary tubercles. The disease rapidly spreads to the anterior nasal fossæ, anterior part of the septum, and upper lip.

There is a form of tuberculosis of the nose termed tuberculomata, which has the appearance of hyperplastic growths. They are reddish gray in color, vary in size from a bean to a hickory nut, and are usually located on the inferior turbinated bone. Escat and many others contend that all tuberculous affections of the nose are lupoid in character.

Diagnosis.—The diagnosis is based upon the presence of advanced pulmonary or laryngeal tuberculosis, with all its train of severe constitutional symptoms, and the presence of the characteristic bacilli and ulcers within the nose.

Ballenger[2] reports a case of primary tuberculosis of the nose of long standing, but its nodular appearance and cicatricial borders clearly indicate lupus vulgaris exedens.

Prognosis.—The prognosis is unfavorable, and local treatment is palliative.

Lupus of the Nose.

All known forms of lupus vulgaris occur about the cutaneous and mucous surfaces of the nose, the nodular, hypertrophic, exedens, papillaris and maculosus (Fig. 268). The character and extent of the disease is dependent upon the form, stage, and severity which the lupus has assumed.

The disease is described by Caboche under four headings: (*a*) *nodular,* (*b*) *vegetating,* (*c*) *tumor,* and (*d*) *ulcerating.*

(*a*) *Nodular.*—This form is characterized by nodules which are two or three times the size of a pinhead. The surfaces are roughened and are pale rose-colored, and the individual nodules are separated by small, irregular grooves. Sometimes the latter become ulcerated, causing cicatricial, nipple-like lobules.

The nodular type usually originates in the mucosa of the anterior part of the nasal fossæ.

(*b*) *Vegetating.*—In the vegetating variety, also called lupus hypertrophicus, there is extensive hyperplasia of a pale-rose or bluish-lilac color. There is usually a formation of crusts upon the vegetations, which are separated by little grooves. The vegetations feel soft to a probe or curet.

(*c*) *Tumor.*—The appearance of the nasal mucosa in the tumor variety is that of pedunculated or sessile tumors, which may fill the entire nasal cavity. These wart-like growths are pale bluish white with a red tinge. On superficial examination the gross appearance is smooth, but actually the surface is covered with elevations about the size of a millet seed. The lupus tumor is elastic, bleeds little or not at all on probing, and usually is accompanied by some other manifestations of lupus.

---

[2] Diseases of the Nose, Throat and Ear.

(*d*) *Ulcerating.*—Ulceration may occur in any type of the disease and at any stage of the process. The borders of the ulceration are irregular and cicatrized areas are present in advanced cases. The base is granular, sometimes necrotic, and is surrounded by a zone of lupus nodules.

Etiology of Lupus.—The disease is due to the invasions of the tubercle bacillus, but its slow development, tendency to heal, cicatrize and recur, and its purely local character serve to differ-

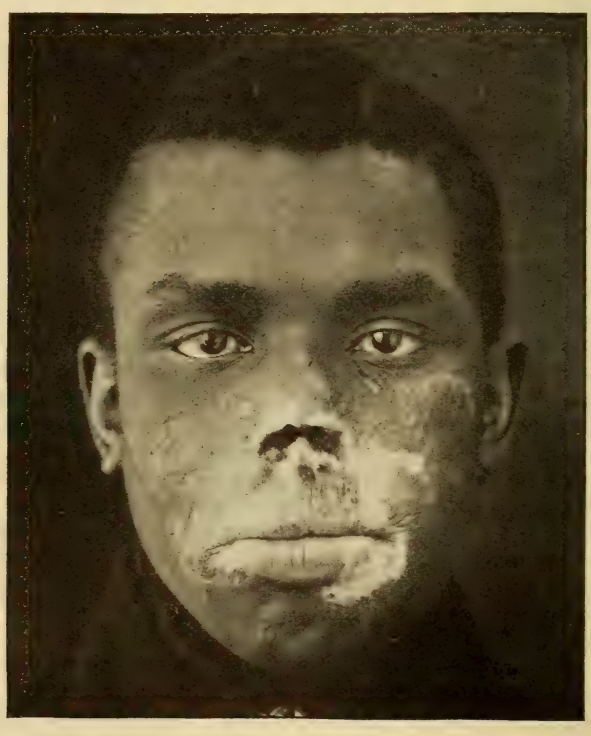

Fig. 269.—Lupus vulgaris. The anterior portion of the septal cartilage and the alæ nasi are partially destroyed. Absence of pigment is due in great measure to X-ray applications. (From collection of *Dr. John A. Fordyce.*)

entiate it from virulent ulcerative tuberculosis. The disease is more common in females than in males (75 per cent., according to Caboche), and it occurs during middle life from about 20 to 50 years.

Pathology.—The mucous membrane over the septal cartilage, the floor of the nose and the anterior part of the inferior turbinal are most frequently involved. The cartilage itself becomes involved later, but the bone never. The septal cartilage is easily perforated if the lupus nodules occur on both sides. In 200 cases seen by Mygind perforation occurred in 29 per cent. The perfora-

tion is rounded and regular and of varying size. The septal perforation alone rarely causes deformity of the nose. The anterior limit of the septal perforations is at the junction of the septal mucous membrane and the skin. The border of the perforation is commonly fungoid and soft, bleeds easily and is considerably thickened. Part of the edge may be thin and healed, while the remainder is thickened and ulcerated. Stenotic deformities may follow in the healing. There may be various degrees of fibrous tissue formation, the process breaking down in one place and healing in another. This fibrosis may cause atrophy of the inferior turbinal. In severe and neglected cases the septal cartilage and alæ nasi may be destroyed (Fig. 269), producing a terrible death's-head appearance. The accompanying lymphangitis gives a red and swollen aspect to the end of the nose.

The disease tends to extend outward upon the cutaneous surfaces, where it pursues a slow and insidious course and with typical symptoms (Figs. 269 and 284).

Symptoms.—In lupus there may be no symptoms for years, perhaps some lachrymation or a rebellious dermatitis of the vestibule, or a torpid and recurring lymphangitis of the alæ and tip of the nose may be all that is noticed. As the disease progresses obstructive symptoms supervene, with mucopurulent discharge. The ulcerative stage is characterized by a thicker purulent secretion with an occasional admixture of blood. Occasionally the spreading of the process to the pharynx or larynx will produce symptoms which result in an examination of the nose and the discovery of the initial process there.

The cutaneous symptoms are lymphangitis and the appearance of groups of nodules, which may coalesce or ulcerate with resultant cicatrices. There are periods of active progress of the disease which are followed by healing with keloid-appearing scars. Recurrences are the rule and always with some extension into new tissue. Deformity is marked whenever the alæ have been partially or wholly destroyed.

Diagnosis.—Recurring lobular lymphangitis, persistent unilateral dermatitis about the vestibule, and epiphora should direct attention to the parts of election for lupus in the nasal mucosa. Chronic rhinitis sometimes gives a mammillated appearance to the nasal mucosa, but the surfaces are smooth, bluish and without ulcerations. An advanced syphiloma should not be mistaken for lupus. Its rapid progress, smooth appearance, early breaking down into one or two ulcers and its involvement of bone are all quite the opposite of lupus. In recent syphilitic perforations of the septum denuded bone can nearly always be detected with the probe; in lupus never, except when bone has been exposed by cauterizing agents. In lupus the lesion never exists without similar lesions in the neighboring mucosa.

Finally, in doubtful cases resort may be had to the Wassermann test, antisyphilitic medication, microscopic examination or to inoculation in order to ascertain the nature of the suspected lesion.

Prognosis.—Lupus is amenable to treatment, and while recurrence is probable the treatment materially retards its progress. Spontaneous recovery is possible. Sometimes lupus extends to the larynx and lungs and causes death from pulmonary tuberculosis. The slowness of the process allows hope of eradication, but complications may set in even in the apparently cured cases, with rapid ending. The disease tends to extend in all directions, involving at times the skin, frequently the lachrymal duct, either as a simple or specific inflammation. It seldom involves the nasal sinuses.

Treatment.—No form of treatment will cure all cases and recurrences are common. In a communication from John A. Fordyce he states: "The chief advance in our treatment of tuberculosis (lupus) in recent years is the Finsen and Roentgen-ray treatment. Lupus of the anterior nares, in a large percentage of cases, involves the mucous membrane and is influenced in a degree by X-rays applied within the nostril. Lately I have had a modification of the Cornell tube made which enables me to apply the rays for some distance inside the nostrils. This can be done with greater ease where there has been destruction of the alæ. Where the lesion is beyond the influence of X-rays we have nothing better than destruction of the tissue with the galvanic cautery, the dental burr of Fox, the curet or the usual chemical caustics."

After removal by surgical methods the surfaces may be treated locally by applications of the following formula:—

℞ Iodin	1 part.
Potassium iodid	2 parts.
Distilled water	2 parts.

The X-ray yields brilliant results in some cases and fails utterly in others.

Hollander advises the employment of nascent iodid of mercury as follows:—

Fifteen minutes before treatment two drams of a 5 per cent. potassium iodid solution is taken. Then an application of powdered calomel is made to the lesion. The iodin eliminated from the mucosa combines with the calomel and gives rise to nascent iodid of mercury, which has a most energetic action.

In the vegetating form Caboche advises the application of tampons containing 80 per cent. lactic acid for twenty-five to thirty minutes. In the still more extensive and vegetating forms he curets, under chloroform anesthesia, and then applies 75 per cent. lactic acid tamponings three times a week. He claims that the mammillated infiltration disappears rapidly, leaving a regular mucosa, smooth and normal.

TUBERCULOSIS OF THE ACCESSORY SINUSES.

In postmortems on tuberculous patients the sinuses have been found involved in from 20 to 50 per cent. of cases. In the living, however, positive symptoms of tuberculous sinus disease are rarely found. Primary tuberculosis of the antrum of Highmore has been

reported in only a few instances, but the process is generally secondary and in rare instances it may begin in the bone instead of the mucous membrane.

The treatment is the same as in the chronic suppurative cases, but must be more radical, and the results are less favorable.

TUBERCULOSIS OF THE MOUTH AND PHARYNX.

Tuberculosis of the mouth and pharynx is a rare affection, but during recent years there has been a tendency to carefully differentiate the lesions of these organs and the microscope has been a valuable aid.

The result has shown a vast increase in the reports of cases and is suggestive that the affection is more common than had previously been supposed.

In the mouth tuberculosis attacks the lips, cheeks, gums (Fig. 270), hard palate, soft palate (Fig. 271), tongue (Fig. 272), teeth and alveolar process. In the pharynx the disease attacks the tonsils (Fig. 273), soft palate, faucial pillars and posterior pharyngeal wall (Fig. 271). The lesions rarely occur singly and are probably secondary to that of the larynx and lungs in the majority of cases, primary development being rare.

According to Levy, the classifications are two in number, the benign and malignant, or, according to Grünwald, the endogenous and the exogenous. Levy contends that "the exogenous or ascending form, that which may be designated as the inoculation variety or purely local, represents the less active, sluggish or benign type, while the endogenous or descending variety, that which represents infection through blood and lymph streams, through miliary deposits or infection from within, corresponds to the more active, virulent, malignant type."

Etiology.—The disease is more common in males, and in rare cases the only demonstrable lesion is in the mouth or pharynx, thus furnishing some tangible evidence that local irritation and membranous abrasions are causative factors. But Angay's[3] contention that the most frequent mode of infection is through the blood-current, while probably borne out by clinical experience, the lymph-current furnishes almost or quite as convenient a pathway for the transmission of infection. On the lips it occurs in the form of ulcer. On the tongue it starts as a small granule upon the dorsum or at the border. This in turn ulcerates and the resultant ulcers are surrounded by irregular edges and covered by caseous spots. The cervical glands near the angle of the jaw are seldom affected and the salivary glands are almost immune from tuberculosis, only a few cases having been reported.

The disease is characterized by miliary tubercles and is associated with the miliary form of tuberculosis of the lungs. The affection is more common in the tonsils than in other areas of the

---

[3] International Centralblatt für Laryngologie, 1896, p. 212.

mouth and pharynx. Wood (1904) contends that "the tonsillar tissue of the throat, because of its peculiar anatomical construction and its topographic relations, is more liable to become infected by tuberculosis than any other part of the upper respiratory tract." A. Latham found by inoculation that 7 out of 45 consecutive cases of hypertrophy of the tonsils in children, ages ranging from three months to fifteen years, were tuberculous. Ordinary enlarged tonsils and adenoids rarely contain tuberculous nodules (Bezold). The tonsils are affected in nearly all cases of advanced pulmonary tuberculosis, and 5 per cent. of all cases of hypertrophy of the pharyngeal tonsil are tuberculous (G. B. Wood). Others have from time to time reported undoubted cases of primary tuberculosis of the tonsils. Secondary tuberculosis of the tonsils generally assumes the form of ulceration. With chronic cervical adenitis, if tuberculosis is suspected, attention should be directed to the lymphoid ring.

Infiltration of the faucial tonsil with miliary tubercles cannot be positively determined except by the microscope or by inoculation.

Pathology.—The miliary tubercles develop in the submucous tissue. The margins of the ulcerations are irregular and at first small and discrete, separated by infiltrated tissues. These break down and produce a mouse-nibbled appearance. There is no surrounding zone of congestion and inflammation as seen in other ulcers. The surrounding mucosa is pale and anemic. The ulcers are not so punched out as in syphilis, and are bathed in a small amount of mucopus. Cervical adenitis is generally present. The ulcers tend to spread laterally and not deeply. The base of the ulcers is covered with a dirty-white secretion, and on cleansing are more or less nodular. Scattered over the ulcerated surface and on its margins may be found small, red granulations, interspersed with yellow or grayish pinhead spots (Trelot).

Jonathan Wright has divided the tuberculous lesions of the tonsils into three forms: 1. Irregular, shallow erosions of the epithelium of the crypts, with no previous formation of tubercles, no caseous metamorphosis, no giant cells. The floor of the ulcer is formed by infiltrated lymphoid tissue. Tubercle bacilli in great numbers are also found in the contents of the crypts, which are yellowish white and contain thick matter with no odor. Cervical adenitis is a late symptom.

2. Typical tubercles, with giant cells and caseous degeneration. The ulcers are deeper than in the first variety.

3. Diffuse tuberculous infiltration where the tonsil loses most of its normal tissue and is surrounded by a fibrous capsule covered with mucosa.

In tuberculosis of the pharyngeal tonsil tubercle bacilli are few and giant cells common. The lingual tonsil is occasionally affected.

Symptoms.—Tuberculosis of the mouth and fauces may exist for months without producing troublesome symptoms. In the miliary form the general symptoms usually overshadow those in

Fig. 270.—Tuberculous ulceration of the gums. (From "Tuberculosis of the Mouth." *Robert Levy,* with permission.)

Fig. 271.—Tuberculous ulceration of the hard palate, soft palate, uvula and posterior wall of the pharynx. (From "Tuberculosis of the Mouth." *Robert Levy,* with permission.)

Fig. 272.—Tuberculous ulceration of the tongue. (From a patient of *Dr. J. C. Sharp,* with permission.)

Fig. 273.—Tuberculous ulceration of the tonsils. (From "Tuberculosis of the Mouth." *Robert Levy,* with permission.)

the pharynx. Discrete ulcers may occur in severe types when accompanied by general infection. Pain is never marked during the early stages and its advent is in the form of burning sensations during deglutition. During the later stages pain becomes severe. When the ulcers are on the posterior pharyngeal wall or in the tonsils (Figs. 271 and 273) the pain radiates to the ears. There is considerable localized infiltration about the ulcers and considerable secretion of grayish, viscid mucus. The advent of tissue necrosis is marked by odor. Emaciation develops rapidly on account of insufficient nourishment and the ravages of the disease. There is reflex cough, hectic temperature, and when the soft palate is involved liquids pass into the nose and nasopharynx. The mucopus is allowed to accumulate on account of the pain, and efforts to clear the throat are accompanied by a gurgling, rattling sound, which is also heard during respiration.

Upon examination in the acute miliary form there is at first a studding with grayish, translucent spots, varying in size from a small pinhead to a millet seed. These project above the mucous membrane, which is very anemic. There is generally considerable edema of the soft palate and uvula, sometimes occurring in small defined areas scattered uniformly, which in appearance are not unlike sudamina on the skin. In a few days they ulcerate and gradually coalesce. Thick, tenacious mucopus exudes from the ulcers. Tubercle bacilli are very few, and are more often found in the marginal scrapings. Sometimes, in indolent cases, excessive granulation tissue forms, hiding the ulcer. In this form marked enlargement of the cervical lymph glands occurs.

Diagnosis.—Tuberculous ulcerations are of superficial, pale, worm-eaten aspect, with yellowish spots and minute elevations scattered over the surface, and without inflammatory borders, and the diagnosis is confirmed by detection of the tubercle bacillus under the microscope, by outlining the typical tubercle structures in stained secretions, and by inoculation of guinea-pigs. General tuberculosis is usually present.

Differential Diagnosis.—The disease should be differentiated from syphilis, diphtheria and lupus. The tuberculous ulcer is seldom primary and is more painful than the syphilitic. The outlines are more irregular, the margins less elevated and congested, and there is less excavation. It does not respond to specific treatment. Mixed cases are said to occur. When in doubt a microscopic examination of a section or inoculation is indicated.

In diphtheria there is a pinkish membrane, which is removed with difficulty, leaving a bleeding surface. There is no membrane formation in tuberculosis, and the secretion is readily sponged off. The margins of a diphtheritic ulcer are deeply inflamed, while the margins are pale in tuberculosis. The Klebs-Loeffler bacillus instead of the tubercle bacillus is found in diphtheria. Diphtheritic ulcer disappears in a few days; tuberculous ulcer gradually extends.

In lupus the development is slow, while in acute tuberculosis there is a more rapid ulcerative process. There is no temperature

in lupus, and no pain. There are nodular deposits near the ulcerated areas in lupus; none in acute tuberculosis. Cicatrices over healed areas are found in lupus; rarely in tuberculosis.

Prognosis.—A very few cases of acute tuberculosis of the mouth and pharynx have been reported healed. The great majority succumb in from a few days to a few weeks.

Treatment.—The treatment is mainly palliative, although curative measures, both local and general, are indicated. Palliative measures are chiefly efficacious for the relief of pain. The ulcers should be kept clean by alkaline sprays and various dusting powders applied. These tend to retard the activity of the disease and allay the pain. Powdered orthoform is valuable for the relief of pain. Mild astringents, such as sprays of sulphate or chlorid of zinc, 4 grains to the ounce, may be employed. Sprays of menthol, 3 per cent., cocaine, 5 per cent., are helpful measures for the relief of pain. Morphine powder, gr. ⅛, in starch, gr. iij, may be dusted over the surface of the ulcers. If the condition warrants, discrete ulcers may be curetted with a sharp curet and the base touched with lactic acid, repeating the latter applications every four days. Meanwhile the ulcers should be cleansed several times a day with alkaline washes. Occasionally a cure of the ulcer is thus effected, but the patient generally succumbs to the process in the lungs.

On the principle that much of the pain is due to the development of neuromata on the exposed nerve filaments it is often justifiable to use the above-named surgical measures even in hopeless cases. To relieve the pain during deglutition it is recommended that a spray of cocaine, 2 per cent., or a small ¼ grain pellet of cocaine be dissolved in the mouth a half hour before meals. Semi-solids are advised for diet since they are better tolerated.

Lupus of the Mouth and Pharynx.

Lupus of the mouth and pharynx is nearly always secondary to lupus of the nose or skin and manifests the same tendency to ulcerate, heal, cicatrize and recur. The tubercles coalesce or bunch together into nodules and ulcerate mildly and slowly without much secretion. Nodules occur in various stages, some healed, some ulcerating, some not broken down. Tubercle bacilli are very sparsely found in the nodules.

Symptoms.—Stiffness of the part involved, which interferes with its function, is a prominent symptom. Deglutition is somewhat impaired and there is a tendency for liquid food to regurgitate through the nose, and for the voice to acquire a nasal twang. The parts are more apt to be anesthetic than hyperesthetic. Complicating cervical adenitis is common.

Diagnosis.—The diagnosis is based upon the slow development, nodular formation, cicatricial borders, slight ulcerations, and slight discharge. The disease is painless, does not respond to iodids, and is readily differentiated from acute tuberculosis and malignant disease by the characteristic general and local symptoms and gross appearance.

Treatment.—The treatment in the main is the same as that of lupus of the nasal mucosa. Mild cases of lupus of the palate are benefited by applications of equal parts of resorcin, balsam of Peru and mucilage. Fordyce injected tuberculin (B. E.) from $\frac{1}{1000}$ of a milligram to 1 milligram, after a modification of Wright's method, with marked improvement, but the improvement was not permanent and recurrence took place.

TUBERCULOSIS OF THE LARYNX.

This affection is variously described as consumption of the throat, laryngeal phthisis, and tuberculosis of the larynx. It is characterized by glandular and connective-tissue infiltration and ulceration.

Etiology and Pathology.—Among laryngologists the belief is general that laryngeal tuberculosis is almost invariably a secondary affection, and this view is strongly supported by postmortem findings. Three cases of primary tuberculosis of the larynx have been authenticated by autopsy, thus showing the rare exceptions to the rule.

It occurs at all ages, but most frequently between twenty and thirty. It is very rare in children. In fatal cases of pulmonary tuberculosis the larynx is involved in about one quarter of all cases. Schroetter, of Vienna, found the larynx involved in only 6 per cent.; Heinze, of Leipzig, in 5 per cent., and Osler in 18 to 30 per cent. Parker states that 80 per cent. of larynxes are abnormal in phthisis, 50 per cent. being non-tuberculous lesions due to irritation of the cough and sputum, and 30 per cent. to true tubercle involvement. Kidd states that in 50 per cent. of the fatal phthisis cases there is some tuberculous lesion in the larynx, and clinically he observed it in 20 to 25 per cent. of cases. Laryngeal tuberculosis is more common in men than in women, about 2½ to 1, and it is very rare under ten years of age. Lake reports two cases of laryngeal infection from tuberculosis of the ear.

The laryngeal invasion may occur very early in the history of lung involvement, and be unilateral or bilateral. The point of entrance is said to be through the gland ducts in the ventricles (Wood), but the path of infection may be by direct inoculation, and also through the blood-stream. Simple lesions of the larynx are extremely common in phthisis due to coughing, which produces congestion. These abnormalities consist in anemic areas, chronic laryngitis, and abrasions, and they are due to irritation of the sputum or to the strain of coughing. Congested vessels are often seen coursing over anemic areas in the epiglottis, ventricular bands, and arytenoids, the rest of the mucous membrane being normal. Hyperemia of the vocal cords is common, even though the surrounding mucosa is anemic. The disease appears to start in the lymphatics within the larynx. The arytenoid and interarytenoid spaces are generously supplied with lymphatics, and hence are most frequently involved. Ulceration occurs early where the parts are sub-

ject to attrition, such as the cords or vocal process, not so on the arytenoids or aryepiglottic folds. On the other hand, Osler contends that in laryngeal tuberculosis the primary lesion is in the neighborhood of the blood-vessels. The tuberculous deposits may be uniformly distributed over a considerable area and be massed into tumor formations. The ulcerations are usually superficial and irregular in outline, the margins are neither elevated nor surrounded by a zone of hyperemia, and tissue necrosis is rapid. Edema of the aryepiglottic folds is frequently observed. Ulceration of the epiglottic folds, the epiglottis, vocal cords, posterior laryngeal wall, the interarytenoid region, and the ventricular bands marks the progress of the disease. Necrosis of the cartilages of the larynx is common. Dumond reports a case of acute cricoarytenoid arthritis in a case of tuberculous laryngitis, which caused a fixation of the cords in the median line, with much dyspnea.

In miliary tuberculosis of the larynx the mucosa becomes dotted with small, roundish, yellow, millet-seed nodules, scattered or in



Fig. 274.—Tuberculous infiltration of the epiglottis.

groups, accompanied by general edema. There is a tendency for them to rapidly coalesce, soften and ulcerate.

Subglottic edema is a serious, but rare complication. Limited infiltration, with or without superficial ulceration, and generally unilateral, occurs on the cords or ventricular bands. Infiltration about the arytenoids, aryepiglottic folds, or the epiglottis is prone to occur and the epiglottis may become so swollen as to be turban-shaped (Fig. 274). There is but little lymphatic gland involvement so long as the disease remains intrinsic.

In the arytenoid region perineuritis of the recurrent nerves may occur.

Symptoms.—In cases which have advanced to the ulcerative stage the symptoms are characteristic and the diagnosis is not difficult. By this time the general infection has produced emaciation, dyspnea, and pallor. The following are among the prominent symptoms of tuberculous laryngitis:—

Changes in the Voice.—The initial symptoms of laryngeal infection are hoarseness and changeable voice and a prickling sensation which induces cough during phonation. As the disease progresses the voice becomes more hoarse and changeable, being one day clear and the next hoarse. Extensive infiltration and ulceration cause complete aphonia.

Dyspnea.—There is seldom laryngeal dyspnea unless the tume-

faction is very extensive. The cough is more often due to lung involvement than to laryngeal lesion, except when extensive ulceration is present.

Dysphagia.—Whenever the epiglottis or the aryepiglottic folds are ulcerated, dysphagia becomes a distressing symptom. Dysphagia is evoked either by the contact of food passing over the ulcerated surfaces or by the movement of the larynx while coughing or speaking. Patients often refuse food for long periods on account of the dread of pain during deglutition. Deglutition is not painful so long as the ulceration is entirely intrinsic.

Cough and Expectoration.—During the ulcerative stage of tuberculous laryngitis there is increased mucopurulent secretion which may be streaked with blood. Cough is constant and painful. When the lungs are extensively diseased there is free expectoration.

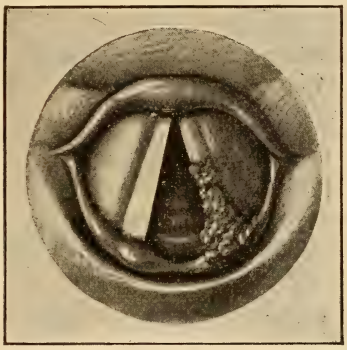

Fig. 275.—Tuberculous ulceration of the vocal cords.

The Clinical Picture.—Upon examination of the larynx the mucous membrane appears pale, with small areas of congestion. During the early stage there is but little secretion, but when ulcerations are present they are constantly bathed in mucopurulent secretion. Pale, pear-shaped swellings in the neighborhood of the aryepiglottic folds, which obliterate the outlines of the cartilage of Wrisburg, are characteristic of the early stage of tuberculosis of the larynx.

Small tubercles underneath the mucous membrane appear as small, grayish elevations the size of a pinhead. They are frequently seen on the epiglottis, aryepiglottic folds and ventricular bands. Tumor formations are common in the interarytenoid space and present a sessile, pedunculated or wart-like appearance. Any degree of arytenoid thickening, when complicating pulmonary tuberculosis, is pathognomonic of laryngeal tuberculosis.

Tuberculous ulceration of the larynx is usually accompanied by edema of the aryepiglottic folds. In epiglottic involvement the accompanying edema causes it to be thickened, swollen, pale and turban-shaped, so that it obstructs the view of the interior of the larynx (Fig. 274). Ulcers on the ventricular bands are irregular in

outline, covered with a thin, gray or yellowish exudate, and the edema of the aryepiglottic fold is, as a rule, more marked on the side of the ulcer. Ulcers on the vocal cords (Fig. 275) are irregular and often serrated in appearance. On phonation it is frequently seen that the cords do not approximate and that quite a space intervenes. There may be irregular action of the cords, with impaired mobility.

Diagnosis.—The diagnosis is not difficult except during the early stage in patients with incipient or central pulmonary lesions. The positive diagnostic symptoms are: 1, history of tuberculosis; 2, the presence of tubercle bacilli in the secretion; 3, the characteristic appearance of the larynx. The disease must be differentiated from syphilis, chronic laryngeal pachydermia, lupus, papillomata, and malignant growths.

In chronic laryngitis and pachydermia laryngis (Chapter XLIX) there is no ulceration and both progress slowly, while tuberculous laryngitis is characterized by pallor of the mucosa and ulceration, and edema and loss of voice are common.

In syphilis the process is usually more rapid, the ulcerations excavate deeper, the margins are more elevated and inflamed, and there is a greater amount of local secretion. When the tuberculous infiltration simulates syphilis the diagnosis may only be arrived at after medication with iodid of potassium.

In lupus the nodule formation and slight superficial ulceration and cicatrization occurring in different parts of the larynx differentiate it from tuberculous ulceration, in which cicatrization is uncommon. The nose, pharynx, mouth, and face are also invariably involved in lupus.

Papillomata are localized warty or cauliflower-like tumors, and are never accompanied by the peculiar pear-shaped swellings of the arytenoids or the ulceration, which are characteristic of tuberculous laryngitis. But in tuberculous subjects the majority of the growths occurring in the larynx are tuberculous.

Malignant growths have a distinct tumor-like dark-red appearance and the mucous membrane in the non-involved portion is always congested. Malignancy rarely occurs before the forty-fifth year, the pain is severe even before ulceration, and frequently radiates to the ears. There is early involvement of the laryngeal nerves and vessels, causing interference with the movements of the cords, and stenosis is common. An excised portion, examined microscopically, should clear the diagnosis.

Cases of mixed infection occurring with a history of syphilis are sometimes extremely difficult to differentiate. These occur as hyperplastic growths, originating near the arytenoids or from the ventricle of Morgagni. They are pedunculated or sessile. Many times they do not seem to respond to antisyphilitic treatment and run a rapid course.

Prognosis. — Acute pulmonary tuberculosis with laryngeal ulceration is a grave disease and nearly always fatal. Such patients seldom live more than a few weeks. Where the primary lesion is slow and confined to the apices, and the connective-tissue formation

is more rapid than the cell proliferation, the disease may be arrested and occasionally cured. In rare cases where the laryngeal tissue is deeply congested and miliary tubercles are scattered through this area, ulceration rapidly ensues and the patient succumbs in a few weeks. In the tuberculous tumor cases the tendency to ulceration may be so slight that if the lungs improve there may be no ulceration for years, and under favorable general and local treatment recovery may ensue. Should the tumor ulcerate, active surgical intervention may induce healing, providing the general health permits. Extensive ulceration of the larynx presages a rapidly fatal issue and operative interference is both useless and harmful. Tuberculous lesions of the larynx are usually in the same stage as those in the lungs with a like prognosis.

Treatment.—A warm, equable, not too dry climate is favored for patients suffering from tuberculous laryngitis. The colder climates of the Adirondacks or of Colorado are not so good in winter. In southern California there are a few places, such as the Ojai Valley and Pasadena, that are ideal for this condition. The Riviera, Egypt and the Pine Belt of South Carolina are less healthful.

The contraindications to removal to a different climate are rapid loss of flesh, diarrhea, dysphagia, persistent hemoptysis and dyspnea.

Expert local treatment is invariably required; it, therefore, becomes imperative for the patient to sojourn where this can be secured.

Prophylaxis.—The larynx in all cases of phthisis should be closely watched. If local areas of anemia or hyperemia become apparent, steam inhalations, nebulization, sprays or intralaryngeal injections are advantageous, employing such medicaments as creosote, oleum pinus sylvestris, compound tincture of benzoin, menthol and oleum eucalypti.

Chronic laryngitis and other non-tuberculous lesions of the larynx when complicating pulmonary tuberculosis should be treated according to the principles outlined in Chapter XLIX, inasmuch as they furnish a ripe field for infection by the sputum. If slight abrasions or superficial ulcers accompany tuberculous laryngitis, they may be treated by applying a 50 per cent. solution of lactic acid every three or four days and by soothing, emollient sprays or vapors several times daily.

Opinions differ widely upon the question of intralaryngeal surgery for the relief of tuberculosis of the larynx. Krause and Herzog, who were the pioneers in this field of surgery, claimed many cures (1886) from curetment and applications of lactic acid.

Their views have received indorsement from many observers who have employed their methods with apparent prolongation of life and occasional cures.

Opposed to the curetment method are Schrötter, Stoerck and others, who contend that the wound which is made by curetment of the laryngeal ulcers is extremely liable to reinfection from the

secretions; that the improvement is only temporary; that dysphagia is increased, and that the pulmonary disease and general wasting are thereby increased.

Favorable cases for operation are those of localized infiltration with slight ulcerations in individuals who are comparatively

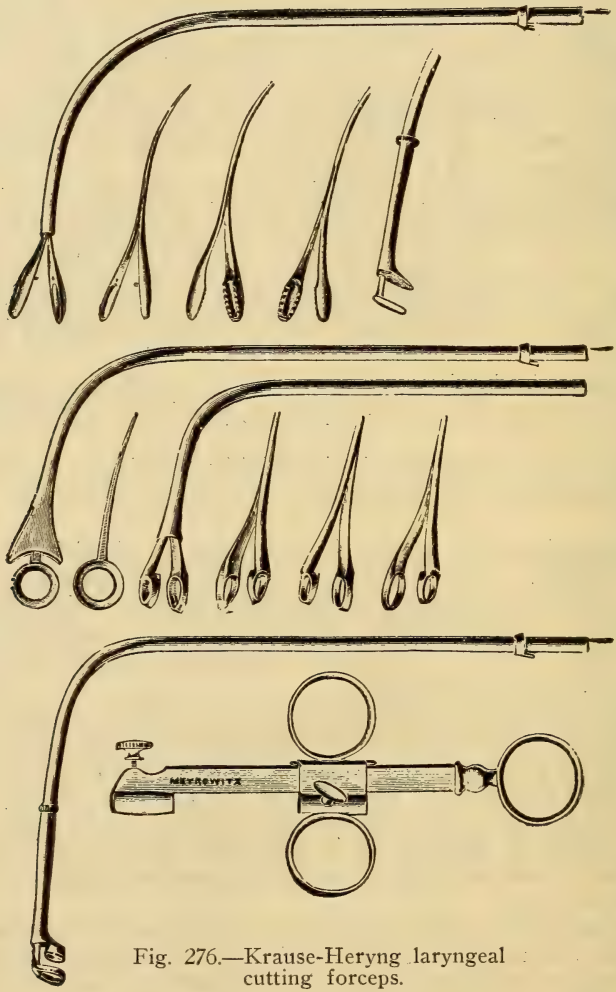

Fig. 276.—Krause-Heryng laryngeal cutting forceps.

strong and in whom none of the ravages of the general disease are apparent.

Moderate tuberculous infiltrations of slow growth do best when let alone, trusting to climatic and general measures for cure. In incipient cases, in favorable climates, under the watchful care of competent laryngologists, the tumors may gradually disappear or

remain stationary for years. Local applications are indicated as soon as there is any evidence of ulceration and necrosis. If dyspnea is caused by the growth surgical procedure should not be long delayed. Gallagher, Levy, Lockard, Johnson and others claim curative results from formaldehyd applied locally. Gallagher has especially emphasized the technique of its administration as follows:—

Procedure:—

1. Slight cocaine anesthesia.
2. Cleanse, and spray with 1 to 3 per cent. formaldehyd solution.
3. Local applications of 5 to 10 per cent. formaldehyd solution.
4. ℞ Orthoform, 7 parts } insufflation.
   Aristol, 1 part }
5. Deep intratracheal injection of:—

℞ Menthol ..... gr. x.
Ol. eucalypti..... fʒj.
Ol. cinnamomi..... ♏j.
Glycerol .....q. s. ad f℥j.

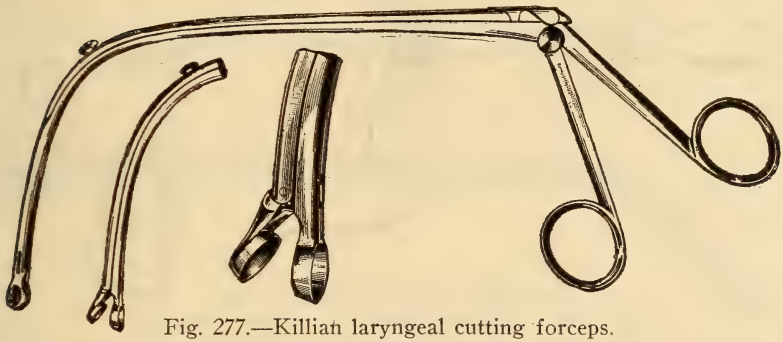

Fig. 277.—Killian laryngeal cutting forceps.

Surgical treatment is contraindicated whenever it is impossible to remove the diseased parts, in actively progressing or extensive disease in the lungs with rapid wasting, when hemoptysis is frequent and in cases of nervous instability, feebleness and old age.

In the acute miliary form the treatment should be palliative only, as the disease is rapidly fatal. Extensive cutting operations require profound cocaine anesthesia. A 20 per cent. solution of cocaine applied locally to the tissues, at intervals of five minutes, for a period of thirty minutes, usually is sufficient. Growths and necrotic areas may then be removed with cutting forceps. For this purpose the Krause-Heryng (Fig. 276) or Killian (Fig. 277) cutting forceps is employed.

It is important to limit curettage to the necrosed and ulcerated areas. After removal of the growth the denuded area is dried and then touched with lactic acid solution, 10 to 50 per cent., or pure nitric acid. Rapid healing must be promoted or reinfection will occur. For some days subsequent to operation the patient should avoid speaking, and coughing should be controlled by the adminis-

tration of codeine, heroin, etc. Laryngeal hemorrhage may be controlled by adrenalin sprays or applications of equal parts of lactic acid and liquor ferri chloridi (Heymann).

Lake uses a combination of lactic acid, 50 per cent.; formalin, 7 per cent.; carbolic acid, 10 per cent., for applying to ulcerations in the larynx. He advises daily applications of the above, the carbolic acid acting as a local anesthetic and relieving some of the after-smarting.

Dry inhalations from a mask placed over the nose and mouth and worn for thirty minutes, as often as needed, are useful as palliative measures. Parker suggests the following: Creosote,

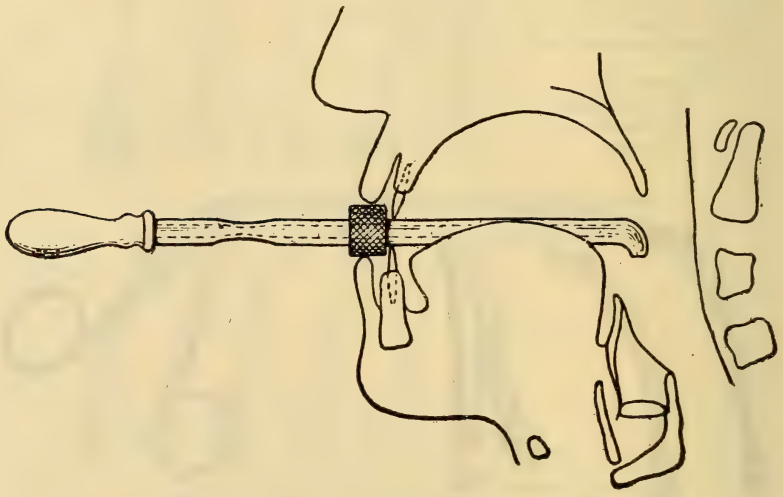

Fig. 278.—Yankauer laryngeal medicine dropper.

80 minims to the ounce of alcohol; oleum pini sylvestris, 40 minims to the ounce of alcohol; oleum eucalypti, 80 minims to the ounce; menthol, 80 minims to the ounce. A half dram to be poured on the mask.

Dysphagia.—If eating semisolids causes pain and violent cough they may be sucked through a glass tube with the head hanging over the edge of the bed, thus preventing the food from entering the larynx (Wolfenden), and rectal alimentation may become necessary as a last resort.

Spraying the larynx with a solution of cocaine 2 per cent. ten minutes before eating, or applying the same with cotton carrier offers relief. Insufflations of powdered orthoform are also effective in controlling pain.

Amputation of the epiglottis is sometimes successful in easing the dysphagia when the ulceration involves the epiglottis.

Yankauer has devised a long medicine dropper for dropping oily medications into the larynx (Fig. 278). The bent tip is adjusted to reach just beyond the uvula.

Leduc used an autoinsufflator (Fig. 279) which can be employed by the patient providing the physician cannot be seen daily. The short end is introduced nearly to the posterior wall of the pharynx, the lips are closed, and the powder inspired through two or three short breaths. By placing a rubber band just anterior to the teeth, after being properly adjusted, the correct distance of introduction will be known for the subsequent introductions.

Radiotherapy.—The Finsen light, the Copper-Hewitt light, the Roentgen ray and radium have formed the medium of innumerable experiments for the relief of pain and the cure of laryngeal tuberculosis, but so far have proved of no avail except for the relief of pain.

Finally, if a cure for laryngeal tuberculosis is to be obtained, it will be secured only by the employment of all known means of

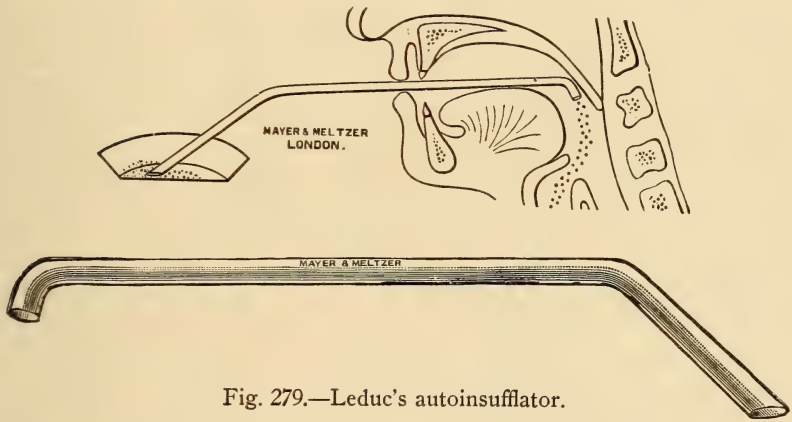

Fig. 279.—Leduc's autoinsufflator.

treatment of both general tuberculosis and its complications; hence, but little may be expected from local medication or surgery of the larynx except when combined with all the more modern methods of management and treatment.

Lupus of the Larynx.

Etiology.—Primary lupus of the larynx is exceedingly rare. It is usually secondary to that in the pharynx, nose or face.

Pathology.—The pathology is the same as that of lupus in the pharynx, heretofore described.

Symptoms.—The voice becomes hoarse during the early stages, to be followed by complete aphonia when the true and false cords become involved. Dyspnea is very severe whenever the larynx becomes stenosed. There is an irritating cough with but slight secretion and no pain. Tubercle bacilli are seldom found.

Examination.—As elsewhere, lupus in the larynx is observed in all stages, from the nodule to that of ulceration and cicatrization. It has the same general appearance here as described in the pharynx

and nose. During the progress of cicatrization puckered white scars are produced, often causing great deformities. The disease usually commences in the epiglottis, thence extending to the aryepiglottic folds and ventricular bands.

Prognosis.—Laryngeal lupus is practically never cured. It may be arrested for a time, but it will finally reappear and cause a fatal termination.

Treatment.—Constitutional treatment is the same as for lupus in the pharynx. The nodules should be removed under cocaine and the bases painted with lactic acid in 10 to 50 per cent. solution the same as in other tuberculous lesions. The lactic acid applications should be repeated every three days until the ulcers have disappeared. Tracheotomy may be required when dyspnea becomes urgent.

CHAPTER XXX.

THE INFLUENCE OF GENERAL DISEASES UPON THE EAR, NOSE AND THROAT.

(Continued.)

SYPHILIS OF THE EAR, NOSE AND THROAT.

General Remarks.—It is now quite generally conceded that the Spirocheta pallida is the causal agent of syphilis. The initial lesion consists of diffuse infiltration of round cells in the papillæ and mucosa, larger epithelioid cells, and giant cells. Conjointly a thickening of the intima of the small blood-vessels and changes in the nerve fibres of the part also take place (Berkley). In the secondary lesion there is infiltration of the endothelial and plasma cells, interspersed between the loosened epithelial cells, many of the latter exhibiting nuclear fragmentation (J. Wright). The tertiary lesion is supposed to arise from secondary exudates left behind, consisting of proliferating endothelial and connective-tissue cells, epithelioid cells and giant cells. Retrograde metamorphosis comes about by caseation or absorption beginning at the giant and epithelioid cells.

The general specific treatment is more important than the local, which consists mostly in cleansing the affected parts. Treatment should be begun as soon as the diagnosis is certain, and should be as vigorous as the condition of the patient will permit.

To embark upon the sea of specific medication is beyond the province of this book. Suffice it to say that the disease is amenable to medication, and it is of the utmost importance to curtail its ravages in order to avoid the disastrous deformities and troublesome sequelæ which sometimes obtain in the ear, nose, and throat. Few diseases respond so readily to definite specific treatment as does syphilis to mercury and iodin, and the reader is referred to appropriate text-books and monographs for detailed information in regard to the employment of these remedies.

Salvarsan with the formula $C_{12}H_{12}O_2N_2As_2$ marks a distinct advance in the treatment of syphilis but not as efficacious as was first supposed.

As sufficient time has elapsed to study the results of the treatment of syphilis by means of arsenical preparations, viz., salvarsan, neo-salvarsan, and silver salvarsan, it has been found that its efficacy is enhanced by increasing the number of administrations. Furthermore, it is universally recommended that the arsenic treat-

ment should be accompanied by prolonged administrations of mercury and iodid of potash. The latter may be continued for from one to two years. About two weeks subsequent to the administration of the sixth dose a Wassermann test should be made to determine whether the disease still exists. If so, the patient is subjected to a repetition of the arsenical treatment. This is repeated until the Wassermann becomes negative. In some instances as many as fifty injections are necessary, and some cases never give a negative complement fixation. If the negative test is obtained the patient should be retested at six-month intervals for a period of two years.

SYPHILIS OF THE EXTERNAL EAR.

Primary syphilis of the external ear is a rare affection. Politzer reports three cases. Secondary manifestations are more common and generally occur in conjunction with similar eruptions (macular, papular, and pustular) on the forehead and scalp. Gummata are seldom observed in the external ear. In the external meatus, condylomata and ulcers are the most common forms of syphilis. The former occur as grayish-red, warty efflorescences which gradually increase in size and cause swelling and secretion from the external auditory canal.

Symptoms.—At first there are no symptoms, but the advent of ulceration marks the commencement of pain of a lancinating character which is aggravated by movements of the jaw. At the same time subjective noises and deafness appear. Ulcers generally form on the posterior and inferior wall, are attended with profuse fetid discharge and a cure requires from a few weeks to several months of active local and general treatment. Papular infiltration has been observed on the membrana tympani. Gummata of the external ear are usually associated with syphilis of the tympanum. They may occur in the auricle, external auditory canal or membrana tympani. Exostoses of the canal sometimes result from syphilis.

Treatment.—Locally the ulcerations and granulations should be cauterized with silver nitrate or chromic acid and the parts kept clean until healing is complete. When the growths are smaller tincture of iodin may be employed, or they may be dusted with calomel.

SYPHILIS OF THE MIDDLE EAR.

Etiology and Symptomatology.—Primary syphilis of the middle ear is possible only by extension *per tubem* of a chancre of the pharynx, and its appearance in the tympanum is a rare occurrence. Ulcers and condylomata may cause strictures or atresia of the Eustachian tube. In the middle ear the process may set up a mucous or purulent inflammation. Women with hereditary syphilis, according to Gradenigo, are prone to develop otosclerosis between the ages of twenty and thirty.

When due to secondary or tertiary ulceration or hyperplasia, the hearing is markedly affected, especially when caries or necrosis is present. Facial paralysis, brain abscess and sinus-thrombosis are among the serious complications. Chronic suppurative otitis media is frequently associated with syphilis, and it probably results by contiguity from syphilis of the nasopharynx. Erosion of the internal carotid occurred in a case of secondary syphilis of the middle ear (Pilz).

The author has observed several cases of gumma of the middle ear which at the onset simulated attacks of acute purulent otitis media. In one instance the ear drum was opened on account of its bulging appearance. The patient also had considerable pain radiating from the mastoid region and for a short period it was feared that a mastoiditis was developing. The pain finally subsided and the gumma did not fully break down but the patient was left with considerable deafness. In this instance the correct diagnosis was never made until ulceration and perforation of the soft palate showed conclusive evidence of syphilis.

Diagnosis.—Diagnosis is often difficult and only possible (without a history of the disease elsewhere) when there is rapid destruction of the tissues in non-tuberculous patients. Additional data of diagnostic value is obtained by using the Wassermann and Noguchi tests. Only positive findings with the Wassermann reaction are to be considered of value. Negative findings mean nothing. The test should be repeated a few times before a negative report is considered final.

Prognosis.—The prognosis is favorable in the primary and secondary stages when properly treated. Ordinary cases in the tertiary stage recover under treatment, but the ultimate results upon the hearing in old cachectic individuals, or when the affection is complicated with granulomata, polypi, caries, and total deafness is very unfavorable.

Treatment.—Early general treatment must be relied upon for cure. Local treatment is employed only for cleansing, drainage, and the removal of necrosed bone (Chapters VIII and XIX).

SYPHILIS OF THE INTERNAL EAR.

Syphilis of the internal ear occurs more often in the late secondary or beginning tertiary stage, rarely before the skin eruption. Labyrinthine involvement may occur alone or in conjunction with inflammatory conditions of the middle ear. The labyrinth is said to be involved in from 7 to 48 per cent. of all internal-ear cases (Schwabach, Krelschmann, Wiese).

Pathology.—The periosteal thickenings and infiltrations become more or less organized into connective tissue and the footplate of the stapes may become immobilized in some cases. Bone absorption sometimes occurs and is replaced with connective tissue. Hemorrhagic and other exudates may become densely organized, and infiltration may occur in the acoustic nerve. Politzer reports a case of infiltration in the ganglion cells in Rosenthal's canal. The internal-ear involvement may be a part of a purulent panotitis. Ecchymosis of the acoustic nerve has been demonstrated.

Symptoms.—Symptomatologically the onset of the disease is sudden and its appearance is characterized by marked deafness, tinnitus, vertigo, and disturbance of equilibrium. Deafness is less liable to be progressive than in otosclerosis (Politzer). Intense tinnitus continues even after deafness becomes complete, but the vertigo may disappear in a few months. Diplacusis has been reported by Roosa, and Moos and Steinbrügge report cases of otalgia due to periosteal infiltrate in the labyrinth. There is nothing pathognomonic about the findings in the middle ear or Eustachian tube unless mucous patches or gummata are found therein. The mastoid lymph-glands may be much enlarged. Deafness is marked in most cases, generally both ears being affected to different degrees. The course is often very rapid; sometimes complete deafness occurring within a few days. Improvement, when it occurs, comes about very slowly.

Diagnosis.—Diagnosis mainly depends upon evidence of the disease in other parts of the body. Rapid development of deafness, without other middle-ear symptoms, in young individuals is very suspicious of tertiary syphilis. In a case of chronic non-purulent otitis media with rapid development of internal-ear deafness syphilis may be suspected. The diagnosis in cases which develop gradually is very difficult. In childhood the rapid onset of deafness without demonstrable cause is nearly always due to congenital syphilis. According to Hutchinson and Jackson, 10 per cent. of all non-purulent deafness occurring in children is of syphilitic origin. Baratoux found it to occur in 33⅓ per cent.

Prognosis.—The prognosis is very unfavorable in cases of long standing, less so in recent cases. It is unfavorable in old age, anemia, marasmus, and malignant syphilis. The congenital form is extremely obstinate. Relapses may also occur.

Treatment.—The treatment is that of the general disease. Pilocarpine in a 2 per cent. solution subcutaneously administered, gradually increasing the dose from 4 to 12 drops daily, is recommended by Politzer and Bacon. This method in the author's experience has been of doubtful benefit, and his chief reliance is placed upon the so-called "mixed treatment."

SYPHILIS OF THE NOSE, MOUTH, PHARYNX, AND LARYNX.

A. Primary (chancre).
B. Secondary (erythema, mucous patch).
C. Tertiary (gummata).
D. Congenital.
E. Syphilis of the accessory sinuses.

A. PRIMARY SYPHILIS.

Syphilis of the Nose.

Etiology.—The nose is rarely the seat of chancre. There are a few cases in literature in which it developed on the septum at the mucocutaneous juncture from picking the nose with an infected finger. It is usually located upon the alæ at the junction of the mucous membrane (Fig. 280).

Bulkley reports 95 primary lesions in the nose out of 9058 cases of syphilis. Basserau, Clerq, le Forte, Fournier and Ricord found two primary lesions of the nose out of 2244 cases of syphilis.

Syphilis of the Mouth and Pharynx.

In the mouth and pharynx the disease is more common, chancres being found on the lips, tongue, palate, faucial pillars, tonsils, and, more rarely, on the posterior pharyngeal wall.

The infection enters through broken or diseased mucous membrane as a result of kissing, perverted sexuality, or by contact with

Fig. 280.—Primary chancre of the nose. (From collection of *Dr. John A. Fordyce,* with permission.)

infected fingers, knives, forks, or the infected instruments of physicians and dentists.

Texier reports a case of multiple chancre of the mouth and pharynx, one on each tonsil, and one on the lip.

Syphilis of the Larynx.

In the larynx primary chancre is very rare. Moure has reported a case wherein it occurred on the edge of the epiglottis, and Poyst one on the left ventricular band.

Symptoms.—The disease is characterized by a hard, indurated mass which appears upon the surface of the membrane, sometimes with slight ulceration, but with little discharge. There is little or no pain when it occurs upon the alæ or in the vestibule, but the swelling may

interfere somewhat with nasal respiration. Epistaxis intervenes when ulceration is present.

In the mouth and throat the chancre causes slight pain, which is usually more marked during deglutition. The swelling is indurated, and a grayish ulceration covered with thick mucus may occupy its centre. The cervical glands, especially those under the jaw of the affected side, become enlarged and extremely hard.

Diagnosis.—The disease develops more rapidly than lupus or malignant neoplasms, and less rapidly than furuncle. Early enlargement of the cervical glands is characteristic of syphilis. It may become necessary to wait for the appearance of secondary symptoms, which appear in about six weeks, in order to establish the diagnosis. Ulceration in malignant diseases invariably progresses. That of syphilis is of small area and remains stationary.

Prognosis.—The chancre disappears in a few weeks, leaving little or no scar.

Treatment.—Beyond ordinary cleansing measures, no treatment should be employed until the diagnosis is positive, after which vigorous internal medication with mercury, according to approved methods, is imperative.

B. SECONDARY SYPHILIS (ERYTHEMA, MUCOUS PATCH).

Secondary syphilis occurs in the form of erythema, mucous patches, and superficial ulceration. In the nose this consists of a characteristic erythematous area or mucous patch located upon the mucous membrane. This mucous patch is unusual in the nose, and more common in the mouth and pharynx, where the secondary lesion appears in about six weeks subsequent to the initial chancre. Mucous patches, while not true ulcers, have the appearance of superficial ulcerated areas. They are the result of necrosis of the superficial epithelia, whereby these cells appear grayish white. They are perceptibly elevated above the mucous membrane, and surrounded by a zone of active hyperemia.

In the pharynx they attack chiefly the soft palate and tonsils, but the sharply defined patches may spread over the anterior pillars and uvula. The patches are round or ovoid, ranging in size from a split pea to a bean. Mucous patches are persistent and tend to recur even in the tertiary stage. The larynx is less frequently the seat of mucous patches, but erythema is commonly seen in the early secondary stage of syphilis. Mucous patches occurring in the region of the larynx usually attack the epiglottis, vocal cords or arytenoids. Upon the cords they produce a red and white mottled appearance which is quite suggestive.

Symptoms.—In the nose the symptoms are similar to those of acute rhinitis, although more lasting and persistent. There is a burning sensation within the nasal cavity, and sneezing is common. Nocturnal headaches are occasionally complained of. There is usually an accompanying sore throat, for the treatment of which the patient primarily applies.

The mucous patches in the mouth and pharynx produce considerable pain, which is aggravated by muscular movements. The skin lesion precedes the mucous patch and becomes a valuable symptom for purposes of diagnosis. Headache is common, and the hair, eyebrows and beard may fall out in patches.

In the larynx the symptoms are those of a mild chronic laryngitis. There is hoarseness and a slight secretion, which gives rise to a cough and clearing of the throat. Dysphagia occurs only when the epiglottis or aryepiglottic folds become involved.

Diagnosis.—The typical mucous patches are quite characteristic in appearance and are accompanied by enlargement of the suboccipital, cervical, femoral and inguinal glands. These symptoms, in conjunction with the various syphilides of the skin and occasional warty excrescences, combine to render an early diagnosis comparatively easy.

Prognosis.—Under appropriate treatment the mucous patches disappear in from two to six weeks, leaving no trace. Reappearance is common up to two years, when the treatment is neglected.

When appearing upon the vocal cords there is usually a slight impairment of voice subsequent to their disappearance.

Treatment.—The chief reliance must be placed upon appropriate internal medication (see text-books on general medicine). Some benefit arises from applications of fused nitrate of silver upon the surface of the patches every three days, and all secretions should be frequently washed away by means of alkaline sprays. On account of the extreme contagiousness of secondary syphilis of the mouth and pharynx, special knives, forks, cups, glasses, etc., should be employed, and these should be washed separately. Kissing and other forms of contact should be forbidden. Warty excrescences when present may be destroyed by fused chromic acid or nitrate of silver, and the mouth frequently cleansed with a solution of potassium chlorid, 12 grs. to the ounce, and chlorid of zinc, 10 grs. to the ounce.

C. TERTIARY SYPHILIS (GUMMA).

The characteristic lesions of tertiary syphilis rarely appear under two years from the date of the primary lesion; more often fully five years elapse, and gummata may appear even after fifteen or twenty years. The pathological appearances are those of the gumma, the ulcerated or broken-down gumma, necrosis of cartilage, and bone, and finally, resultant deformities, scars and adhesions. All stages of gummata are found in the nose, appearing in the tissues of the septum, the bony framework or the alæ. They usually break down rapidly, but may remain stationary for some time. In this location they are circumscribed, nodular or diffuse, the latter form being more common. Upon breaking down they result in deep ulcers and necrosis of cartilage and bone.

In the mouth and pharynx the gummata appear upon the posterior pharyngeal wall, hard palate, faucial pillars, tongue (Fig. 281) or tonsils. They are indurated swellings, which are either circumscribed or diffuse. They are round or oval, ranging in size from a small pea

to a hickory nut. They are found on the epiglottis, aryepiglottic folds, ventricular bands and walls of the larynx. When multiple they produce a lobulated appearance (Fig. 282). The growth is rapid and necrosis occurs early.

The pathological changes in the ulcerative stage depend upon the situation and depth of the involvement. In the epiglottis there may be partial or total destruction of the cartilage, and the ulceration may extend into the base of the tongue. Ulceration of the aryepiglottic folds often causes twisting of the epiglottis, due to the contracting cicatrix, with narrowing of the introitus of the larynx.

In other cases the arytenoids become necrosed, resulting in deformity, and ankylosis of the cricoarytenoid articulations. Whenever the ventricular bands become ulcerated there is much loss of tissue, which may extend to the true cords. After healing a variety of deformities and adhesions forms, some of which are prone to cause atresia of the larynx.

Fig. 283.—Nasal deformity (saddle-back) resulting from syphilitic necrosis of the nasal and turbinate bones.

Symptoms. — The appearance of gummata within the nose is usually characterized by the manifold symptoms of nasal obstruction. Pain soon appears, is worse at night, and becomes intensified as necrosis develops.

Necrosis and ulceration are accompanied by a discharge of foul mucopus, and the formation of masses of thick scabs, which are blown from the nose. Particles of necrosed bone may also be blown or otherwise removed from the nasal cavities. Bare and loose bones are easily detected with the probe, the vomer being most frequently involved. The masses of retained necrosed bone emit a foul stench. Opinions vary as to whether atrophic rhinitis with ozena may sometimes be of syphilitic origin.

The nasal and turbinal bones often become necrosed and separate from their attachments, resulting in external saddle-back and other deformities (Fig. 283). Adhesions, nasal stenosis, polypi, and a variety of internal deformities result from the ravages of tertiary nasal syphilis. The most serious of these deformities are:—

1. Collapse of the entire anterior third of the nose (Fig. 284).

Fig. 281.—Gumma of the tongue healing. Male aged 30. Resulting from syphilis three years ago. (From collection of *Dr. John A. Fordyce,* with permission.)

Fig. 282.—Interstitial glossitis. Syphilis 6 years old. Patient chews tobacco and drinks. Mouth sore for 5 years; the same condition, he says, as now exists. Tongue is thickened, fissured and seat of leucokeratosis. The same condition of leucokeratosis extends back along line of teeth from angles of the mouth. (From collection of *Dr. John A. Fordyce*, with permission.)

2. Sinking in of the entire nostril so that only the slits of the nostril project.

3. Destruction of the alæ and complete nasal stenosis.

In the Pharynx.—Syphilitic gummata when occurring in the nasopharynx are usually found upon the posterior wall in the form of swellings, which may vary in size. They give rise to pain, altered voice and sometimes difficulty in deglutition; nasal respiration is interfered with, and regurgitation of liquids into the nasopharynx and out through the nasal passages is common. Upon breaking down the surface becomes ulcerated, with a mucopurulent discharge into the oropharynx. Large ulcers are liable to develop upon the upper wall of the soft palate, the granulations from which

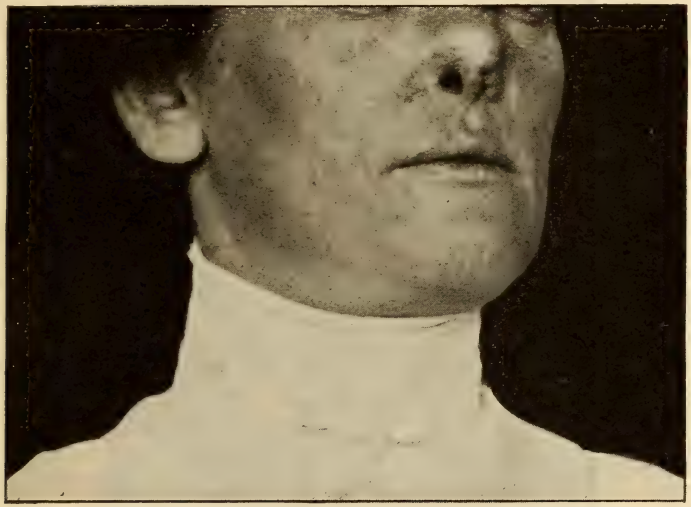

Fig. 284.—Collapse of anterior portion of nose. The subject of this particular photograph is a victim of lupus and not of syphilis.

are prone to result in adhesions of the soft palate to the posterior wall, a very distressing sequela of this disease. Syphilitic perforations of the soft palate produce voice sounds similar to those of cleft palate, and liquids and food pass through the perforations into the nose.

Nodular gummata generally appear on the soft palate and resemble lupus, the surface appearing rough and thickened. Both superficial and deep ulcers accompany the tertiary lesion, the former in the early tertiary, and the latter during the later stages. Gummatous ulcers present a round, punched-out appearance, with irregular margins and excavated centres, which are covered with sloughing tissue and foul secretion.

A variety of deformities results from the destruction of tissue and from the contracting cicatrices. Adhesion of the posterior pillars to the posterior pharyngeal wall produces atresia. Adhesion

of the soft palate to the posterior pharyngeal wall is the commonest form (Fig. 285) and the results are disastrous to nasal breathing and the proper ventilation of the middle ear. Constriction of the pharyngeal ostium and the Eustachian tube may result.

Of the Larynx.—The tertiary manifestations of syphilis in the larynx are in the order of their occurrence:—

1, Gummata; 2, ulcerations; 3, perichondritis and necrosis of tissue; 4, the resultant scars, deformities, and adhesions.

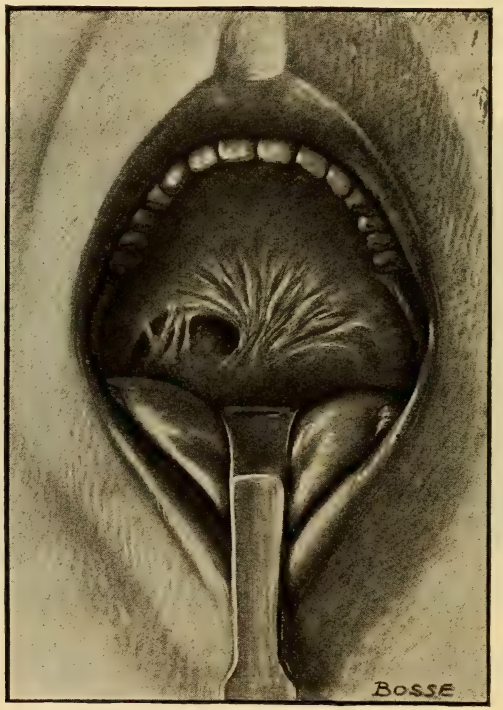

Fig. 285.—Cicatricial adhesion of the soft palate to the posterior pharyngeal wall.

Gummata may appear in any portion of the larynx and are either diffuse or circumscribed. They are found upon the epiglottis, arytenoids, vocal cords, and the ventricles. They are deep-red, oval-appearing swellings, surrounded by inflammatory areas. They tend to break down rapidly and ulcerate.

The first manifestation of ulceration is the appearance of a small, yellowish central area. Syphilitic ulcerations of the larynx are usually deep and extensive, with the appearance of being punched out. The edges are sharp and well defined, and surrounded with a red and edematous areola. They invariably occur as sequelæ of gummata. The ulcerated surfaces are covered with portions of necrosed tissue, which are bathed in pus.

As the ulcerative process extends, the perichondrium and the laryngeal cartilages become the seat of a gummatous infiltration. This stage is characterized by marked swelling of the soft tissues, abscess formations and necrosis of the cartilages. Necrosis of the cartilages is attended with extensive destruction of the laryngeal tissues. Whenever the epiglottis is the seat of a gumma there is a sensation as of a lump in the throat of which the patient is constantly conscious, especially during the act of swallowing. Gummata in other portions of the larynx usually produce more or less dyspnea. The voice becomes hoarse or aphonic, the degree thereof depending upon the amount of interference with the movements of the vocal cords.

During the active stages of ulceration edema of the larynx may develop and evoke sufficient dyspnea to necessitate either

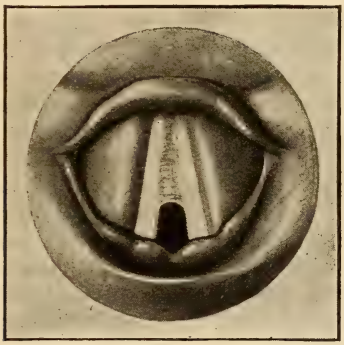

Fig. 286.—Cicatricial web-formation between the vocal cords.

scarification or tracheotomy. The vocal cords, when involved, show irregular changes and marked immobility.

The sequelæ of extensive necrosis mark the advent of the fourth stage of laryngeal syphilis—namely, scars, adhesions, and stenosis. Tertiary syphilis of the larynx almost invariably results in permanent damage to its structures. The epiglottis may become deformed, partially or wholly destroyed, or adherent to the surrounding structures. One or both vocal cords may be destroyed by the ulcerative process or become adherent to the surrounding tissues. In some instances they become partially attached to each other by means of a web of connective tissue (Fig. 286). Fixation of the cords may result from ankylosis of the cricoarytenoid cartilages. The subglottic region may become narrowed as a result of connective-tissue bands.

The principal permanent results are: Dyspnea from narrowing of the calibre of the larynx, fixation or paralysis of the vocal cords, and loss of voice. During the stage of necrosis fetor of the breath is a marked symptom.

Diagnosis.—The diagnosis is based upon the characteristic appearance of the lesion, the history of syphilis and its controllability by antisyphilitic medications.

Prognosis.—Gummata in acquired syphilis, when seen early, usually respond favorably to medication. Under early and vigorous internal treatment they disappear in from one to eight weeks. In neglected cases ulceration ensues with more serious results in the form of scars, cicatrizations, and deformities.

Of deformities the serious types are adhesions of the soft palate to the posterior pharyngeal wall and those occurring within the larynx. In all the prognosis should be guarded, inasmuch as death may occur suddenly from edema or complete stenosis. In this type the voice usually becomes permanently impaired or aphonic.

Treatment.—The gumma, when nodular and not ulcerating, requires no local treatment. At this stage it is possible by prompt and vigorous internal medication to effect a cure without ulceration, necrosis or subsequent deformity. The ulcer, when superficial, is benefited by the use of local cleansing alkaline washes or sprays, of which the physiological normal salt solution is the type, followed by topical applications of argyol in 25 per cent. solution, or silver nitrate in 5 per cent. to 10 per cent. solution.

The Nose.—Necrosis of the bones and cartilages of the nose necessitates a resort to surgical measures. The presence of necrosed bone is revealed by the characteristic odor and by the use of the probe. Before operating the location and extent of the necrosed area should be carefully mapped out. This procedure is facilitated by first packing the nasal cavities with a solution which contains adrenalin 1 : 5000 and cocaine 2 per cent. The adrenalin effects marked shrinking of the soft tissues, thus yielding a better view of the diseased bone, and the cocaine produces local anesthesia of the parts preparatory to the removal of the diseased bone and soft tissues.

The Operation.—Having located the necrosed sequestrum, it is usually possible to accomplish its removal with forceps. When the necrosed masses are large it becomes necessary to incise the soft tissues about them in order that extraction may be effected without unnecessary laceration. In case the nasal bones separate and come away serious external deformity results (Fig. 283).

The removal of the turbinals and vomer is less serious, while the loss of the entire cartilaginous septum is followed by collapse of the tip (Fig. 284). Even though deformities occur, it is none the less necessary to remove all necrosed bone and curet necrosed areas.

Postoperative treatment consists in washing the nasal cavity with warm salt solution, followed by applications of argyrol in 25 per cent. solution to the diseased areas. Healing takes place rapidly under vigorous internal medication.

Treatment of the deformities of the nose when due to syphilis should never be attempted until the underlying disease is under full control. A variety of plastic operations, combined with the insertion of metal, hard-rubber and bone splints have been devised. The results of this form of treatment are usually unsatisfactory. The most effective method of overcoming these deformities is by

paraffin injections, for a description and illustration of which see Chapter XL.

The Nasopharynx and Pharynx.—The treatment of tertiary syphilis of the nasopharynx is constitutional, as heretofore described, but in case of ulcerations every possible effort should be made to prevent adhesions. This may be accomplished by cauterizing the ulcerated surface with a strong solution of nitrate of silver or iodin, and by keeping the surfaces clean by syringing with salt or other alkaline solutions. Any tendency to the formation of adhesions should be promptly met by separating the bands at frequent intervals. Adhesions of the soft palate with the posterior pharyngeal wall when already formed are most difficult to break down. Being usually due to the ulcerative process associated with tertiary syphilis, with strong and inelastic new connective-tissue formations, they resist almost every effort to restore the normal functions of the nasopharynx. The clinical picture of palatal adhesions is variable, depending upon the site of the ulcers as well as the changes in the structure and shape of the velum. The adhesions may be partial or total, and are situated either at the margin of the velum or above it. The ear is almost invariably involved by obliteration (partial or complete) of the Eustachian tube.

The treatment of deforming cicatrices in the pharynx, especially those of adhesions of the soft palate to the posterior pharyngeal wall, is invariably unsatisfactory, inasmuch as syphilitic adhesions consist of dense, white, tough bands which radiate in all directions from the centre of the original ulceration. On the posterior pharyngeal wall the submucosa may be bound down to the anterior portion of the cervical vertebræ. To the finger the scar feels immovable and hard. The least that may be expected is to maintain a small communication between the posterior nares and the pharynx. After incision through the adhesion, Coakley[2] advocates the introduction of a tape drawn through both the nostrils and the mouth, the ends to be tied so as to keep the incised edges apart.

The Larynx.—Owing to the slight discomfort induced by gummata in this region, the surgeon is seldom consulted until the stage of ulceration. The ulcerative stage threatens serious consequences in the form of permanent loss of the voice, and laryngeal stenosis. It therefore becomes imperative that the internal medication be rapidly pushed to its physiological limits in order to prevent these serious sequelæ.

Locally, soothing sprays and applications for the relief of cough and pain often become necessary. Mild attacks of perichondritis of the laryngeal cartilages often resolve under internal medication, without necrosis.

Should necrosis intervene it becomes necessary to remove the diseased areas. Such operations may be performed either with

---

[2] Diseases of the Nose and Throat.

indirect illumination or, preferably, by direct laryngoscopy (see Chapter LIII).

The advent of dyspnea during the course of tertiary laryngeal syphilis is of serious import. When due to the location or size of a gumma the patient should remain quiet until the mass subsides as the result of general treatment. Edema developing during the stage of ulceration which does not produce urgent symptoms often subsides upon scarification of the tissues. The laryngeal mucosa should first be anesthetized by spraying with a solution of cocaine, after which several incisions may be made into the edematous portions by means of a guarded knifeblade (Fig. 502).

Exudation immediately follows, which may be prolonged by steam inhalations. If the dyspnea increases notwithstanding the scarification, tracheotomy should be performed without delay. In some instances the dyspnea is caused by the dislodgment of sequestra into the lumen of the larynx, and the resultant urgent symptoms require removal by laryngoscopy or laryngotomy. The surgical treatment of laryngeal stenosis and adhesions is fully described in Chapter XLIX.

D. CONGENITAL SYPHILIS.

Secondary Lesions.

Etiology.—In the secondary form congenital syphilis of the nose, throat, and larynx usually appears during the first few weeks of life in the form of erythema or mucous patches, which are precisely the same as those of acquired syphilis.

Symptoms.—The chief symptom is nasal discharge and occlusion, with snuffling, snoring, and mouth breathing. The child can take the breast or bottle for only a few seconds at a time. He emaciates rapidly and becomes wrinkled and weazened in appearance.

In the pharynx and larynx the disease produces a hoarse cry, which is quite characteristic and suggests infiltration in the larynx. Gaucher claims congenital syphilis as a causative factor in hyperplasia of the pharyngeal tonsil. Glandular hypertrophy and the typical skin eruptions aid in confirming the diagnosis.

Tertiary Lesions.

The tertiary form of congenital syphilis commonly appears from 7 to 14 years of age. The range may be from 4 to 20 years. Typical gummata and ulcerations develop the same as in acquired syphilis.

The Ear.—Congenital tertiary syphilis, when it involves any portion of the auditory apparatus and especially the labyrinth or auditory nerve trunk, produces serious and sometimes permanent impairment of the hearing function, and in many cases marked nystagmus and vertigo. The following case furnishes an illustration:—

H. D., female, aged 16 years. Father healthy, but mother had contracted syphilis six months previous to her marriage. The mother had nine pregnancies and five miscarriages, five of which occurred prior to the birth of the patient. The child had blisters on the sides of her feet when born, but otherwise had remained well since childhood, except for a spontaneous nystagmus and some disturbance of equilibrium. She is well developed physically, but somewhat backward mentally. Her nasal respiration has always been somewhat impaired, owing to a septal spur, adenoids and hypertrophied tonsils. There had been no perceptible impairment of her hearing. On November 4, 1909, upon awakening, she complained of pain in her right knee and foot, and that she could not hear. She had intense tinnitus and marked vertigo. The right knee was swollen and painful to the touch, and there was considerable muscular weakness of the right arm and leg. Her reflexes were exaggerated. When standing with the eyes closed she swayed to the left, but felt as though falling to the right side. An examination of the pharynx revealed absence of the uvula and a partial adhesion of the soft palate to the posterior pharyngeal wall.

The right membrana tympani was retracted and the left inflamed.

Functional Tests.—Weber test was heard to the right. When Bárány's noise-producer apparatus was applied to the right ear, neither loud voice nor tuning fork heard, showing total deafness in left.

Caloric Test.—Irrigation with cold and hot water showed no reaction in left ear. The *Wassermann test,* made some time after the commencement of specific treatment, was negative.

The patient was admitted to the Post-graduate Hospital on November 26th. She then had marked arthritis of the right knee and ankle, which soon extended to the left knee and ankle. The joints were swollen, painful and tender. She had a temperature ranging from 101° to 104° for about a week, when it became normal and remained so. There was a partial ankylosis of both knee-joints, which was overcome by heat, massage and passive movements. She was given the usual antispecific treatment, and she rapidly improved. January 7th she was discharged and taken to her home. Soon afterward she developed an interstitial keratitis in the right eye. The iodid of potassium was rapidly increased up to 120 grains three times per day.

The loss of hearing has remained permanent. She still suffers somewhat from vertigo and has repeated attacks of keratitis in both eyes, but the joints have cleared up and she is able to walk about and attend to her duties.

In the larynx of the infant the chief symptoms are bleating or almost voiceless crying, and cough which is lacking in tone. Dyspnea is present and commonly accompanied by laryngismus stridulus. Edema and dysphagia are common. Hutchinson's teeth are found in older children. Postmortem examinations have shown that necrosis of the laryngeal cartilages does occur in syphilitic infants.

Prognosis.—Under two years of age the disease is very grave, few cases surviving. Death occurs from asphyxia, starvation, malnutrition or bronchopneumonia. Older children may become victims of the various forms of laryngeal deformities.

Treatment.—The treatment is the same as in acquired forms.

E. SYPHILIS OF THE ACCESSORY SINUSES.

Tertiary syphilitic bone necrosis of the accessory sinuses is occasionally observed, usually attacking the frontal and ethmoidal cavities first, and later the antrum of Highmore and the sphenoidal. Gummata invariably originate in the bone and not in the mucosa.

Leucoplakia Oris.

Leucoplakia oris, sometimes known as psoriasis buccalis, is an oral disorder which may affect the entire mouth, but is usually most marked in the anterior portions. The usual site is upon the anterior half of the surface of the tongue and along its margin, although the mucous membrane of the lips, angle of the mouth and cheeks are sometimes covered by these bluish-white, white, opaline or somewhat yellowish patches; in addition to the smooth patches, either shining and moist or dull and dry, the tongue often shows small cracks and minute ulcers.

The pathology consists in passive hyperemia and round-celled infiltration of the mucosa due to the presence of inflammatory irritation. The covering of the patches is made up mostly of hyperplasia and hyperkeratosis of the epithelium.

The **main etiological factor** is syphilis; here leucoplakia shows itself in the recently infected cases. W. Erb found a clear history of syphilis in 80 per cent. of his cases. The condition, however, is aggravated and prolonged by gastric catarrh, excessive smoking and by nasal secretions, both catarrhal and purulent. It is considered more significant when occurring upon the tongue, many authorities believing that the epithelial proliferation has a tendency to degenerate into cancer.

There are no distressing **symptoms,** only slight pain being experienced at the seat of the lesions.

The **treatment** is chiefly local; yet, in some cases, tonic, antiluetic or other constitutional treatment must be resorted to. Locally Leistikow uses the following paste: Resorcin, 6 parts; terræ siliceæ, 3 parts; lard, 1 part; this is applied over the patches with a swab after eating and before going to bed. In a week or two the patches are said to disappear. Rinsing the mouth frequently with an alkaline wash is useful, and, to overcome the hyperemia caused by the resorcin, applications of balsam of Peru are recommended.

In obstinate cases Rosenberg has had excellent results by the local application of a 20 per cent. solution of iodid of potassium.

To avoid the evolution of this disease into true cancer Perrin completely extirpates the spots or patches by surgical means.

CHAPTER XXXI.

THE INFLUENCE OF GENERAL DISEASES UPON THE EAR, NOSE AND THROAT.

(Continued.)

DIPHTHERIA.

General Remarks.—Diphtheria is an acute contagious disease, characterized by fibrinous exudate which is produced by the Klebs-Loeffler bacillus. The exudate occurs most frequently on the tonsils, soft palate, accessory sinuses and larynx, and rarely in the middle ear or external auditory canal. In severe cases the membrane extends in all directions, occasionally involving the contiguous skin. The disease rarely occurs primarily in the external auditory canal.

Etiology.—It is essentially a disease of childhood, occurring chiefly from the second to the fifteenth year, the proportion being larger from the second to the fifth. Inflammatory enlargement of the glands composing the lymphoid ring, disease of the mucosa of the nose, throat, and mouth, and lowered conditions of general nutrition are predisposing factors. The specific cause of the disease is the Klebs-Loeffler bacillus (Fig. 287). In New York City it is most prevalent between October and March. The disease is universal both as to race and locality, but is more prevalent among poorly nourished children in overcrowded tenements. Sunshine, fresh air and good sanitation are foes to the diphtheria bacillus.

The scarlatinal sore throat is usually susceptible to the Klebs-Loeffler bacillus, which is very hardy and capable of living many months outside the body.

Mode of Infection.—Infection often takes place through clothes, instruments and utensils, in which the germ may live many months. Likewise it persists in the nose, throat and mouth long after the disease has disappeared and with little, if any, decrease in virulency. The infection is transmitted by towels, napkins, clothing, bedding, books, rugs, wall paper, and cooking utensils in use about diphtheritic patients, and may be conveyed by naturally immune attendants. Infection may thus contaminate the milk supply and cause the disease in cats and dogs as well as in individuals. The disease is directly conveyed by kissing, inhaling directly from the diphtheritic any mucus or floating particles of infection. Solis-Cohen reports 27 cases of latent diphtheria with mild symptoms of tonsillitis and pharyngitis. It occurs with greater frequency through contaminated food than through inspired air. Diphtheria appears either in epidemic, endemic or sporadic form, and always with varying severity. The incubation period varies from twenty-four hours to a week—usually from three to four days.

Pathology.—The onset of the disease is characterized by hyperemia and round-cell infiltration in the mucous membrane and by the transudation of lymph. The characteristic diphtheritic membrane is the result of coagulation necrosis of the epithelial layer of the mucous membrane, which is produced by the toxins. The diphtheritic membrane ordinarily extends to the submucous layer, and only in severe cases does it reach the underlying tissue. The coagulation of lymph into fibrin makes the false membrane very firm and tenacious, and the exudate causes the membrane to be raised above the surrounding level.

The color of the membrane ranges from a dirty gray when superficial to a dark green or black when the deep blood-vessels become involved, thus cutting off nutrition and by so doing pro-

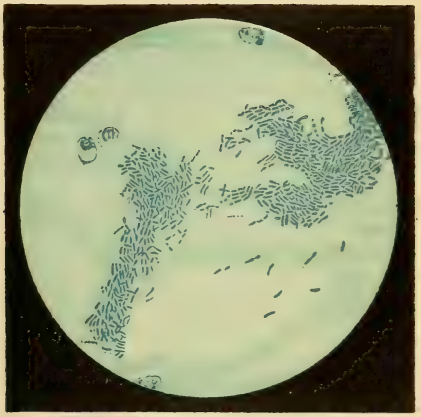

Fig. 287.—Diphtheria or Klebs-Loeffler bacilli. Smear deposit. Loeffler's stain. *(Lenhartz-Brooks.)*

ducing gangrene. A line of demarkation appears in from four to six days; the fibrin becomes granular; epithelial cells disintegrate, and the membrane separates in large or small pieces. If the involvement is deep an ulcerating surface is left. There is more or less cervical adenitis.

Antitoxin possesses the power to cut short the membranous proliferation. There is usually no extension of the diphtheritic membrane after twelve hours from the time of injecting antitoxin, and as a rule the membranous exudate disappears entirely in from thirty-six to forty-eight hours after an injection of antitoxin.

Types of the Disease.—(*a*) *Non-membranous,* in which there is redness and infiltration of the mucosa but no membranous exudate. The Klebs-Loeffler bacilli are present in the secretions.

(*b*) *Fibrinous* (Monti).—The microscopic findings show the Klebs-Loeffler bacilli in pure culture unmixed with other pathogenic organisms. The membranous exudate may be localized or diffuse, and the toxemia mild or severe.

(*c*) *Mixed Infections* (Monti).—In this type there is severe inflammation of the submucosa, which tends to necrosis of the tissues, the formation of phlegmon, gangrene and other severe manifestations, all resulting from the combined action of the toxins of the Klebs-Loeffler bacillus and other pathogenic organisms, notably the streptococci.

DIPHTHERIA OF THE EAR.

Etiology.—Primary diphtheria of the ear is very rare. Otitis media purulenta acuta occurs in 10 per cent. of all cases of diphtheria (Duel), and it shows a marked tendency to become chronic. When the purulent otitis continues during convalescence from diphtheria the Klebs-Loeffler bacilli are generally associated with streptococci. The involvement of the ear is more frequent in the malignant and fatal forms of the disease. In the latter a normal tympanum is seldom found. In 25 fatal cases only 1 had a normal ear (Siebenmann). The disease usually comes on at the height of the nasopharyngeal process, and the infective bacteria probably enter the tympanic cavity through the Eustachian tube. Diphtheritic bacilli, once in the ear, are liable to remain for a long time, but they lose much of their virulence after the subsidence of the acute symptoms.

Symptoms.—Otalgia is severe and tends to remain several days after perforation of the membrana tympani. Perforation of the drum is very rapid, more rapid than in the ordinary acute purulent cases, and the temperature rise is higher. In very young children cerebral symptoms, delirium and convulsions may occur at the onset. Enlarged cervical lymph glands are more common than in ordinary purulent otitis media. The rapid destruction of the drum is due to the toxic necrosis induced by the specific bacteria, which are conducive to rapid destruction of these tissues. Occasionally, the characteristic membrane may be visible in the middle ear, and extends outward into the external auditory canal. It can be removed only with force, leaving a bleeding surface. The discharge is slight during the first few days, but, as the membrane separates, it becomes profuse, foul, and sometimes bloody. The mucous membrane of the tympanum becomes swollen, red and edematous. Mastoiditis and other serious complications are comparatively common in diphtheritic otitis media.

Prognosis.—The suppuration is prone to persist and to become chronic unless terminated by appropriate treatment. Large, permanent perforations in the drum usually result, through which granulations and polypi may protrude. The suppuration sometimes becomes chronic, with resultant bone necrosis.

Deafness is marked during the acute stage, but improves as the disease subsides. There is usually a moderate residual deafness. Partial or total deafness remains when the labyrinth has been seriously involved, and when occurring in infants deaf-mutism may thus result. Combined with scarlatina the process is usually more destructive and the involvement more extensive.

Treatment.—Aside from the usual antitoxin and general measures of treatment, thorough paracentesis should be performed at the first sign of tympanic pain. Otherwise the treatment is the same as in ordinary cases of otitis media purulenta acuta. An important prophylactic measure consists in cleansing the nose and throat from the onset of the diphtheritic attack with hot normal salt solution, as frequently as is necessary to keep the surfaces clean. This will often prevent the extension of the process much beyond the original seat of the disease.

DIPHTHERIA OF THE NOSE, THROAT AND LARYNX.

Symptoms.—There are both local and constitutional symptoms, the latter, evidently, arising from the effect of the toxins in the general circulation. Among the constitutional symptoms fever, muscular weakness, and depression are prominent. The onset of the disease is characterized by general malaise, loss of appetite, and, sometimes, vomiting. Convulsions sometimes occur in infants, while older children and adults do not complain until the sensation of soreness and stiffness appears at the site of the exudate. The temperature varies from 101° to 104° during the first three or four days, during which time the pulse is usually accelerated.

During the later stages the pulse may become slow, irregular or intermittent, on account of cardiac weakness.

In severe forms there is a great prostration, delirium, extremely foul odor, dark complexion, extensive cervical adenitis, and death may ensue as early as the second day.

The most serious complications are cervical adenitis, myocarditis, endocarditis, nephritis, purulent otitis media and laryngeal stenosis.

Locally there are pain and soreness around the inflamed mucous areas and evidences of mechanical obstruction to nasal and laryngeal respiration due to the exudate. The odor from the membranous exudate is foul and quite characteristic.

Nasal Diphtheria.

Diphtheria of the nose rarely occurs unaccompanied by pharyngeal manifestations. The symptoms peculiar to nasal diphtheria are as follows: At the onset there is a profuse discharge of mucopus, which produces excoriation about the nostrils. This symptom, occurring suddenly in young children, should arouse suspicion, and a test culture should be taken.

Upon examination the characteristic membranous exudate will be found upon the septum or turbinals, and as the disease progresses the discharge becomes blood-tinged and epistaxis may take place. There is a tendency to mouth breathing and the breath is foul. The constitutional symptoms are mild if the anterior portion of the nose alone is involved. Cervical adenitis is common. The membrane may completely fill the nostril, and spread over the

FIGURE 288.

Case A.—Common Type of Diphtheria. Child three years old. Seen on fourth day of illness at the Willard Parker Hospital. Exudate covering tonsils, pharynx, and uvula. Received in all 16,000 units of antitoxin. Throat clear on sixth day. Case discharged cured. (Original.)

Case B.—Follicular Type of Diphtheria. Child seven years old. Seen on second day of illness at the Willard Parker Hospital. The membrane involved the lacunæ of the tonsils. Note the close resemblance to follicular tonsillitis. Received in all 6000 units of antitoxin. (Original.)

Case C.—Hemorrhagic Type of Diphtheria. Child seven and one-half years old. Seen on sixth day of illness at the Willard Parker Hospital. Tonsillar and postpharyngeal exudate. Severe nasal and postpharyngeal hemorrhages during exfoliation of membrane. Received in all 15,000 units of antitoxin. Throat clear on ninth day of illness. Myocarditis developed. Case discharged cured four weeks after admission. (Original.)

Case D.—Septic Type of Diphtheria. Child eight years old. Seen on the fifth day of illness at the Willard Parker Hospital. The pseudomembrane in this case covered the hard palate and extended in one large mass down the pharynx, completely hiding the tonsils. (Original.)

(*Fischer,* with permission.)

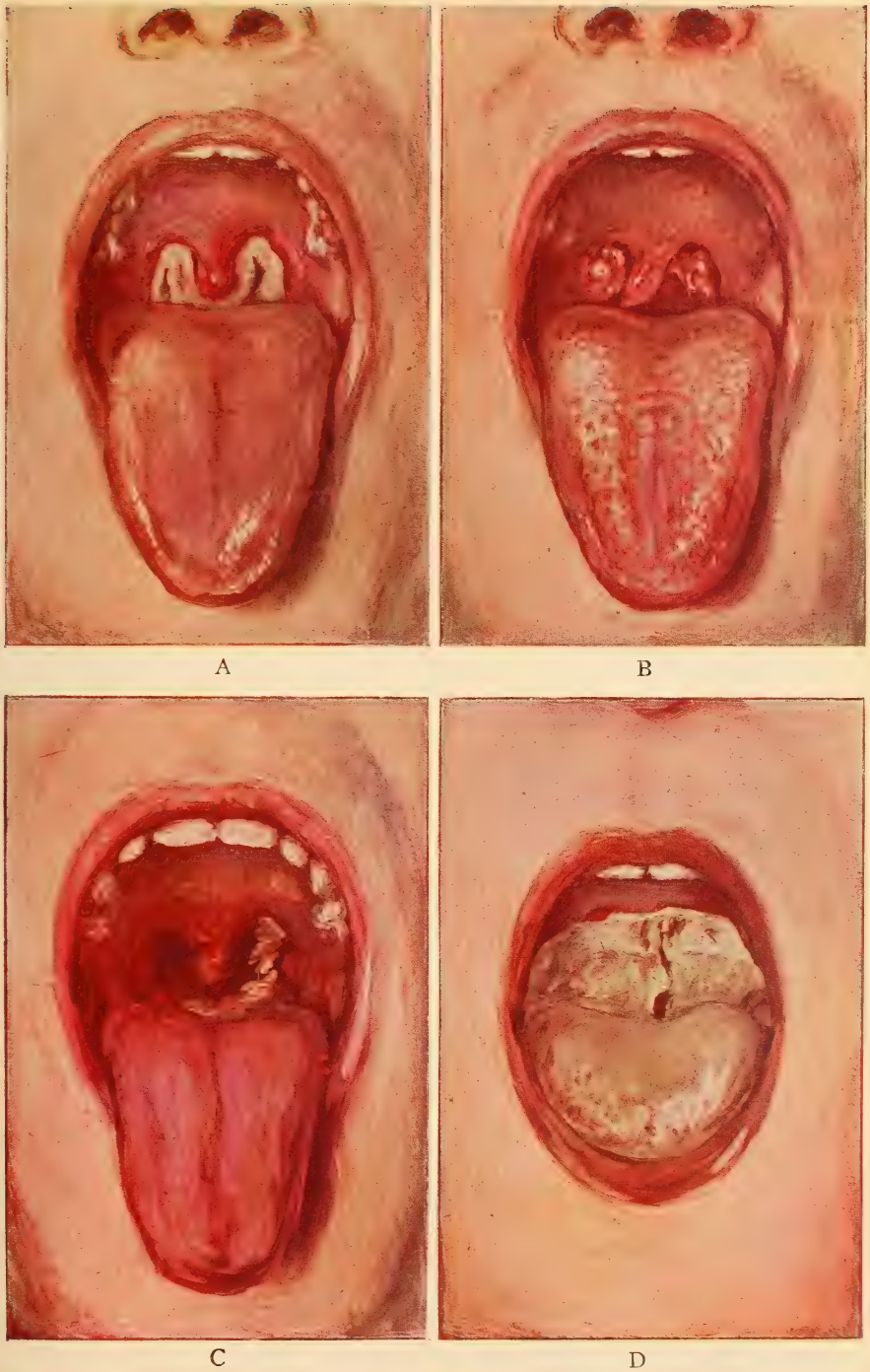

Fig. 288.

septum and inferior turbinal. As this separates, complete casts of the interior of the nose may be discharged. An ulcer is often left behind. Middle-ear suppuration is a common complication of nasal diphtheria.

Pharyngeal Diphtheria.

As a rule, the diphtheritic membrane develops primarily upon the tonsils and extends by contiguity to the uvula, soft palate, and posterior pharyngeal wall. Patients having adenoids and diseased tonsils are not only more liable to the disease, but the attacks are severer and complications are more frequent.

Examination.—A thin, grayish membrane, either circumscribed or in patches, appears upon the tonsil, pillars, soft palate, or posterior pharyngeal wall (Fig. 288). The false membrane gradually becomes thicker and hence elevated above the surrounding membrane. The patch is surrounded by a narrow, dark, hyperemic zone, and during the early stages it may be mistaken for lacunar tonsillitis. It is removed with difficulty, and a bleeding surface remains. The exudate re-forms rapidly.

When gangrenous, the exudate becomes greenish or black. Without antitoxin the membrane disappears in from five to twelve days. The edges gradually separate and curl up and large pieces break away, leaving ulcers. In every suspected case a culture should be taken from the secretions of the diseased area for laboratory examination.

Laryngeal Diphtheria.

Laryngeal diphtheria usually occurs as a secondary manifestation of either the nasal or pharyngeal types, and is characterized by a dry, croupy cough and a hoarse voice. In severe cases, with extensive areas of exudate, dyspnea rapidly ensues, the voice is lost, and impeded or stridulous respiration is observed. This is accompanied by extreme restlessness, tenseness of the sternocleidomastoids, retraction above and below the clavicles and of the diaphragmatic portions of the chest during inspiration and cyanosis unless relief is obtained, otherwise a fatal issue ensues.

In favorable cases the membrane is circumscribed and remains so until it gradually exfoliates. The disappearance of the exudate marks the gradual subsidence of the laryngeal symptoms.

Differential Diagnosis.—Streptococcic tonsillitis is common in scarlet fever, measles and other infections. The exudate in these cases tends to coalesce and form a membrane which in appearance is similar to that of diphtheria. Bacteriological diagnosis often becomes the sole criterion.

The mucous patch of syphilis differs from diphtheritic exudate as follows: It is thin, non-adherent, with slight or no elevation above the surrounding mucosa. Its duration is without definite limitations, there is lack of acute constitutional symptoms, and there is the added presence of other specific symptoms of syphilis.

Pharyngeal mycosis differs from diphtheria by being a non-inflammatory condition, with no constitutional symptoms. The conical projections are characteristic. On examination with the microscope the *Mycelium leptothrix buccalis* is found.

Prognosis.—In uncomplicated nasal and pharyngeal diphtheria in patients subjected to antitoxin during the first three days the prognosis is good, the death rate not exceeding 4 to 10 per cent. Mild cases may suddenly become virulent, or fatal complications may quickly terminate in death.

The prognosis is influenced by the character of the epidemic, the prevailing type of the disease, the condition and surroundings of the patient, the age of the patient, the laryngeal type, and by such complications as glandular involvement, cardiac failure, epistaxis, gangrene, and bronchopneumonia.

TREATMENT OF DIPHTHERIA.

The treatment of diphtheria is considered under four headings: 1, prophylactic; 2, hygienic and dietetic; 3, constitutional; 4, local.

Prophylactic.—The virulence of the diphtheritic bacillus has become well known as a result of the bacteriological studies of recent years. The Klebs-Loeffler bacillus is found in the upper air passages for long periods after all constitutional symptoms of the disease have passed away. Nurses and other attendants of diphtheritic patients may likewise convey the germs without constitutional or marked local symptoms of the disease. Prophylaxis, therefore, becomes an important phase in the treatment.

The Schick Test and Its Application.—In 1913, Schick published a description of a clinical test showing that diphtheria is not contracted except by those individuals who have no antitoxin in their blood and tissues. Patients giving positive Schick reactions are not immune to diphtheria; while patients giving negative Schick reactions may be considered immune from this disease. It has been found that the former or non-immune individuals may be immunized by the proper injection of the substance known as toxin-antitoxin. Schick test control outfits are now furnished by all well equipped laboratories, so that private physicians as well as health departments are able to apply this test to those under their care. It is recommended that the immunizing test shall consist of three injections ranging from three to five L plus tests of toxin-antitoxin, one or two weeks apart. The importance of this procedure in the preservation of child-health cannot be over estimated. A quotation from the New York City Health Department circular to parents is as follows:—

Diphtheria.—It is true that since the discovery of antitoxin much illness from this disease has been prevented and many lives have been spared. Yet the records of the Health Department of this city show what ravages this scourge of childhood still causes.

Here are some of the figures:

Diphtheria: Incidence and Mortality, 1917-1921.

Year	Cases	Deaths
1917	12,624	1,158
1918	11,455	1,245
1919	14,014	1,239
1920	14,166	1,045
1921	15,052	807

Only on Dec. 18, 1920, the Health Department called attention to a recent alarming increase in the number of cases of diphtheria. During the last half of the year the cases decreased markedly.

For years and years physicians have been experimenting to discover some means of ridding the world of this disease. And why should they not hope to succeed? Two hundred years ago smallpox carried off hundreds of thousands of people yearly, and many of the persons one passed in the street were pockmarked for life. Today we know that vaccination has all but wiped out this dreadful disease, so that a few cases occurring in one year in a city as big as New York are a source of surprise and alarm.

A Wonderful Discovery.—It should therefore be a source of great joy to parents to learn that as the result of a recent discovery by Dr. Schick it is now possible to say with certainty that diphtheria can be prevented and that not many years hence there will probably be as little diphtheria then as there is smallpox now.

This discovery consists of two parts:

1. A method of finding out whether a child (or grown-up) is liable to get diphtheria or not.

2. A method of preventing those who are susceptible to diphtheria from ever catching this disease.

How It Works.—The first of these is called the Schick Test. It has been found that there are some children who will never get diphtheria, while others may. In other words, some are immune, while others are not. The purpose of the *Schick test* is to find out whether or not a child is immune to diphtheria, that is, whether he is likely to catch the disease or whether he is not.

This is done by giving the child a tiny injection in the skin of the arm and then watching whether a red spot is to be seen on the arm a few days afterward. By the presence or absence of this spot, the doctor can tell positively which children may get diphtheria and which never will.

If the spot shows that a child may get diphtheria, then it is possible by means of three more injections of a different kind, given about a week apart, to "vaccinate" the child against diphtheria so that he will probably be protected against this disease for the rest of his life.

It Is Absolutely Safe.—One of the fine things about this method of diphtheria vaccination is that children are not made sick by it, as sometimes happens after smallpox vaccination, and often after typhoid vaccination. At the most they may suffer for a day or two from a painful spot in the arm and a slight fever. People who have heard how some of the men in the army suffered after some of the injections they received need have no fear; no child has ever been known to become seriously ill as a result of the Schick injections.

Personal Experiences.—Having heard about this test many physicians, school principals and teachers came to the conclusion that if it is so valuable a protection against this serious disease, it was only their duty that their own children should receive the benefit of the vaccine. They, therefore, had the injections given to them and they stated that they can vouch for the fact that their children did not as a rule feel the slightest illness or inconvenience as a result. They can now be sure that their children will never catch diphtheria from a schoolmate or other person.

For The Good Of The School Kiddies.—Their next thought was what was good for their own youngsters was equally good for the million boys and girls attending the schools in New York City. More especially did they think this when they considered how many of these children were actually falling victims to this

disease. During the nine weeks from Nov. 6 to Dec. 31, 1920, many thousands of school children were sent home because of sore throats which led the school nurse to suspect diphtheria. Of these 3,544 actually developed diphtheria and 211 died from the disease. Then many others had to be kept at home because of diphtheria in the family.

The school authorities have asked the Department of Health to have this test applied free of charge to all those children whose parents would give their consent. The school doctors are ready to extend this great benefit to all the children and will begin to make the test this month.

This Is Your Opportunity.—So we take this occasion to recommend to you in the strongest terms that, when the nurse sends home a slip asking whether you will give your consent in this matter, you will consent to have the *Schick Test* and the immunization performed. Remember that no child will be given these valuable injections without consent of the parent; so don't miss this opportunity. If you are in doubt, ask your doctor who, if you wish, is ready to perform the *Schick Test* himself. The Department of Health gives a certificate of vaccination against diphtheria to each child who exhibits a negative Schick test either before or after receiving the injections. Don't you want your children to hold this certificate? Don't you want to know as a positive fact that they have been protected for good against this dangerous sickness?

And, by the way, the majority of children under five years are susceptible to diphtheria most easily. You can have the Schick Test and injections given to your children who do not attend school by applying at the nearest Baby Health Station or Branch Office of the Bureau of Preventable Diseases.

Inasmuch as the nasopharynx is often the seat of hypertrophied tonsils and adenoids, which predispose to attacks of diphtheria on account of the admirable soil which they furnish for the growth of the Klebs-Loeffler bacilli, it is a wise precaution, as a preventive measure, to have them removed at the proper time (Chapters XLIII, XLVI), but never during any period when the nasopharyngeal tissue is the seat of infection.

Nurses and attendants of diphtheritic patients should make frequent use of sprays or gargles of normal salt solution or dilute alcohol, in order to remove all retained infective secretions. In the throat 1:5000 solution of bichlorid of mercury may have some bactericidal effect, providing care is used not to swallow the fluid.

Hygienic and Dietetic Treatment.—The following rules have been promulgated and enforced by the Health Department of the City of New York:—

Diphtheria is a very catching disease and is carried by the discharge thrown out from the nose, throat and mouth of patients in coughing, sneezing and spitting, or by towels, handkerchiefs, toys, eating utensils, etc., which have been soiled by the discharges from such patients.

To avoid getting this disease you must keep away from patients who have it.

To avoid spreading the disease the sick person must be kept in a well lighted and ventilated room to which no persons are admitted except the doctor, the nurse, or the person who takes care of the patient.

Patients suffering from diphtheria must be quarantined for a minimum period of twelve days, and until two successive cultures taken from the nose and throat, not less than twenty-four hours apart, and examined at the laboratory of the Department of Health, show that diphtheria bacilli are no longer present.

In families where there is a case of diphtheria, the well children must not be allowed in public places to mingle or play with other children.

School children, school teachers, librarians or those who work in nurseries will be excluded from school work until seven days after quarantine is over, and

until a culture from the nose and throat of such persons is found to show an absence of diphtheria bacilli.

Persons engaged in the preparation, manufacture, sale or handling of foodstuffs will be excluded from work until quarantine is ended, and until a culture from the nose and throat does not show the presence of diphtheria bacilli.

Parents and others who are not engaged in the above occupations, may continue at work, except where isolation is not satisfactory.

A placard is placed on the outer door of the apartment, or on the door of the sick room in a private house, boarding house or hotel.

Discharge from the mouth, throat and nose should be received on cloths, gauze or paper handkerchiefs and immediately burned or destroyed. If handkerchiefs are used for this purpose they should be boiled.

Dogs, cats and other pets must be kept out of the sick room.

Bed linen, towels, nightgowns, etc., must be disinfected by soaking in a 2½ per cent. carbolic acid or 2 per cent. lysol solution for one or more hours. This should be done before such articles are removed from the sick room. These articles should then be boiled in soap suds for one-quarter of an hour. The patient should not use handkerchiefs; paper napkins or tissue or toilet paper should be used instead and placed promptly in a paper bag and then destroyed by burning.

Dishes and utensils used by the patients should be kept in the sick room until patient's recovery unless scalded with boiling water before removal.

Milk bottles must not be taken into the sick room. All windows must be screened during the fly season.

Cases occurring in rooms in rear of or connected with a store, will either be removed to the hospital, or the store will be closed and kept under police surveillance until the termination of the case.

No homework, such as tailoring, laundering, manufacturing of cigars, foodstuffs or other merchandise will be permitted in the room or apartment occupied by the family.

The nurse or other person attending to the patient may leave the premises for air or exercise, but must not visit homes or public places where they may come in contact with children.

Upon recovery, the patient should be bathed and the hair washed in warm soap suds, then dressed in clean clothes which have not been kept in the sick room.

Dietetic.—It is of the utmost importance to maintain the tissues of the body by proper food. Any food which may be easily digested and assimilated is admissible to the diphtheritic patient. Peptonized milk stands at the head of the list of nutritive foods for diphtheritic patients. It may be diluted with thoroughly cooked oatmeal, barley, or rice. Older children may occasionally take a raw egg beaten up in milk. Buttermilk and zoolak are nutritive and easily assimilated. Animal broths may be substituted whenever milk is not well borne, or administered as a change of diet. Acid fruits—oranges, grapes, lemons and cranberries—are usually well borne. It is sometimes necessary to resort to rectal feeding where intubation has been performed, and the following formula is recommended: Peptonized milk, 1 ounce; laudanum, 1 cubic millimetre. To this may be added the yolk of a raw egg if desired.

Constitutional Treatment.—The antitoxin treatment of diphtheria has long since passed the stage of experiment, and, therefore, no longer needs defense. It is most effective when administered during the early stages of the disease—that is, before the end of the third day. A favored method of administration is by hypodermic, although it has been made use of per os and per rectum. Hypo-

dermatically, it is now administered by means of a special syringe, the glass barrel of which contains the dose of antitoxin, great care being exercised in sterilizing the syringe, needle, the skin of the patient and the physician's hands. In this manner secondary abscess formations at the seat of the puncture are prevented.

The following (Fig. 289) is a copy of the printed directions and cut of the syringe which is furnished by the health department of the City of New York:—

Fig. 289.—Antitoxin syringe.

Site of Injection.—A portion of the body is generally selected where there is much loose subcutaneous tissue, and the injection made directly under the skin. The region of the back on either side below the scapula and above the border of the ilium offers possibly the best site. The skin should be thoroughly washed with soap and water, afterward with a disinfectant, and last with alcohol.

Directions for Operating Syringe.—After preparing the site on the patient for injection, remove paper wrapping from short end of needle (leaving the long end of the needle wrapped for protection) and force the short end through rubber stopper of the syringe to the hub. Then remove wire and paper wrapping from long end of needle, and, holding the syringe in a perpendicular position with needle *elevated,* expel the air. The syringe is then ready for the operation, all parts of it having been thoroughly sterilized in the laboratory.

The Dose Required.—The dose of antitoxin depends upon the severity of the attack and the age of the patient. Children from one to five years of age usually require a primary dose of from 1500 to 3000 units. Older children should receive from 3000 to 5000 units, and, in unusually severe toxemic cases with extensive pseudomembrane and cervical lymph gland enlargement, an initial dose of 10,000 units may be injected. Visible improvement is indicated by the sloughing of the pseudomembrane, improvement in appearance and appetite, and lower temperature. Whenever no such improvement takes place after from twelve to twenty-four hours, a second but minimum dose should be administered. Free purgation at the commencement of the disease either with castor-oil or calomel is favored.

The antitoxin treatment is more favorable when only the Klebs-Loeffler infection is present. Mixed infections are less amenable to its effects. Marked streptococcemia in addition to general diphtheria creates an unfavorable prognosis, inasmuch as the antitoxin produces no effect upon the streptococcic invasion.

It is important to closely watch the condition of the heart as evinced by the pulse during the course of an attack of diphtheria. Evidences of cardiac weakness may appear at any time. The pulse may be either rapid, irregular, intermittent or unduly slow, the

latter being the most common. At the first sign of heart-failure, all unnecessary exertion on the part of the patient should be interdicted. He should remain in bed and not be allowed to rise for any purpose, and all excitement avoided. The diphtheritic toxins tend to produce a depressing effect upon the heart. Stimulants, therefore, should be commenced upon the first evidence of cardiac weakness. Whiskey and strychnia are the remedies commonly employed for this purpose. They are well borne both by children and adults. From 30 drops to 2 teaspoonfuls of whiskey, and from $\frac{1}{200}$ to $\frac{1}{60}$

Fig. 290.—Method of nasal syringing employed in the contagious cases of the Riverside Hospital. *(Fischer.)*

of a grain of strychnia, according to the patient's age, is the proper dosage. Tokay wine, champagne and coffee are often well borne.

Treatment of the postdiphtheritic paralysis consists in the administration of small doses of strychnia, forced nutrition and moderate exercise in the open air. This form of paralysis is self-limited, but a cure is hastened by these measures. Nephritis and cardiac complications should receive the skilled treatment of internal medicine practitioners.

Local Treatment. (*a*) *Nasal Diphtheria.*—In addition to measures employed for the general elimination of the toxic elements of the disease through the bowels, kidneys, and skin, local measures prove most beneficial. It is important to remove all surplus secretion from the nasal cavity at frequent intervals, for the purpose of

maintaining nasal respiration, and, further, to remove all retained toxic elements, which are commonly associated with the Klebs-Loeffler bacillus in the nasal cavity. The diphtheritic membrane is not easily removed, and undue force should never be employed for this purpose. Whenever it is thought necessary to remove the accumulated exudate from the nose it should be done by means of the douche bag in the following manner (Fig. 290) :—

The child is first wrapped in a blanket with the arms so pinned that struggle is impossible, and is then laid upon the side with the head slightly lower than the body. Employing a 2-quart fountain syringe with a glass or hard-rubber nozzle and filled with a normal

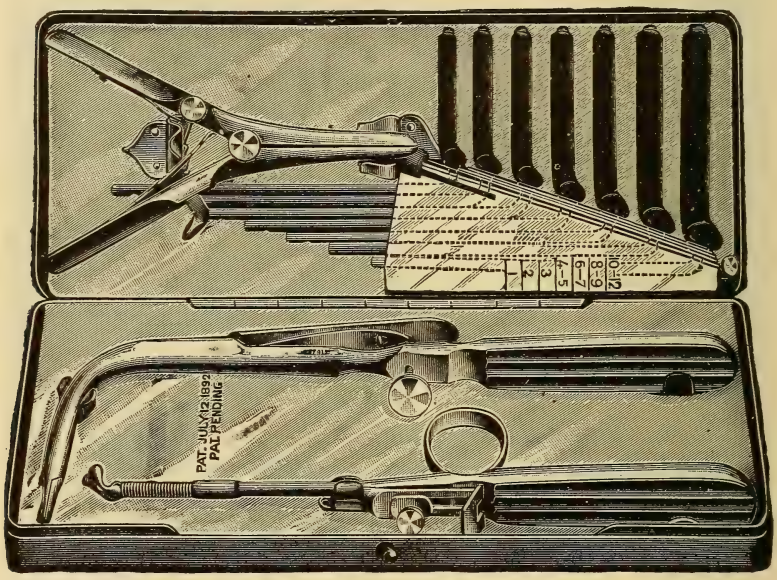

Fig. 291.—O'Dwyer's set of intubation instruments.

salt solution, or ½ per cent. solution of permanganate of potash, at about 115° temperature, the upper nostril is thoroughly washed, by raising the bag from 1 to 5 feet above the child's head. Following this suggestion in detail, the solution, instead of running into the nasopharynx, flows out through the opposite nostril. The procedure is then repeated upon the opposite side, after reversing the position of the child. In severe cases the nasal cavities should be douched from four to eight times a day. Unless previously trained to the use of sprays, the child will rebel during the first few treatments, but finally submits with good grace.

(*b*) *Pharyngeal Diphtheria.*—The forcible removal of the diphtheritic membrane from the oropharynx is a harmful measure. In all cases, especially the severe types which are characterized by extensive exudate with retained secretions and mixed infection,

much relief is obtained by washing the surfaces with hot saline solution. Here, also, the douche is more efficacious than the spray or gargle. The same solutions may be employed and in the same manner as shown in the previous paragraph and illustrated in Fig. 290, except that the mouth should be widely opened and the fluid allowed to thoroughly wash the oropharyngeal surfaces. A tractable child, lying on the side with the mouth wide open, often even without the aid of a tongue depressor, submits to thorough washing of the oropharynx by the above method.

In the treatment of obstreperous patients, who resist all efforts to douche or swab the throat, it is wiser to abandon these local measures than to persist at the expense of exhaustion or undue strain upon the heart. Of the so-called solvents of the diphtheritic membrane none have any marked effect. There seems to be some efficacy in steaming the nose and nasopharynx with a 2 per cent. sulphurous acid solution.

Fig. 292.—The mummy bandage, showing child in proper position for the dorsal method of intubation. All instruments required are carefully arranged. *(Fischer.)*

It is generally conceded that the local measures above described, whereby the septic secretions are promptly removed from the nose and nasopharynx, serve to minimize the tendency to toxemia and to lymphadenitis.

(*c*) *Laryngeal Type.*—At the onset of an attack of laryngeal diphtheria the patient should be subjected to the continuous use of steam inhalations by being placed under a tent erected over the bed or cot, underneath which a croup kettle is kept boiling. Marked relief is sometimes obtained by fumigating 10 grains of calomel underneath the tent. Emetics are to be avoided when the heart action is weak. In mild cases which are early submitted to the antitoxin and steam inhalation treatment the membrane exfoliates without serious symptoms of obstructed respiration.

The early administration of antitoxin has largely reduced the mortality from laryngeal diphtheria, and minimized the proportion of cases requiring intubation or tracheotomy. For the relief of laryngeal stenosis induced by diphtheria, intubation as devised by

the late Joseph O'Dwyer has largely superseded tracheotomy, the latter being employed only when intubation tubes are not at hand, when the laryngeal edema is widespread, and in cases of membranous exudate in the lower tracheal tract.

Intubation.—Intubation is employed for the relief of laryngeal stenosis, the chief symptoms of which are obstructed breathing, cyanosis, retraction at the clavicles and epigastrium, and failing pulse. The indications for intubation according to O'Dwyer are "marked by a more or less sinking in of the yielding portions of the chest, lower ribs and sternum, episternal notch and supraclavicular

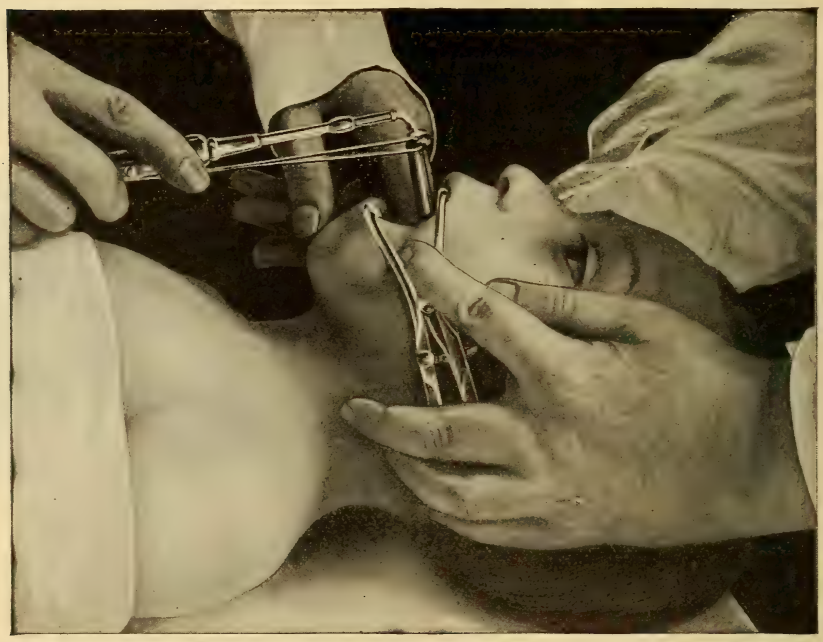

Fig. 293.—Intubation. First step. Index finger raising the tip of the epiglottis. The tube guided along the finger. Original. (*Fischer.*)

regions during inspiration. Recessions at the root of the neck are more significant than those below, as violent contractions of the diaphragm aid in drawing in the free border of the ribs and sternum." "Abiding cyanosis is too late a symptom to wait for." "Children sometimes remain long in one position when suffering severely from want of breath, and continued restlessness, if consciousness be unimpaired is, therefore, an important indication that it is time to afford relief."

O'Dwyer's set of intubation tubes (see Fig. 291) and accessories are necessary for the performance of intubation, the sizes of the intubation tubes being given according to a scale of ages. The operation is performed either by the dorsal method or upright

method, the former being employed by the attendants at the Willard Parker Hospital, of New York City. The dorsal method of intubation possesses the advantage of requiring less assistance, and at the same time being more available in emergencies.

The child is placed flat upon the back (Fig. 292), the arms and legs being firmly held in place by wrapping in a blanket. A mouth gag is inserted between the jaws on the left side, and the nurse holds the head firmly. The operator stands upon the patient's right

Fig. 294.—Intubation. The tube passing the epiglottis. Entering the larynx. Original. (*Fischer.*)

side and introduces the left forefinger until able to elevate and fix the epiglottis (Fig. 293). It now becomes a simple procedure to introduce the tube with the right hand and insert it into the interior of the larynx (Fig. 294). A partial description quoted from O'Dwyer's method in the upright position is herewith appended. The nurse is seated on a low, straight-backed chair, and the patient's arms secured to his side by a sheet passed around the body. He is placed on the lap, with the head resting on the left shoulder of the nurse. The gag is then inserted well back between the teeth and the left angle of the mouth and opened widely. An assistant stands behind the patient and holds the head firmly by

placing one hand at either side, and at the same time slightly elevates the chin. The operator stands in front of the patient, holding the introducer in the right hand, the thumb resting just behind the knob that serves to detach the tube. The index finger of the left hand is carried well down in the pharynx in a median line, raising and fixing the epiglottis, while the tube is carried along the side into the larynx. The distal extremity of the tube should be kept in contact with the finger and even striking it a little obliquely toward the right side of the larynx if necessary to get inside the left aryepiglottic fold, especially in young children. As

Fig. 295.—Casselberry method of feeding. *(Fischer.)*

soon as the cannula is inserted, the introducer, with obturator attached, is withdrawn by pressing forward the button on the upper surface while counterpressure is made with the index finger on the trigger beneath. To prevent the tube from being also withdrawn the left finger must be kept in contact with its left shoulder. The tube should be carried well down in the larynx before detaching. The gag is removed as soon as the tube is in place, but the string is allowed to remain in place until certain that dyspnea is relieved. In removing the string the finger must be reinserted to hold the tube down. A characteristic cough follows immediately whenever the tube has been properly inserted, and during the paroxysm mucus and mucopus are freely expelled. The most marked indica-

tion that the tube has been properly inserted is found in the almost instantaneous relief of all symptoms of stenosis.

The introduction of the tube should invariably be performed without the employment of any force whatever. Quick intubation requires that the operator make certain of the position of the epiglottis, hold the tube exactly in the median line, and bear in mind the difficulties it must overcome in order to reach the larynx.

The most common accident during intubation is the introduction of the tube into the esophagus. Cases also have been reported

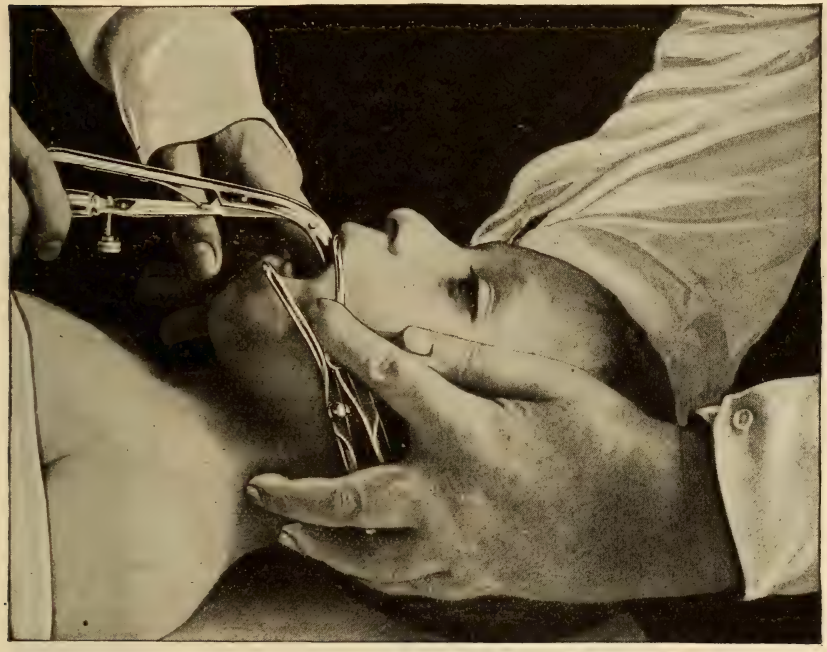

Fig. 296.—Extubation. First step. Gag in position. Extractor is guided along the left index finger until the beak enters the lumen of the tube. Original. (*Fischer.*)

wherein the membrane was pushed downward by the tube without relief of the stenosis, requiring a reintroduction.

The American Pediatric Society's collective investigations show a mortality of 21 per cent. in laryngeal diphtheria or croup, and 27.24 per cent. in intubated cases combined with antitoxin.

Intubation in Chronic Stenosis.—It is proper here to mention the uses of intubation for chronic stenosis and for laryngeal papillomata. O'Dwyer mentions the use of intubation in chronic stenosis: 1, for cicatricial stenosis due to injury from syphilis and traumatism; 2, narrowing of the space both below and above the vocal bands from the products of inflammation—simple, tuberculous, specific, malignant, hypertrophic, and pachydermia laryngis; 3, for

the cure of granulations resulting from long-continued wearing of a tracheal cannula; 4, in papillomata of the larynx; 5, deformities of the larynx from injury or disease; 6, ankylosis of the cricoarytenoid articulation, and arthritis deformans of the same part; 7, aphonia spastica.

After the introduction of the tube the child should be returned to bed and the steam inhalations continued. As the membrane separates and the swelling of the mucosa subsides, the tube is prone to loosen and become expelled during coughing. Should the tube

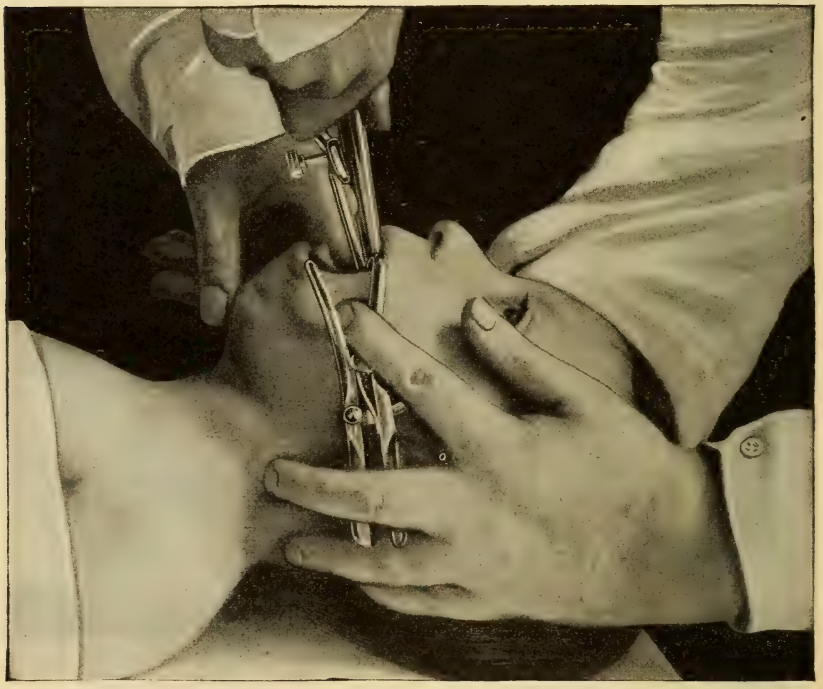

Fig. 297.—Extubation. Second step. The beak of the extractor holding the tube firmly; the operator withdraws the tube. Original. (*Fischer.*)

slip downward into the trachea an immediate tracheotomy becomes necessary, through which the tube is easily removed.

Feeding after Intubation.—Several plans have been devised by clinical observers for feeding children who have been intubated on account of the discomfort arising from the liability of liquids to enter the trachea. Whenever possible mouth feeding is preferable, and semisolid food like custard, junket, milk toast, cornstarch, rice pudding, soft-boiled eggs, concentrated broths, jellies, water ices and ice-cream may be administered. Gavage and rectal feeding are extremely distasteful to most patients. The Casselberry method (Fig. 295) is usually employed.

Extubation.—About six days after the onset of the laryngeal obstruction, providing respiration has been free during the preceding two days, it is generally safe to remove the tube. Never, however, without watching the patient for at least an hour after extubating, inasmuch as the laryngeal mucosa sometimes swells sufficiently to demand reintubation. A case occurred in the Willard Parker Hospital where a tube was reintroduced forty times during the course of the disease.

To extubate, the patient is prepared precisely as for intubation. The left finger is introduced until it comes in contact with the tube. The extubator, held in the right hand, is guided along the finger until its beak enters the lumen of the tube (Fig. 296). Firm pressure is then made on the lever of the extubator, with the right thumb and the tube lifted upward about one inch and then carefully withdrawn from the throat (Fig. 297).

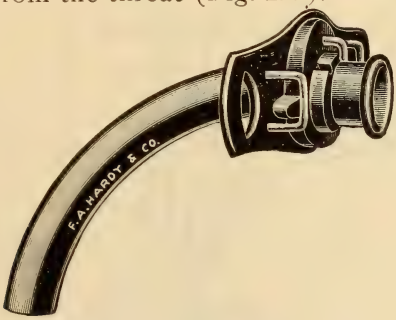

Fig. 298.—A tracheotomy tube.

Tracheotomy.—Whenever the obstruction to the respiration is below the larynx or above the level of the cords, or becomes so great within the larynx itself that the tube cannot be introduced, tracheotomy furnishes the only means of relief. Cases of this type are invariably severe and many fatalities from bronchopneumonia or toxemia are recorded.

The indications having been heretofore defined, the operation is performed as follows: Jackson advocates the Schleich infiltration anesthesia with the patient in the Trendelenburg position, which position should be maintained for twenty-four hours subsequent to the operation.

The high tracheotomy operation is preferable to the trachéotomie inférieur of Trousseau, the hemorrhage in the former being much less. In performing high tracheotomy the usual aseptic precautions should be maintained in all particulars. After locating the cricoid cartilage with the fingers of the left hand the entire larynx is held firmly while the skin and subcutaneous tissues are incised in the median line down to the outer surface of the trachea. If time permits all bleeding points should now be ligatured before opening the trachea. Whenever suffocation is imminent the hemorrhage may be partially controlled by the pressure of retractors.

Incision is now made through the two or three upper rings of the trachea. The aperture is held open, either by means of the dilator or by the introduction of a heavy probe or elevator, and the cannula (Fig. 298) slipped into position. Proper introduction of the cannula immediately causes a characteristic reflex cough, which forces quantities of blood and other secretions through the tube, and suffocation is at once relieved (Fig. 299). The cannula is now carefully secured by tapes tied around the patient's neck.

There are certain difficulties which attend the operation of tracheotomy, the chief of which are hemorrhage, a too small incision, asphyxiation either from obstruction to the cannula or dis-

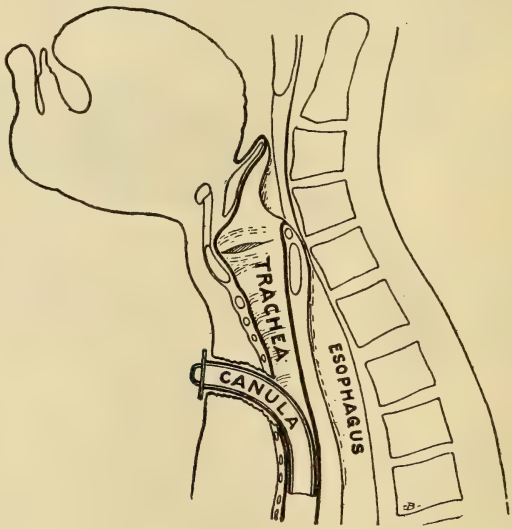

Fig. 299.—Lateral view of the tracheotomy tube in position.

lodged membrane, and numerous complications in the form of infection of the tracheal wound, septic pneumonia, ulcerations of the trachea, and erysipelas are sometimes observed. Incidentally, the tracheotomy tubes commonly sold are too short for adults; therefore, the surgeon should keep the larger sizes and shapes on hand.

After-treatment.—The surfaces around the tracheal wound should be lightly packed with sterile gauze, the patient placed in bed with the head lowered, and one or two layers of thin gauze placed over the opening of the tube. The inner cannula should be removed every two or three hours and thoroughly cleansed in carbolic solution. Steam inhalations are soothing and tend to prevent bronchial complications. Whenever performed for diphtheria under antitoxin treatment, it is not usually necessary to wear the tube longer than from three to five days, after which it may be removed and the wound allowed to heal.

Sequelæ as Affecting the Ear, Nose and Throat.

Paralysis of the Soft Palate.—The occurrence of faucial paralysis before the separation of the diphtheritic membrane, due to involvement of the deeper tissues, renders the prognosis unfavorable. Postdiphtheritic paralysis is self-limited, but is prone to extend over a large portion of the muscular system. Whenever the soft palate is the seat of paralysis, the patient swallows with difficulty and fluids tend to regurgitate through the nose. There is also a peculiar nasal character to the voice. It is sometimes necessary to feed by gavage for a short time. The duration of postdiphtheritic paralysis ranges from three weeks to six months, after which it gradually disappears. Chronic rhinitis and diseased adenoids and tonsils are among the sequelæ of diphtheria.

SCARLATINA.

I. THE EAR.

Acute purulent otitis media is the most common complication of scarlatina. The younger the child the greater the frequency of otitic involvement. This is probably due to the anatomical formation of the Eustachian tube in young children. It occurs more frequently when the mucosa of the nose and throat is severely involved, and the infection extends through the Eustachian tube from the pharynx. Generally, both ears are affected. About 12 per cent. of all cases of chronic purulent otitis media are the result of scarlet fever. In 185 cases of scarlatinal acute purulent otitis media Bezold found:—

In 30 entire destruction of the membrana tympani, with the loss of one or more ossicles.
In 59 the perforations comprised two-thirds or more of the membrane.
In 13 there were small perforations.
In 44 there were granulations or polypi.
In 15 there was total loss of hearing on one side.
In 6 there was total loss of hearing on both sides.
In 77 the hearing distance for low voice was less than 20 inches.

Mastoiditis is not common in simple scarlatina, but is comparatively frequent whenever the scarlatinal infection is mixed with diphtheria, measles, or other infections. Duel in his report of 6000 cases found mastoiditis in two cases of uncomplicated scarlatina, 20 in combined scarlet fever and diphtheria, and 2 in combined scarlatina, diphtheria, and measles.

MacCullum in a study of 5000 cases of scarlet fever found mastoiditis in $^{8}/_{100}$ of 1 per cent. The author believes it to occur more frequently, that it is often unobserved, and that a timely mastoid operation would lower the percentage of chronic purulent cases and conserve the hearing function. MacCullum further found that a combination of two exanthemata produced middle-ear suppuration in 50 per cent., with a marked tendency to be bilateral and

to extend to the mastoid. Scarlatina causes more cases of deafness and deaf-mutism than any other disease of childhood, 10 per cent., according to May, being due to this cause. The occurrence of middle-ear inflammation in scarlatina has been reported as follows:—

Downie	12.6 %	
Finlayson	10 "	out of 4339 cases.
Caiger	11 "	" " " 4015 "
MacCullum	18 "	" " " 5000 "
Duel	20 "	" " " 6000 "
Burckhart	33 "	of his cases.
Fischer	20 "	out of 397 "

Purulent otitis media may occur as early as the fourth day of the disease or as late as the fortieth.

Symptoms.—The symptoms are similar to those observed in purulent otitis from other causes (Chapter XVIII). In all cases of scarlet fever the ears should be carefully inspected daily. Pain in the ear, rise of temperature, and inflammation and bulging of the drum membrane serve to establish a diagnosis. Purulent otitis media is more likely to develop at the height of the nasopharyngeal process. There is great destruction of the drum membrane, due to coagulation necrosis caused by the toxins. Suppuration is prone to be protracted unless an early incision of the drum membrane is made and persistent local treatment maintained. Residual perforations nearly always remain. If the otorrhea becomes chronic the process is characterized by odor, deafness, and the development of polypi, granulations and bone necrosis. Deafness during the attack is considerable, but this improves as the inflammation subsides. Otitis interna from panotitis, or involvement of the auditory nerve or cochlea, may occur.

Prognosis.—In simple scarlatinal otitis, when skillfully treated, the prognosis is favorable. When the infection is mixed and the disease is unduly septic, or when it occurs in weakened children who have adenoids, the otorrhea is liable to become chronic, the hearing impaired or lost, and mastoid, labyrinthine, and cerebral complications may occur. Prompt and vigorous treatment (Chapter XVIII) favorably affects the prognosis.

II. THE NOSE.

The nasal manifestations of scarlatina are chiefly a slight rhinitis with coryza, and, occasionally, epistaxis. In severe types there is extensive ulceration of the turbinals and septum, and involvement of the accessory sinuses. Adhesions between the turbinals and septum may result from the ulcerative process.

III. THE OROPHARYNX.

During the first twenty-four hours the mucous membrane shows a fine vivid red erythema, which consists of minute red points on the hard palate, except in the mildest cases. The tonsils are

sometimes covered with a tenacious grayish membrane, of streptococcic origin (unless the case be one of double infection with diphtheria). In moderate cases the tonsils are inflamed as in follicular tonsillitis, the membrane being easily detached from the crypts. The diphtheritic form generally occurs later in the disease, after the fever has disappeared. In very severe forms this membrane may extend over the entire fauces and into the nose, middle ear, larynx, etc. The color varies from grayish, or greenish, to black (gangrenous). To differentiate this form from diphtheria requires the art of bacteriology. Gangrenous angina may be present from the start, or be preceded by a grayish membrane which sloughs. Cervical adenitis is common.

IV. THE LARYNX.

Acute laryngitis may accompany any attack of scarlatina, and edema of the larynx, in the extremely congestive type, sometimes occurs.

TREATMENT OF THE EAR, NOSE AND THROAT.

In all cases of scarlatina wherein the nose and nasopharynx become filled with secretions they should be irrigated with hot normal salt solution as in diphtheria (Fig. 290), the frequency being governed by the severity of the process. Vigorous blowing of the nose should be avoided, inasmuch as the act is liable to force infection into the Eustachian tube. At the onset of an attack of purulent otitis media the drum membrane should be incised (Fig. 55), and the ear otherwise treated in the manner described in Chapter XVIII. The occurrence of mastoiditis of scarlatinal origin calls for an early mastoid operation.

MEASLES.

Ear Complications.—The aural complications of measles are chiefly confined to the purulent and catarrhal forms of otitis media.

The Eustachian tube is the usual pathway of infection, but Richardson and others have demonstrated that the infection may reach the tympanum through the blood-vessels and lymphatics.

The tympanic cavity probably contains either a serous or purulent exudate in from 70 to 90 per cent. of cases of measles. Weiss found the membrana tympani inflamed in 50 per cent. of all children affected with measles.

An attack of acute purulent otitis media, when complicating measles, usually starts soon after the beginning of the disease, and only rarely is a late manifestation.

Tobeitz contends that in measles we are dealing with a primary exanthematous affection of the middle ear. That ear complications are common is proven by statistical reports. Out of 501 cases of measles observed by Downie in the Children's Hospital, Glasgow, otitis media purulenta acuta occurred in 26.1 per cent. In 1000 cases of measles MacCullum found 24 per cent. of otitis media

purulenta acuta. Mastoiditis is more common in measles than in scarlatina, is prone to be quick in developing and severe in type. The invasion is usually so rapid and the symptoms so profound that it becomes imperative to perform the mastoid operation without delay. Moreover, it is justifiable to operate early on account of the severity of the infection. Bilateral middle-ear infection and bilateral mastoiditis are extremely common in measles.

Tobeitz found middle-ear complications in 86 per cent. of all fatal cases of measles, and Bezold found ear disease in 17 out of 18 fatal cases of measles.

Nose Complications.—Acute coryza is characteristic of the initial stage of measles, and the discharge is at first mucoid, later mucopurulent or purulent. Sometimes there is epistaxis. The inflammatory engorgement of the nasal mucosa produces great discomfort to the patient, and nasal respiration is proportionately obstructed. Headache is common and the accessory sinuses sometimes become involved sufficiently to induce severe pain and a sensation of pressure. Ulceration and adhesions result in the severer cases. The inflammatory process is prone to extend to the Eustachian tube, where it causes obstruction and consequent rarefaction in the tympanum, which in turn induces tympanic effusion; or infection enters the tympanum, where it induces purulent otitis media.

Mouth and Pharynx Complications.—"Small, irregular, rose-colored spots with a very minute bluish speck just large enough to be visible in the centre of the rose area," as described by Koplik, are seen upon the mucous membrane inside the cheek during the first day of the attack in over 80 per cent. of cases.

The pharyngeal mucosa is inflamed. Blotchy areas of congestion similar to the eruption on the skin, some of which are even purpuric, develop upon the palate.

Follicular tonsillitis is common, but streptococcic membrane formation rarely occurs. The lymphoid tissue in the vault of the pharynx and the faucial tonsils becomes swollen from the irritation of the nasal discharge.

Postmortems on cases of measles show inflammation and infiltration of adenoid tissue in the nasopharynx and pharynx.

Laryngeal Complications.—Simple acute laryngitis is usually present at the outset of the disease. The voice is hoarse and a dry cough persists. The process may be so severe as to produce edema and ulcerations. Bronchitis is almost invariably present, and pneumonia is an occasional complication.

Local Treatment.—The preventive treatment of ear complications is conducted by the employment of soothing and cleansing local medication to the mucosa of the nose and throat during the stage of coryza. A spray of alkaline solution or of normal salt solution, to either of which sufficient adrenalin may be added to make the solution 1 : 10,000, used every two hours serves to wash away retained secretions and to reduce the swelling in the nose and about the Eustachian tube. In this manner tubal obstruction

and its consequences may be avoided. Even when a slight collection of serous or seromucous fluid has collected in the middle ear no operative interference is necessary so long as no bulging of the membrana tympani occurs, and the treatment must be directed to the Eustachian tube by inflation after thorough cleansing of the nose and nasopharynx. In purulent cases with severe pain and bulging of the drumhead early paracentesis and local treatment the same as for otitis media purulenta acuta should be followed.

Rubeola (Rubella; German Measles); Rötheln.—Corlett describes rubeola or rubella as "a mild form of infection which always follows a benignant course and first appears as a general or constitutional disease, accompanied by a slight run of temperature and slight feeling of illness."

It is an affection characterized by a pinkish rash which appears first upon the face and scalp and gradually extends downward over the entire body, moderate rise of temperature and desquamation. Moderate coryza and suffusion of the eyes generally precede the appearance of the eruption, and sneezing may or may not be present. The throat symptoms consist in moderate swelling of the pharynx and tonsils and slight cough. No eruption appears upon the buccal mucous membranes. According to Thierfelder, swelling of the subauricular and superior jugular lymphatic glands is a constant prodromal symptom, and Atkinson states that enlargement of the superficial lymphatic glands of the neck may be the most striking symptom. The disease runs a mild course, the prognosis is good, and no specific treatment is necessary. The patient should remain in bed until the fever and eruption subside; the diet should be light and mild cathartics administered.

CHAPTER XXXII.

THE INFLUENCE OF GENERAL DISEASES UPON THE EAR, NOSE AND THROAT.

(*Continued.*)

TYPHOID FEVER.

THE principal typhoid lesions found in the upper respiratory tract are active hyperemia with slight erosions of the mucous membrane, which sometimes permit the entrance of other organisms, deep ulcers, perichondritis, ulceration of the adenoid tissue similar to that of Peyer's patches, and middle-ear inflammation.

Ear.—The mechanical (catarrhal) type is the most common aural complication of typhoid fever, but acute purulent otitis media occurs in from 2 to 3 per cent. of cases. In 579 cases of typhoid fever observed by McCaw acute purulent otitis media occurred in 29. Four of this number developed mastoiditis, with two deaths. Day reports one fatal case of typhoid mastoiditis in which infection was due to embolism.

There is a greater destruction of the membrana tympani than in ordinary purulent otitis, and the perforations are often double or multiple (Figs. 174 and 175). Mastoiditis is rare, but invariably severe in this type, with a large percentage of fatalities, as shown by reports of Day and McCaw.

Hemorrhage into the labyrinth is a rare complication, but occurs as often in typhoid as in any other infectious disease.

Nose.—Epistaxis is an early and common symptom of typhoid fever. It is observed in about 20 per cent. of typhoid cases. During the later stages crusts are prone to form upon the nasal mucosa, which are picked by the semiconscious patient until ulcers are produced. The septal cartilage may thus become perforated.

Mouth and Pharynx.—In severe or neglected cases of typhoid fever the tongue becomes dry, glazed or fissured and the lips ulcerated from continued picking by the patient. Clean-cut superficial ulcers on the soft palate and pharynx are occasional complications.

Anders mentions patchy whitish elevations on the tonsils, which ulcerate.

Larynx.—Superficial laryngeal inflammation is present in a large proportion of typhoid cases. There is a tendency to deep ulceration in typhoid laryngitis, due to metastatic thrombosis or to ordinary pus bacteria. The trachea is occasionally the seat of ulceration.

In an exhaustive study of 360 cases of typhoid by Jackson[1] the following laryngeal complications were found:—

[1] Transactions of the American Laryngological, Rhinological, and Otological Society, 1905, p. 223.

Number examined	360	Cases.	
Ulcerative laryngitis in	68	"	(18.9%)
Started as abscess of larynx in	4	"	(5.9%)
Required tracheotomy	8	"	(11.8%)
Perichondritis with necrosis in	6	"	(8.8%)
Perichondritis without necrosis in	11	"	(16.2%)
Abscess from perforation in	2	"	(3.0%)
Ulcerative tracheitis in	9	"	(13.2%)
Ulcerative tracheitis with perforation and emphysema in	1	Case.	(1.5%)
Ulcerative tracheitis with abscess of the thyroid glands	1	"	(1.5%)
Pus foci in remote locations in	15	Cases.	(22.0%)
Associated with acute purulent otitis media	11	"	(16.2%)
Associated with leukophlegmasia	6	"	(8.8%)
Died	4	"	(5.9%)

These ulcerations were located as follows:—

Epiglottis	42	Anterior commissure	4
Aryepiglottidean	22	Infraglottic region	3
Interarytenoid space	18	Trachea	4
Arytenoids	10	Bifurcation	2
Ventricular bands	7	Bronchi	2
Ventricle	5	Vocal bands	1

Typhoid laryngeal ulceration is rarely observed prior to the twenty-first day of the disease. In postmortems on typhoid patients in 61 cases there were 14 with ulceration in the larynx (St. Bartholomew's Hospital report); in 113 autopsies, 20 with ulceration and perichondritis (Vincent); in 6513 cases, 439 deaths, ulcer in 30 per cent. (Onskow); in 2000 autopsies, 107 ulcerative laryngitis cases (Munich).

General Remarks on Treatment.—From the commencement of the disease the nose, mouth, and oropharynx should be cleansed at frequent intervals; the fountain syringe filled with hot normal salt solution, as recommended in diphtheria (Fig. 290), is a convenient method. The teeth should be brushed twice daily with a good dental powder, and the gums and tongue swabbed with a ½ per cent. solution of carbolic acid or a saturated solution of boric acid. The nose, throat, and larynx may also be sprayed with a 2 per cent. solution of camphor and menthol in benzoinol. Intratracheal injections of the same formula bring great relief. Medicated steam inhalations are soothing to the mucous membrane.

Mild laryngeal edema may be controlled by sprays or intratracheal injections of adrenalin solution 1 : 5000. Symptoms of stenosis require tacheotomy or intubation, the latter being without efficacy in laryngeal edema and adductor paralysis. Early tracheotomy (see page 467), performed under local anesthesia (Schleich's solution), is advisable as soon as respiration becomes seriously impeded. The remarkable success attending the use of vaccine for the prevention of typhoid fever is worthy of note in relation to its value as an eliminator of the above-described serious complications.

TYPHUS FEVER.

At the time of an attack of typhus fever the dorsum of the tongue becomes brown and fissured. In severe cases gangrene of the nose, cancrum oris, and abscess of the parotid gland may develop. Noma of the auricle is a rare complication and originates in the cartilaginous meatus.

PERTUSSIS (WHOOPING-COUGH.)

During the course of pertussis ulcerations sometimes develop upon the under surface of the tongue as a result of trauma. During the early stages of the disease some rhinitis is present. Epistaxis may appear as a complication, and is induced by the train of the paroxysms of coughing upon the hyperdilated anterior septal vessels. Patients in advanced life who suffer from pertussis sometimes develop labyrinthine hypertrophy, congestion or hemorrhage. Submucous hemorrhage in the palate, tonsils, or pharynx, granular pharyngitis, and congestion and hemorrhage of the larynx are among the complications of the disease. According to Gottstein, edema of the larynx is quite common.

EPIDEMIC PAROTITIS (MUMPS).

During the active stage of an attack of epidemic parotitis, especially when bilateral, patients experience considerable difficulty in opening the mouth for speech or deglutition. The orifices of Stenson's ducts opposite the second upper molar teeth may show come congestion, with increased or decreased flow of saliva. Rarely the parotid gland suppurates or becomes gangrenous. There may be otalgia, or very rarely otitis interna, with deafness, the anatomical explanation of this being still problematical. Rarely an otitis media purulenta acuta develops during convalescence. Labyrinthine hemorrhage is a rare complication. (Toynbee.) Urbantschitsch (1906) reports a case in a twelve-year-old deaf-mute. It is usually accompanied by tinnitus, vertigo, nausea, and frontal or occipital pain. The following typical case is reported from the author's case book:—

Case IV. F. W., male, aged eighteen years, consulted me on April 2, 1912, with the following history: On January 2, 1912, he had suffered from an attack of mumps of extreme severity. During the early stage he had fainting spells and his family physician had told his mother that the pancreas was evidently involved. Two weeks from the onset of the attack he became extremely dizzy and complained of excessive tinnitus in the right ear. Three days later he became completely deaf in the right ear, and his family physician stated that the eyes were slightly fixed toward the right side. For four days during this time he was almost entirely unconscious; the vertigo remained severe, and continued for over two weeks. During the four severest days forced feeding became necessary. There was no abscess. He gradually improved and the vertigo finally disappeared, but his hearing remained *nil*. A sister contracted the disease from him and her attack was followed by a double ovaritis, and for a period of one week she had double vision.

At the time of my examination the patient had entirely lost the hearing of his right ear, both air and bone conduction being destroyed, as proved by the employment of the noise producer. The semicircular canals had evidently somewhat improved, but the nystagmus upon irritation of the right side lasted less than two-thirds of that upon the left side. He was examined on January 4, 1913. He is still completely deaf to all sound in his right ear, but the vestibule upon the affected side is now irritable.

SMALL-POX.

Briefly stated, the ear, nose, and throat complications of small-pox are inflammation, swelling, edema, and hemorrhage of the mucous membranes, edema of the glottis, ulceration of the larynx, and purulent otitis media. They are not constant, and the ordinary methods of treatment for similar conditions may be adopted.

INFLUENZA.

Influenza usually attacks the entire upper respiratory tract, often extending to the middle ear. The invasion is bacterial and is characterized by pain, rise in temperature, depression, and exhaustion.

The recent epidemic of so-called Spanish Influenza, ran its course in America, chiefly from September 1918 to February 1919. But for the history of influenzal epidemics dating back to 1137 the recent visitation might have been considered unusual in that the chief complication was pneumonia, in its most malignant form. It is also to be noted that the general experience of laryngologists and otologists showed only a moderate tendency to aural complications. This, of course, is contrary to the history of this affection in influenzal epidemics of recent years. Dench, in the New York State Medical Journal of July, 1919, page 265, quotes statistics from St. Luke's Hospital, covering 882 cases of influenza from September 28, 1918, to March 31, 1919. Of these, sixteen developed acute purulent otitis media, eventuating in six mastoid operations, or a little over one tenth of one per cent. He further states that in the entire hospital during that period, from all sources, only twenty-four mastoid operations were performed, while during the same period 1917 to 1918, in the same hospital, thirty-four mastoid operations were performed, showing conclusively that during the recent epidemic, aural complications were less than has been observed in recent years. It has been the experience of the author that the same holds true of influenzal invasion of the nasal accessory sinuses. This experience is borne out by careful statistics reported from the various army camps in the United States. Epistaxis, during the onset was fairly common. Several cases of purulent pansinusitis, double mastoiditis and meningitis have been reported, but these are rare exceptions.

Ear.—In some epidemics the disease manifests a strong predilection to attack the middle ear by extension from the nasopharynx through the Eustachian tube. It is extremely violent and rapid in its course; mastoiditis and serious intranasal involvement are common. Kerley reports (1905) that 58 out of 77 cases of otitis media purulenta acuta in children were caused by influenza. The exudate from the perforated drumhead during the early stages is usually hemorrhagic and fibrinous in character, after which it becomes entirely purulent.

Pain.—Pain is severe and often persists several days after the perforation of the drumhead. The invasion of the middle ear is usually streptococcic; hence the severity of the symptoms and the large proportion of mastoid and other complications. In severe types there is rapid destruction of both soft tissue and bone.

Cheatle has observed that, when influenza mastoiditis occurs in individuals who have but slight development of mastoid cells, and mastoid antra which are surrounded with dense impervious walls, there is grave danger of the infection forcing its way through the thin posterior antral wall to the posterior cranial fossa, or through the thin roof (tegmen antra) to the middle cranial fossa, thus producing meningitis, brain abscess or sinus-thrombosis. Influenza occurring in those who have chronic purulent otitis media produces fresh infection with all the symptoms of the acute attack.

Treatment.—For the general treatment of influenza the reader is referred to works on general medicine.

On account of the virulency and rapidity of the purulent process when occurring in the middle ear, it becomes imperative that an incision of the drum membrane be made as soon as the diagnosis is estab-

lished, and further treatment carried out exactly as described for purulent otitis media (Chapter XVIII).

Nose.—Acute rhinitis due to influenza is fully described in Chapter XXXIII.

Mouth and Throat.—Acute pharyngitis and simple acute and lacunar tonsillitis are commonly associated with influenza. The mucous membranes become intensely congested and the lymphoid tissue markedly swollen. Cultures from the tonsil contain mixed influenza bacilli, streptococci, etc. The cervical lymph glands are usually much swollen, and when they suppurate the secretion invariably contains streptococci. It is possible that those which do not suppurate contain only the influenza bacillus or other pus bacteria, not streptococci.

Larnyx.—Various grades of laryngitis accompany the upper respiratory type of influenza. Hemorrhagic laryngitis is frequently observed, and in rare instances edema and ulcerative processes occur.

Various sequelæ result from influenza, and they are due to peripheral neuritis. Anosmia and parosmia are common. Paralysis of the soft palate, paralysis of the vocal cords, abductor paralysis, both unilateral and bilateral, may occur early during convalescence.

EPIDEMIC CEREBROSPINAL MENINGITIS.

In cerebrospinal meningitis coryza is usually present, and according to Finkelstein the meningococcus is always present in the nasal discharges.

Ear.—The ear is occasionally the seat of a complicating otitis media purulenta, but the chief lesion is labyrinthine effusion (Chapter XXVIII), which usually results in permanent deafness and mutism.

ENCEPHALITIS LETHARGICA.

During recent years the author has observed several cases of acute purulent otitis media and mastoiditis as a complication of encephalitis lethargica. These cases have caused considerable concern until the exact diagnosis could be made, for the reason that a purulent meningitis directly from the ear was in every instance suspected. In one case a double mastoiditis developed simultaneously with the encephalitis lethargica. The latter being extremely mild in type. The bacteriological examination of the pus from the ear in all these cases showed streptococci as the invading organism.

LOBAR PNEUMONIA.

In young children acute purulent otitis media may complicate lobar pneumonia, especially when the nasopharynx is inflamed. Craiger reports 125 cases of otitis media purulenta acuta out of 1000 cases of lobar pneumonia.

ERYSIPELAS.

Erysipelas of the upper respiratory tract occurs as a direct inoculation, and is usually an autoinfection from the nasal mucosa. The mucous membranes of the mouth and throat become swollen and the process extends into the larynx. Generally laryngeal edema, when it occurs in erysipelas, is caused from without the larynx and not from within.

Ear.—Erysipelas of the auricle usually follows traumatism. Primary erysipelas of the auricle is rare, being generally an extension from the face or from a mastoid incision. Erysipelas of the ear is more fully described in Chapter X.

Nose.—Erysipelas of the nasal mucosa is usually secondary to that of the contiguous skin. It is prone to become bilateral and to cause complete nasal obstruction. The appearance of the mucosa is dusky red, with many ecchymotic areas.

The cervical lymphatic glands become enlarged, with a marked tendency to suppurate. The accessory nasal sinuses are almost invariably involved.

Fatal meningitis may result by direct extension through the cribriform plate of the ethmoid.

Pharynx.—Pharyngeal erysipelas commences with a disagreeable sensation of smarting in the throat, followed by swelling and dysphagia. The throat is vividly red, dry, glistening, and swollen. Blebs occur on the mucosa over the cheek, tonsils, and pharynx, and the uvula is markedly edematous. In some cases there is a fibrinous exudate over the tonsils and phlegmonous ulceration is a rare complication. It is apt to spread to the nose, Eustachian tubes, tympanum, and mastoid cells, producing violent inflammation in its path. The cervical glands are more involved than in the pure nasal type.

The prognosis is very grave.

Treatment.—In addition to the more general measures elsewhere described, local cleansing measures are indicated for the relief of distressing symptoms and the removal of secretion. The oropharynx should be douched with hot normal salt solution at intervals of from two to six hours (Fig. 290).

Larynx.—Erysipelas seldom involves the larynx and only secondarily to that of the skin of the face and oropharynx.

The appearance of the laryngeal mucosa is similar to that described in the pharynx. Great dyspnea, dysphagia, and aphonia appear, early necessitating tracheotomy, with the result that the tracheal wound generally becomes infected with the disease. The prognosis is extremely grave.

Treatment.—Early tracheotomy and strong stimulating general treatment to tide over the crisis is necessary.

RHEUMATIC FEVER.

Acute articular rheumatism is probably due to a diplococcus—the *Diplococcus rheumaticus* (Fritz Meyer). This diplococcus has

been frequently found on the tonsils, and in the subcutaneous nodules which are more common in England and America. It is possible that this agent may enter through an inflamed mucous membrane. Triboulet and Coyon in two cases found a diplococcus or diplobacillus which produces in rabbits violent endocarditis, with large masses of vegetations about the mitral valves. Sixty per cent. of all cases of tonsillitis, when accompanied by fever, are said to be of rheumatic character. Packer, Meyer, Wade and Gurich have reported cases wherein endocarditis and acute articular rheumatism followed lacunar tonsillitis.

In an attack of rheumatic fever the laryngeal joints may become involved, producing fixation and varying degrees of ankylosis.

Mosely has collected 11 cases of cricoarytenoid ankylosis occurring in the rheumatic.

Ear.—Rheumatic individuals sometimes suffer from otalgia, which is out of proportion to the local pathological appearances and it is claimed to result from interossicular inflammation. Rheumatic paralysis of the auditory nerve has been reported as occurring in a few cases at the time of the general attack.

Treatment.—For the general treatment of rheumatism the reader is referred to text-books on general medicine. The local treatment of acute tonsillitis is described in Chapter XLV.

MALARIA.

Acute rhinitis of an obstinate nature is sometimes the prodromal symptom of malaria. Hemorrhage from the nose and pharynx, rarely from the larynx, may occur in severe attacks. Neuroses of the palate and pharynx, producing dysphagia, and of the larynx, causing hoarseness or spasmodic coughing, have been reported.

Ear.—Malaria sometimes produces disturbances of hearing through its effect on the auditory nerve in its course or terminations.

Quinine given for the disease is liable to affect the internal ear, especially if there is already some disease of this organ, brought about by selective congestion of the ear through vasomotor influence (Kirchner).

HYDROPHOBIA.

Aural Symptoms.—Hyperesthesia of the ears is common in the prodromal stage of hydrophobia.

Laryngeal Symptoms.—In the beginning there is congestion, and the voice may be husky. Dysphagia occurs early. During the stage of excitement a noise, a draught of air, or verbal suggestion may produce spasm of the mouth and larynx, with a sense of dyspnea. Effort to eat causes intensely painful spasm of the muscles of the larynx and the elevators of the hyoid bone. This produces the so-called fear of water. No relief is obtained from treatment.

RHINOSCLEROMA.

In accordance with the more recent investigations rhinoscleroma is believed to be of bacterial origin, the Frisch bacilli

within the Mikulicz cells and in the surrounding tissues having been found in all of the cases. This disease is characterized by the formation of nodular granulomata in the vestibule of the nose. The nodules are of extreme hardness, and occur either singly or in groups. They are of slow growth, gradually extending outward upon the lip and cheek and inward by invading first the septal and inferior turbinal tissues, thence into the rhinopharynx, and finally involving the Eustachian tube, pharynx, larynx, trachea, and bronchi.

The disease is chiefly prevalent among the inhabitants of Russia, Austria, Eastern Prussia, and Central America, where it is endemic. It is about equally divided between the sexes, and according to Gottheil all cases occur in the third decennium or later. Güntzer controverts this and contends that the disease, though mostly found in adults, may begin during childhood, and cites cases affected in childhood and infancy. It is confined chiefly to the poorer classes.

Diagnosis.—The diagnosis, according to Gerber, is based upon eight observations, which are as follows:—

"1. Changes of the nose externally which would cause suspicion are wanting in most cases.

"2. The occlusion of the nose, which is often the beginning of the disease, shows on rhinoscopic examination to be due to the thick, rigid, at the beginning soft, later very hard, more or less nodular swellings of the mucous membrane of both the septum and turbinates and which sooner or later fill up the entire nose.

"3. These typical changes are not always found anteriorly but are seen first, with posterior rhinoscopy, as a narrowing of the choanæ from thickening of the septum, the Eustachian prominences and the lateral folds of the mucous membrane.

"4. Often the pharynx is found normal on direct examination, but here too in some cases we see scleromal infiltration, which reminds one of syphilis and tuberculosis, hypertrophies, contractions and tumefactions of the soft palate and the posterior pharyngeal wall.

"5. Sooner or later, mostly in the very chronic course of the disease, the larynx becomes affected by stenosis, due to subglottic swelling; the swelling may be above the chink. In some cases the larynx is primarily affected and the disease extends upward.

"6. The secretions may be normal; in other cases may show a picture of ozena and 'ozena trachealis.'

"7. It is characteristic of these thickenings, excepting in the very beginning, that they are hard, tough and rigid, and do not ulcerate, although a superficial secondary erosion is seen now and then.

"8. Finally, the microscopical examination will show the Mikulicz cells and the bacilli of Frisch."

Dr. J. H. Güntzer, in an exhaustive thesis,[2] reports two cases treated at the Manhattan Eye and Ear Hospital by vaccine and radiotherapy, and concludes that: "The X-ray treatment, at this time, holds out the best prospects of a possible cure for scleroma; that the vaccine treatment has at least caused a local immunity and

[2] Scleroma of the Upper Respiratory Tract.

may be a means of possible cure if used for a long time, and, as to frequency and quantity, in proper dosage, and that, with no criteria to guide my original work in this disease, these points in the vaccine treatment still need to be worked out, and that surgery has only an elective place in the treatment of scleroma, and is useful only as an auxiliary."

In both cases the vaccine treatment was given for a period of several months, after which it was combined with the X-ray treatment, given at intervals of two or three days. In both cases there was marked improvement in the general health, the infiltration materially subsided, and the symptoms ameliorated.

GLANDERS.

This is a rare disease which is peculiar to horses and due to the bacillus mallei. It is communicable to men through abrasions in the skin or mucosa. Infection is acquired from contact with infected horses.

Pathology.—There are granulomatous tumors made up of epithelioid cells and the glanders bacillus. The nodules break down early, with the formation of ulcers. The mucous membrane of the nose becomes inflamed and a profuse purulent discharge persists. Small, firm nodules appear first on the septum and turbinals; these rapidly become first red, then yellow from necrosis, and in a few days they break down, leaving ulcers. The nose is usually greatly swollen. The same process may attack the lips, tongue, tonsil or pharynx. The maxillary and frontal sinuses may be involved, and rarely the ethmoidal or sphenoidal sinus.

Prognosis.—Glanders is usually fatal in from eight to ten days.

Treatment.—Treatment is unavailing, but relief is obtained from ordinary cleansing measures.

ACTINOMYCOSIS.

Synonym.—Lumpy jaw.

This is a chronic infectious disease due to the *actinomyces* or rayfungus, the *Streptothrix actinomyces*. It is rare in this country. The mode of infection is probably through the food. It is common in cattle, and they are supposed to acquire the affection from fungus-laden straw, chaff, and grain. The fungus gains entrance through abrasions in the mucous membranes.

Pathology.—In the early stage there is a granuloma similar to that of tuberculosis, composed of round cells, epithelioid elements, and giant cells. Later there is a great increase in connective-tissue elements. Finally it breaks down and causes great destruction of the underlying structures. The tongue is sometimes involved. De Simoni reported a primary case in the nose, spreading to the palate. It has occurred in the antrum of Highmore. J. C. Beck reports a case involving the tonsils, the left tympanum and mastoid process, death occurring in one week from intracranial hemorrhage. Several cases involving the larynx have been reported by Heinrich and Henrici, in one of which it started in a carious tooth.

Diagnosis.—The diagnosis depends upon the discovery of the rayfungus in the pus.

Symptoms.—A somewhat irregular nodule forms upon the lips, tongue or tonsil. The growth is rapid with but little pain; the nodule begins to break down in a few weeks, and, from numerous sinuses, pus and small yellow masses are discharged which contain the streptothrix.

Treatment.—The growth should be completely excised, and this is possible only when the disease involves the lips. On the tongue or tonsils the process is prone to extend to the digestive or respiratory tract. In recent cases the iodides in large doses may afford relief.

Fig. 300.—Leprosy. A native of Jamaica with marked nodular lesions of face, destruction of the nasal cartilages, and characteristic leonine expression. (Photograph loaned by *Dr. E. Echeverria,* of Costa Rica.)

LEPROSY.

The contagion of leprosy is probably conveyed by the secretion of the nose, throat, and mouth. Sticker believes the initial lesion to be an ulcer on the nasal septum. The nose is more frequently involved than the larynx or pharynx.

Pathology.—There is a formation of tubercles which consist of round-cell infiltration, of various sizes, with bacilli in large numbers about and in the cells. These gradually break down and extend, forming ulcers, and on healing form cicatrices. Involvement of the mucous membrane of the mouth, throat, and larynx is a later manifestation of the disease.

Symptoms.—There is diffuse infiltration of the septum and inferior turbinal, with congestion of the mucosa. Mucopurulent secretion is abundant, with a tendency to the formation of crusts. Small, yellow, shiny tubercles the size of a split pea appear upon

the septum. The process is sometimes destructive to the cartilage and bones of the nose (Fig. 300). The faucial pillars and uvula are more often affected than the hard palate and tonsils.

Likewise the epiglottis is more often affected than the laryngeal structures. In severe cases the process extends throughout the larynx, causing hoarseness, dyspnea and perichrondritis, or necrosis of the cartilage.

Prognosis.—Death often occurs from laryngeal complications or aspiration pneumonia. The tubercules ultimately ulcerate and usually heal.

GOUT (PODAGRA).

Acute pharyngitis or laryngitis of a very painful type may occur before or during an attack of gout. The mucosa appears intensely dry and glazed and the uvula may be very edematous. Chronic catarrh of the mucous membrane of the nose and throat is common in the gouty.

Pain is greater than the local condition seems to warrant, and it shoots up to the ears or to the temporomaxillary articulation.

Infected tonsils may well be suspected as a predisposing cause of this condition.

Tophi have been found in the throat.

The laryngeal symptoms of gout are similar to those of the nose and throat, and are characterized by swelling, congestion, and dryness. The edges of the true or false cords and the interarytenoid space are the parts commonly affected. The deposit of urates in the cords or in the cricoarytenoid joints is occasionally observed.

Ears.—Eczema of the auricle or canal is common in gouty subjects. Tophi frequently occur on the auricle. Exostoses are sometimes produced in the external auditory meatus, and some authors believe that otosclerosis may be due to gout.

Treatment.—The treatment is necessarily dietetic and hygienic in accordance with the rules laid down in text-books on general medicine. In every instance, however, foci of infection should be sought in the tonsils and teeth.

DISEASES OF THE DIGESTIVE SYSTEM.

The diseases peculiar to the digestive tract evince a marked tendency to become the exciting cause of inflammatory affections along the upper respiratory tract or to aggravate those already in progress and these local primary inflammations in the mouth or pharynx may extend by contiguity to the nose, ear, or larynx.

(*a*) **Teeth.**—A general examination of the digestive tract should begin with the teeth. Foul, neglected, necrosed teeth favor the growth of deleterious micro-organisms, which are prone to induce secondary infection of the oropharynx. A suppurative process in and around the upper incisor teeth may burrow upward and form an abscess in the floor of the nose or in the septum. Necrosis of an upper bicuspid or molar tooth, by extending through the antral floor, becomes the exciting cause of empyema within

the maxillary sinus. The severe pains sometimes associated with carious upper teeth tend to radiate to the ear.

(*b*) **Mouth.**—Inflammations of the mucosa of the mouth, whether simple, aphthous, ulcerative, parasitic (thrush) or gangrenous (noma), often extend to the neighboring mucous membranes.

(*c*) **Pharynx.**—Ulceration or inflammation of the nasopharynx is a common cause of otalgia. In acute tonsillitis the pain is commonly referred to the ear. These diseases are fully discussed in appropriate chapters.

(*d*) **Esophagus.**—Esophageal diseases may extend to the larynx and pharynx. Malignant growths when located in the upper part of the esophagus eventually extend to the pharynx and larynx, producing paralysis, dysphagia, and aphonia. When the lower portion of the esophagus is the seat of cancer, pressure is brought to bear upon the laryngeal nerve, causing laryngeal paralysis, but the pain or paresthesia is referred to the tonsils or root of the tongue (Stein).

(*e*) **Stomach and Intestines.**—Indigestion, whether due to gastric or gastrointestinal affections, is prone to evoke troublesome congestion of the mucosa of the upper respiratory tract, which persists until the primary cause is eliminated. These disturbances vary from simple congestion to inflammation and hypertrophy. A characteristic symptom of this type is the patient's intolerance to examination of the fauces and pharynx, due to the hyperesthesia of these parts.

In like manner digestive disturbances are believed to result from idiopathic affections of the nose and throat. The continuous swallowing of the discharge emanating from diseased adenoids and tonsils by children, or of pus from ozena, or suppurating accessory sinuses by adults, has a deleterious effect upon the digestive functions. Kerley calls attention to the prevalence of colds and adenoids in children who eat excessive amounts of cane-sugar. Stomatitis, aphtha, cancrum oris, herpes, nasopharyngitis and laryngitis are commonly of digestive origin. Cases of edema of the larynx due to catarrhal inflammation of the intestines and cirrhosis of the liver have been reported by Schrötter, Schmidt, and Löri. Hyperemia of the throat in the vomiting of gastritis or regurgitation of dyspepsia is common. Butyric acid and other eructations from gastric fermentation irritate the mucosa of the upper air tract. Hyperemia of the upper respiratory tract and lingual varix are commonly associated with constipation, and indicanuria induces nasopharyngeal congestion. Obstinate nasopharyngitis is observed in connection with Glénard's disease.

(*f*) **Liver.**—The nasopharyngeal mucosa is often congested in advanced cirrhosis of the liver. Ecchymoses and alarming epistaxis are commonly observed in cirrhotic patients. In chronic jaundice the time required for coagulation of the blood to take place may be lengthened from three and a half to four and a half minutes (normal) to eleven or twelve minutes; hence the tendency

to hemorrhage of the mucous membranes. The danger of operating in this condition is, therefore, considerable, because of the difficulty of controlling hemorrhage.

The vascular, lymphatic and nerve interrelationship which exists between various organs of the body is still further illustrated by the manner in which toxins and infections are conveyed from the diseased to the healthy; thus infections of the ear, nose, and throat evoke cervical adenitis; the appearance of asthma in conjunction with vasomotor rhinitis, arthritis from infected tonsils, and the simultaneous appearance of streptococcemic appendicitis and tonsillitis.

(*g*) **The Lungs.**—Various diseases when appearing primarily in the lungs evoke secondary manifestations in the nose and throat. Among these are pulmonary tuberculosis, which has heretofore been considered (Chapter XXIX). Acute and chronic bronchitis and pleuritis induce secondary laryngitis and pharyngitis, partly from the mechanical irritation produced by coughing and from the infection and irritation of the secretions.

An excessive paroxysmal cough often induces hemorrhage from the nose, pharynx, or larynx, but, unless there is some ulceration or tumor to account for it, the amount is slight. Occasional cases of laryngeal ulceration have been reported in bronchopneumonia. A metallic cough and laryngeal paralysis (either abductor or complete) of the cords may occur in chronic thickening of the pleura, due to involvement of the recurrent laryngeal nerve, or in apical fibrosis of the right lung.

The same symptoms are also observed in some cases of enlarged bronchial lymph glands, or from tumors in the upper mediastinum. Thymic enlargement in infants evokes characteristic stridor, and sometimes, during anesthesia, sudden death.

ASTHMA.

Pulmonary asthmas are of three distinct types:—

1. Allergic asthma.
2. Bacterial infective asthma.
3. Combination of allergic and infective asthmas.

1. In some instances allergic asthma is due to the deposition of the dust of powders or chemicals upon the respiratory tubes of an animal sensitive to these substances and is a local manifestation of a general condition the same as is hay fever. In fact, hay fever patients will suffer with asthma if the pollens to which they are sensitive reach the bronchial passages. The chief substances responsible for allergic asthma are various animal emanations, food and bacterial proteins, chemical odors, and various powders and dusts. The animals most commonly responsible for the spasmodic asthmas are the horse, dog, rabbit, goat, chicken and goose emanations. The foods responsible for most of the asthmas of children, and in some cases of adults, are: wheat, rice, flour, eggs, and milk. Bacterial protein sensitization asthma has been rare in

the Manhattan Eye, Ear and Throat Hospital clinic; in fact, we seriously doubt if sensitization to bacterial protein exists. The bacterial sensitization phase of our work has been most unsatisfactory and we are inclined to think bacteria are responsible for asthmas as infective agents only. There are a multitude of powders that at times cause asthma and the one responsible is often most illusive and difficult to find. The age of the onset of asthma is very important. The earlier it develops the more likely it is to be a sensitization asthma. The treatment of allergic asthma consists of elimination of the offending substance, or the desensitization and immunization of the patient to the extracts made from the exciting substances. Operations upon the nose and throat will have little value when a patient has asthma of the purely anaphylactic variety.

2. Infective Bronchial Asthma. Classically a pyogenic inflammatory infection of the bronchial mucosa, lymphoid tissue and musculature. These bacteria and their toxins periodically irritate the vago-constrictor mechanism of the bronchioles, thus producing a spasmodic obstruction of respiration. The infective type also produces a chronic obstruction to the bronchi by inflammatory thickening of the mucosa of the passages. In the infective types and mixed forms, the treatment consists of drugs, specific proteins, vaccines, operative procedures, climatic and generally supportive measures. Vaccines are of frequent aid to the infective types. The vaccines should be made fresh every four to six weeks and treatment continued over a long period of time.

3. A combination of sensitization and bacterial invasion frequently exists. The sensitization asthmas are very susceptible to infections. It frequently requires a long study and patience to get at the fundamental facts in an asthmatic patient.

Some forms of eczema, particularly in children, have resulted from sensitizations. The foods usually responsible are cereals, eggs, and milk. Walker has previously reported the frequency of eczema associated with asthma in children. The explanation for the eczematous tendency in sensitive animals has received considerable scientific support. Auer has recently shown that sensitized rabbits will more easily develop an eczematous condition of the ears after application of a skin irritant than the normal rabbit controls.

Urticaria, chronic conjunctivitis, acute gastric collapse have resulted from sensitization.

Treatment (See Hay Fever, Allergy and Pollen-therapy, p. 652). —The correction of nasal deformities, the removal of polypi, and the eradication of diseased turbinals and accessory sinus affections is indicated in all cases of asthma. As a preventive measure Sajous recommends the administration of thyroid extract in 3-grain doses three times a day, to be reduced to 2 grains twice daily after four days, this treatment to be commenced about four weeks before the usual onset of periodical attack.

Treatment by the various specific sera has not met with gen-

eral success. In America the usual irritant is the pollen of the rose, ragweed, and goldenrod, while in Europe it is more often that of the grain-bearing grasses. This may account for the greater success from the administration of Dunbar's serum abroad, as it is made from the grain pollen. Somers reports some success from the use of the goldenrod antitoxin. Michaels, Braden Kyle, and others have investigated the chemical changes in the nasal and buccal secretions in sufferers from hyperesthetic rhinitis, and contend that a subacid condition, due to faulty elimination, attended by excessive ammonia salt production is, in some instances, a source of irritation in hay fever.

During the attack much relief is obtained by abstaining from alcohol, tobacco, rich foods and by a careful observance of recognized rules of hygiene. The nasal mucosa may be cleansed with bland alkaline sprays and protected by liquid vaselin, which may be medicated with camphor and menthol, 2 per cent.

A spray of 2 to 4 per cent. cocaine and 1:5000 adrenalin by contracting the arterioles gives temporary relief. To some patients adrenalin is extremely irritating, and in these its local use aggravates the symptoms.

The administration of thyroid extract, grs. iij, is worthy of trial, and codeine taken at night is beneficial. Excitement and over-exertion should be avoided. Of all forms of treatment the climatic is the most successful.

ANGIONEUROTIC EDEMA.

Angioneurotic edema is characterized by the appearance of circumscribed swellings upon the skin or mucous surface, which are the result of vasomotor neuroses.

It is a rare disease which may appear upon any portion of the surface of the body. It occasionally develops in the mucosa of the pharynx or larynx. The edematous patches are pearly gray in color, non-inflammatory, and are not attended by febrile symptoms. They appear suddenly, and after from one to three days subside. In the pharynx angioneurotic edema rarely produces serious symptoms, but in the larynx the edematous tissue may produce serious dyspnea or asphyxiation.

The treatment of this disease is precisely the same as that indicated for infectious epiglottitis (Chapter XLVIII).

CIRCULATORY SYSTEM.

In all diseases of the heart, whether primary or secondary, where the compensation is insufficient there exists a tendency to congestion of the mucous membranes and tissues of the head. In the upper respiratory tract epistaxis, labyrinthine and other hemorrhages occasionally result. Edema of the larynx is sometimes of cardiac origin. Whenever left abductor laryngeal paralysis complicates severe pericardial effusion it is due to pressure on the left recurrent laryngeal nerve. Aneurisms in the thorax frequently

cause laryngeal paralysis and aphonia by pressure upon the recurrent laryngeal nerve. Aneurism of the aortic arch usually involves the left recurrent laryngeal nerve. Aneurism of the ascending portion of the aorta by extending into the right pleura may finally involve the right recurrent laryngeal nerve. Occasionally both nerves are involved. Aneurism of the subclavian artery may also cause paralysis of the larynx. Paralysis of the left vocal cord is commonly the first symptom induced by aneurism of the arch of the aorta.

Malignant endocarditis has been traced in some cases to streptococci tonsillitis. High blood-pressure in arteriosclerosis may



Fig. 301.—The Faught blood-pressure apparatus applied to a patient's arm.

produce nausea, headache, vertigo, and tinnitus. If this occurs in one with considerable deafness, labyrinthine disease may be wrongly inferred. The sphygmomanometer (Fig. 301) serves to verify the diagnosis. Vasodilators are the appropriate remedial agents. Labyrinthine hemorrhage is more common in individuals with atheromatous arteries.

(*a*) **Anemia.**—Anemic symptoms are apparent earlier and are more pronounced in the nose than in the conjunctiva, lips and gums. It is characterized by a shrunken and pale appearance. Olfactory hallucinations and tinnitus aurium are common in anemia when due to sudden hemorrhage. Anemia of the soft palate and epiglottis is characteristic of advanced phthisis. The pharyngeal mucosa in anemia is pale and either hyperesthetic or anesthetic, while the voice may become functionally weak, husky, or

even aphonic. In severe anemia ecchymotic spots and various hemorrhages of the mucosa are quite common. Labyrinthine hemorrhage may occur in pernicious anemia.

(*b*) **Leukemia.**—The complications of leukemia found in the nose, throat, and ear are cancrum oris, inflammation of the tonsils and pharynx, often with necrotic areas, epistaxis, hemorrhage into the tympanum or labyrinth, and deafness. Vidal and Isandert found disturbances of hearing in 10 per cent. of all cases of leukemia. Schwabach states that in acute leukemia deafness arises in the initial stages, while in the chronic form deafness appears in the later stages.

In various forms of purpura, whether toxic, neurotic, in the newborn or in hemophiliacs, and purpura hæmorrhagica, surgical operations are extremely dangerous. Attempts have recently been made to increase the coagulation of the blood by the subcutaneous injection of a serum, or by the direct transfusion of the blood of a normal individual.

HODGKIN'S DISEASE.

During an attack of Hodgkin's disease the mucosa is often waxy and pale yellow in appearance. Epistaxis and other hemorrhages are not so frequent as in leukemia. In severe cases lymph nodules appear on the tonsils, epiglottis, aryepiglottic folds, and sometimes in other parts of the larynx and trachea. They appear as small, soft, whitish, and slightly raised spots, with a tendency to necrosis and ulceration. Extensive infiltration and sometimes large tumors appear in the tonsils and in other parts of the pharynx or at the base of the tongue. Involvement of the bronchial glands may cause laryngeal paralysis through pressure upon the recurrent laryngeal nerve, or pressure symptoms may be produced on the bronchi or trachea.

TABES DORSALIS
(Locomotor Ataxia).

Tabes dorsalis is attended with several symptoms which are referable to the throat and larynx, the most common of which is paralysis of the laryngeal muscles. The abductor muscles are the first to succumb, but in advanced cases the tensors also may become involved. Complete recurrent paralysis is rare.

Laryngeal paralysis is often the earliest symptom of tabes, and according to Watson Williams is always accompanied by marked and persistent increase in the pulse rate.

Laryngeal crises is a later symptom of tabes and is characterized by paroxysms of coughing, which are immediately followed by dyspnea. Violent rasping cough and strident inspiratory sound, together with the excitement due to the patient's fear of impending suffocation, produce an alarming series of symptoms. Respiration finally ceases temporarily, and the patient may lose consciousness or complain of vertigo. The attack usually lasts about thirty

seconds, after which the respirations become normal. Fatal cases of laryngeal crises have been reported.

Regarding laryngeal crises, Touche found 12 cases in 40 cases examined. Green found 7 out of 60 cases examined. Moore and Martin report fatal cases of recurrent laryngeal spasm, complicated by bronchial spasm. In both cases tracheotomy was performed, but death from exhaustion ensued in about ten days. Whenever there is lack of co-ordination of the muscular movements of the larynx, ataxic movements of the cords may be seen, in consequence of which the speech becomes jerky and uncertain. Anesthesia and hyperesthesia of the pharynx and larynx is occasionally observed as a complication of tabes. Paresthesia is more rare.

Progressive deafness, according to Duchenne, is common in locomotor ataxia, and is due to atrophy of the acoustic nerve. Morepurgo and Marina examined 53 tabetics and found only 10 who had normal hearing. According to Politzer, tabes is accompanied by unbearable tinnitus, the disease being bilateral and often accompanied by vertigo.

SCURVY.

In scurvy the gums are swollen, edematous, or ulcerated and bleed easily; the teeth are foul and become loose or fall out. The tongue may be swollen. Hemorrhagic areas which tend to ulcerate sometimes appear in the mouth or pharynx.

UREMIA.

The lowered resistance of the body which accompanies advanced kidney lesions tends to aggravate all forms of aural affections.

A special uremic stomatitis has been described by Barie. It occurs on the lips, gums and tongue, which become swollen and ulcerated with increase of saliva.

CHRONIC INTERSTITIAL NEPHRITIS.

Edema of the glottis, epistaxis, tinnitus, vertigo, and deafness are observed in chronic interstitial nephritis and less commonly in parenchymatous nephritis.

GENITAL SYSTEM.

Periodic hyperemia of the nasal mucosa, turgescence of the inferior turbinals, epistaxis, hyperesthesia, and paresthesia are sometimes observed in conjunction with disturbances in the genital tract in both males and females. Voice weakness and slight hoarseness sometimes occur in female singers at the menstrual period. According to Ménière and Jacobson, sudden cessation of menstruation may produce labyrinthine hemorrhage. Vicarious bleeding from the external auditory canal has been reported in a few instances, and more commonly from the nose and throat.

Lautmann and Fliess claim to have found hyperesthetic points on the inferior turbinal and septum in dysmenorrhea. Bettmann reports a case of labial and laryngeal herpes appearing regularly one week prior to the menstrual flow.

PREGNANCY.

The influence of pregnancy on tuberculosis of the larynx is baneful. In a series reported by Küttner, 200 out of 231 died during or shortly after delivery. Freudenthal[4] reports a similar experience. Furthermore about 75 per cent. of children born of mothers who have tuberculous laryngitis die within the first year.

PUBERTY.

There is a marked growth and development of the upper respiratory tract, especially in the male, at puberty, with a tendency to congestion of the mucosa. The accessory sinuses may also grow rapidly at this time, and adenoids of moderate size which previously obstructed respiration may now, owing to increased size of the nasopharynx, no longer interfere. At this period the vocal cords increase markedly in length in the male; not so much in the female. This explains the breaking of the boy's voice at this period. The laryngeal muscles become easily fatigued; therefore, squeaking and hoarseness are easily evoked. The "change of voice" requires about one year. Occasionally the voice becomes temporarily or permanently falsetto, especially if much used in singing at this time. Persistent falsetto is treated by vocal and respiratory exercise, such as deep and slow respirations and production of deep tones several times a day. Later, words should be pronounced deeply and slowly, gradually lengthening the exercises until reading aloud may be employed. In two or three weeks a cure is effected.

STATUS LYMPHATICUS.

Status lymphaticus, so named by Paltauf, is characterized by a persistent or hypoplastic thymus gland, associated with hyperplasia of the tonsils, adenoids, lymph-nodes, lymphatic elements of the intestinal tract and spleen. The importance of status lymphaticus in diseases of the upper air tract is due to the liability of the victims of this diathesis to suddenly die during the administration of anesthesia, especially chloroform. Fatalities have also been known to follow sudden shock and injection of diphtheria antitoxin. Cock's[5] has reported an interesting series of cases and calls attention to the significance of dyspnea and stridorous breathing in newborn children. It often happens that the presence of status lymphaticus first becomes apparent when anesthesia has been induced and alarming or fatal results have ensued. The diagnosis is difficult,

---

[4] Transactions of the American Laryngological, Rhinological and Otological Society, 1907, p. 274.

[5] The Laryngoscope, July, 1910; August, 1912.

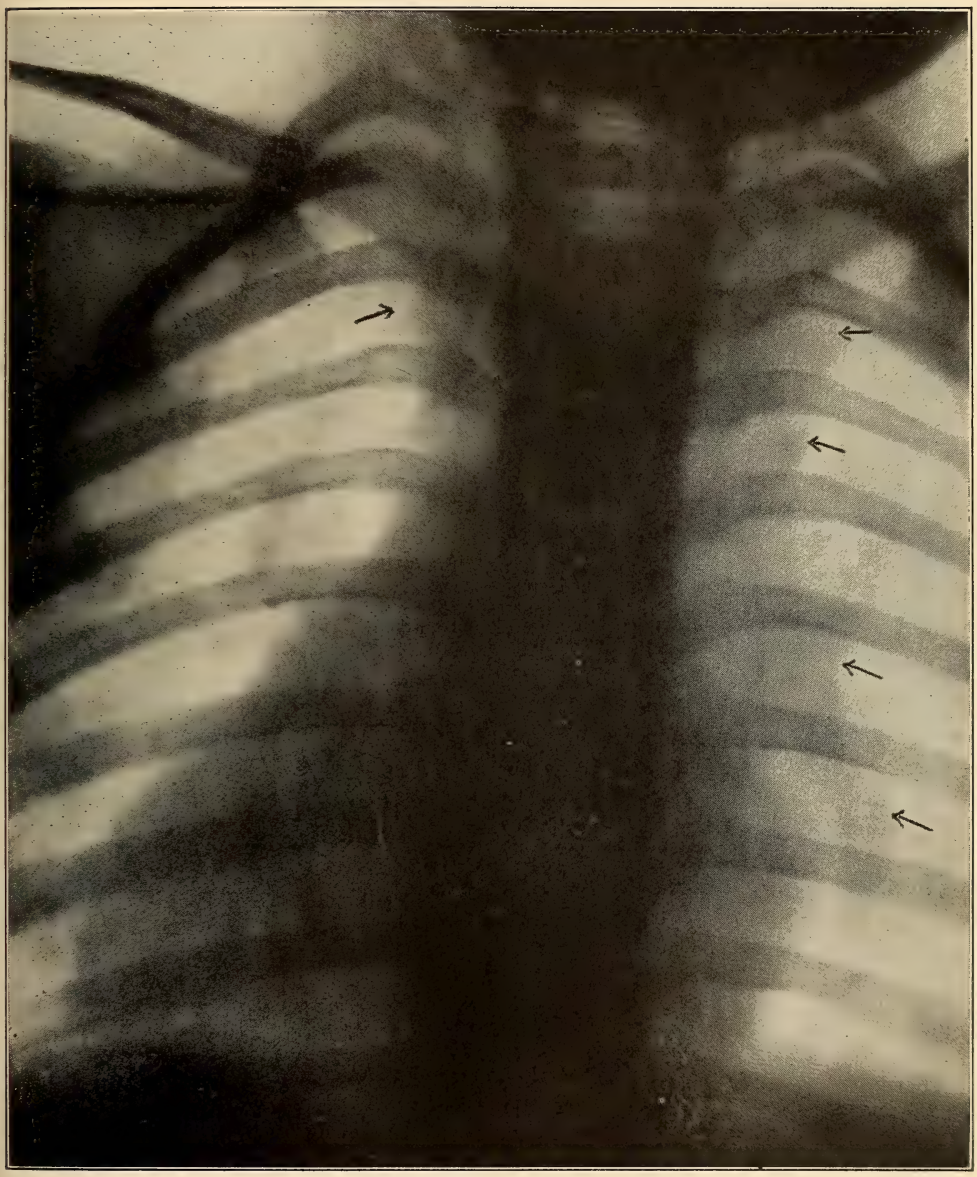

Fig. 302.—The radiograph arrows point to the outer borders of the enlarged thymus gland, which extends to and overlaps the aorta and heart.

although percussion of the enlarged thymus gland may be of some benefit. Radiography (Fig. 302) seems to offer the surest diagnostic evidence of this affection. Dr. John E. MacKenty has reported a case (Fig. 302) with the following history: Child aged 3 years, normal at birth. Shortly after birth began to lose weight, but was restored by mercurial inunctions. In August, 1912, was given antitoxin for an attack of diphtheria and the larynx was intubated. The tube was kept in for six weeks. Obstructed dyspnea remained until December. Child is anemic; nutrition is defective; pulse accelerated, but temperature normal. There is retraction of the lower costal region and supraclavicular spaces on inspiration. Expiration from left lung prolonged and whistling, due probably to pressure on left bronchus. There is no known treatment for this diathesis, but it is here suggested that in cases of known status lymphaticus, anesthesia, particularly chloroform narcosis, should be avoided. Where the dyspnea has been due to the mechanical pressure of the enlarged thymus gland upon the trachea, Jackson and others have excised a portion of the gland, or have pulled it forward and sutured it to the sternum, after the preliminary performance of tracheotomy with a tube long enough to reach below the obstruction.

PART III.

The Nose and Accessory Sinuses.—The Pharynx and Fauces.—The Larynx.

SECTION I.

The Nose and the Nasal Accessory Sinuses.

CHAPTER XXXIII.

ACUTE INFLAMMATORY AFFECTIONS OF THE NASAL MUCOSA.

RHINITIS.

General Remarks.—This extremely common affection both in its acute and chronic form was believed by Galen to be the result of a secretion from the brain passing through the orifices of the ethmoid into the nose, the process relieving the brain of superfluous substances. Schneider successfully combated this theory, and after him the nasal mucous membrane is sometimes called the Schneiderian membrane. In France a cold in the head is still designated *rheume de cerveaux*. During later years, as the result of pathological study, a more intelligent classification has been rendered possible, showing the variety of diseases which may be, generally, classified under the term *rhinitis*.

Pertaining to the probable bacterial origin of intranasal diseases, it may be stated that, aside from the air-borne organisms with which the vibrissæ are contaminated, the organisms found most frequently in inflammatory conditions of the mucous membrane of the nose are the diphtheria bacillus, the influenza bacillus, the *Micrococcus catarrhalis,* and less commonly the pneumococcus. In suppuration of the accessory nasal cavities the bacteriology varies. In antrum disease the micro-organisms are numerous, with the *Bacteria fusiformis* predominating when the infection is from carious teeth; the other bacteria found are the pneumococcus, streptococcus, staphylococcus, and the *Micrococcus catarrhalis.* Often these can be found in pure culture.

The nasopharynx may harbor this same variety of micro-organisms, with the addition of the meningococcus, and frequently without exhibiting any pathological features until the tissue resistance is lowered or the increase in bacterial virulence may arouse them into activity. While the subject has not, as yet, been suffi-

ciently investigated to point to a positive bacteriology of the majority of the diseases of the nose and the accessory cavities, still the specific organisms of some of the infectious diseases affecting the nasal cavities are readily isolated, as the tubercle bacilli in tuberculosis and lupus, the *Spirocheta pallida* in syphilis, the *Bacillus lepræ* in leprosy, the bacilli of Frisch in rhinoscleroma, the *Bacillus mallei* in glanders, and Klebs-Loeffler bacilli in diphtheria.

The various forms of rhinitis may be classified under two general headings, viz., acute and chronic.

SIMPLE ACUTE RHINITIS
(Acute Coryza, "Cold in the Head").

Acute nasal catarrh is an inflammatory process involving the nasal mucosa, with an accumulation of lymphocytes in the tissues surrounding the blood-vessels. This accounts for the copious exudate which accompanies the disease at times, and the congestion is of sufficient severity to produce capillary rupture and extravasations.

Etiology.—The predisposing causes of simple acute rhinitis are physical exhaustion, chronic rhinitis, constitutional disorders, age, heredity, and bad hygiene. Individuals who suffer from chronic rhinitis resulting from intranasal obstruction are extremely liable to attacks of simple acute rhinitis.

Among the constitutional disorders which predispose to this affection are the gouty diathesis, rheumatism, diabetes, dyspepsia, asthma, cardiac diseases, and Bright's disease. Physical exhaustion, whether from overwork, dissipation or disease, creates a susceptibility to attacks of simple acute rhinitis. Likewise the deterioration of health which follows prolonged association with insanitary surroundings strongly predisposes to this affection.

We mention, as examples of the latter, vitiated air, overcrowding, defective diet, insanitation, sedentary habits and neglect of body cleanliness. Of the exciting causes, chemical irritants, exposure to cold, dampness, and, according to Parker, extreme heat, or to bacterial irritants (infections) are the most noteworthy. Furthermore it is significant that simple acute rhinitis is more common during the change of seasons.

No specific germ has yet been isolated, but its bacterial nature is undoubted, since in most cases the *Bacillus influenzæ,* the *Micrococcus catarrhalis,* and Friedländer's bacillus are found.

Bacteria within the nasal cavities may long remain inactive; on the contrary, however, they may rapidly develop pathogenic properties provided favorable conditions appear in the way of circulatory disturbances in the nasal mucous membrane, or when the general health is below par, thus lowering the bodily resistance.

It is doubtful whether micro-organisms alone ever primarily give rise to simple acute catarrhal rhinitis, and it is still a disputed point whether the other etiological factors heretofore named may excite an attack without the influence of micro-organisms.

Frequent attacks during childhood signify the presence of hypertrophic lymphoid tissue in the nasopharynx.

Pathology.—The pathological changes may be classified according to three clinical stages of the disease. (*a*) Initial stage or onset. The onset of simple acute rhinitis is characterized by sudden congestion of the capillaries of the nasal mucosa, accompanied by dryness, swelling, a shiny appearance and reduced secretion. (*b*) During the second stage infiltration of the mucosa becomes more marked and the secretions more profuse, the latter at first being serous and gradually becoming mucopurulent as the third stage is reached. Meanwhile the nasal passages become "stuffed" or blocked as a result of the tumefaction of the mucous membrane and turbinal tissues. (*c*) The third stage is marked by gradual cessation of the injection and infiltration of the mucosa, and by profuse mucopurulent or purulent discharge. In neglected cases the third stage may be prolonged indefinitely, and gradually assume the characteristics of chronic catarrh. Otherwise the secretions gradually subside and the mucosa returns to the normal state.

Symptoms.—An attack of acute rhinitis is usually ushered in by sneezing and a sensation of nasal stuffiness or obstruction. The obstruction is associated with a burning sensation in the nose, tenderness over the forehead upon pressure, heat in and below the eyes, lachrymation, a general sense of dryness of the mouth and throat, and often perversion or absence of the sense of smell and taste. Soon after the onset the general symptoms supervene, such as languor, fatigue, chilliness, and prostration. The general disturbances may be slight, but very commonly they are prolonged and distressing on account of the predominance of one or more of these manifestations. After a few hours the nasal obstruction becomes associated with a profuse watery discharge and the mucosa which was at first hyperemic becomes so much infiltrated that one or both nostrils may become entirely occluded. The nasal obstruction commonly alternates from one nostril to the other. The serous exudate soon changes to a mucopurulent and therefore thicker discharge as a result of the increasing admixture with cellular elements, and meanwhile it diminishes in quantity. The discharge often possesses an irritating quality which produces excoriation of the skin about the nasal orifices and upper lip. There may be a slight rise of temperature and considerable loss of appetite. On account of the interference with taste and smell, habitual users of tobacco usually abstain voluntarily during this period. Mouth-breathing is the rule, especially during sleep, resulting in great dryness of the pharyngeal and laryngeal mucosa. Nursing children, on account of the attendant nasal obstruction, encounter much difficulty in taking nourishment, being frequently obliged to drop the nipple in order to breathe. The swelling of the mucosa gradually subsides, and the secretion slowly diminishes and finally disappears; the attack usually terminates after a week or the proverbial nine days.

Complications.—Occasionally the disease extends over a period of several weeks, especially the influenzal forms, or when com-

plicated by involvement of the accessory sinuses or the middle ear, or of the pharynx or larynx. The nasopharynx is almost invariably involved in every case, and an associated acute tonsillitis is common. Simple acute rhinitis is quite often secondary to an attack of acute tonsillitis. Sometimes the catarrhal affection in the nose shows a marked tendency to extend to the deeper air passages, even to the bronchi. In certain individuals an attack of simple acute rhinitis predisposes to prolonged bronchial inflammation. The disease also may extend to the lachrymal ducts and the conjunctiva, and often involves the Eustachian tube, thus producing temporary obstruction of its calibre and consequent acute catarrhal otitis media (see Chapter XVI). A prolonged purulent involvement of the nasal accessory sinuses occasionally persists, requiring special treatment in order to prevent chronic empyema of these cavities. These complications are more prone to occur in the influenzal forms, to be described later.

Treatment. Prophylaxis.—Frequent attacks of simple acute rhinitis, especially in adults, demand the inauguration of stringent preventive measures. The following remarks relating to the general care of the body are appropriate in their relation to taking cold:—

An ordinary draft of air in a room never should induce an attack of acute rhinitis in a person who habitually practises proper hygienic health measures, and one who fears such exposure confesses to a lack of resistance which is incompatible with good health. The efforts of all individuals, and especially those who abide in changeable climates, should be to fortify the resisting power of the body; in other words, to develop resistance rather than to attempt prevention by means of "coddling" habits, either during childhood or adult life. For this purpose a morning application of cold water to the body, either in the form of a sponge, spray, or plunge, is highly recommended. Most healthy individuals react readily and promptly from a sudden plunge into cold water, and in a considerable proportion the reaction takes place without rubbing with a towel. Nevertheless much benefit arises from friction, induced by rubbing the entire body with a coarse bath towel immediately after the bath.

The cold bath is contraindicated in persons who for any reason do not react after friction is applied to the surface. To those unaccustomed to its use and who desire to commence the daily morning bath, the temperature of the water for the first few days should be moderate and gradually lowered each morning until the proper temperature for quick reaction has been reached. Furthermore the brisk rubbing benefits the capillary circulation.

The morning use of cold water may safely be commenced in children as young as two years, and this procedure should become a part of the daily habit of all children who are free from constitutional affections. The tonic effects are most marked and the tendency to colds proportionately reduced as the body can accustom itself to the sudden application of cold water. One who

can safely resist the shock of the cold plunge or even that of sponging may with impunity and confidence expect to resist ordinary drafts and exposure.

Bodily resistance is also considerably influenced by the quantity and texture of clothing worn. The clothing should be judiciously selected to meet the requirements of the locality, occupation and the degree of exposure. The clothing of persons with indoor occupations should differ materially from that worn by those with outdoor occupations. In this connection it may be stated that excessive clothing may do as much harm as insufficient. Whenever the occupation requires indoor life, the undergarments should be of light weight, to be supplemented by heavy outer garments when going out of doors. It is not wise to wear heavyweight woolen undergarments in occupations unattended by undue exposure; light wool will usually suffice. Of late the linen-mesh underwear has obtained considerable popularity, upon the theory that bodily moisture rapidly passes through this fabric.

Protection of the feet from dampness and cold is of great importance. Whenever the streets or sidewalks are wet or slushy, rubbers should be worn to protect the feet from dampness. Exposure to drafts does not induce colds in the same proportion as does the neglect to protect the feet from cold and dampness.

The prolonged inhalation of vitiated air should also be avoided. All occupied rooms and particularly sleeping apartments should be sufficiently ventilated to insure the proper amount of oxygen.

The air of a sleeping apartment should be fresh, and on account of warm bed covering the temperature may safely be lowered to 50° or even lower. In extreme weather the temperature of the sleeping apartment can be controlled by allowing sufficient heat to enter the room.

Bodily exercise promotes resistance and thus tends to prevent colds. A brisk walk to and from business or at the lunch hour, accompanied by deep breathing, is of great benefit, although every individual, if possible, should at regular intervals indulge in more fatiguing and general muscular exercise. The gymnasium with its variety of implements for indoor exercise, bicycling, walking, hunting, horseback riding, golf and tennis for outdoor exercise are examples of healthful and helpful methods to be employed, always bearing in mind that free perspiration is of great benefit to the human economy. Even the gymnasium can be dispensed with by employing a few forms of muscular exercises in one's own home. No person may expect to maintain perfect health who refrains from systematic physical exercise.

General and Local Treatment.—It is extremely difficult to induce persons suffering with acute rhinitis to submit to the form of treatment which mitigates its severity, lessens its duration and almost surely guarantees immunity from troublesome and even severe or serious complications. As a rule, patients know that the disease is self-limited, that in a large proportion of cases serious

complications do not occur, and they unwittingly run risks by attending to their usual duties, and only those who are prone to prolonged complications are willing to submit to the necessary restrictions and medication. Elderly persons should invariably remain indoors during the active stages of acute rhinitis.

At the onset, in individuals who consent to remain in bed, or at least indoors for two or three days, by taking a hot mustard footbath, a draught of hot lemonade and ten grains of Dover's powder, sweating is induced and the symptoms are ameliorated. A saline cathartic should be administered on the following morning. This form of medication is hardly to be recommended except during the early stages, after which the indications are for the relief of the obstructive turgescence, the cleansing of the nose and the nasopharynx, and the prevention of complications. At this stage it is still desirable that the patient abstain from work and remain indoors. The internal administration of extract of belladonna, grain $\frac{1}{8}$, every two or three hours, or atropine, grain $\frac{1}{120}$, at the same intervals until cessation of the coryza ensues, will be found of considerable benefit. The administration of quinine, in doses of from 2 to 5 grains three times a day, is useful in shortening the attack. During the early stages many individuals are benefited by taking large and frequent doses of sodii bicarb.

For the temporary relief of the turgescence of the mucous membrane, the local application of adrenalin to be used in the form of a spray in strength of 1:5000, the dilutions being made with normal salt solution, is recommended. With such a solution the entire nasal mucosa may be freely sprayed at intervals of from one to three hours in order to relieve the stenosis. Unfortunately in a considerable proportion of patients this medicament evokes severe sneezing and aggravates the coryza. In these it should not be employed.

That the effect is not permanent is well known; nevertheless the patient is able to breathe and sleep comfortably, and no deleterious effects result from its use. One marked advantage gained is the complete and thorough washing out, at frequent intervals, of the pent-up secretion, which undoubtedly carries away a preponderance of the micro-organisms.

After the tissues have contracted and the secretions have been blown out, it is advisable to spray the mucous membrane with some form of oily medicament. The O. B. Douglas formula of benzoinol possesses many virtues for this purpose:—

℞ Thymol	gr. x.
Eucalyptol	gtt. xx.
Menthol	gr. xxx.
Ol. cubebs	gr. xl.
Benzoinol	℥iv.
Oil rose	q. s.

The De Vilbiss hand atomizer (Fig. 303) is a convenient, serviceable, and reliable spray apparatus.

The oil produces a soothing effect upon the mucous membrane and it also tends to counteract the irritation of the skin surround-

ing the nose caused by the discharge. It is neither necessary nor advisable to employ cocaine during an attack of coryza, and patients never should be allowed to make use of it in any form, on account of its depressing effects and the attendant danger of forming the cocaine habit. The two above-named local applications are sufficient for all requirements until the active symptoms have passed, when for some days it may be necessary to wash away surplus secretions. Non-irritating simple alkaline sprays (pulv. alkali antiseptic, N. F.) or normal physiological salt solution may be used for this purpose.

RHINITIS OF INFLUENZA (LA GRIPPE)

is an acute rhinitis resulting from a bacterial invasion, either of the influenza bacillus (Pfeiffer bacillus) or the *Micrococcus catarrhalis,* is always of a severe type, and accompanies the majority of cases of influenza or grippe.



Fig. 303.—The De Vilbiss hand atomizer.

The symptoms do not differ essentially from those of ordinary acute rhinitis. Added to these, however, are the profound constitutional effects of the disease itself as manifested in the high temperature, severe pain, profound depression, and exhaustion. The presence of the streptococcus along with the influenza type of infection, with its tendency to rapid invasion, renders the grippal form of rhinitis extremely liable to extend to the accessory sinuses of the nose, the middle ear, and downward into the larynx, trachea, bronchial tubes, and pulmonary lobules. During epidemics of influenza the more severe types of accessory-sinus infection are observed. Middle-ear suppuration, also of a severe type, often accompanied by rapid extension into the mastoid process, and even to the meninges, is prone to occur. It must be emphasized that in any case of grippe the accessory sinuses and the middle ear should be carefully and persistently watched, so that the first advent of any involvement of the same may be noted.

Treatment.—Much has been written in regard to the general treatment of this affection, but, so far as the inflammatory conditions of the upper air passages are concerned, it may be stated, in a general way, that rest in bed is of the utmost importance and it should be insisted upon in all cases. Free catharsis and the administration of 5-grain doses of aspirin every four hours, or a sufficient amount of salol and phenacetin to control the pain—usually 2½

grains of phenacetin with 2½ grains of salol every hour for three or four hours—will suffice, after which time the dose may be repeated at intervals of three to six hours when necessary. The immersion of the feet in hot mustard water at the commencement is of beneficial effect in relieving the intense turgescence of the nasal mucosa. At all times the secretions from the nose and nasopharynx should frequently be washed away, precisely as in simple acute rhinitis, care being taken to advise patients to avoid forcible blowing of the nose, an act which is liable to force infection into the Eustachian tubes.

Sinus involvement should be treated as laid down in the chapters on diseases of the nasal accessory sinuses and an infectious grippal otitis media as advised in Chapter XVIII.

RHINITIS OF THE ACUTE EXANTHEMATA AND OTHER SYSTEMIC INFECTIONS.

The rhinitis accompanying the acute exanthemata and other systemic infections is mentioned in Chapter XXXI, but we reaffirm that it is unusually severe, especially in measles, and should receive special treatment from the very commencement of the disease. In measles the turgescence of the mucosa is sufficient to materially affect nasal respiration and phonation, and it is the chief symptom noticeable during the stage of invasion. This is invariably accompanied by rise of temperature, cough, congestion of the conjunctiva, more or less headache, and occasionally nausea. These symptoms usually precede the appearance of the characteristic rash by two to four days. The symptoms are present, but less marked and less permanent with pertussis, scarlet fever, and other infectious diseases. Of late much has been written concerning pansinusitis as a complication of measles and scarlet fever, particularly the latter.

DIPHTHERITIC RHINITIS.

For detailed description see Chapter XXXI. Diphtheritic rhinitis is sometimes observed as an accompaniment of faucial diphtheria. Occasionally nasal diphtheria occurs primarily, and then the diphtheritic membrane limits itself to the nasal mucosa. It may exist for a considerable period, its exact nature being revealed only upon a careful inspection of the nasal cavities and an examination by culture for the Klebs-Loeffler bacillus. The treatment is the same as for faucial diphtheria, antitoxin, etc. (see Chapter XXXI).

MEMBRANOUS RHINITIS.

Membranous rhinitis is an inflammation involving the mucosa of the nasal cavities, which results in a membranous formation that involves not only the epithelial, but also the subepithelial portions of the membrane. By many it is believed to be diphtheritic, but clinical experience, supported by microscopical findings, whereby it is shown that many cases occur without the presence of the

Klebs-Loeffler bacillus, would seem to indicate that this disease may occur independently of diphtheria. Individuals living in badly ventilated, damp and otherwise unhygienic quarters are peculiarly liable to membranous rhinitis. It sometimes occurs as a result of traumatism and severe irritants.

Locally, hydrogen dioxid in dilution 1 to 3, used as a spray or alkaline antiseptic douching, will separate the false membrane. Occasionally, however, it becomes necessary to gently remove portions of the membranous tissue, which may relieve the obstruction for a time.

Inasmuch as membranous rhinitis is most prevalent in children of a lymphatic or rachitic type, dietetic and tonic treatment is the most beneficial in these cases. Syrupus ferri iodidi et syrupus calcii lactophosphas are the best internal remedies.

ACUTE RHINITIS DUE TO LOCAL SPECIFIC INFECTIONS (Gonorrhea, Erysipelas).

Gonorrheal rhinitis is always secondary. Young infants with gonorrheal ophthalmia occasionally are victims of the nasal form.

For the treatment of the nasal involvement in gonorrheal rhinitis frequent applications of a 25 per cent. argyrol solution, after cleansing the nasal chambers with an alkaline or boric acid wash, will arrest the infection. For the control of treatment, the microscopic examination of smears from the discharge will reveal the presence or absence of Neisser's gonococci.

Whenever erysipelas invades the nasal cavities it is liable to be accompanied by an acute rhinitis of unusual severity, which manifests a tendency to extend to contiguous membranes. High temperature is one of its marked symptoms. Facial erysipelas is supposed to have its infection atrium in an abrasion or fissure about the nasal vestibule.

The general treatment of erysipelas is fully outlined on pages 100, 252, and 476. Locally, simple cleansing of the mucosa with non-irritating alkaline sprays affords relief to the distressing intranasal inflammation.

ACUTE RHINITIS DUE TO CHEMICAL AND MECHANICAL (TRAUMATIC) CAUSES.

Acute inflammation involving the nasal mucosa may result from the inhalation of poisonous or hot vapors or fumes, as from ammonia, the corrosive acids, iodin, bromin, etc., or vitiated air laden with irritating mineral and vegetable dust particles, or smoke, and usually is accompanied by a similar inflammatory condition along the entire respiratory tract. This, and the mechanical type have sometimes been referred to as "occupation rhinitis." The susceptibility of certain individuals is marked, especially to the gases in chemical laboratories, mines, foundries, artificial ice plants, and manufacturing establishments where chemicals are used in large quantities. After a prolonged sojourn in the pure air of the

country, patients returning to the city are prone to develop acute rhinitis of this type.

In the acute rhinitis resulting from mechanical causes the inflammation arises from intranasal traumatism, either accidental or operative, or from the inhalation of dust-laden atmosphere in mines, granaries, mills, in wood sawing or carving shops, in gold, silver and brass smithies, stone-cutting, and other irritating manufacturing and industrial pursuits.

Intranasal operations, the removal of septal spurs or turbinal hypertrophies, even when done under strict aseptic precautions, are usually followed by sufficient reaction to produce more or less general inflammation of the nasal mucosa.

Symptoms.—In the rhinitis due to chemical causes, such as the inhalation of noxious vapors and dust in the various pursuits enumerated above, the local symptoms differ from the acute type of rhinitis in that they come on suddenly, are more severe, and the nasal and lower respiratory tissues become edematous and obstructed. When the mucosa of the pharynx and the larynx becomes slightly edematous, mild dyspnea, cough and dysphagia are thereby induced. These symptoms come on rapidly, and, in the severer cases when accompanied by extensive edema which extends to the larynx, asphyxia is threatened.

With the rhinitis caused by irritation from mechanical causes, the local nasal symptoms do not differ from those already discussed under the acute catarrhal variety; but the accompanying inflammatory condition along the rest of the respiratory tract is of a slow, chronic type, with bronchial or pulmonary involvement, producing a form of pneumonokoniosis, associated with cough, expectoration, and emaciation.

Diagnosis.—In these cases a diagnosis is readily made from the history of the case and by inspection.

Prognosis.—In the severe type (chemical) the prognosis is unfavorable, on account of the danger of a fatal termination from acute edema of the larynx and lungs. In the milder type the prognosis is unfavorable when the inflammatory process terminates in deep sloughing of the mucosa with its concomitant septic absorption.

In the rhinitis due to mechanical causes the prognosis is good when the patient is withdrawn from the vicious environment or baneful occupation.

Treatment.—The rhinitis of mechanical irritation is amenable to the same treatment as prescribed for an acute or chronic catarrhal rhinitis. The treatment for the inflammatory reaction after operative manipulation is given on page 536.

For the mild form of pharyngeal and laryngeal edema in the chemical variety, scarification, puncture and spraying with adrenalin solution 1:2000, or an aqueous cold-iced 50 per cent. ichthyol solution have been found efficacious in reducing the waterlogged condition of the connective-tissue spaces of the submucosa.

A favorite spray in common use at the Manhattan Eye, Ear and Throat Hospital for the relief of this condition is made up as follows:—

℞ Glyceride tannin,
Lemon juice,
Adrenalin chloride (1:1000)
Normal salt solution ..... āā ʒij

Sig. Keep in ice box and spray larynx every half hour.

Where asphyxia threatens, a tracheotomy becomes imperative.

CHAPTER XXXIV.

CHRONIC INFLAMMATORY AFFECTIONS OF THE NOSE.

CHRONIC RHINITIS.

SIMPLE CHRONIC RHINITIS.

Synonyms.—Chronic coryza, chronic blennorrhea, rhinitis chronica, chronic nasal catarrh.

Simple chronic rhinitis is a chronic inflammation of the nasal mucosa, accompanied by hyperemia, swelling and varying degrees of hyperplasia of the soft tissues, and changes in the secretions. The thickening of the mucous membrane varies according to the stage and severity of the disease. In the milder cases it is limited to a slight hyperplasia; but, when the disease is prolonged and of a severe type, the mucosa becomes the seat of turgescence, moderate hyperplasia and edematous infiltration.

Etiology.—In simple chronic rhinitis the etiology differs only slightly from that of acute catarrhal rhinitis. In a general way the condition is attributed to long-continued factors of variable character, among which are the intranasal obstructions, impurities of the inspired air, or frequently recurring attacks of acute rhinitis, from which a perfect recovery has not taken place. The predisposing causes are also quite similar to those attending simple acute rhinitis. Diathesis plays an important rôle. Hence, gouty, rheumatic, diabetic, and strumous patients are peculiarly liable.

Pathology.—In simple chronic rhinitis there is at first an intense engorgement of the blood-vessels, both venous and arterial, which tend to lose their contractile power. Later there is marked relaxation of the tissues, with exudation of cell elements and the gradual increase in connective-tissue formation. Later on, contraction takes place which may eventuate in glandular atrophy. This affection is probably due primarily to an invasion of pathogenic micro-organisms in a large proportion of cases, in proof of which may be cited the preponderance of patients in whom the disease dates from the exanthemata and other systemic affections. The bacillus of Friedländer, being found in all cases, is most likely the infectious agent, although the disease may be prolonged by saprophytic germs having their habitat in the nasal secretory products, thus irritating the mucosa.

Symptoms.—The chief clinical phenomena of simple chronic rhinitis are increased secretion and intranasal obstruction. The discharge during the earlier stages while profuse is of a watery character. As the condition becomes more chronic it becomes mucopurulent, with a tendency to the formation of crusts. Hawking and spitting are complained of; the obstruction is usually more noticeable at night and is liable to be attended with complete

occlusion of one or both nostrils. The obstruction may alternate from one side to the other. The swelling of the mucosa is sometimes influenced by gravitation, in which event the most dependent side during sleep becomes obstructed, so that the patient by sleeping first upon one side and then upon the other is able to alternate his nasal breathing.

Sufferers from simple chronic rhinitis are unduly prone to acute attacks. Along with the symptoms of simple rhinitis, dull pain over the bridge of the nose, frontal headache, and mental dullness (aprosexia) are complained of. The nasopharynx and larynx are often simultaneously involved, and the mucosa is often bathed with a mucopurulent exudate. Upon palpation the engorged tissues will be found extremely boggy and soft. Invasion of the Eustachian tube produces tubal obstruction and thereby causes attacks of acute catarrhal otitis media (see Chapter XVI).

Diagnosis.—The diagnosis of simple chronic rhinitis is not difficult to determine, except to differentiate between the simple and the hypertrophic forms. The diagnosis is founded upon the clinical history and the changes in the nasal mucosa, the latter being determinable by inspection, palpation and the character of the discharge.

Prognosis.—The disease is aggravated to such a degree by environment, climate, and occupation that it is often a difficult matter to entirely eradicate it. The prognosis is favorably influenced by the adoption of measures which increase the resisting power of the individual (see page 497). This is accomplished by outdoor exercise, bathing (cold baths in the morning), the regulation of diet, and by the correction of individual habits which may be detrimental to one's efforts to relieve and cure. A cure, however, is no guarantee against future attacks. In neglected cases the tissue changes gradually increase until well-marked hypertrophy becomes noticeable and the disease becomes a true hypertrophic rhinitis.

Treatment.—Preliminary to local or operative interference the general physical condition of the patient should be carefully investigated. A history of rheumatism, gout, lithemia, diabetes, renal or hepatic lesions or syphilis necessitates proper internal, dietetic, and hygienic treatment. All reasonable means should be employed for developing the bodily resistance to acute attacks, in accordance with the suggestions outlined under preventive treatment of acute catarrhal rhinitis (Chapter XXXIII). While positive and permanent tissue changes may not be corrected by the above-mentioned measures, at least the further progress of the disease may be retarded. A very large percentage of cases of simple chronic rhinitis come under this general heading and are greatly relieved by constitutional and hygienic treatment.

Septal spurs, deflections, and deviations (Chapter XXXV), when of sufficient size or of such shape as to interfere with respiration or drainage (Fig. 310), or when they remain in contact with the turbinated tissues (Fig. 362), should be considered as having a

causal relation to the disease and should be promptly removed. The same holds true with deformed, enlarged, or cystic turbinal bones (see Chapter XXXVI), although these are more prevalent in the hyperplastic form of the disease. All intranasal obstructions, unless due to temporary hyperemia and congestion, should be removed by some form of operative interference. Usually the best results are obtained by combining needed surgical and constitutional treatment with frequent and thorough cleansing of the nasal cavities by means of bland saline solutions, and proper attention to hygiene and diet.

Simple congestion and swelling of the tissues when unaccompanied by hyperplastic changes do not require and should not be subjected to operative treatment. The temptation to cut or destroy the tissues at this stage is often very great. Occasionally, on account of the enormous and apparently uncontrollable swelling, it may be necessary to remove certain small portions in order to re-establish drainage and respiration. Under such circumstances the tissues should be removed surgically by means of clean cuts with knife or scissors (see Fig. 349); never by caustics. Escharotics leave ugly sloughs, sometimes deeply seated, and accomplish but little permanent benefit.

After-treatment.—Intranasal cleansing for a long period of time is often necessary, and, in damp or changeable climates, the majority of inhabitants have sufficient chronic rhinitis to require at least morning cleansing of the nasal cavities.

CHRONIC HYPERPLASTIC (HYPERTROPHIC) RHINITIS.

Synonyms.—Chronic hypertrophic rhinitis, hypertrophy of the turbinated bones, hypertrophic nasal catarrh.

In the hypertrophic or hyperplastic form, chronic rhinitis is an inflammatory process which involves the nasal mucosa, more especially the turbinal tissues, and is accompanied by permanent increase in the soft tissues and changes in the character of the secretions.

Etiology.—The hypertrophic form of chronic rhinitis is always a result of prolonged or neglected simple chronic rhinitis. The inflammation which accompanies recurrent attacks of the acute and prolonged simple chronic rhinitis must inevitably lead to sufficient tissue increase to produce true hyperplasia. Deformities, enlargements of the turbinated bones (see Chapter XXXVI), septal spurs and deflections (see Chapter XXXV), by causing pressure upon the surrounding tissues and interfering with drainage and respiration, become common etiological factors. Defects in nasal conformation whereby the nostrils do not sufficiently dilate to admit of proper nasal respiration are frequently overlooked etiologically. The affection is extremely liable to occur in patients who suffer from such constitutional diseases as rheumatism, gout, diabetes, and anemia, and it is influenced by climate, occupation, diet, and habits of living. Advanced chronic and hyperplastic rhinitis is rarely observed under adult age, and men seem to be more susceptible to it than women.

Pathology.—During the early stages the turgescence may largely be accounted for by a general and almost continuous dilatation of the blood-vessels, but the dilatation gradually becomes complicated by connective-tissue infiltration and gradual increase in the thickness and density of the soft tissues. As the disease progresses, the walls of the blood-vessels also become thickened and infiltrated, the tissue increase receiving its blood-supply from newly developed capillaries. The hyperplasia is chiefly located in the tissues covering the inferior turbinal bone, the posterior end of which frequently becomes enormously enlarged (Fig. 355), its outer surface uneven, sometimes with deep lobulations and indentations. Smooth, circumscribed excrescences have been designated as polypoid hypertrophies or degenerations and hyperplasias; those with very uneven surfaces as papillomata (Hofmann); but these designations are objectionable from an histological point of view.

Symptoms.—The chief clinical phenomena are nasal obstruction, greatly altered secretions, and in many instances slight odor. The degree of nasal obstruction depends upon the severity of the disease and the location of the swelling, and it varies from partial permeability to total closure of the nasal chambers. None of these symptoms should be considered absolutely pathognomonic, inasmuch as they are also observed in simple chronic rhinitis and in those individuals who suffer from nasal deformities which produce obstruction. In the chronic form, however, the symptoms mentioned are almost constantly present, although varying in degree. The mucosa of the affected parts is thickened, congested, and often bathed with a mucopurulent exudate. Hyperplasia, even to a slight degree in narrow nostrils, is sufficient to give rise to marked evidence of nasal obstruction. In youthful individuals true hyperplasia rarely is found, the simple chronic catarrhal form being more prevalent before puberty. During the earlier stages the mucous membrane usually is much reddened, but, when the hyperplasia is excessive, and shows a tendency to polypoid appearance, with uneven or lobulated surfaces, the membrane often becomes pale and usually is covered with a mucopurulent secretion. Enlargement of the turbinal bone itself is occasionally observed, but is not the rule. Variations in shape, particularly of the inferior turbinals, are often mistaken for enlargement. As a rule, deformities of the septum are present, with ridges or spurs, which impinge upon the soft tissues and thus aggravate the symptoms. In nervous or sensitive individuals the nasal obstruction constitutes an extremely annoying symptom, especially at night, at which time the obstruction alternates from side to side, by gravitating toward the side which is next to the pillow. Mouth-breathing, especially at night, becomes the rule, and it is often accompanied by snoring. An annoying symptom resulting from mouth-breathing is the extreme dryness of the mouth and throat. In advanced cases of long standing there is diminution or loss of the sense of smell (anosmia).

Nasal obstruction, long continued, results secondarily in marked interference with the mucous membrane of the postnasal and pharyngeal regions, whereby it gradually becomes congested and inflamed.

Occasionally nasal polypi will be found, although as a rule these tumors are directly caused by chronic infection of the accessory sinuses and commonly protrude from their orifices. The obstructive lesion within the nasal chambers usually interferes with the resonance (timbre) of the voice. The obstruction as a rule arises from the inferior turbinal, and the soft tissues in its immediate vicinity often become much hypertrophied. Occasionally aprosexia ensues on account of the long-continued intranasal pressure, and headache is a common symptom. The secretion is always altered in proportion to the extent of the inflammatory changes which have taken place in the soft tissues. The secretion shows a tendency to become viscid and thick, and clings to the surfaces with considerable tenacity, sometimes becoming incrusted, in which event its removal is difficult. Infection of the retained secretions with saprophytic bacteria results in fermentation and an offensive odor, a condition which undoubtedly produces much local irritation of the mucosa.

Of the more remote symptoms the following are noteworthy, viz., *cough,* due to the presence of the secretion in the nasopharynx; *hawking* and *clearing* of the throat; *sneezing* evoked by contact pressure of opposing membranes; *sensations* of *pressure* about the eyes and forehead; *surface ulcerations* upon the *septum* and *mucous membranes; excoriations* and *redness* about the nasal orifices, and, finally, tinnitus and a sensation of fullness in the ears.

Diagnosis.—An exhaustive examination of the entire nasal and nasopharyngeal tract is essential in order to render a positive diagnosis, and it should be conducted in the following manner: After ascertaining a history of the case from the patient, he should be subjected to a thorough examination of the nasal passages, beginning with an anterior rhinoscopic examination, meanwhile carefully noting the color of the membrane, the degree of its apparent thickening, the location of such thickening, the general form of the turbinals, the presence or absence of septal deflections and spurs, and the amount and nature of the secretions. This should be followed by posterior rhinoscopy, thereby observing the general appearance of the mucosa of the rhinopharynx, whether adenoids or adhesive bands are present, the conditions of the posterior ends of the turbinals, and the patulency of the orifices of the Eustachian tubes. The nature of the postnasal secretions likewise should be determined. Knowing that the intumescence accompanying acute coryza and simple chronic catarrh, and that the engorgement resulting from plethora, local irritants or neuroses, are accompanied with apparent true hyperplasia, means of differentiation should be employed. This is best accomplished by spraying the entire mucous surface with a weak solution of cocaine. This application is imme-

diately followed by rapid reduction of the engorgement which attends the simpler forms of congestion, and even in that associated with a simple chronic catarrh. True hyperplasia, however, still will remain, but the superficial engorgement will be reduced, even in hyperplastic conditions. The employment of suprarenal solution is less efficacious for diagnostic purposes, inasmuch as the effects of the remedy are too drastic and the contraction of the blood-vessels is too extensive.

Examination subsequent to the cocaine shrinkage will, if true hyperplasia be present, reveal the following conditions, depending upon the stage and extent of the pathological process. Examination with the probe, with slight pressure upon any portion of the hyperplastic areas, will reveal a boggy condition, upon which, if indentations are made, the impression fills in rather slowly, the contrary being true when the enlargement is due to turgescence of the mucosa. The rapid resumption from the indentations indicates an early stage of the disease, or that the affection is not true hyperplasia. The chronicity of the hyperplastic development is proportionate with the length of time observed in the filling in of indentations.

In some cases the under surface of the inferior turbinal is found to rest upon the meatal floor after cocainization, and retained secretions are located along the lateral nasal wall. The hyperplasias often amount to mulberry-like tumors, which surround the posterior ends of the inferior turbinals (Fig. 354). Usually these are nodular, but occasionally the surfaces are smooth and glistening. In extreme cases the same mulberry-like pendulous membranous enlargement may extend along the entire under surface of the inferior turbinal, and protrude into the epipharynx, where they are commonly mistaken for polypi. Extensive hyperplasia of the tissues covering the middle turbinal, unaccompanied by complicating sinus infection, is rare.

A membranous thickening upon one or both sides of the nasal septum, usually more marked in the upper portion or along the attachment of the vomer and cartilaginous portions, occasionally occurs. Such thickenings to a mild degree are usually present.

The peculiar pale, rounded mass will be observed along the posterior border of the vomer, just inside the choanæ and is seen only by posterior rhinoscopy. These are prone to occur when deflections or spurs are present, although occasionally they are bilateral.

One or more of the above-described conditions may be present in the same patient. While chronic hyperplastic rhinitis rarely is unilateral, often there is marked variation in the two sides. When associated with septal deflections or spurs the disease may be limited to the side upon which such spurs or deflections exist.

Differential Diagnosis.—The application of cocaine spray eliminates the more acute swelling which accompanies acute coryza, simple chronic catarrh and the various neuroses. At the same time

it brings into view deflections, spurs, polypi, and foreign bodies. The tumors, whether malignant or benign, such as fibromata, polypi and malignant growths, usually are circumscribed, while hyperplastic swellings cover larger segments of the mucosa. Hyperplasia gives an air-cushion sensation upon contact with the probe; whereas fibromata admit of considerable motion and are denser.

Malignant growths are localized, dense, and accompanied with glandular enlargement and other characteristic symptoms (see Chapter XLII).

Prognosis.—Under proper hygienic surroundings, when unaccompanied by grave general disease, in patients who submit to the proper local and surgical treatment the prognosis is favorable. The chief difficulties are those resulting from habits of life, occupation, general environment and systemic diseases.

Treatment.—Medicinal treatment, whether applied locally or administered internally, is palliative and of some benefit, nevertheless it is inadequate on account of the presence of the inflammatory new formations; hence operative procedures of some form must be relied upon for permanent relief. Extensive operations, however, rarely are necessary, except in advanced cases where more or less obstruction has taken place. It is important that the mucous surfaces be kept clean as possible and all retained secretions removed. For this purpose bland, non-irritating alkaline sprays are most efficacious.

After cleansing, the surfaces should be sprayed with a medicated oily preparation (Douglas formula of benzoinol, page 499) both for the purpose of protecting the freshly cleansed membrane from the deleterious influences of dust or even exposure to cold air, and to obtain the benefit of the local application of the medicaments. The majority of the spray solutions in general use are too strong and induce a marked irritating effect upon the nasal mucosa, which results in a prolonged watery secretion from the nose. Sprays containing glycerin produce like effects. Postoperative spraying is also essential in order to remove excessive secretions and to maintain at least partially aseptic surfaces.

Rheumatism, gout, diabetes and that form of malnutrition in which an excess of uric acid is present require prompt and thorough internal administration of proper remedial agents. When accompanied by disturbances of digestion and assimilation marked amelioration of the intranasal symptoms will be obtained by the administration of cathartics and other remedies which tend to restore these functions. Patients of plethoric habit, the gouty, the alcoholic or dyspeptic types should submit to regulation of diet, abstain from excesses of alcohol and tobacco, take sufficient exercise and avoid overheated rooms. A sojourn at some healthful resort, especially where a simple *régime* with baths, etc., is enforced, is most beneficial. For patients of the thin, neurotic type, Parker recommends the following mixture to be taken three times a day:—

℞ Citrate of iron and ammonium ..... gr. x.
Carbonate of ammonium ..... gr. v.
Fowler's solution ..... ♏iij.
Tr. nux vomica ..... ♏v.
Glycerin ..... ♏xv.
Water .....q. s. ad ℥j.

The suggestions made under the preventive treatment of simple acute rhinitis, page 497, should be adopted.

The operative treatment of hypertrophic rhinitis is described in Chapters XXXV and XXXVI.

ATROPHIC RHINITIS AND OZENA.

Atrophic rhinitis, chronic atrophic rhinitis, cirrhotic rhinitis, rhinitis sicca and rhinitis atrophica are the synonyms applied to an atrophic state of the nasal mucosa and turbinal structures, resulting from one of several inflammatory processes. Marked variations in character, extent, and symptoms are observed during a careful study of a series of cases of atrophic rhinitis.

In some individuals the mucous membrane only is involved, and occasionally one cavity only, while in others there is a marked tendency to absorption of the bony structures within the nose and the accumulation of masses of malodorous inspissated crusts. The simple form may not be attended with distinctive symptoms, but the secretions are always altered as a result of the pathological changes.

Etiology.—The actual cause of atrophic rhinitis never has been definitely demonstrated, although much speculation has been indulged in by careful observers whose conclusions have shown wide variance. The author's observations, based largely upon clinical experience, have convinced him that the condition results from a considerable number of etiological factors acting either alone or in combination. That an inflammatory process of long duration, or one which has rapidly involved the nasal mucosa, and which furthermore has seriously interfered with the blood-vessels of these parts and consequently with the nutrition of the tissues, thereby inducing hyperplasia, should finally result in such further alterations in nutrition as to produce serious structural degeneration, resulting in atrophy, does not seem improbable. Clinically this undoubtedly occurs, but why this result should be found in one case and true hypertrophy of both mucosa and bone in another, which never terminates in atrophy, it is difficult to understand. That atrophy often occurs without a preceding hypertrophy may be easily demonstrated, proving definitely that the atrophic state is not necessarily to be considered as a later stage of an hypertrophic inflammatory process. While opinions vary as to the primary or secondary nature of atrophic rhinitis the preponderance of evidence favors the view that it is always secondary to some pre-existing local inflammation. Syphilis should not be considered as having any causal relation, although occasionally a specific history accom-

panies the disease, as do tuberculous and other grave systemic affections. Micro-organisms, accessory-sinus disease, glandular degenerative processes, individual idiosyncrasy and diathesis may play a part, but are not specific etiological factors.

In its simplest form it may not be a degenerative process, inasmuch as the cellular tissue having become so impaired and reduced as a result of diminished nutrition may produce what must be termed simple atrophy, a condition which readily improves as soon as its cause is removed. In this form the contraction observed follows a pre-existing inflammation which has lessened the vascular supply to the part.

Another simple variety, usually local and unilateral, results from the pressure of septal deflections or spurs.

It is doubtful whether atrophic rhinitis *per se* is an inflammatory condition. Simple atrophy, however, should not be confounded with the more chronic form wherein a true degeneration has taken place.

Abnormally wide nasal cavities in rather flat noses seem to furnish a large proportion of intranasal atrophy. A hereditary tendency to this affection is often discovered. Traumatism, infectious diseases, especially membranous rhinitis, and the pernicious results of inhalations of poisonous fumes and prolonged subjection to insufficient nourishment and badly ventilated living rooms, are important etiological factors. The condition rarely begins after the twenty-fifth year. The larger proportion of cases manifests a tendency to the disease in early life, at about the twelfth year, exceptionally earlier—and it is more common in females than in males. It almost invariably is accompanied by anemia.

Pathology.—In the severer forms the following pathological alterations in the mucosa are to be observed: The normal epithelium gradually desquamates, and the surface of the membrane assumes a smooth, pale, unnatural appearance. Changes in the submucosa result in a marked decrease in the connective tissue. With this is associated a gradual obliteration of the glandular structures, and a marked tendency to obliteration of the blood-vessels. As the contraction progresses, the structures become more or less fibrous, and finally the turbinal bones atrophy. The lower turbinals diminish in size or disappear entirely, while the middle turbinals usually remain in part, even in the severe cases. Bacteria of many varieties are invariably found, but so far no typical pathological organism has been isolated.

Symptoms.—The prominent symptom noted in this disease is the marked alteration in the character of the secretion. Visual examination reveals wide-open nostrils, with a more or less complete loss of the normal anatomical landmarks, and a marked change in the color and general appearance of the mucosa. The mucous membrane frequently is obscured by greenish colored, inspissated masses, underneath which are areas of ulceration. Associated with the dark crusts there is usually an accumulation of purulent or mucopurulent secretion, occupying the more depend-

ent portions of the nares, and commonly purulent secretion is seen in the ethmoid region. Unless the nasal cavities have been recently cleansed they are partially or wholly filled with masses of inspissated secretion, and when ozena is present marked fetor will be noted. The odor is not unlike that which accompanies bone necrosis. It is extremely fetid and probably because of the decomposition which has taken place in the mucopurulent discharge. Some authors believe there is a special ferment in these secretions, an opinion that is not without reason, inasmuch as an ordinary purulent rhinitis, with apparently the same character of secretion, may go on almost indefinitely emitting an ordinary catarrhal odor only. Victims of this affection rarely are conscious of the distressing odor, inasmuch as the terminal filaments of the olfactory nerve have been involved in the atrophic process.

Ozena.—The term ozena, derived from the Greek ὄξαινα, meaning a fetid polypus in the nose, designates a peculiar diffuse disease of the nasal mucosa, which is characterized by the production of a thick, specific, highly offensive secretion, with a tendency to the formation of flakes and crusts, and attended by atrophy of the mucosa, together with certain portions of the subjacent framework of the interior of the nose (Zarniko). The early writers undoubtedly made use of the term to cover all intranasal diseases attended with odor, whether syphilitic or simple ozena. Later on its use became more restricted, and it was employed to designate catarrhal conditions which are characterized by the decomposition of retained intranasal secretions, but it was still looked upon as a disease rather than a symptom. According to our present understanding, the term practically stands for an affection which has been described under Zarniko's definition. It becomes necessary, however, to differentiate various other diseases, which may be accompanied by offensive odor, as, for example, syphilitic necrosis, certain accessory-sinus diseases, glanders, and some neoplasms.

At the 1917 meeting of the American Laryngological Association, Dr. Lewis A. Coffin in presenting a series of X-ray pictures, showing diseased sinuses in children, remarked that "the condition shown, unless spontaneously recovering, is the forerunner of a future atrophic rhinitis." He drew attention to the following points: 1, the frequency with which the antrum had shown disease; 2, that the antrum when diseased is often most foul as to odor—a condition obtaining in no other sinus; 3, that many cases of ozena in his hands had cleared entirely as to odor from opening, ventilating and washing the antrum through the inferior meatus; 4, that, in fact, only one of about twelve, so treated, had failed to clear up as to odor; and 5, that he attributed this failure to the fact that the odor of ozena is due to the stagnating and putrefying processes that take place in a chronically diseased antrum.

Bosworth[1] probably is correct in his deduction that in atrophic rhinitis there is marked decrease in the quantity of nasal secretion, and that the apparent discharge in atrophic rhinitis is partially due

[1] Diseases of the Nose and Throat, p. 169.

to the fact that, on account of the long pre-existing inflammatory process, the normal serous exosmosis has subsided.

The presence of large masses of secretion gives rise to symptoms of obstruction which entirely subsides after their removal, and, while, with wide-open notrils, clear of discharge, the intake of air is usually free, the dryness of the membranes often extends to the nasopharynx and larynx, where it induces annoying irritation. Superficial ulceration, although rare, sometimes occurs, especially along the cartilaginous portion of the septum, and is due to constant picking of the nose in an effort to remove the crusts. These ulcerations occasionally go on to perforation of the septum. The crust masses usually remain *in situ* for several days, finally being forced out of place and dislodged in whole or in part as the result of the effort of the patient to obtain relief from the annoying obstruction. Unless aided by sprays or douches the cavities rarely ever become thoroughly clean and free from crusts. Epistaxis occasionally follows the efforts to dislodge the retained secretion, especially if vigorous mechanical means are employed. The dryness of the pharynx and larynx probably results from the loss of normal moisture imparted to the air in its course through the nasal cavities. In severe cases masses of dried, inspissated mucus form in the epipharynx, thereby causing a sensation of irritation which necessitates vigorous efforts for removal. A common complication in advanced cases is a tendency to a deposit of crusts upon the walls of the pharynx, larynx, and trachea in consequence of the lack of moisture which is normally imparted to the air while passing through the nasal cavities

Differential Diagnosis.—It is necessary to differentiate ozena as a symptom from chronic sinusitis other than the antrum. Syphilitic and tuberculous lesions, especially when there has been marked destruction of tissue, resulting from necrosis of both the soft and bony intranasal structures, may be confounded with atrophic rhinitis. Syphilis with necrosis produces an odor quite similar to ozena. Acquired syphilis, however, rarely occurs in extreme youth, and even when suspected a clear history usually can be elicited. The odor which accompanies prolonged retention of foreign bodies in the nasal cavities may be confounded with ozena, but a rhinoscopic examination, aided by the probe, usually reveals the foreign body if present.

Prognosis.—In this disease the mucous membrane has well-nigh lost its normal secreting function, and its glandular structures have largely become obliterated. Marked changes both in the mucosa and the submucosa also have occurred; the turbinals have become reduced and their erectile function destroyed. With these known and incurable conditions the prognosis is unfavorable so far as complete restoration of normal function is concerned. Even to modify the discharge and control the symptoms require frequent and indefinitely continued treatment. During the earlier stages in the class of cases where the apparent atrophy has resulted from some pre-existent local lesions, such as deformities of the septum, septal spurs, etc., or from empyema of the accessory sinuses, it is quite possible to arrest the disease and often to restore the functions of the nasal mucosa. The same applies to treat-

ment inaugurated early in the history of the disease, and antedating the period when fetid symptoms appear. Fortunately after middle life the disease tends to become less annoying, with less tendency to the formation of crusts and hence less fetor.

Treatment.—In every case a careful investigation of both antra should be made and if necessary a radiograph obtained. If disease of the antrum is found it should be eradicated by proper surgical interference. Local treatment should be antedated by a careful physical examination of the patient and a minute inquiry pertaining to the general history. The varieties and severity of the diseases from which the individual has suffered and any grave constitutional disease or hereditary tendency, should be given full consideration. As a rule these patients require well-directed internal medication in the form of iron, cod-liver oil, potassium iodid and the hypophosphites, and full instructions relating to hygiene, diet, and habits of life.

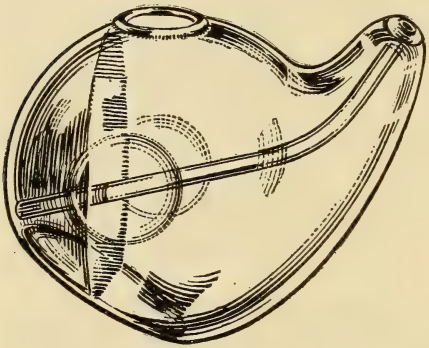

Fig. 304.—Fowler's nasal douche.

The primary indication in the local treatment of the disease is the softening and removal of the secretions and thorough cleansing of the nasal mucosa. Two general varieties of medicaments are appropriate for this purpose: first, those employed for softening and removing the incrustations and secretions; second, those employed for deodorizing the surfaces and stimulating the mucosa. The ordinary intranasal spray apparatus is of little avail, inasmuch as an insufficient quantity of fluid can be sprayed. A fountain syringe or some form of douche-cup (Fig. 304) or postnasal syringe (Fig. 305) are requisite, in order to separate the crusts, and bland aqueous solutions should be employed. A powder made up of sodium bicarbonate and sodium chlorid in the proportion of two to one, kept dry, of which a teaspoonful may be used in a pint of warm water for syringing or douching, will suffice, although other alkaline solutions may be used. Whenever the masses are unusually dry and tenacious the cleansing process will be facilitated by employing a warm solution (1 to 3 dilution) of peroxid of hydrogen to be followed by the blander solutions heretofore mentioned. Kyle recommends the following mixture for cleansing the mucous surfaces:—

℞ Sodii biboratis,
Sodii bicarbonatis,
Sodii chloratis,
Potassii bicarbonatis ..... āā gr. xv.
Acidi carbolici ..... ♏ iij.
Aquæ destillatæ ..... q. s. ad ℥ij.
M. Sig.: To be used with nasal douche.

Patients should be instructed how to properly employ the douche and thus avoid its dangers. The Fowler nasal douche (Fig. 304) obviates the dangers in part. Any ordinary douche-bag or receptacle, having been filled with the solution, should be hung at a point just a little above the level of the nose, with the tip introduced into one nostril; the patient in the meantime should breathe through the wide-open mouth, with the head bent slightly forward. This will close off the nasopharynx from the oropharynx, and the water flowing into one nostril will return from the other. Too much force should not be used, and it is imperative that the patient should be cautioned not to blow the nose in the ordinary way—by closing one nostril—but to blow both nostrils simultaneously without finger pressure and in this way dislodge the crusts. These precautions are necessary in order to prevent the introduction of infection into the middle ear. Mddle-ear infection occasionally occurs from the injudicious use of the nasal douche, but, if the precautions heretofore mentioned are followed, this unfortunate accident will not occur. While, as a rule, patients should be advised against the use of the nasal douche for ordinary catarrhal conditions, in atrophic rhinitis with ozena its employment is justifiable. After a

Fig. 305.—Postnasal syringe.

few minutes the larger masses will loosen and come away. It is important, however, that every particle of retained secretion should be removed at each treatment, by means of cotton probe or forceps. The author has found that dipping the cotton-tipped probe into rather hot water aids materially in wiping away the remaining secretion.

The postnasal region should also be inspected and completely cleansed. For this purpose it is sometimes necessary to use a small throat mirror while wiping away the crusts with a curved applicator. The author's flexible silver applicator (Fig. 438) serves well for this purpose. After thorough cleansing, the entire mucosa should be subjected to an application of some form of stimulating and disinfecting solution. For this purpose ichthyol heads the list. The following formula is recommended:—

℞ Ichthyol,
Glycerin ..... āā ʒij.
Aquæ ..... q. s. ad ℥j.

This should be wiped over the entire surface by means of cotton-tipped applicators. More recent experience with argyrol in 25 per cent. solution has also shown favorable results. Variations in the remedies used are desirable, both in the cleansing and the stimulating applications. The Mandel solutions, in the following formulæ, are also highly commended by various authors, for applying to the nasal membranes after the secretions have been removed.

MANDEL No. 1.

℞ Glycerin ..... ℥v.
Potassium iodid..... ʒij.
Iodin ..... ʒss.

MANDEL No. 2.

℞ Glycerin ..... ℥v.
Potassium iodid..... ʒiv.
Iodin ..... ʒj.

MANDEL No. 3.

℞ Glycerin ..... ℥v.
Potassium iodid..... ʒvj.
Iodin ..... ʒiss.

The acetotartrate of aluminum in the proportion of from ½ to 1 dram to the ounce has both a stimulating and antiseptic effect upon the membranes.

Packing the nose with cotton lint or gauze, thereby causing a watery secretion, is a painful procedure and would be available for the nasal cavities only, and is of doubtful efficiency.

The above treatment does not contemplate the restoration of the altered mucosa. Its real purpose is to rid the patient of the disgusting stench and discomfort of the retained secretions, and possibly to arrest the further progress of the disease. Patients usually seek relief from the ozena, and they should receive the encouraging advice that by persistent and long-continued treatment, aided by intelligent and carefully directed home treatment, the distressing symptoms at least may be controlled. They should frankly be told that in order to accomplish this the treatment must be painstaking and long continued. They should be taught how properly to use the douche and to make local applications to the nasal mucous membrane, and even to that of the nasopharynx. It is quite possible to train these patients to use even the postnasal syringe with safety. Two or three daily home treatments and several office treatments each week for a period of several months will be necessary. Home treatment night and morning at least will be found necessary for an almost indefinite period of time. It is often difficult to persuade patients to persist in carrying out the twice-daily intranasal cleansing after they become comparatively free from the formation of crusts.

Vibratory massage of the nasal mucosa is a painful procedure. Mechanically it gives rise to considerable watery secretion, but its results are *nil*. The same holds true with the galvanic current. The galvanocautery is contraindicated, inasmuch as in this disease it is reprehensible to destroy any tissue within the nose, except unhealthy granulations or polypi. Ulcerating surfaces should be cleansed and touched with a solution of nitrate of silver, 30 to 60 grains to the ounce.

A. Blau has recommended the use of paraffin to build up atrophied turbinal bones in order to secure normal circulation of

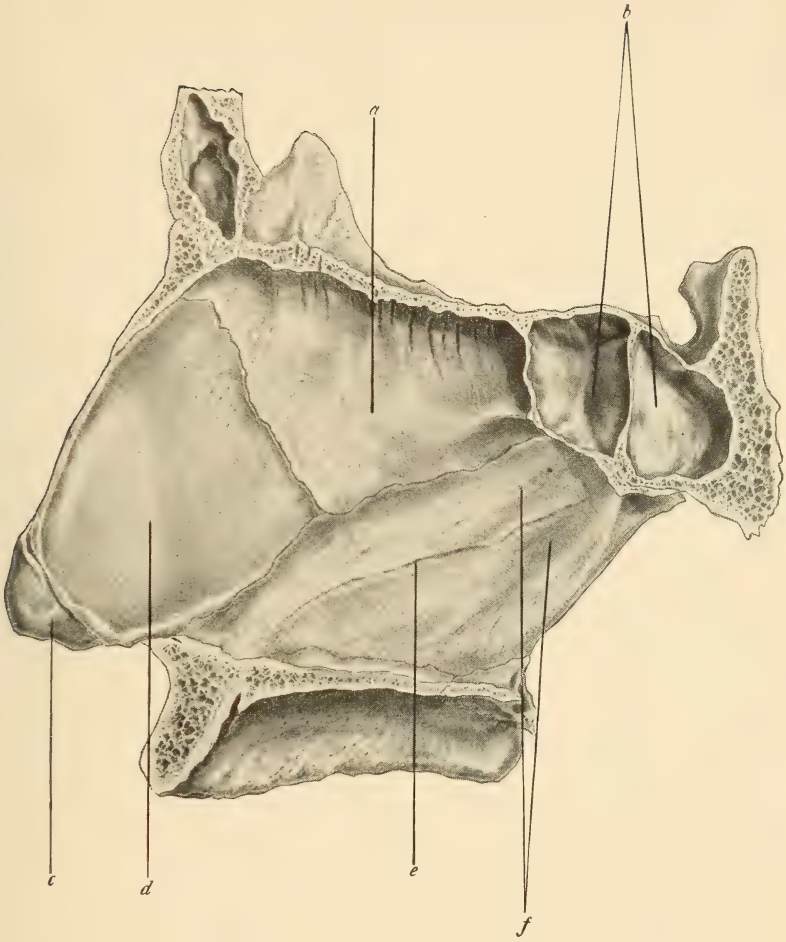

Fig. 306.—The anatomical formation of the nasal septum.
(From *Deaver,* with permission.)

a, Perpendicular plate of ethmoid.
b, Sphenoidal sinus.
c, Inferior lateral cartilage.
d, Septal cartilage.
e, Groove for nasopalatine nerve.
f, Vomer.

the air current in the nares. The operation consists in an attempt to reconstruct the form of the inferior turbinal tissues by means of injections of semisolid paraffin into the submucous tissues. It is claimed that the following results are obtained: 1, the secretion becomes thinner; 2, the tendency to the formation of crusts is lessened, and, 3, a larger surface of mucous membrane is gained, and thereby more moisture is imparted to the inspired air.

Lake recommends that the injections be small, with repetitions at intervals of about one week. The method requires a needle three inches in length, which is attached to the paraffin syringe (Fig. 420). In three cases reported by Broeckart there were decided changes in the secretion, and the crust formations diminished. The technique of paraffin injections is described in Chapter XL. The lactic acid bacillus in pure culture has been recommended for the local treatment of this affection. From 15 to 20 minims of the solution should be dropped into the nostril, the head being thrown backward in order that the solution may flow over the nasal mucosa.

The high-frequency current also has been advocated as a measure of local treatment. The current should be applied directly to the diseased mucosa by means of small, especially devised applicators.

CHRONIC PURULENT RHINITIS.

Synonyms.—Suppurative rhinitis, purulent nasal catarrh.

Definition.—Chronic purulent inflammation of the nasal mucosa, unaccompanied by purulent sinusitis, is a rare affection. It is characterized by a persistent purulent rhinorrhea, due to infection of the nasal mucous membranes, and usually dates from childhood.

Bosworth contends that it occurs as a primary affection in children and eventuates in atrophic rhinitis in adult life. It should be differentiated from the far more common purulent sinusitis.

Etiology.—It is believed to be primarily due to some acute infectious disease like the exanthemata, and to be aggravated by attacks of simple acute rhinitis.

It is probable that in a considerable proportion of the cases the primary infection occurs at birth from infected vaginal secretions from the mother. Kyle describes two cases in adults in which the infection was carried to the nasal mucosa, one from the urethra and the other from a discharging ear, by means of the patient's finger.

Purulent rhinitis rarely is seen by the rhinologist during the incipient stage. There is a profuse discharge of an admixture of pus and mucus in varying proportions. The mucous membrane becomes the seat of marked hyperemia, but without bogginess or hyperplasia.

Symptoms.—The predominating symptom is a persistent discharge from both nostrils of a yellowish, viscid, mucopurulent fluid. While the rhinorrhea is not fetid, it often is so profuse that the nasal cavities become blocked and the excess flows backward into

the pharynx and forward over the surface of the upper lip. Temporary relief from the obstructive symptoms is obtained by blowing or washing out the retained secretion.

Diagnosis.—The diagnosis is based upon a painstaking examination of the anterior nasal cavities in order to exclude purulent sinusitis, foreign bodies and tuberculous and syphilitic affections as a cause of the rhinorrhea.

Prognosis.—Without treatment the disease tends to progress, and there is considerable ground for the belief that it may eventuate in chronic atrophic rhinitis with ozena. Cases which during the early stage are placed under proper treatment usually recover, but any changes which have taken place in the structure of the mucous membrane will remain permanent.

Treatment.—The prophylactic treatment heretofore described for simple catarrhal rhinitis should be inaugurated at once (Chapter XXXIII), in order to build up the resisting power of the patient and to lessen the tendency to exacerbations. If any underlying constitutional affection is discovered, it should be subjected to proper internal treatment, to which iron, cod-liver oil, or arsenic may be added with benefit.

Locally, the treatment should consist in keeping the nasal mucosa as clear and as free from retention of pus as possible. In children the nasal douche employed two or three times daily, precisely the same as for scarlet fever and diphtheria (Fig. 290), is most effective for cleansing purposes. Meanwhile, all the precautions heretofore mentioned under the treatment of atrophic rhinitis should be observed, in order to preserve the middle ear from infection.

As a preliminary measure, and for the purpose of actively attacking the pus secretion, the nose may be sprayed once a day with a dilute solution of hydrogen peroxid (Kyle), to be followed by a douche of normal physiological salt solution, or a saturated solution of boric acid, or the following:—

℞ Sodii bicarb.,	
Sodii biborat.	āā ʒss.
Borolyptol	ʒiv.
White sugar	ʒij.
Aquæ	q. s. ad ℥viij.

Solutions of hydrarg. bichlorid, while unavailable for young children, may be employed in older persons, but in the nose the strength of the solution should not exceed 1 : 8000, or 1 : 10,000.

Following the cleansing process the membrane should be wiped dry with a cotton-tipped applicator, after which an astringent should be applied. The astringent may be applied in the form of a spray or by means of cotton carriers. Nitrate of silver solution, from 10 to 30 grains to the ounce, or solution of argyrol, 25 per cent., may be applied over the entire diseased surface.

Bosworth recommends a formula as follows:—

℞ Sulphocarbolate of zinc..... gr. xl.
Bichlorid of mercury..... gr. ⅖.
Aquæ .....q. s. ad ℥viij.
M. Sig.: Apply to the mucous surfaces after cleansing.

By carefully and persistently carrying out the treatment outlined above, in the majority of cases a successful outcome may be expected. It is often necessary to prolong the treatment for several months in order to succeed.

RHINITIS FROM SPECIFIC INFLAMMATIONS
(Diphtheria, Scarlatina, Measles, Grippe, etc.).

See Chapters XXIX, XXX, XXXI, and XXXII, on the Influence of General Medical Diseases upon the Ear, Nose, and Throat.

RHINITIS CASEOSA.

This rare affection receives its name from its chief symptom, which is a persistent exudation of fetid, cheesy secretion into the nasal chambers.

Etiology.—While its cause is not definitely known, it is believed to result from some grave constitutional disease like tuberculosis or syphilis, associated with chronic rhinitis.

Pathology.—There is no distinctive pathological lesion; neither is there any definite micro-organism in the discharge.

According to Kyle, the caseous exudate contains microscopically granular leucocytes, fatty cells, cholesterin crystals and stearin.

Symptoms.—The chief symptoms are loss of the sense of smell, considerable headache, nasal obstruction, and discharge of extremely fetid odor.

Treatment.—1. Thorough cleansing and scraping away of the accumulated material, aided by sprays of dilute peroxid of hydrogen, or boric acid solution.

2. A thorough examination of the intranasal structures and accessory sinuses, in order to ascertain whether they are the seat of specific lesions.

3. Destruction of granulations, removal of necrosed bone when found.

4. The application of solutions of silver nitrate 10 to 30 grains to the ounce; or argyrol, 25 per cent., to the mucosa.

CHAPTER XXXV.

THE NASAL SEPTUM AND ITS PATHOLOGICAL CONDITIONS.

ANATOMY.

THREE individual structures enter into the formation of the nasal septum. The lower posterior portion is formed by the vomer, the upper posterior by the perpendicular plate of the ethmoid, and the remaining or anterior portion by the triangular cartilage (Fig. 306), the latter being the portion chiefly involved in septal deformities. The entire framework consists of the vomer, the perpendicular plate of the ethmoid, the palatine crests, the rostrum of the sphenoid, and the triangular cartilage.

The vomer is rhomboid in shape, its lower margin being united with the palatine and nasal crests, the upper short margin deviating to form two wing-like projections (alæ vomeris), between which the rostrum of the sphenoid is inserted.

The septum is thickest about its lower one-third, at the point of junction between the vomer and the palatine and nasal crests; the upper olfactory region and the anterior portions of the septum are relatively thin. The choanæ are separated by the posterior concave margin of the vomer. The perpendicular plate of the ethmoid is connected anteriorly with the triangular cartilage and posteriorly with the vomer, with which it is blended.

The cartilaginous septum is irregular in outline, variable in size, and separates the anterior portion of the nasal cavities. The lower anterior margin lies free (columna nasi). This portion of the cartilage is often spoken of as the membranous septum. Its upper margin is interposed between the lateral cartilages of the external nose, reaching upward as far as the nasal crest. The entire septum as far as the columna nasi is covered with mucous membrane. The mucosa is firmly united with the periosteum and the perichondrium, forming a fibromucous membrane which cannot be readily separated from its base, especially at the anterior portion.

The nasal septum receives its blood-supply from the nasopalatine, the anterior and the posterior ethmoid and the septal arteries, the chief source of supply being the nasopalatine.

In the mucosa of the septum, in its upper segment, a large proportion of the ramifications from the olfactory bulb are situated. The sensory nerve supply comes from the first and second branches of the trigeminus, the vidian and the nasopalatine branch from Meckel's ganglion. The septum serves the double purpose of dividing the nasal cavity into two conical or wedge-shaped compartments, and at the same time serves as an important factor in the framework and the general conformation of the nose.

DEFORMITIES OF THE NASAL SEPTUM.

The deformities of the nasal septum may be divided into three general varieties: 1, those resulting from simple spurs or crests; 2, deviations or deflections; 3, perforations, the result either of

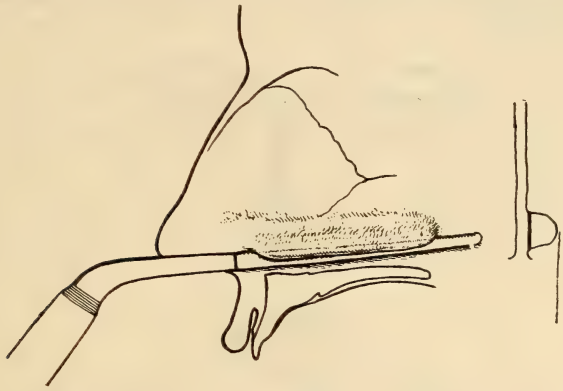

Fig. 307.—Septal spur parallel with the floor of the nasal cavity. The dotted lines indicate the line to be followed in removal by means of saw.

ulceration or traumatism. Added to this the deformity is sometimes simulated, either at its base or its upper portion, by an accumulation of mucous glands, and by synechia.

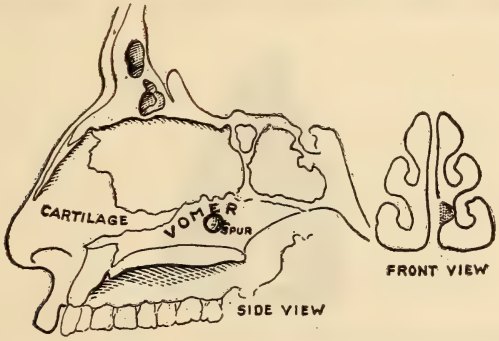

Fig. 308.—The cone-shaped septal spur situated upon the vomer.

Septal Spurs.—Local thickenings and cartilaginous or bony ridges on the septum are designated as spurs, which usually appear in the form of crests or spines. When the outgrowth occurs on the cartilaginous septum it is known as an ecchondrosis, and when occurring on the osseous portion of the septum it is termed an exostosis. These may be present either with or without deviations.

Their direction is generally anteroposterior, parallel to the floor of the nose (Fig. 307), or projecting at a right angle from the

septum, but occasionally they are vertical. Parker describes a spur which is located along the junction of the perpendicular plate of the ethmoid with the vomer, and runs in an upward and backward direction.

Another less common form is a cone-shaped offshoot from the vomer, which has a broad base and is located well back upon the vomer (Fig. 308).

Fig. 309.—A deflected septum of normal thickness throughout and without spurs or crests.

Deviations and Deflections.—In early life, up to about the seventh year, the septum is practically straight (Fig. 363) in 80 per cent. of individuals; it is rarely deviated in primitive peoples. In adult life, however, fully 76 per cent. show deflections, to the left more frequently than to the right, and this condition is the com-

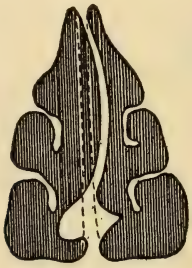

Fig. 310.—A deflected and thickened septum with a ridge upon each side.

monest of all the abnormalities found within the nasal cavity. It may be described as a permanent bending of the septum from the median line, whereby the nasal cavities are no longer divided symmetrically, one cavity being widened at the expense of the other.

The variations in form, extent and location are numerous and difficult of classification. Two general varieties, however, may be described: (*a*) those in which the septum is of normal thickness and unaccompanied by spurs, ridges or crests (Fig. 309); (*b*)

deflections (with or without thickenings) which are accompanied by one or more spurs, ridges or crests (Fig. 310).

The subdivisions of these varieties are many, depending on the location and general direction of the deformity. The more common subdivisions are: 1, those in which the deflection assumes an anteroposterior direction, the apparent bending being from above downward, the concave lower portion assuming an anteroposterior direction; 2, a common variety in which the deflection assumes a vertical direction, the line of convexity being also vertical (Fig. 311); 3, a variety often described as a sigmoid or S-shaped deflection (Fig. 312), in which the deformity is so placed that the anterior portion of the septum projects into one naris, and the posterior portion into the naris of the opposite side; 4, a less common but extremely troublesome variety, in which the septum assumes a variety of irregular forms difficult to describe, and usually resulting from violent traumatism; 5, a type in which the

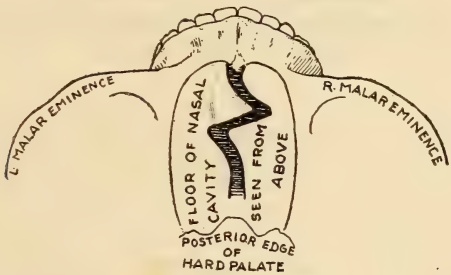

Fig. 311.—The vertical deflection of the nasal septum.

deflection is so situated that the lower (anterior) margin projects into the opposite nostril, where it produces obstruction (Fig. 338).

The subdivisions of the second class are practically the same, but in each case the deformity is accompanied by inflammatory thickenings in the form of crests or spurs. Coakley[1] has aptly illustrated these deflections by making use of a blotter, held with the long sides parallel to the floor while the two short sides are pressed upon, when the blotter will be seen to bend, the convexity now being vertical. The S-shaped deviations of the septum are represented by the doubly bent blotter.

These general forms, in varying degrees, practically represent the types to be observed. Considerable variations may take place without seriously interfering with respiration and drainage, or without inducing pressure symptoms; yet a deflection may be so extreme as to render respiration on the affected side impossible, and at other times crests or spurs impinge upon the tissues of the lateral nasal wall, thereby causing inflammatory and pressure symptoms.

---

[1] Diseases of the Nose and Throat, p. 124.

Deflections commonly exert severe pressure upon the middle turbinal, and even force this structure upward and outward from its normal location.

Etiology.—Various theories have been advanced concerning the causation of septal deformities. In many instances, however, their advocates have advanced but little proof. The chief causative agents in producing septal deformities are:—

(*a*) *Congenital Malformations.*—These occur in but a small percentage of the cases.

(*b*) *The arrested or the excessive development of the facial bones* are factors likewise found in a small proportion of the cases of septal deflections. Furthermore, the method of septal development is conducive to a variety of deformities which occur as a result of facial asymmetry and malformation of the contiguous bony structures, especially of the hard palate.

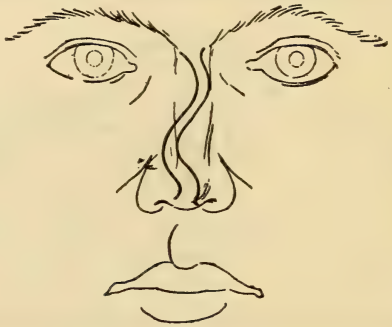

Fig. 312.—A diagrammatic representation of the sigmoid or S-shaped deflection.

(*c*) *Traumatism,* which is probably the commonest factor in the etiology of these deformities. The prominent location of the nose renders it extremely liable to injury by direct violence either during instrumental delivery at birth, or in the accidents of later life, the septum suffering by trauma more frequently than other parts of the nasal scaffolding. A blow or fall on the nose during childhood is often forgotten, and the low grade inflammatory process at the site of injury progresses and increases the deformity as nasal development progresses. This accounts for the fact that in the majority of cases relief is only sought after childhood. According to Mosher, "trauma as well as delayed eruption of the incisor teeth can displace the premaxillary wings and distort the vomer groove, resulting in spurs and causing deviations anteriorly and posteriorly."

Pathology.—Where the irregularity of the septum is due to a simple outgrowth or spur, it is defined either as an ecchondrosis (cartilaginous), or an exostosis (bony). The ecchondrosis is usually found on the anterior portion of the septum and the exostosis on the posterior portion. Occasionally a spur may be

both cartilaginous and bony. Ridges or crests are found at different places along the lines of junction of the cartilaginous and bony portions of the septum, and may project into either nostril. Spurs and ridges are usually no hindrance, but may cause more or less obstruction to nasal respiration and drainage, or be the points of origin for reflex disturbances.

When the deviations are due to traumatism, the inflammatory changes in the perichondrium and periosteum of the septum may result in localized thickenings with negative pressure, which in turn may induce attacks of catarrhal or purulent inflammation of the nasal mucosa and the accessory nasal cavities.

Symptoms.—The symptomatology varies according to the degree of septal deformity. Slight deformity, whether due to spur or deflection, produces no symptoms. Where the deflection or deviation is marked, external nasal deformity may be noticed and symptoms of obstruction, either to respiration or drainage, are in evidence. The patient complains of inability to breathe freely through the nose, obstructed breathing being mostly on the side of the septal convexity. It is worse at night, and often causes mouth-breathing.

Catarrhal inflammation sooner or later develops behind the obstruction, first of the nasal mucous membrane, later of the pharynx, and in severe cases it extends to the larynx and bronchi, thereby causing discharge, cough and alteration of the voice. Headache, vertigo and aprosexia may result from the retarded drainage of the accessory nasal cavities. High deviations are prone to induce frontal headaches, which are more severe in the morning hours, in contradistinction to those of ocular origin.

In young individuals defective development, particularly of the chest, and impairment of the general health are among the later manifestations.

Locally there may be itching, discharge and sneezing. Attacks of epistaxis are due to the patient's interference with crusts on either the septum or spurs. The sense of smell and taste may be impaired or perverted. Tinnitus and chronic catarrhal otitis media also are associated with nasal obstruction of septal origin. Of the reflex symptoms which are evoked by impingement of the deflection or spur upon the turbinal tissues, headache, neuralgia and sneezing, rhinorrhea, hay fever and asthma are the chief.

Differential Diagnosis.—A careful rhinoscopic examination is sufficient to determine a deviation or deflection of the septum. A concavity is found on one side of the septum, and on the other side the corresponding convexity. Upon the concave side the inferior turbinal is usually swollen or hypertrophied. At times the external contour of the nose is twisted or bent toward the side of convexity.

Spurs or ridges are differentiated from the simple thickenings of the mucous membrane by palpating with the probe. A syphilitic gumma of the septum is usually situated on either side of the septum high up, and has a boggy feel when palpated. Furthermore, it soon disappears under antiluetic treatment.

In fractures of the nasal bones, if recent, one can elicit crepitus; but in an old fracture as a rule the nasal bones are displaced outward and the septum appears thickened above and posteriorly. In

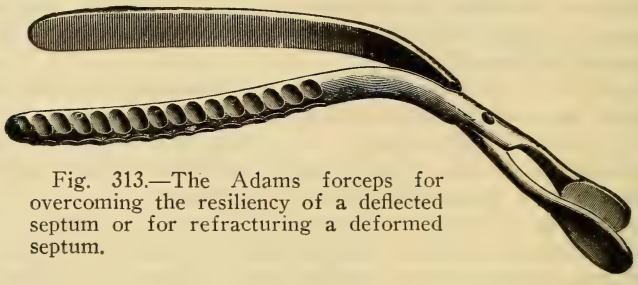

Fig. 313.—The Adams forceps for overcoming the resiliency of a deflected septum or for refracturing a deformed septum.

an abscess or hematoma of the septum one usually can obtain a history of a recent traumatism, and palpation with the probe will aid

Fig. 314.—Ballenger's mucosa knife.

in differentiating either condition from a septal deviation. Tumors of the septum, malignant or benign (see Chapter XLII), are readily distinguished from either septal deflections or deviations.

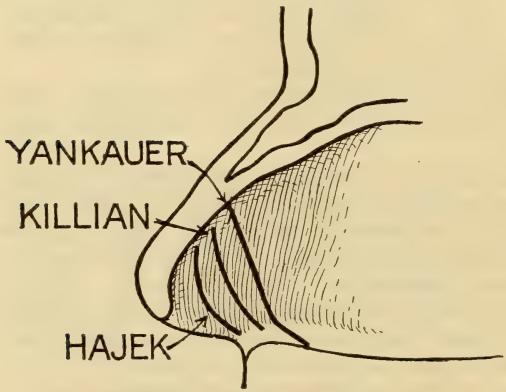

Fig. 315.—Showing the line of incision employed by Hajek, Killian, and Yankauer.

Treatment.—Owing to the character of its structure, surgical measures only will prove efficacious for the correction of the various deformities of the nasal septum. Surgical interference, however, is indicated only in those cases in which the deformity impedes respiration or obstructs nasal drainage, with or without congestive phenomena; when reflex neuroses or aural complications are encountered, or in those cases where it becomes necessary to relieve stenosis in order to gain access to the accessory sinuses. Occasionally, when the septal deformity is not great, a partial removal of the inferior turbinal will suffice to re-establish proper nasal respiration and drainage.

Walshman has well defined the indications for the removal of spurs: 1, when they impede free breathing through the nose; 2, when they appear to be the cause of reflex irritation; 3, when they are the seat

of ulceration, with or without hemorrhage; 4, when they present at the external nares and cause external deformity. To these may be added occasional cases when the operation becomes necessary in order to allow the introduction of the Eustachian catheter in the treatment of middle ear diseases.

Operations Upon the Nasal Septum.—Various operations have been devised and recommended for the correction of septal deformities, nearly all within recent years.

Of these operations which include the Asch, the Roe, the Gleason and the Submucous Resection, all have fallen into disuse except the last named. Therefore, in this edition the author has purposely eliminated the text and illustrations of the three operations first named, which are no longer employed by rhinologists.

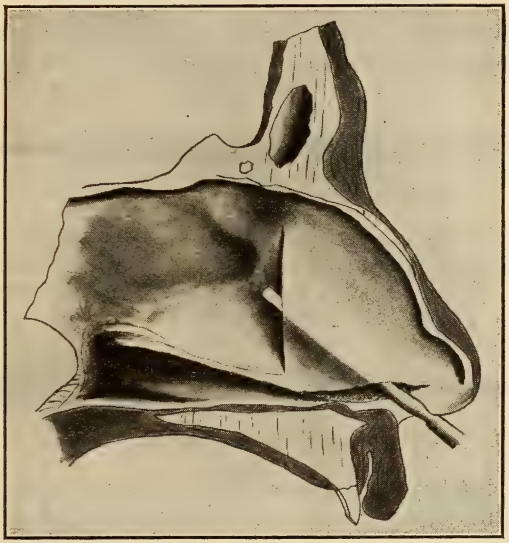

Fig. 316.—Freer's L-shaped incision for the submucous resection operation. Note the point which remains uncut until the balance of flap has been elevated.

Submucous Resection of the Nasal Septum.—The submucous resection operation contemplates the complete removal of the cartilage and bone which compose the deformed part of the septum, allowing the perichondrium and mucous membrane of either side to fall together and form a septum without its deformed intermediary framework.

In preparing the patient for a septal operation all hair should be clipped from both nasal vestibules. This procedure is an aid to cleanliness and it gives the operator a clearer view of the deeper portions of the nasal cavities. The nasal cavities should then be thoroughly cleansed with a normal saline solution, and the upper lip, the nose, the adjacent areas, and the vestibules should be painted with iodine, followed by a wash of alcohol. Twenty grains

of sodium bromid administered a half-hour before the operation acts as a sedative and to that extent adds to the patient's comfort.

The length of time taken to properly perform the operation is from twenty minutes to one hour, and it never should be under-

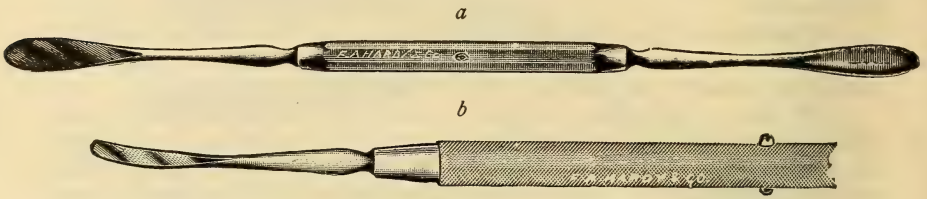

Fig. 317.—Perichondrium elevators. *a,* Ballenger's. *b,* Freer's.

taken unless the operator has sufficient time to work with deliberation. It is preferably performed under local anesthesia, inasmuch as the hemorrhage rarely is sufficient to interfere with the work, the field may the more easily be illuminated, and the patient in

Fig. 318.—Dunning's periosteal elevator.

various ways is thereby enabled to render valuable assistance, especially in changing the position of his head. Cocaine or alypin, in solution of 5 to 20 per cent. combined with adrenalin chlorid solution, from 1:5000 to 1:1000, applied to both surfaces of the

Fig. 319.—Small oval curet for penetrating the septal cartilage.

septum for about twenty minutes, may be relied upon to completely anesthetize the septal tissues. The crystals of cocaine, when rubbed upon the septal surfaces with a pledget of cotton moistened (Freer) in adrenalin solution, 1:100, will more rapidly produce

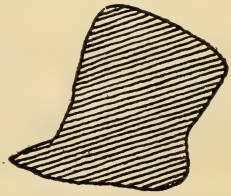

Fig. 320.—Specimen of septal cartilage removed with the swivel knife.

anesthesia, and are thought to block the vascular and lymphatic channels of the mucosa, and so prevent systemic poisoning from absorption of the local anesthetic.

The most practical mixture for local anesthesia in the nose is made by mixing equal parts of a 10 per cent. cocaine solution and

a 1:1000 adrenalin chlorid solution. This combination produces a mixture containing 5 per cent. cocaine and adrenalin chlorid 1:2000. This combination is ample for prolonged local anesthesia, is safe and can be freely applied by means of cotton pledgets. The hypodermic injection of a few drops of a ½ of 1 per cent. solution of

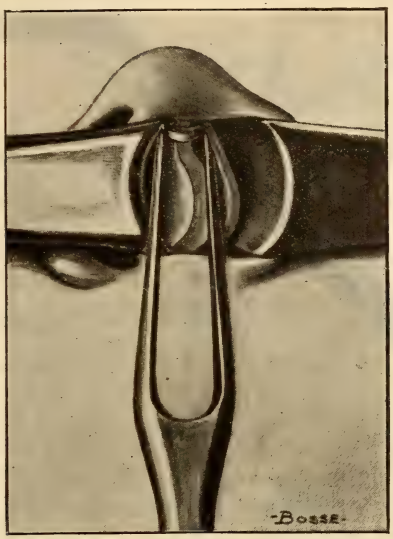

Fig. 321.—The mucochondrium has been separated from both sides of the cartilage in accordance with the description in the text. The Ballenger swivel knife is inserted into the cartilage incision preparatory to its removal. (Partly schematic.)

cocaine or of a 2 per cent. solution of novocaine underneath the mucochondrium at various points, but particularly at the area of the primary incision, not only induces rapid anesthesia, but, by partially separating the mucochondrium from the cartilage, renders valuable assistance in that step of the operation.

Fig. 322.—The Ballenger swivel knife.

While the operation may thus be performed without actual pain, the suffering of the patient should never be lightly considered, inasmuch as, almost invariably, rather severe shock attends this operative procedure. It is often necessary to administer a stimulant in the form of whiskey or a dram of the aromatic spirits of ammonia if the patient feels faint, or he should be allowed to lie down for a few minutes. The discomforts which arise from faintness and shock may largely be obviated by placing the patient upon

an operating table, with the headrest elevated to the highest position. Furthermore this position does not materially interfere with the technique of the operation. The operation preferably should be performed in a hospital, so that the patient immediately may retire and remain in bed until the following day. If done in the

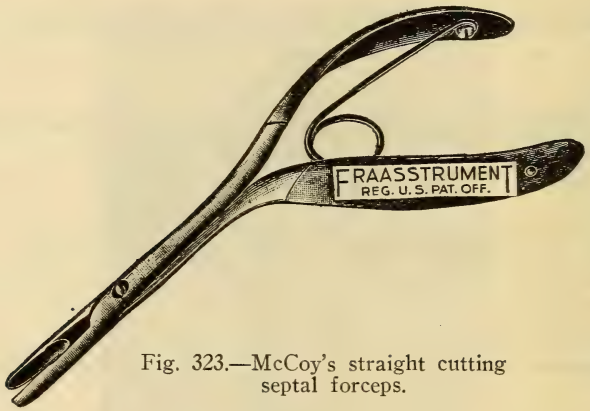

Fig. 323.—McCoy's straight cutting septal forceps.

operator's office, the patient should be taken to his home in a car or other conveyance and not allowed to walk through the streets.

Operation.—The primary incision through the mucous membrane and the perichondrium is, by most operators, made upon the convex surface.

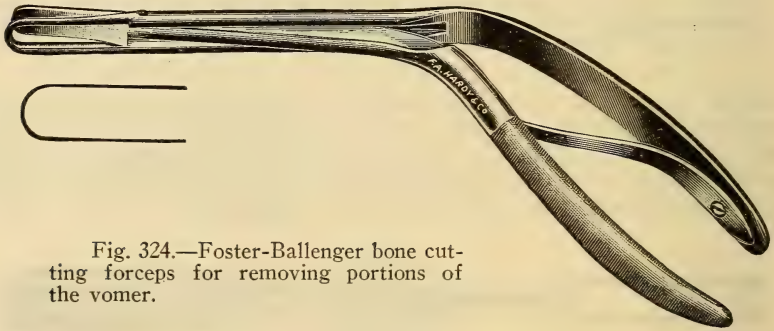

Fig. 324.—Foster-Ballenger bone cutting forceps for removing portions of the vomer.

The location of the incision, its length and its direction may be left to the individuality of the operator so long as the cartilage is finally exposed and incised well in front of the septal band.

The incisions recommended by Killian, Hajek and Yankauer are similar, the latter extending the lower limit across the floor of the vestibule (Fig. 315), while that of Freer (Fig. 316) is termed the reverse L-incision.

In following the Freer plan a horizontal incision is made along the base of the septum at its junction with the nasal floor, extending about one inch from the mucocutaneous junction within the

vestibule. A vertical incision is then made to intersect with the inner end of the horizontal one, but during the process of elevating the mucochondrium a small segment between the intersecting points of the two incisions should be left intact (Fig. 316).

Having completed the elevating of the mucochondrium the small segment is cut and the flap is reflected forward and upward, where it is held by a retractor.



Fig. 325.—Carter's fenestrated nasal speculum.

If one of the incisions first mentioned has been employed, the mucous membrane and perichondrium of the corresponding side should then be separated from the cartilage by means of special elevators (Figs. 317, 318), which should be moved in an upward and downward direction in their long axis in order to prevent

Fig. 326.—Dann's self-retaining nasal speculum.

accidental perforation of the mucous membrane. By completing the separation with the long edge of a blunt elevator, the mucochondrium and periosteum are stripped from the septum.

Having separated the mucous membrane from the septal cartilage over a wide area upon the side of the primary incision a vertical incision is made through the cartilage to the perichondrium of the opposite side, following the line of the primary incision in

the mucous membrane. Great pains should be taken not to wound the mucous membrane of the opposite side. A safer method is to scrape through the cartilage to the perichondrium of the opposite side with a small curet (Yankauer) (Fig. 319). Through this in-

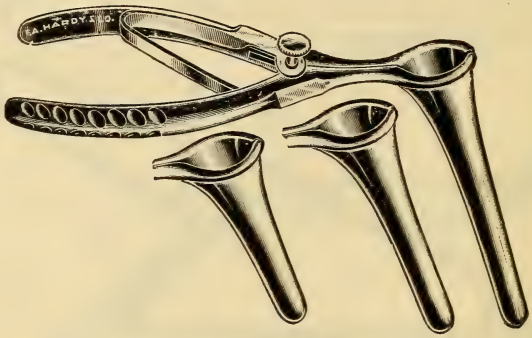

Fig. 327.—Killian's submucous speculum.

cision or excavation in the cartilage a small elevator is passed, and the perichondrium and mucosa are carefully separated from a similar area upon the opposite side of the septum (Fig. 321). This must be done with extreme care and deliberation in order to avoid

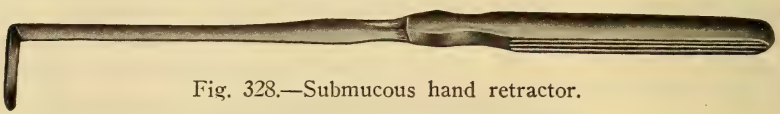

Fig. 328.—Submucous hand retractor.

tearing or bruising the mucous membrane, with the attendant danger of sloughing or perforation.

When the mucochondrium has been well separated from the

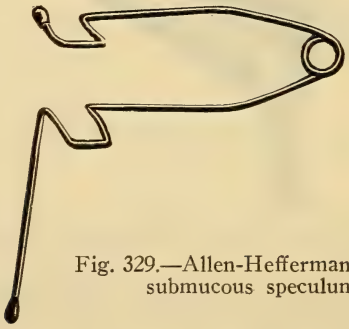

Fig. 329.—Allen-Heffermann's submucous speculum.

septum on both sides, the cartilage is removed piecemeal with a cutting forceps, or preferably in its entirety (Fig. 320) with the Ballenger swivel knife (Figs. 322 and 323). This instrument is perfectly adapted to this purpose, it is entirely safe and it shortens the time of operation. The procedure up to this point, however,

must be considered as preliminary to the real operation, which consists in the removal of the deflected portions of the vomer, the perpendicular plate of the ethmoid and the maxillary ridge. Spreading open the primary incision through the membrane, the operator will easily see the projecting edge of the cartilage that remains, or if all the cartilage has been removed the edges of the vomer come into view. Sharp cutting forceps (Fig. 323) should now be carefully introduced and the balance of the deflection removed. The two mucosa curtains are best held apart by either

Fig. 330.—Yankauer's periosteum elevator.

Killian's long submucous speculum (Fig. 327) or one of the various retractors (Fig. 328) or specula (Figs. 325, 326) devised for this purpose.

To gain access to the maxillary ridge a sharp separator is often necessary for the purpose of separating the periosteum along the floor; Yankauer's instrument (Fig. 330) is useful for this manipulation. The ridge is removed either by cutting forceps (Fig. 323) or the Hajek crotch chisel (Fig. 334) driven with a mallet. The latter (Fig. 335) is more accurate and hence is preferable for the removal of the ridge, and a large portion of this bony tissue should be excised. For the vomer and ethmoidal portions the various punch forceps or small, slender rongeur forceps serve the purpose.

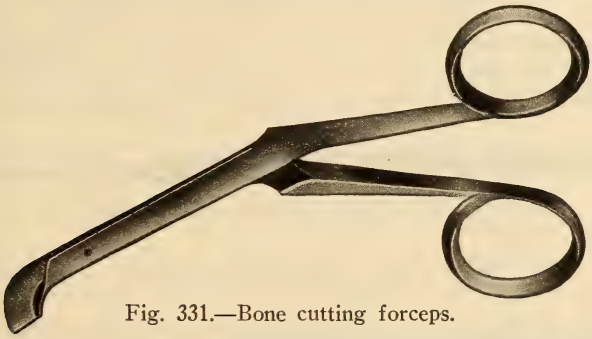

Fig. 331.—Bone cutting forceps.

The full measure of success depends upon the complete removal of all parts of the septal framework which enter into the deflection or obstruction.

In removing the cartilaginous portion of the septum it is advisable to retain sufficient cartilage along the bridge of the nose and the frenum to maintain its symmetry, and thus avoid the so-called "saddleback" nose.

After complete removal of bone and cartilage, the operative field between the mucous membranes is douched with normal saline solution in order to wash out the *débris* of excised cartilage; then the surfaces of the mucochondrium should be drawn together and

the cut edges approximated as nearly as possible. Sutures (Fig. 332) should be employed whenever they may be utilized to prevent perforations. The Jansen curved needles are admirably adapted for this purpose.

The convex side is packed well back with sterile vaselin gauze, or a strip of sterile rubber tissue is first pushed well back in the nasal cavity where the convexity existed, and against this rubber tissue sufficient plain sterile gauze is packed to fill the cavity. The vaselin gauze and the rubber tissue prevent adhesion of the packing to the mucous membrane, and likewise make the removal of the dressing easier; the opposite nostril should be similarly but lightly packed. The packing lessens the tendency to postoperative hemorrhage and prevents the formation of hematomata.

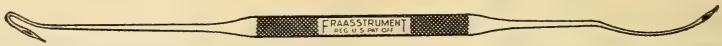

Fig. 332.—Yankauer's suture needle.

Secondary hemorrhage is rare. Ballenger introduces a Simpson sponge tent (Fig. 342) into each nostril instead of the gauze packing, and removes them in from twenty-four to forty-eight hours.

After-treatment.—The patient should remain in bed until the following day, and the further after-treatment should consist in the removal of the packing after twenty-four to forty-eight hours, the packing being thereafter dispensed with. The nasal cavities are douched daily for cleansing purposes with a normal saline solution. A Douglass douche bag (Fig. 336), or the Fowler nasal douche (Fig. 304), is practical for this purpose, but violent "blowing" of the nose should be avoided for some time after douching.

Sutures should be removed about the third day. The incisions heal in from four to seven days when the mucous membrane has

Fig. 333.—Pierce's submucous dissector.

not been torn; otherwise granulations appear and final healing is delayed. Slight postoperative thickenings about the maxillary ridge often disappear by absorption after a few weeks.

Yankauer's instruments, which are illustrated in Fig. 337, facilitate the submucous operation, and need no further description.

With the exception of the resection operation, the above-described operative procedures depend upon some form of crushing or breaking of the septal cartilage for the purpose of overcoming its resiliency. They, therefore, represent one general type of operation, while the submucous resection accomplishes the result by means of the removal of a large portion of the septal cartilage, together with the bone deformities which exist in the individual case.

The Comparative Value of the Various Septal Operations.—The submucous operation is difficult. Much skill and considerable

time is required in its performance, but the healing is wonderfully prompt. The submucous resection rarely fails to relieve the stenosis, but it may be attended with serious complications or sequelæ. A few deaths from meningitis recently have been reported as a result of this operation; hence it should be performed only under strict asepsis, and at all times it should be considered a major surgical procedure. While some untoward results may follow any operation for correction of deviated septa, not all, however, can

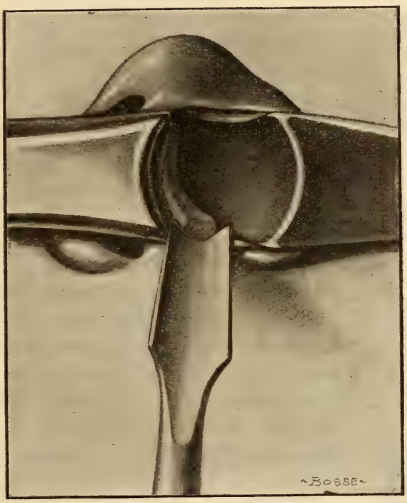

Fig. 334.—The crotch chisel applied to the maxillary ridge.

be attributed to the operation *per se*. These complications are hemorrhage, hematomata, erysipelas, follicular tonsillitis, inflammation of the accessory sinuses, fauces or larynx, unintentional injury to neighboring parts, septal perforations, synechia or atresia of the nasal passages, septal abscess and hematomata.

Anterior Dislocation of the Columnar Cartilage.—The treatment of the type in which the lower (anterior) margin of the septal cartilage projects into the nostril is conducted as follows: 1. Make

Fig. 335.—The Hajek septal chisel.

an incision along the line of the free border of the cartilage. 2. Retract the soft tissues and perichondrium from both (lateral) sides for a considerable distance. 3. Remove the projecting portions of the cartilage with the Ballenger swivel knife (Fig. 338) or scissors. 4. Close the wound by means of sutures.

The Removal of Septal Spurs.—A majority of the deviations of the septum are accompanied by spurs or ridges, but the latter commonly occur independent of the deviation or deflection. These are

composed either of bone or cartilage, or of bone and cartilage combined. They occur in various forms, sizes and locations, the maxillary ridge furnishing the larger proportion. They are often of large size and impinge upon the turbinal or lateral nasal wall (Fig. 339). One form often overlooked, unless the soft tissues are fully contracted, is the cone-shaped spur heretofore mentioned (page 523) situated far back upon the vomer.

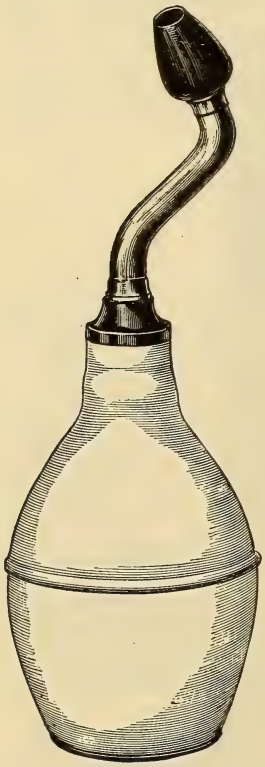

Fig. 336.—The Douglass douche bag.

Where small spurs are present at the time a submucous operation is contemplated, it is advisable to remove them through the incision after the mucochondrium has been separated.

Large spurs, however, may require removal either at the time of the major operation or some time thereafter. Several methods have been advocated for the removal of septal spurs, and various trephines, burrs, saws (Fig. 340) and other cutting instruments have been devised for the purpose. The instrument in common use is the saw, whereby the entire spur is completely severed at its base. The same results may be obtained by means of the electric trephine, burr or dental drill. Many operators have advised a submucous resection of the spur by making a primary incision through the mucous membrane and perichondrium, to be followed by complete retraction of these tissues over the entire surface of the spur, so that after the removal of the underlying spur the membranes may be allowed to fall over the resultant exposed surface. Theoretically, this procedure seems wise, but the claims are not usually fulfilled, chiefly for the reason that the membrane is usually considerably thickened, and thus covers space which could be utilized for the ventilation of the nostril. In the author's experience the removal of the entire spur, membrane and all close to its base, while requiring considerable time for a final healing, rarely results either in ulcer or troublesome scar tissue. As a rule a healthy, smooth surface results. Whenever a spur has an unusually broad base an exception should be made and that portion of the mucochondrium lying above the level of the utmost projection of the spur should be elevated by means of a lineal incision, and periosteum elevators, and the same retracted during the sawing process. After removing the spur the loose membrane should be drawn downward over the denuded surface.

The patient should be prepared by thorough cleansing of the nostrils and the surrounding outer surfaces near the nose. A solution of cocaine or alypin and adrenalin in the proportion already

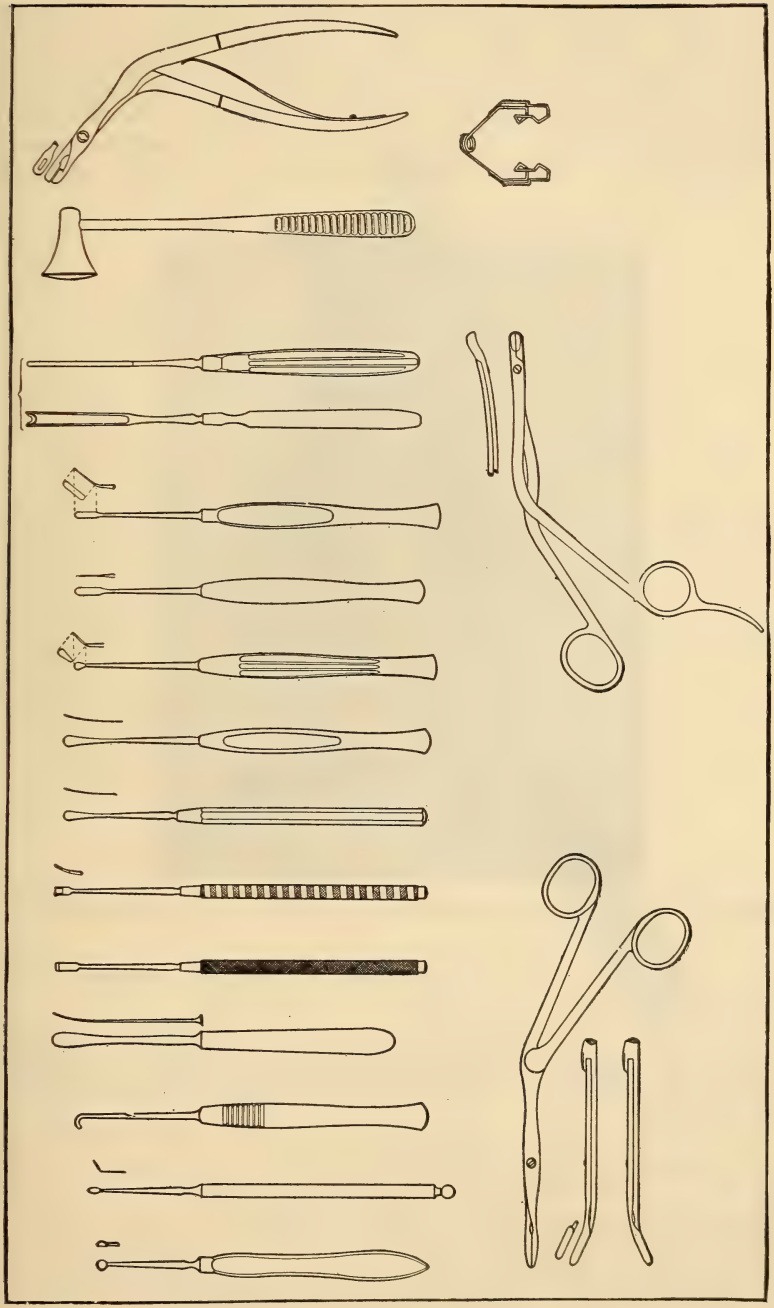

Fig. 337.—Submucous resection set, containing the models devised by Yankauer and others.

recommended in this chapter should be applied to both sides of the septum by means of cotton pledgets (Fig. 347), after the manner described in Chapter XXXVI. The time requisite for anesthetization is about twenty minutes, after which the operation may be performed with a sharp saw (Fig. 341) without pain. The under surface of the spur is usually a rather sharp ledge. The removal is therefore preferably accomplished by sawing from below upward. It is important to continue the line of removal parallel with the

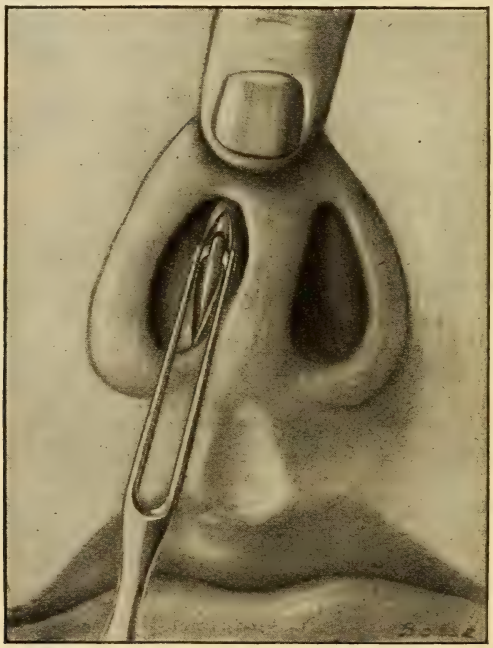

Fig. 338.—Removal of the projecting free border of the septal cartilage.

septum, as there is a tendency for the saw to gradually curve outward (Fig. 307).

The removal of septal spurs often causes considerable hemorrhage. This usually subsides spontaneously, but an occasional spurting of blood may require tampons (Fig. 342) or packing (Chapter XL).

As soon as the saw has passed through the hard tissue it is well to complete the excision with a slender pair of angular scissors (Fig. 343). If the resultant surface is smooth the operation may be considered completed, but if a small projection of bone remains it should be removed with a saw or some sharp cutting instrument. The wound should now be cleansed with physiological salt solution. The majority of authors advise that no dressing of any kind be em-

ployed. The author does not hold this view, but completes the operation by laying over the cut surface a small strip of sterile gauze which has been dipped into a solution of acetotartrate of aluminum (12 per cent.). His reasons are that it covers the cut surface with a sterile and slightly astringent dressing, and, while

Fig. 339.—Septal spur which impinges upon the inferior turbinal.

not in any sense considered as packing, the subsequent inflammatory reaction following the operation makes sufficient pressure between the turbinals and septum to hold this in place and practically control the hemorrhage which might otherwise occur.

This is left *in situ* for from one to two days. So far as the results are concerned this form of dressing prevents secondary



Fig. 340.—The Bosworth nasal saw.

hemorrhage and infection. Furthermore it lessens the danger of synechiæ and subsequent granulations. The question of secondary hemorrhage is considered in Chapter XL.

PERFORATIONS OF THE SEPTUM.

There are two general varieties of septal perforations: 1, those in which the cartilaginous portion only is involved, and, 2, perforations involving the bony portions.

The first class constitutes the larger proportion, and as a rule

the perforations are oval and are located just beyond the vestibule, a little above the floor of the nose (Fig. 344). They are usually the result of rhinitis sicca, attacks of diphtheria, syphilis, tuberculosis, typhoid fever, a septal abscess, gangrene, the electric cautery, caustics, and surgical operations. Certain drugs cause necrosis of the cartilage, *e.g.*, phosphorus or mercury and the caustic action of

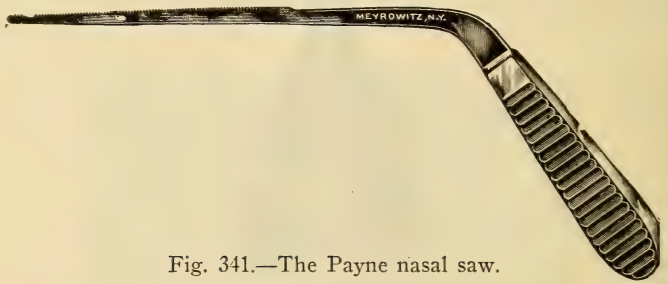

Fig. 341.—The Payne nasal saw.

chromic acid. A perforation usually commences as a slight ulcer, produced by the action of an irritating current of air, or from picking the nose. Continued efforts to remove the inspissated masses covering the ulcers result in still deeper excavations, until finally perforations occur. Rhinitis sicca produces a condition of the membrane which renders it peculiarly liable to become ulcerated. The proportion of ulcerations following typhoid fever is large. The tendency to pick scabs following the removal of spurs may result in ulceration and subsequent perforation.



Fig. 342.—Simpson's (Berney's) sponge tampon.

Perforations involving the bony portions of the septum are usually the result of syphilitic necrosis, and in rare instances of tuberculosis, lupus, phosphorus or mercurial poisoning.

The chief symptom of a cartilaginous perforation is the blocking up of one or both nasal passages with scabs or crusts which accumulate upon its margins. These crusts by their size not only obstruct nasal respiration, but produce a tickling or itching sensation which impels the patient to attempt their removal. After a time these removals are followed by small hemorrhages and still further destruction of cartilage. An annoying symptom sometimes observed in small perforations, especially with deflections, is respiratory whistling. The simpler forms of perforations are not accompanied by external deformity. In the more severe forms

(usually syphilitic) wherein the cartilaginous septum and portions of the bony septum have succumbed to necrosis, serious external deformity results. These deformities assume different types, sometimes resulting in what is known as a saddleback nose (Fig. 422), and occasionally the entire soft portions of the nose, no longer supported by cartilages, fall and produce ugly deformities.

During the progress of the necrotic process, a copious discharge of purulent, fetid matter takes place. The diagnosis never is difficult, inasmuch as rhinoscopic examination readily reveals the perforation. The edges of the perforation are sometimes granular and bleeding, but in old perforations the edges are entirely healed and covered with whitish, new-formed connective tissue.

Prognosis.—A septal perforation, except one exceedingly small, and unattended with ulceration, rarely fills in. Occasionally, in traumatic cases with small perforations, a suture properly applied may result in closure.

Fig. 343.—Knight's angular scissors.

Treatment.—In cartilaginous perforations with healed edges no treatment should be attempted except for removal of the crusts by means of bland sprays. In more recent perforations, accompanied by granular or ulcerated edges, attempts should be made to induce healing and thus prevent further destruction of cartilage.

Goldstein has devised a plastic flap operation in which, after having trimmed or pared the free edge of the mucous membrane from the border of the perforation, he elevates the mucoperichondrium from its attachment about the free border of the perforation upon both sides, for a distance of about one-half inch. He then resects the rim of cartilage thus exposed, using the Ballenger single-tined swivel knife.

A flap of mucous membrane, the dimensions of which are larger than the original perforation, is then lifted from a convenient, contiguous portion of the septum, and is swung and fitted into the space from which the ring of cartilage was resected. A few interrupted sutures are introduced in order to hold it in place. It is obvious that one side of this flap must heal by granulation from the borders of the surrounding membrane.

Chevalier Jackson has suggested a plastic procedure for closing septal perforations by transplanting sufficient tissue from the inferior turbinal.

Patients with perforations should always be cautioned against removal of scabs by means of picking. The scabs should first be softened and loosened by bland sprays and then be blown out. The denuded surfaces should be painted with a solution of nitrate of silver 20 grains to the ounce. Applications of a 25 per cent. solution of ichthyol, and a 2 per cent. to 5 per cent. ointment of menthol in white vaselin has a healing effect.

Whenever granulation tissue is found it should be scraped away and the basal surface touched either with fused chromic acid or nitrate of silver, or a solution of 50 per cent. lactic acid. Perforations attended with necrosis of the bony septum require a preliminary removal of all necrotic bone by means of the curet, in connection with such internal treatment as the nature of the associated constitutional disease requires.

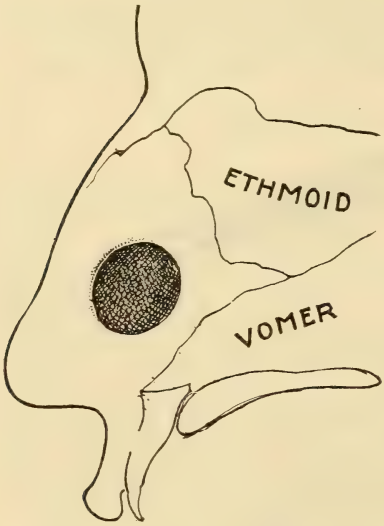

Fig. 344.—A perforation of the cartilaginous septum.

ULCERATIONS OF THE SEPTUM.

The septum may be the seat of superficial or deep ulceration, the latter usually resulting in perforation. When due to syphilis or tuberculosis it may eventuate in extensive necrosis of the adjacent intranasal structures. Superficial ulcers are prone to develop upon the convex surface of a deflected septum, primarily in consequence of the irritation of the air current and by the particles of dust which it contains. The ulcers are aggravated by the constant attempts of the patient to remove the crusts by picking the nose.

Treatment.—The patient should be cautioned against picking the nose and advised to use some bland alkaline or antiseptic wash for the purpose of softening and removing the crusts, after which 25 per cent. ichthyol or the 2 per cent. to 5 per cent. menthol ointment should be applied to the denuded surface. They may, after thorough cleansing and drying, be covered with aristol or iodoform with good results. Exuberant granulations about the edges should be destroyed with chromic acid or acid nitrate of mercury. Deep ulcerations are prone to result in perforations.

HEMATOMA OF THE SEPTUM.

A hematoma of the septum is an extravasation of blood, between the mucous membrane and the cartilage, as a result of an injury to the nose. If small, they disappear by absorption; if large, they undergo organization and produce septal thickening. If they become infected,

abscess results. Hematomata of the septum, unless of small size, produce marked obstruction to nasal respiration. A large, oval, fluctuating tumor, immediately following an injury, is sufficient to establish a diagnosis. It is differentiated from abscess by its brief duration. The prognosis, except when infection takes place, is good.

Treatment.—When of considerable size the clot should be removed by free incision. The cavity should be irrigated with an antiseptic solution, and its surfaces held together by pressure for a period of three or four days. The dressing should be changed as often as is necessary to keep the entire surface clean.

ABSCESS OF THE SEPTUM.

Abscess of the septum is an accumulation of pus in the septum, with or without destruction of portions of the cartilage. It is usually the result of traumatism, with sufficient abrasion to allow the entrance of pathogenic micro-organisms. If allowed to remain without incision, the deeper structures become necrosed and perforation may result. The symptoms are a sensation of fullness, interference with respiration, pain, heat, and sometimes rise of body temperature and chills. Upon examination a fluctuating tumor is observed in one or both nostrils. A foul, mawkish odor is noticeable. The surface of the abscess may be bright red or slightly yellow.

Prognosis.—Early incision and evacuation usually effects a cure, with but little destruction of tissue and no external deformity. Delayed cases wherein the cartilage has succumbed to the purulent process may be followed by a perforation of the septum and even sufficient loss of cartilage to cause external deformity.

Treatment.—Incision and evacuation is the only treatment. The incision should be followed by thorough cleansing of the cavity and the curetment of all necrosed areas and the introduction of a small strip of gauze for drainage. Very commonly the pus quickly reaccumulates, in which event a second incision becomes necessary.

The after-treatment consists in maintaining the apposition of the abscess surfaces by packing the nasal chambers with iodoform or plain sterile gauze; the gauze is removed daily.

ADHESIONS (SYNECHIÆ) OF THE SEPTUM.

Adhesions or synechiæ are due to traumatic or inflammatory causes whereby the septum and outer nasal wall are injured simultaneously. They may result from syphilis, tuberculosis, diphtheria, foreign bodies, external violence or intranasal operations. They are prone to follow the removal of septal spurs, in patients who neglect the after-treatment. Various synechiæ are depicted in Fig. 362, and the treatment is outlined on page 565.

CHAPTER XXXVI.

THE TURBINATE BONES.

SURGICAL AND PATHOLOGICAL ANATOMY.

THE turbinate bones are three processes projecting into the lumen of the nasal cavity from the lateral nasal wall, to which they are attached (Fig. 345), and which comprises the nasal process and internal surface of the superior maxilla, the lachrymal, palate and sphenoid bones. The turbinate bones are ranged one above the other in a nearly longitudinal direction.

The inferior turbinal (Fig. 345) only is a distinct bone, and is the largest and thickest of the three. Its conformation is scroll-like and under normal conditions its surface is free from contact with the nasal septum, the floor of the inferior meatus, or the lateral nasal wall, except at the line of attachment thereto. It extends from the inner margin of the vestibule to the posterior nares.

The middle turbinal (Fig. 345) is shorter than the inferior by about one-third. Its location is above and parallel to the posterior two-thirds of the latter. It arises from the lateral mass of the ethmoid bone, and should be considered as part of the ethmoid system.

The superior turbinal is the smallest of these processes, and also arises from the lateral mass of the ethmoid bone. It occupies a portion of the posterior and superior third of the nasal cavity. Its anterior portion is higher and occupies a position about opposite the tendo-oculi.

In rare instances a rudimentary fourth turbinal is found higher up, lying parallel with the superior.

These scroll-like processes are subject to considerable variation in size and shape, and, with their covering of mucous membrane, blood-vessels, nerves and other soft tissues, are known as the turbinals.

They are employed as landmarks for the purpose of subdividing the nasal cavities anatomically into three portions, which are termed the inferior, middle and superior meatuses.

The inferior meatus (Fig. 345) is that portion of the nasal cavity below the inferior turbinal and contains the nasolachrymal duct, at a point about one inch behind the anterior nasal orifice.

The middle meatus (Fig. 345) is the portion of the nasal cavity lying between the middle and inferior turbinals, into which open the ostium maxillare, the anterior ethmoidal cells and the infundibulum. This meatus is open above, behind and beneath, and therefore allows free access to the inhaled air.

The superior meatus (Fig. 345) is the pathway which extends between the superior and middle turbinals, into which open the

sphenoidal sinus and the posterior ethmoidal cells. It is closed in front and opens only downward and backward.

The arterial supply of the lateral nasal walls, including the turbinals, is derived from the anterior and posterior ethmoidal branches of the ophthalmic, and the sphenopalatine branch of the internal maxillary.

The sensory nerve supply of the turbinals and the lateral nasal wall is furnished by the anterior ethmoidals, the dental branch of the superior maxillary and branches of the Vidian nerve.

The nerves of special sense are composed of a set of branches of the olfactory nerve, which spread on the superior and the upper

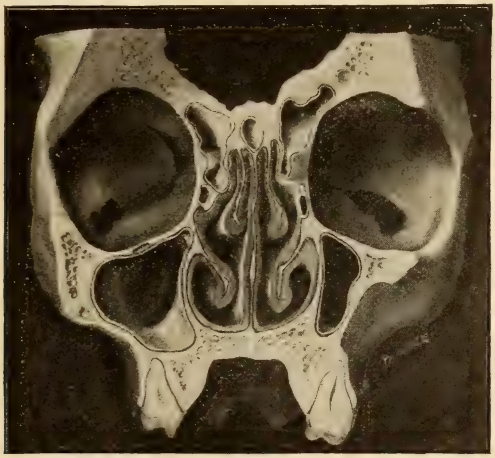

Fig. 345.—Vertical coronal section of the skull, with key plate.

portion of the middle turbinals and branches of the sphenopalatine ganglion, which terminate in the mucosa of the inferior and middle turbinals and the inferior surface of the superior turbinal.

PHYSIOLOGICAL FUNCTION.

The most important portion of the mucosa lining the respiratory region of the nose is the part covering the inferior turbinal and about the lower two-thirds of the middle turbinal. This sometimes is described as the respiratory portion of the nasal fossa. In this locality the membrane is dense, with increased vascularity, while in the upper or olfactory region the membrane is thin, delicate and has less tendency to hypertrophic changes. This variation in the character of the mucosa is explained by the large proportion of veins located in the submucous layers over the middle and inferior turbinals, and also by the fact that the membrane in this locality is characterized by the presence of cavernous spaces and erectile tissue. The erectile tissue is located chiefly along the inferior surface and posterior end of the inferior turbinal. The

cavernous spaces and the erectile tissue permit an enormous distention with blood. Hence any pathological changes of the mucosa in this region seriously affect the respiratory function of the nose and give rise to local as well as general disturbances. The peculiar vascular supply of the turbinals produces the phenomenon of erection and collapse whenever these tissues pass through a period of congestion or anemia of the venous sinuses. The same arrangement of the vascular supply of the turbinals is also the basis of their enormous heat-radiating power and their proportionate ability to pour out an abundance of watery vapor. In this manner the inspired air is furnished both with proper heat and moisture before entering the lower respiratory tract. In cases wherein, as a result

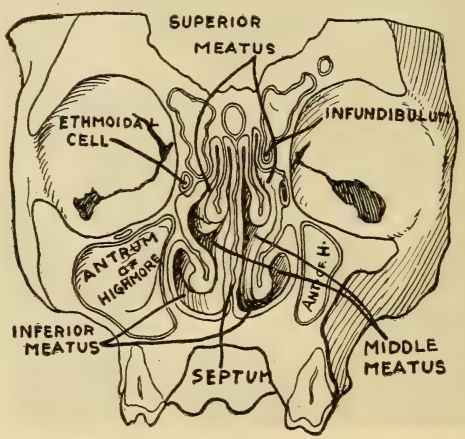

Key plate for Fig. 345.

of pathological changes, these functions are restricted or destroyed, the mucosa of the lower respiratory tract, which does not possess these functions to any degree, becomes more or less irritated and the tendency to bronchial inflammation is increased. The average quantity of watery vapor thrown off each twenty-four hours has been estimated by Grayson at about 500 grams.

The mucous membrane covering the nasal fossæ is sometimes termed the Schneiderian or pituitary membrane. The nasal cavities and the accessory sinuses are lined by mucous membrane which is continuous with that of the pharynx, and even that of the nasolachrymal ducts and the lachrymal sacs. This fact partially explains the ease with which a purulent process may extend throughout this entire region, and often with disastrous results.

The nasal mucous membrane has three layers, an upper epithelial layer in which the variety of epithelium differs according to the region, *e.g.:* In the olfactory or upper region a non-ciliated columnar variety is found, which contains the olfactory cells or nerve endings, and the mucous membrane is thinner. In the respiratory or lowest region the epithelium is of the ciliated or

columnar variety. Beneath the epithelial layer is a second layer or basement membrane, and a third layer made up of connective tissue varying in thickness, which is composed of white elastic and fibrous elements, containing the vascular, glandular, nerve and lymphatic structures.

The lining of the nasal vestibule is cutaneous in character and its epithelium is of the squamous or flat pavement variety. The color of the mucous membrane is bright red or pink.

DISEASES OF THE SUPERIOR AND MIDDLE TURBINALS.

These are conveniently considered together on account of the peculiar structure of the region and because of the intimate relation of both turbinals with the ethmoidal cells. The chief clinical importance attaches to the middle turbinal, its anatomical relations and cell-like construction rendering it peculiarly liable to involvement in both general nasal and ethmoidal purulent processes. The space occupied by these turbinals is extremely limited; hence any pathological increase in size brings their outer surfaces into contact with the septum or the lateral nasal wall, separately or together, and produces nasal obstruction and pressure symptoms.

Fig. 346.—Cystic middle turbinal with a large edematous polypus.

The principal lesions in these bones, herein considered, are characterized by one common objective symptom, viz., *enlargement.* The lesions usually consist of cysts and bone abscesses, but occasionally cases of osteophytic osteitis and rarefying osteitis and neoplasms, either benign or malignant, are found.

The anterior portion of the middle turbinal often consists of one or more large cells (Fig. 346). Opinions vary as to whether these cells are the result of pathological processes, anomalously located ethmoid cells or primary cysts (mucoceles). Turner, Harmer and others incline to the view that any one of these three causes may account for the condition. Often they increase during adult life, without pathological changes, but more commonly the increase is due to the extension of purulent processes from the ethmoidal cells, in which event they may assume the type of the pyocele or mucocele.

The remaining pathological changes in the bone substance of the middle turbinals are periostitis and osteitis. Enlargement of the middle turbinal from osteitis is usually confined to its anterior

end. The pathological change is gradual and is supposed to be the result of the irritating effects of dust and various other impurities which reach these tissues through the inspired air.

Recurrent attacks of simple acute rhinitis, under certain conditions, are also believed to produce the same result. Of the pathological changes in the mucosa, simple edema and polypoid degeneration are the chief.

In a considerable proportion of cases both the turbinal bone and its mucosa are the seat of pathological changes which require differentiation in the matter of diagnosis. When the bone alone is enlarged the mucosa is usually thin and appears as a firm covering with a smooth, regular surface which is hard and resistant. Certain other features are characteristic. When the mucosa participates in the diseased process, there is a purplish discoloration in hyperplastic inflammations of the mucosa, an edematous or translucent appearance in mucoid hypertrophy (Fig. 434), and a rough, uneven surface covered with gelatinous-like masses in polypoid degeneration (Fig. 346). A variety of symptoms arise as the result of the last-named lesions of the middle or superior turbinals, some of which are necessarily reflex in character.

The chief of these are: 1, symptoms referable to direct pressure upon the nerves; 2, symptoms referable to obstruction of the drainage from the superior meatus, with or without occlusion of the orifices of the accessory sinuses (unilateral, sometimes bilateral), neuralgic headache, ocular symptoms; 3, hay fever (see Chapter XXXII); 4, bronchial spasm (asthma) (see Chapter XXXII); 5, impairment of the sense of smell (anosmia).

Treatment.—Any disease or abnormality of the middle turbinal should arouse a suspicion of accessory-sinus involvement. The pathological changes in the turbinals, above described, rarely occur primarily, but are of common occurrence in connection with ethmoidal, maxillary and frontal sinus infections.

Cysts of the middle turbinal associated with ethmoidal-sinus disease should be surgically removed in a manner that will permit the surgeon to inspect the deeper structures with a view to the eradication of the underlying disease.

Treatment of the Enlarged Middle Turbinal Bone.—Based upon the pathological changes it is obvious that local treatment and internal medication are effective only in cases of acute inflammation of the mucosa. Here the treatment is the same as that which has already been described as adaptable for simple acute rhinitis (see Chapter XXXIII).

Surgical Treatment.—Enlarged middle turbinals, whether cystic or the result of periostitis or osteitis, should be subjected to operative measures: (*a*) When pressure symptoms are produced by the enlargement. (*b*) When the middle turbinal is the seat of extensive polypoid degeneration. (*c*) When the purulent process has invaded the cavity or cavities within the bone. (*d*) In cases where its removal is required as a preliminary step to the excavation of the ethmoidal cells, or for exploring of the frontal sinus, sphenoidal sinus, or maxillary antrum.

Preparation of the Patient.—The nasal cavities should be thoroughly cleansed of all secretions as a preliminary measure. Before proceeding to cleanse the cavities the long hairs in the nasal vestibule should be clipped away, both for purposes of cleanliness and to facilitate the inspection of the operative field. The nasal

Fig. 347.—Angular flat applicator. The flattened out absorbent cotton, soaked with the anesthetic, has been laid upon it for the purpose of introducing it into the nares.

cavities should then be thoroughly sprayed with normal physiological salt solution, and the external surface of the nose and lip should be thoroughly scrubbed with 1 : 5000 bichlorid of mercury solution.

The Anesthetic.—The operation is preferably performed under local anesthesia, on account of the free hemorrhage which invariably

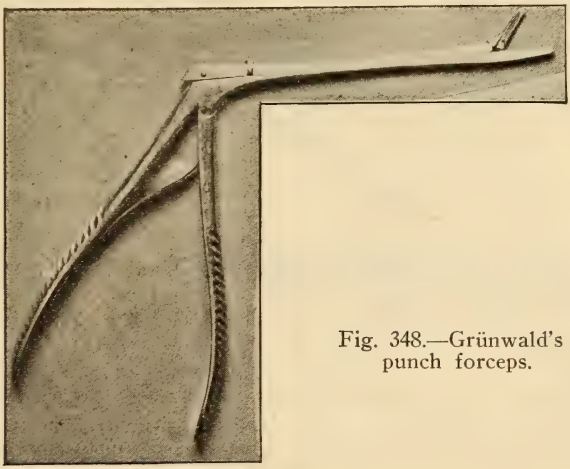

Fig. 348.—Grünwald's punch forceps.

attends the use of a general anesthetic and the consequent difficulty of obtaining at all times a good view of the operative field. When local anesthesia is employed the operation may be performed with the patient in the upright position, there is but slight hemorrhage, and the operative field is under constant observation, which insures both accuracy and rapidity.

The induction of local anesthesia is accomplished as follows: (*a*) Spray the nasal mucosa with a solution of cocaine or alypin 2 per cent. in adrenalin solution 1 : 5000, avoiding if possible the

entrance of the anesthetic into the pharynx. (*b*) After ten minutes apply flattened pledgets of absorbent cotton soaked in a 4 to 10 per cent. solution of cocaine in adrenalin 1 : 5000 to the middle turbinal bone. The pledgets are prepared and introduced as follows: A small flattened-out portion of absorbent cotton is placed upon the surgeon's forefinger and moistened with the anesthetic solution by means of an ordinary glass dropper. The pledget is then placed upon the angular flat applicator (Fig. 347), by means of which it is carried into the nasal cavity. The first pledget should be spread upon the septal surface of the middle turbinal; the second between the middle turbinal and the lateral nasal wall, and the third is made to cover any remaining portions of the bone. The pledgets should remain *in situ* for at least a period of twenty minutes in order to insure complete anesthesia of the parts.

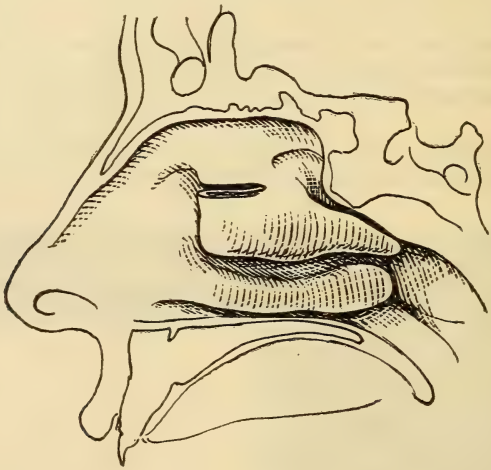

Fig. 349.—The primary incision for the middle turbinotomy.

The Operation.—Turbinotomy and turbinectomy are the terms which designate the operation by which a part or the whole of a turbinal bone is removed. The procedure, so far as it relates to the middle turbinal, as a rule is that of turbinotomy, whereby the anterior bulbous extremity of the bone is resected, although, when extensive disease of the anterior and posterior ethmoidal cells is present, it becomes necessary to remove the entire turbinal (turbinectomy). The operation should invariably be of sufficient extent to prevent future intranasal pressure, and to remove adjacent polypi and to enable the operator to approach the diseased ethmoidal cells or the sphenoidal cavity.

The steps of the operation for the removal of the anterior bulbous extremity of the middle turbinal are as follows:—

(*a*) Introduce a Grünwald punch forceps (Fig. 348) and clip about one-third of the anterior portion of the attachment of the bone (Fig. 349). The Holmes scissors (Fig. 350) are also adaptable for this purpose.

(*b*) The wire loop attached to a Krause snare (Fig. 351) is then introduced, allowing the distal portion of the loop to enter the primary incision and the heel to be pressed as far posteriorly as possible along the under surface of the bone (Fig. 352). In some instances better results are obtained by introducing the loop with its distal end upon the under surface and the tip of the cannula well pressed into the primary incision.

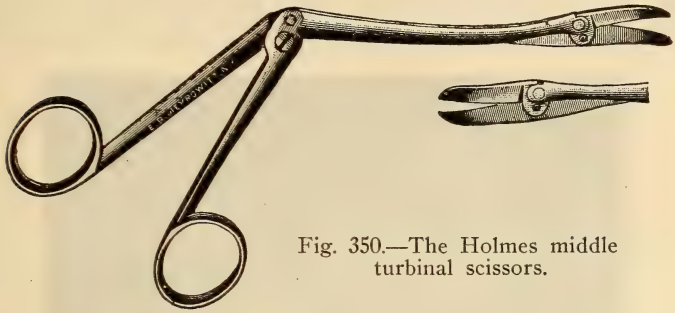

Fig. 350.—The Holmes middle turbinal scissors.

The operation may also be effectively performed by making the primary incision with angular clipping forceps, commencing at about the junction of the anterior and middle thirds of the bone and extending it in a perpendicular direction, after which the snare loop is introduced deeply into the incision and the bone cut away.

(*c*) Upon the removal of the segment of bone after the manner above described (Fig. 353), all remaining polypoid masses, shreds of

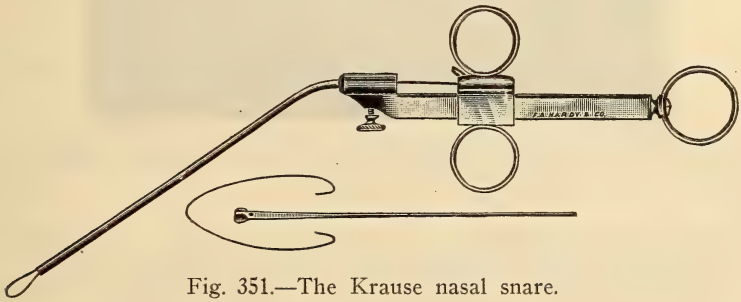

Fig. 351.—The Krause nasal snare.

tissue and particles of diseased bone should be completely removed. For this purpose Brüning's forceps (Fig. 401) is a most effective instrument, and its safety commends its use. By grasping the remaining shreds, polypi or segments of diseased bone, the instrument both breaks and pulls away the masses without danger of penetrating and thus injuring the deeper tissues.

The Removal of the Entire Middle Turbinal.—When it is necessary to remove the entire middle turbinal the same preliminary procedure (*a*) should be employed. The incision having been made

a large snare loop is made to engage the entire bone and in this manner it is removed *en masse*.

The primary incision is an important step in either operation, as it prevents the slipping of the wire loop. In many cases this bone may be removed with the clipping forceps alone, by extending the original incision entirely through until the desired portion has been completely separated from its attachment. The operation is usually free from pain, but as a rule the patients suffer slightly from surgical shock, and occasionally from the physiological effects of the anesthetic.

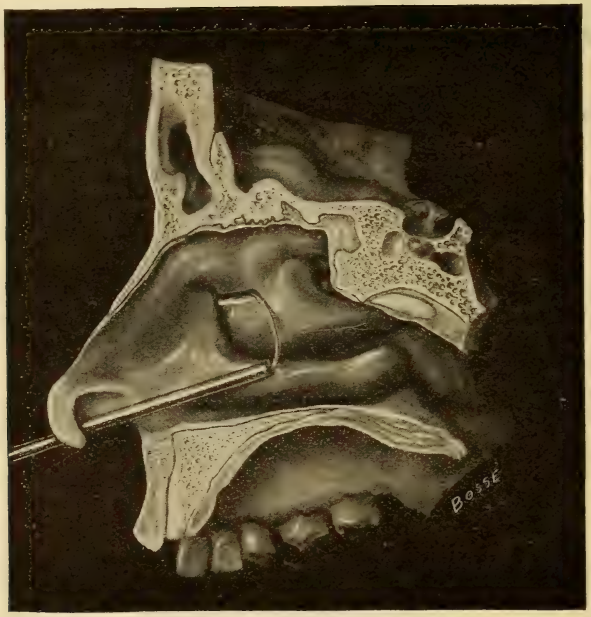

Fig. 352.—The snare in position for severing the anterior portion of the middle turbinal.

The surgical procedures required in extending the operation to the ethmoidal cells are fully described in Chapter XXXIX.

Two methods of operating on the middle turbinal, which are described in the earlier text-books, namely, the use of the galvano-cautery and the electric trephine, are now obsolete, the former on account of its ineffectiveness, and the latter on account of the dangers attending its employment in this location. The hemorrhage attending this operation rarely is excessive, and usually is controlled by pressure. Profuse hemorrhage during the operative procedure may be controlled by introducing a pledget of gauze saturated with a 1 : 5000 solution of adrenalin, to be left for a period of about five minutes.

Upon completion of the operation the entire nasal cavity should

be washed out with a normal salt or alkaline antiseptic solution. The denuded bone surface should then be covered (not packed) with a strip of sterile gauze saturated with a 12 per cent. solution of acetotartrate of aluminum, for the purpose of protection. This solution is both astringent and antiseptic; hence the gauze may safely be left *in situ* for from twenty-four to forty-eight hours. Furthermore, by its employment the dangers of postoperative hemorrhage are materially lessened.

Upon removing the gauze the nasal cavity should again be cleansed in order to remove all retained secretions and blood-clots, and thereafter all dressings should be discarded. But daily cleans-

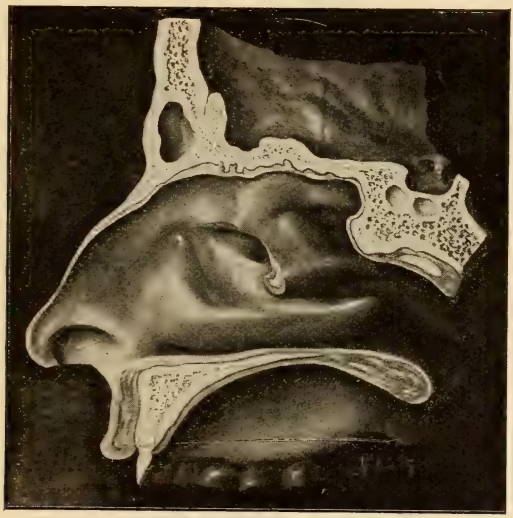

Fig. 353.—The partial middle turbinal operation, with key plate.

ing should be continued until healing is complete. Should there be a tendency to the formation of crusts, applications of weak benzoated or mentholated vaselin may be made over the entire surface.

The Results.—The operation is followed by marked relief from hypersecretion and intranasal pressure, and nasal respiration is improved. When the turbinal enlargement is associated with ethmoiditis and the latter is simultaneously subjected to operative measures, the improvement both in local symptoms and in the general health is marked. Inasmuch as the overdistended ethmoidal cells, together with the enlarged turbinal, sometimes produce a widening of the nose and hence external deformity, the correction of the disease results in marked improvement in the facial expression of the individual.

For a consideration of nasal polypi the reader is referred to Chapter XLII, on New Growths.

DISEASES AND DEFORMITIES OF THE INFERIOR TURBINALS.

The pathological changes which develop in the tissues of the inferior turbinals are chiefly those which pertain to the mucosa underlying the soft tissues and will be considered under the headings: 1, acute inflammation (tumefaction, turgescence); 2, true hyperplasia; 3, atrophy. They are also subject to: 4, malformations and deformities; 5, dilatations, and, 6, synechiæ.

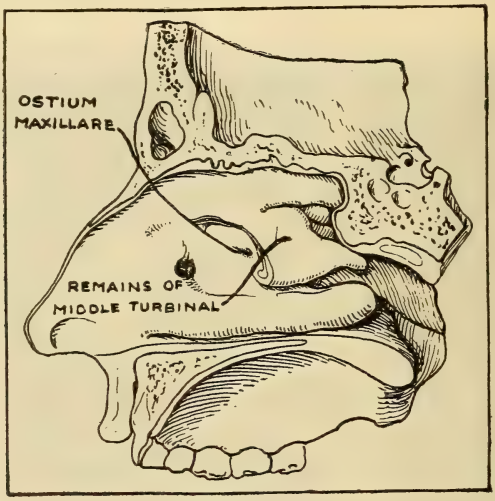

Key plate for Fig. 353.

1. Acute Inflammation.

The pathological changes which accompany acute inflammation of the inferior turbinals consist of tumefaction or turgescence of the mucosa, which usually is intermittent and the result of engorgement of the venous sinuses in this mucosa. This condition usually is associated with a similar inflammatory process (acute rhinitis) which extends throughout the nasal mucosa, and whenever it persists the first step of chronic rhinitis has been reached.

The inferior turbinal and its coverings are subject to all of the acute infections which invade the mucous membrane of the nasal cavities in general. These are fully described under their respective headings in Chapters XXIX, XXX, XXXI, and XXXII.

The swollen tissue is soft and dimples when pressed upon with a probe, but the blood-vessels quickly refill upon the cessation of pressure. Extensive tumefaction of the turbinal causes the latter to impinge upon the septum or upon the floor of the nostril and to obstruct or completely block the inferior meatus. These changes usually are bilateral. Upon the application of cocaine or adrenalin the tumefaction of the mucous membrane completely subsides.

2. True Hyperplasia.

True hyperplasia of the inferior turbinal may occur in any portion of its mucosa, but is more common at the posterior extremity, where it often reaches enormous size (Fig. 354). Extending backward into the postnasal space, these masses sometimes rest upon the upper surface of the palate, where they interfere with nasal respiration and with the ventilation of the middle ear.

Hyperplasia of the inferior turbinal varies from a general thickening of the mucosa to the enormous cauliflower-like elevations which project from sessile attachments to its surface. The latter are often confined to the posterior portion of the bone (Fig. 355), but may extend throughout its entire surface. In one of the



Fig. 354.—A large sessile hyperplasia (polypoid) removed from the posterior extremity of the inferior turbinal of an asthmatic.

author's cases the entire inferior meatus from the vestibule was filled with this type of hyperplastic tissue, which was soft and polypoid in character, and extended into and filled a portion of the postnasal space. The entire mass was engaged in a wire loop and removed.

Symptoms.—True hyperplasia of the inferior turbinal, especially when associated with the deformities hereinafter described, results in sufficient enlargement to produce contact either with the septum or the meatal floor. Hence there is induced a serious disturbance of function on account of the resultant obstruction to nasal respiration and the free outflow of the secretions. Furthermore, the timbre of the voice may become impaired and distressing tinnitus and a sensation of fullness in the ears may ensue. The chief symptom, however, is obstruction, which may be unilateral, bilateral or alternating. In many cases the nasal obstruction increases on the side upon which the patient lies at night. It also is increased when the patient remains in imperfectly ventilated or superheated rooms. The advent of an attack of simple acute rhinitis induces the distressing symptoms which follow complete occlusion of the nares. In

some cases the pressure symptoms cause positive pain, which often is accompanied by nervous irritability and depression.

Diagnosis.—Upon examination by anterior rhinoscopy any unusual enlargement of the inferior turbinal tissues should lead to a painstaking study as to the nature of the existing enlargement. The lower border of the inferior turbinal sometimes touches the floor of the nose and is surrounded by a mass of mucus, which often fills the surrounding spaces. This condition is usually indicative of true hyperplasia, but the latter may definitely be determined by applying a solution of cocaine. Turgescent tissue collapses under this drug, while true hyperplasia is but little affected when subjected to cocaine test. Contact of the inferior turbinal is usually visible, and the degree of pressure may be determined by probing.

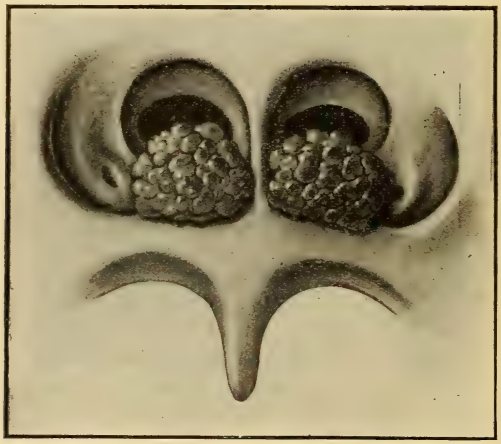

Fig. 355.—Bilateral posterior hyperplasia (cauliflower) of the inferior turbinals.

Posterior hypertrophies are readily located by the aid of the postrhinoscopic mirror. It is not uncommon to discover posterior hypertrophies of the inferior turbinal of such enormous size that they conceal the posterior border of the septum by overlapping it. Furthermore, it is often possible to locate these growths by means of the finger-tip introduced into the nasopharynx.

3. Atrophy.

Atrophy of the inferior turbinal is usually confined to the soft tissues, although in some cases the bone itself becomes partially or wholly absorbed by the atrophic process. Atrophy of the inferior turbinal is invariably associated with a general atrophic process involving the intranasal structures, the symptoms and treatment of which are elsewhere described. (See Atrophic Rhinitis, Chapter XXXIV.)

4. Malformations and Deformities.

Malformations and deformities of the inferior turbinal are more common than is usually supposed. Under normal conditions the bone remains free from contact with the surrounding structures except at its point of attachment. Slight malformations may exist without serious results, but when the deformities are such as to cause impingement of the bone, either upon the septum, the nasal floor; or when the outer surface of the lower portion presses upon the lateral nasal wall, more or less annoying symptoms are produced.

Malformations and deformities may exist without pathological changes in the soft tissues. The most common and controllable are those wherein the scroll-like conformation of the bone is incomplete, leaving its unattached edge widely separated from the body of the bone, and in contact either with the floor of the nostril or against

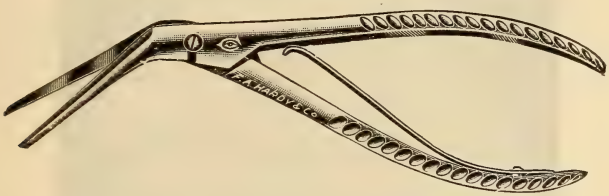

Fig. 356.—The Jackson turbinotomy scissors.

the septum. Occasionally the large whorl of the scroll extends unduly in a lateral direction and impinges upon the lateral nasal wall.

5. Dilatations.

Sacculated enlargement is occasionally observed in the inferior turbinal. It is caused by a separation of the two osseous lamellæ which comprise this bone. A prominent symptom of this condition is compression upon the lachrymal duct. It is important to differentiate a dilatation or sacculation from polypi or osteomata.

Treatment.—(*a*) Local and internal. (*b*) Surgical.

Both the local and internal measures required for the diseases of the inferior turbinals are similar to those already described in the chapters on Acute and Chronic Rhinitis.

Indications for Operation.—Some form of operative interference is indicated whenever the hyperplasia or other disease or deformity of the inferior turbinals produces symptoms of obstruction, intranasal pressure, altered secretion, interference with drainage or with the normal function of the nose.

Operative Treatment.—The operative treatment of hyperplasia, enlargement and deformity of the inferior turbinals may be defined under four general headings:—

(*a*) Reduction of hyperplasia by means of the galvanocautery.

(*b*) Reduction of hyperplasia with snare or scissors.
(*c*) Turbinotomy.
(*d*) Turbinectomy.

General Remarks.—The nose should be prepared for the operation in the same manner as for operations upon the septum or middle turbinal. If the patient is a male who wears a mustache the latter should be covered with gauze, the ends of which are gathered and tied behind the patient's head. Likewise a sterile towel may be applied over the forehead and hair.

The Anesthetic.—Local anesthesia is preferable to general

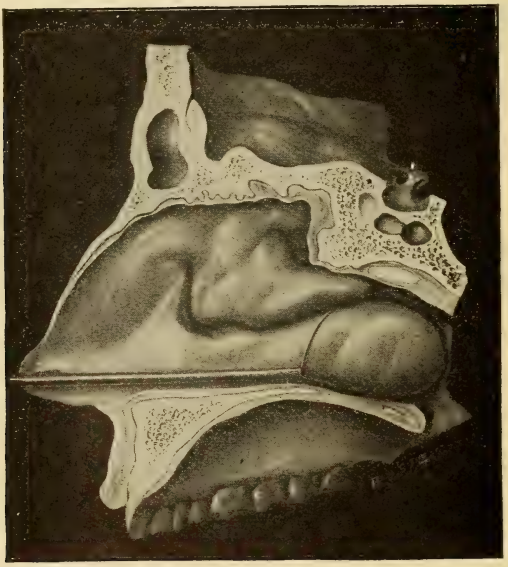

Fig. 357.—The snare in position for removing a posterior hyperplasia of the inferior turbinal.

anesthesia in every particular for operations upon the inferior turbinal. The rules to be followed in applying the local anesthetic are similar to those heretofore outlined for operations upon the middle turbinals.

It is sometimes difficult to introduce the thin pledget of gauze into the space between the turbinal and the lateral nasal wall, but this measure is important to secure complete anesthesia.

The application of caustics and escharotics for the purpose of destroying hyperplasia of the inferior turbinal is a harmful and ineffective measure. They result in severe reaction, with painful and annoying symptoms which continue for several days, after which a large slough separates, leaving a foul granulating surface, and finally considerable scar tissue.

(*a*) *The Galvanocautery.*—The galvanocautery has been widely used for the destruction of turbinal hyperplasia. It is applied

in the form of linear incisions, by puncture and subcutaneously. Applications of the galvanocautery by means of linear incisions, in order to be of lasting benefit, require deep insertions of the cautery knife and extensive searing of the tissues. A violent reaction follows and the resultant scar tissue is out of all proportion to the limited ultimate results.

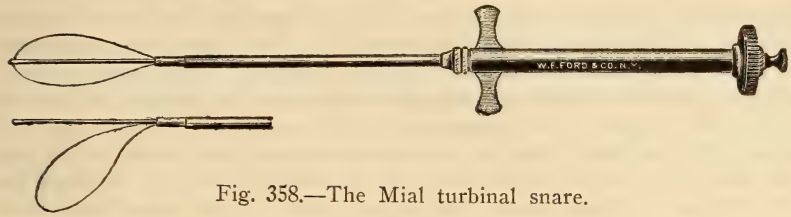

Fig. 358.—The Mial turbinal snare.

It is possible to employ the galvanocautery submucously without wide destruction of the mucous surface. Fine platinum elongated points are employed, which are thrust deeply into the tissue, and the burning is thus chiefly confined to the submucous tissue. The author rarely employs the galvanocautery as a method for reducing inferior turbinal hypertrophies, believing that far better

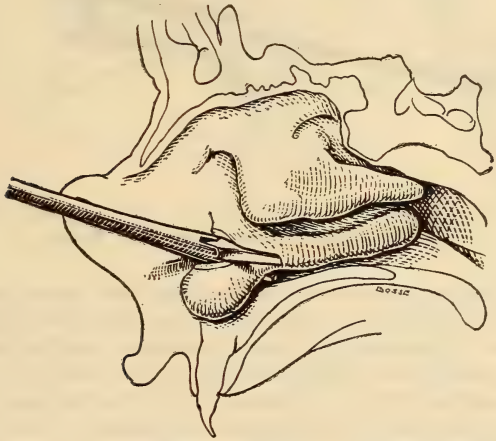

Fig. 359.—Partial (anterior) inferior turbinotomy by means of punch forceps.

results are to be obtained by a clean-cut surgical removal of the tissue with scissors, knife or snare.

(*b*) *Reduction of Hyperplasia with Snare or Scissors.*—For the removal of hyperplasia of the anterior extremity or inferior surface of the inferior turbinal, a preliminary linear incision is made with scissors, at a point which marks the boundary of the quantity of tissue which it is desired to remove, similar to Fig. 359, but not including the bone. The Jackson turbinotomy scissors (Fig. 356) are ideal for this purpose. The operation is completed by engaging

and removing the redundant tissue with a cold-wire snare. In some instances it is possible to remove the desired section of tissue with the scissors alone.

For the removal of posterior hypertrophies the wire snare is the ideal instrument. A variety of snares have been devised for this purpose. As a rule it is possible to operate successfully with a simple straight snare (Fig. 357), by bending the loop slightly before its introduction into the nostril. An ingenious snare has been devised by Mial (Fig. 358) for the removal of posterior hypertrophies. In intractable patients the technique is greatly facilitated by the aid of posterior rhinoscopy. The patient is instructed to depress his tongue; the surgeon manipulates the snare with one hand and observes its movements in the mirror which is held in his other hand. In some cases the engagement of the wire loop over

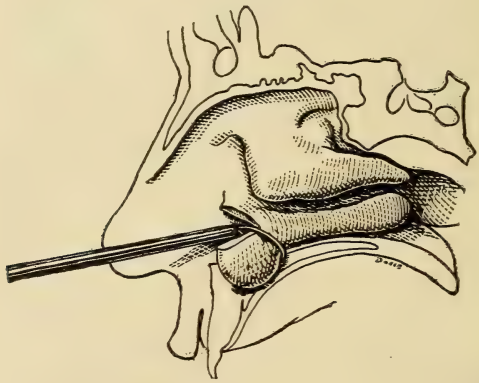

Fig. 360.—Partial (anterior) turbinotomy by the combined employment of the punch or scissors and the snare.

the posterior tip is facilitated by passing the snare directly backward along the floor of the nose, and, when the end of the wire loop has reached the pharynx, the snare cannula is directed backward and slightly toward the median line of the pharynx till it too touches the postpharyngeal wall. This bends the wire loop at an angle toward the posterior tip of the inferior turbinal. The instrument is now slowly withdrawn until the loop encircles the hypertrophy; the snare is then gradually tightened until the wire loop slowly excises the diseased mass. While tightening the loop, the cannula must be gradually extended toward the growth; otherwise the loop will slip away from its position around the tumor.

(*c*) *Turbinotomy.*—The measures recommended for removing the anterior portion of the bone are three in number: 1. With scissors alone. 2. With punch forceps alone. 3. With scissors or punch forceps and snare combined.

1. When the anterior end only is the cause of the obstruction it is possible by introducing the blades of the scissors, one upon the septal side and the other into the space between the turbinal and

the lateral nasal wall, and by tilting the handles upward, to excise the desired section of the bone.

2. The punch forceps (Fig. 348) are most adaptable and effective in the cases above described, on account of their small calibre and strength. The jaws of the instrument are applied to the bone in the lateral plane, or nearly so, and the primary cut (Fig. 359) is made. Without withdrawal the jaws are then reopened and inserted more deeply and thus the incision is extended until the resection is completed.

3. The combined use of the scissors or punch forceps and the cold-wire snare possesses many advantages for the removal of the anterior end of the inferior turbinal. The operation was devised by Lake.

The superiority of the punch forceps over the scissors is in its smaller dimensions, and the furrow which it cuts into the bone

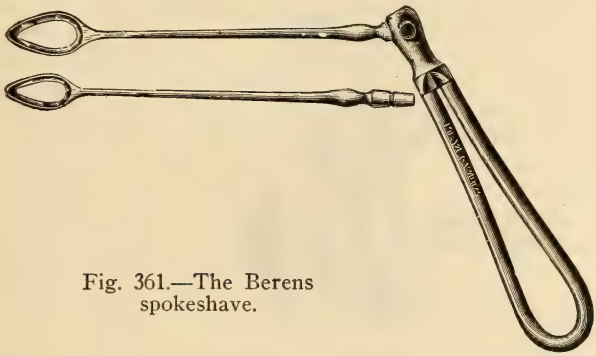

Fig. 361.—The Berens spokeshave.

(Fig. 360) greatly facilitates the subsequent technique for adjusting the snare.

After removing the section of bone, if the snare has failed to reach the limits of the obstruction, the remaining excess of bone can easily be clipped away with the punch forceps.

Posterior inferior turbinotomy is rarely required, inasmuch as the enlargement is usually confined to the soft tissues (hyperplasia). It is accomplished by means of the snare, in the manner described for posterior hyperplasias.

(*d*) *Turbinectomy.*—When the entire inferior turbinal is enormously enlarged, or in case its entire removal becomes imperative as a preliminary to other and more extensive operative measures, it should be cut away *en masse.*

The operation is simple, and, barring occasional annoying hemorrhage, it is unattended by serious consequences. It is best performed by means of a succession of clips with the punch forceps (Fig. 348) carried through its line of attachment along the lateral nasal wall.

The spokeshave (Fig. 361) and the large-sized Ballenger swivel knife (Fig. 322) are also adaptable for this operation.

When the latter instruments are employed they are adjusted over the posterior end of the bone and drawn forward through its line of attachment to the lateral nasal wall. A small preliminary incision should be made through the anterior attachment of the bone, in order to prevent the tearing of the soft tissues as the instrument emerges.

Submucous resection of the inferior turbinal, while feasible so far as the procedure is concerned, is applicable in but a limited proportion of cases, as any enlargement or deformity of the bone usually is accompanied by hyperplasia in its submucosa.

After-treatment.—The after-treatment may be summed up in a few words. For the control of persistent hemorrhage the patient

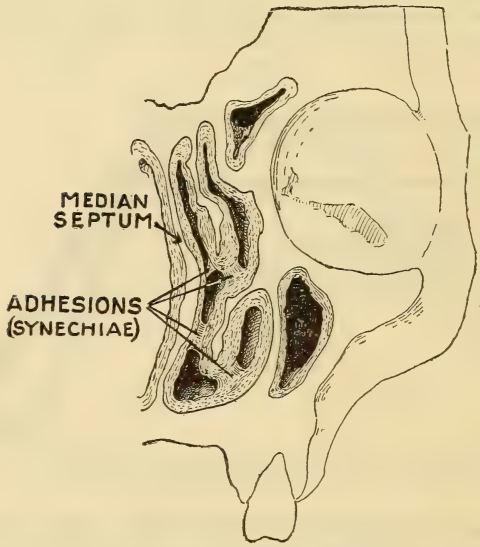

Fig. 362.—The various synechiæ (adhesions) which are observed in the nasal cavities.

may be directed to spray the nostril with adrenalin solution 1 to 5000. It is unnecessary to plug the nostril after an operation upon the inferior turbinal bone, except for the control of excess of hemorrhage, which is a rare occurrence. Tight plugging of the nares causes pain, sometimes produces sloughing, and favors infection. The denuded surface within the nostril may be protected by applying one or two layers of sterile gauze, moistened with a 12 per cent. solution of acetotartrate of aluminum, to which may be added a few drops of a 1 : 5000 solution of adrenalin. The sterile gauze thus prepared produces no pressure or severe pain; it is slightly astringent; it protects the wound from infection, and is an efficient safeguard against secondary hemorrhage.

The after-treatment, further than this, is limited to the observation of the ordinary rules of cleanliness. The inflammatory reaction

is sufficient to cause considerable discomfort and to temporarily interfere with nasal respiration. This may be relieved by means of an occasional spray with a 1:5000 solution of adrenalin. After twenty-four hours the gauze should be removed, and thereafter the treatment should consist only of frequent cleansing with alkaline sprays.

6. Synechiæ.

Synechiæ (Fig. 362) are quite common in the nares and are usually composed of adhesive bands, which unite the turbinal tissues with the septum. Occasionally the inferior and middle turbinals are so joined. They are rarely congenital, and they usually result from traumatism. As a rule they are composed of connective tissue, but occasionally they consist of bone. Synechiæ occasionally extend from the lateral wall to either the inferior or middle turbinal bodies. Acquired connective-tissue synechiæ usually are the result of cicatrization of a nasal ulcer, bungling operative interference, or neglect of after-treatment following surgical operations upon the septum or turbinate bones.

Treatment.—Synechiæ between the middle turbinal and the septum and those which join the inferior turbinal to the nasal septum, the nasal floor or the middle turbinal (Fig. 362) should invariably be resected. The operation is best performed by means of the punch forceps (Fig. 348) whenever the synechiæ can be reached with this instrument. Otherwise the band of tissue should be resected with scissors. By resecting a comparatively thick portion of the synechia, sufficient space is usually gained so that re-formation is not likely to occur. In case recurrence becomes imminent, it is easily overcome by inserting a small section made up of several layers of rubber tissue between the opposing surfaces. This procedure should be repeated from time to time until the raw surfaces are permanently healed. It is obvious that in many of these cases the submucous operation is indicated.

New growths of the turbinals and nasal neuroses are respectively described in Chapters XLI, XLII.

CHAPTER XXXVII.

DISEASES OF THE NASAL ACCESSORY SINUSES.

ANATOMICAL CLASSIFICATION.

General Remarks.—A convenient grouping of the nasal accessory sinuses, based on the clinical phenomena, has been devised by Hajek, in which they are arranged into two series as follows:—

Series I is composed of the maxillary, the anterior ethmoidal and the frontal sinuses. Series II comprises the posterior ethmoidal and the sphenoidal sinuses.

The sinuses composing series I, or the anterior group, drain into the middle meatus (beneath the middle turbinal).

The sinuses which compose series II, or the posterior group, drain into the superior meatus (above the middle turbinal).

The frontal sinus and occasionally one or two anterior ethmoidal (frontoethmoidal) cells communicate with and hence drain into the infundibulum. Drainage of the anterior ethmoidal cells and the maxillary sinus takes place directly into the hiatus semilunaris, with which they normally communicate.

The posterior ethmoidal cells and the sphenoidal sinuses communicate with and drain into the superior meatus. The outlets of the sinuses are by no means constant, and the details regarding such variations as occur are outlined in the surgical anatomy of the individual sinuses. The mode of drainage of an accessory sinus is direct when the ostium is in its floor; but, when the ostium of the sinus is high up and hence remote from its most dependent portion, drainage is effected only by means of the cilia of its epithelial lining.

For example, the outlets of the frontal sinuses invariably are from their most dependent points; hence their secretions gravitate directly into the infundibulum. On the contrary the outlets of the maxillary and sphenoidal sinuses are located high up so that direct drainage is impossible and the secretions must be conveyed by the ciliated epithelium. The relatively small calibre of the outlets of the nasal accessory sinuses is an important clinical factor in the inflammatory processes which invade their lining mucous membranes. It is on account of the lack of adequate drainage and ventilation of the sinuses, owing to the restricted calibre of their openings, that the severity, pathological changes and limitations of these processes differ materially from like inflammations which attack the nasal mucosa proper.

THE MAXILLARY SINUS (ANTRUM OF HIGHMORE).

1. **Anatomy.**—The maxillary sinus or antrum of Highmore is situated in the body of the superior maxillary bone (Fig. 363). It is separated from the nasal cavity by the outer (lateral) nasal wall

(Fig. 364), with the exception of a small opening, the ostium maxillare, which is hereinafter described.

In shape the antrum is a three-sided, irregular, inverted pyramid, the base being formed by the floor of the orbit, and its apex situated over the alveolar process. The roots of the first and second molar teeth sometimes protrude into the maxillary antrum. Some authors place the base of the antrum at the outer wall of the nasal chamber and the apex toward the malar process. The three sides of the pyramid are the facial, orbital and the nasal walls. It is of surgical importance to note that the walls of this sinus vary much in thickness. The thinnest portion is the nasoantral wall in

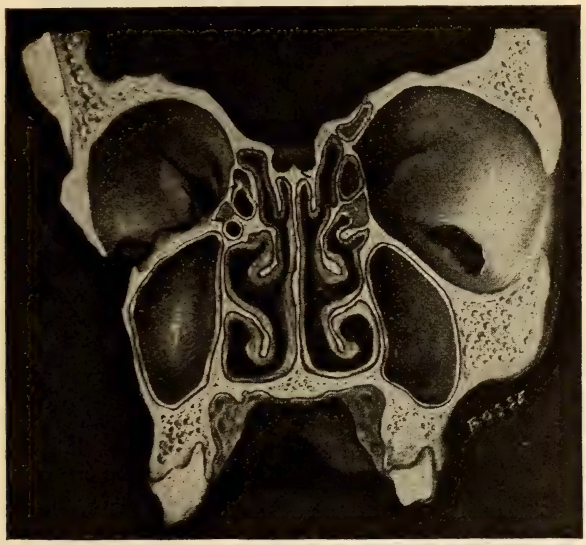

Fig. 363.—Front view of a vertical coronal section of the skull on the plane of the second molar teeth, with key plate.

the region of the ethmoid bone, from which at times it is only separated by a membrane. This fibrous membrane, known as the *hiatus semilunaris*, is situated between the *bulla ethmoidalis* and the *processus uncinatus;* the remaining portions of the inner wall are bony. The thickest wall is the temporal, outer or posterior wall, pointing toward the zygomatic fossa (Fig. 365), the upper posterior angle of which is in contact with the cranial cavity.

The ostium maxillare (Fig. 363) is the natural opening of this sinus, through which it drains into the nasal cavity. It is situated in the lateral nasal wall, nearer the roof than the floor of the cavity, and opens into the middle meatus of the nose at the posterior extremity of the *hiatus semilunaris*. Hence this cavity depends for drainage upon the cilia of the epithelial lining. Sometimes one or more accessory openings are found. The mucoperiosteum lining

the antral cavity is as a rule arranged in folds, and, rarely, the sinus is divided by septa into two or more compartments.

The maxillary ostium (Fig. 364) being high up in the antrum, in the erect position of the body, secretion cannot gravitate into the nasal cavity unless the antrum is entirely filled (Hajek). This opening varies in size and shape; it is usually circular or elliptical, but at times is a mere slit, its direction being downward, forward and outward, and, according to Zuckerkandl, it measures from 3 to 19 mm. in its longitudinal diameter, and about 6 mm. in its transverse diameter. Its hidden position makes it difficult to insert a probe or cannula; but accessory openings when present are more accessible.

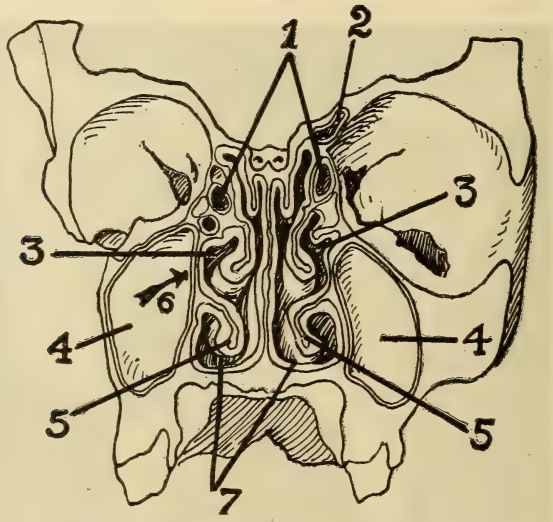

Key plate for Fig. 363.—1, ethmoidal cells; 2, frontal sinus; 3, middle meatus; 4, maxillary antrum; 5, inferior turbinal; 6, ostium maxillare; 7, inferior meatus.

The apex of the antrum (according to our description) is important on account of its relation to the dental process, to diseases of the roots of the teeth, and because the alveolar process sometimes extends into its lumen. The depth of the alveolar process varies, this being due to the absorption of the spongy substances during the development of the antrum. When the bony walls of the cavity are compact and thick there has been little absorption and the cavity is relatively small; with much absorption the size of the antral cavity increases and the thickness of the walls and floor decreases. The thicker the alveolar process, the greater the protection against inflammatory inroads into the antrum from the alveolar contents.

The anterior wall (Fig. 364) is comparatively thin, especially in the region of the canine fossa, and here a large opening into the antrum can easily and safely be made. Its superior boundary is formed by the infraorbital ridge, its inferior by the malar process,

its outer lateral by the malar ridge, and its inner lateral by the free border of the nose.

The roof of the antrum forms also the floor of the orbit (Fig. 365). These two laminæ of bone separate for a small space in the middle portion in order to allow the passage of the infraorbital nerve, which passes anteroposteriorly and emerges from the infraorbital foramen. This nerve is often injured during operations on the antrum.

The maxillary antrum in the adult is the largest of the accessory cavities of the nose; it exists at birth, but only reaches its full

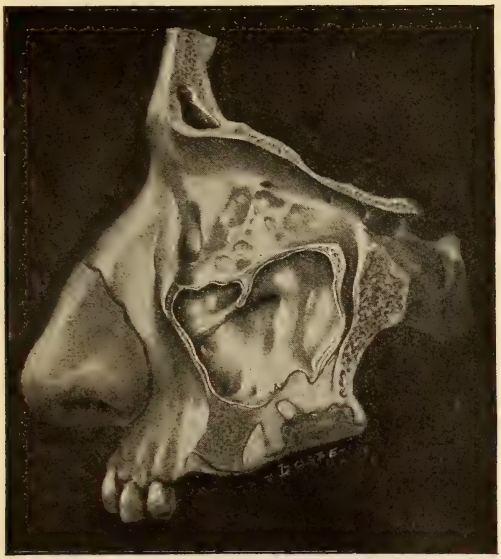

Fig. 364.—Dissection showing the antral surface of the nasoantral wall and ostium maxillare, with key plate.

size at puberty. Its average capacity is about 14 to 15 c.c. Occasionally it is of small size, but rarely is absent. The size and conformation of the maxillary antrum may vary considerably. Dilatations in various directions are due to irregularity in bone absorption during the period of development. Strictures of the bony walls or narrowing of the lumen of the cavity may also exist and interfere with operative attempts to enter the antrum. *Depression* of the facial wall has also been observed. When marked, such depressions render it impossible to reach the antrum through the alveolar process. Sometimes the antral floor is on a higher level than the nasal floor, and this may hinder entrance into the antrum through the inferior nasal meatus. Furthermore, operative efforts to enter the antrum may be frustrated by anomalies of the lateral nasal wall, chiefly by an outward bulging which may reduce the size of the antral cavity considerably. Septa, either membranous

or bony, may divide the cavity wholly or in part. Zuckerkandl has noted a vertical septum dividing the antrum into a posterior and anterior cavity, and Hajek has seen this posterior half infected and a purulent discharge issuing from the olfactory fissure.

Horizontal septa have been found less frequently. The author has observed nooks and recesses formed by small ridges and septa and believes that these favor stagnation and the more rapid development of pyogenic membrane.

The antrum is lined by an extremely delicate mucosa, a continuation of the nasal mucous lining. It is composed of a superficial or epithelial layer (ciliated), a middle or glandular layer (race-

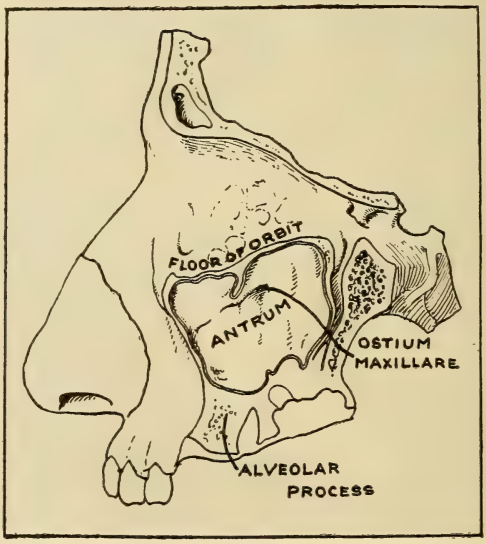

Key plate for Fig. 364.

mose), and a deeper, denser spindle-celled or periosteal layer; these layers are not always entirely distinct. The blood-supply of the antrum is derived from the vessels of the nasal mucosa which pass through the *ostium maxillare,* and some collateral branches of the vessels of the lateral nasal wall which pass through the bone to the inner antral wall.

The topographical anatomy of the maxillary as well as any of the other accessory nasal sinuses is best studied on the moist and dry sections of the head, since the irregularity in dimension and form of these cavities renders accurate description unsatisfactory and often misleading.

Diseases of the Antrum.

Etiology and Pathology.—The antrum of Highmore is subject to acute and chronic inflammatory changes in its lining mucosa, hydrops, necrosis of its walls, cysts, and tumors (benign or malig-

nant). The inflammatory changes are acute or chronic catarrhal, and acute or chronic purulent (empyema). The inflammatory process within the maxillary sinus as a rule is an extension from some part of the nasal cavity or from a neighboring accessory sinus, and includes those which are directly due to the infectious diseases, as the exanthemata, influenza, diphtheria, tuberculosis, and syphilis. The protrusion of carious teeth into the lumen and unclean dental procedures are causes of infection of the antrum. Invasion of the bony walls of the antrum is due either to pathological processes, to traumatism or to tumors.

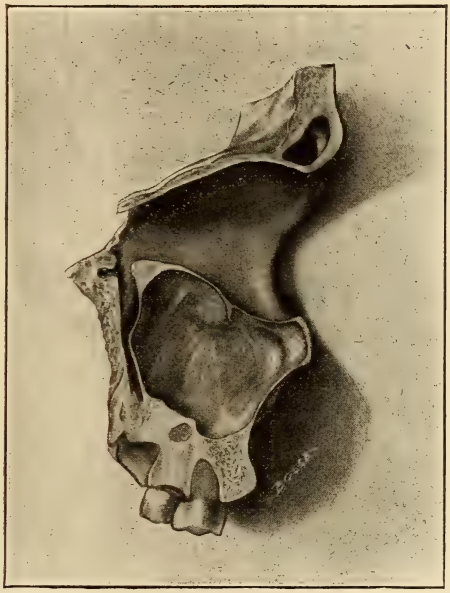

Fig. 365.—The outer or temporal wall of the maxillary antrum, with key plate.

Zuckerkandl, who was the first to accurately describe the catarrhal form, contends that in acute attacks the secretion of mucus is at first slight and appears only after the hyperemia has existed for some time, that the mucosa of the antrum may gradually become infiltrated, swollen and edematous, and that the disease is usually transitory and terminates in resolution. In a limited proportion of cases the disease becomes chronic, in which event the exudate takes place chiefly into the inner layer of the mucosa, while the deeper periosteal cells of the peripheral layer become edematous, and the whole membrane becomes thickened and often spotted with hydropic elevations. According to Domochowsky, this form of chronic catarrhal inflammation may become hypertrophic, or hyperplastic, and transform the mucosa into a pale, hard membrane. The latter process may advance to almost complete obliteration of the antral cavity, or become arrested at any stage of the transformation.

Acute Empyema of the Antrum.

In acute empyema the mucosa of the antrum becomes hyperemic, edematous, showing localized hemorrhages into the tissues, and its surface usually is covered with pus. The pathological changes are more rapid and severe when retention (closed empyema) occurs. Some authors, among them Zuckerkandl, Hajek and Domochowsky, believe that the soft tissue is not swollen to the same extent in this condition as it is in the acute catarrhal form. Acute empyema usually terminates in resolution of the mucous

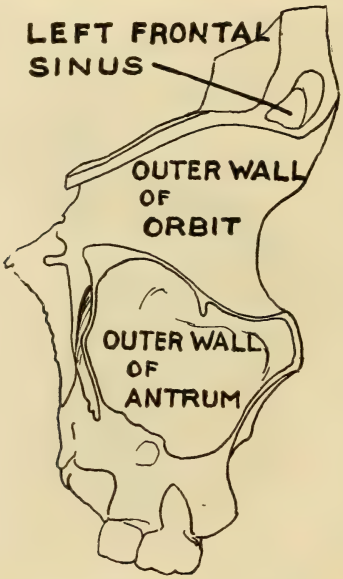

Key plate for Fig. 365.

membrane, but, under unfavorable conditions, ulceration may occur and even extend to the bone and induce caries. Furthermore it may terminate in the chronic form of the disease.

Chronic Empyema of the Antrum.

The pathological changes primarily affect the mucosa as in the chronic catarrhal form. Later the mucosa gradually thickens—dependent somewhat upon the degree of retention—with proliferation of the connective tissue and pus formation; at times the discharge is mucopurulent. Often the cavity is filled with polypoid masses. In the severe forms ulceration of the mucosa takes place, and, when the periosteal layer becomes involved, osteophytes and osteomata may develop. According to Hajek, inflammatory tumors, including cysts, polypi and hydrops of the antrum of Highmore, are probably the result of chronic inflammatory changes in the mucosa.

The polypi are usually located in or about the ostium, and have either a pedunculated or a broad attachment. They are prone to protrude through the ostium into the nasal cavity. Chronic empyema sometimes results from severe or neglected attacks of acute empyema.

Empyema of the antrum is usually unilateral. Occasionally it is bilateral, and, rarely, the entire accessory sinus system becomes involved (pansinusitis).

Symptoms.—The chief symptoms of an empyema of the antrum are pain and the discharge of pus from the nose. Pain is more common and constant in acute empyema, and its severity is dependent upon the degree of retention of the secretions. Likewise retention (closed empyema) occurs more frequently in acute cases. Unless the retention is prolonged as a result of inflammatory thickening of the mucosa surrounding the ostium maxillare, or from protrusion of polypi, the pain gradually subsides. In recent cases with retention the pain is located chiefly about the eminence of the malar bone and in the infraorbital region of the affected side. The teeth of the upper jaw may be the seat of severe pain, and at the same time sensitive to touch. From these points the pain radiates to the orbit, the supraorbital region and toward the ear.

Tenderness upon pressure or percussion is sometimes elicited over the malar process in its anterior portion, in the canine fossa, and in the infraorbital region. The pain, as a rule, is intermittent and neuralgic in character, and with the advent of free discharge it gradually subsides. In chronic empyema pain is less constant, except during exacerbations. Usually the sense of smell is impaired, and sometimes complete anosmia is complained of. A subjective malodor may be present, and occasionally there is nasal obstruction, epistaxis, and eczema in and around the nasal vestibule. Aprosexia, insomnia, and nervous depression or excitement are remote symptoms. In some cases fever, chills and gastric irritability are noted. Fever, however, is rare.

During all stages of an empyema of the antrum a purulent secretion into the middle meatus, with inflammatory thickening or hyperplasia of the nasal mucosa, constitute the constant objective signs. External swelling, while not common, is usually confined to the tissues about the malar eminence. A characteristic of the purulent discharge is its profusion in the morning and its partial or complete cessation during the day. This is accounted for by the situation of the ostium (Fig. 366), which impedes the escape of the secretion in the erect position of the body. The discharge is increased by recurrent colds to which patients with antral diseases are subject. In old cases the discharge is often fetid. In character it is mucopurulent or purulent, and in acute cases the color is sometimes bright yellow.

Diagnosis.—While the variability both of the subjective and objective symptoms makes the diagnosis at times difficult, the following rules for guidance usually suffice to establish a diagnosis of empyema of the maxillary sinus: 1, the intermittence in the

flow of the pus; 2, lowering the maxillary ostium by having the patient bend the head forward and toward the unaffected side (Fränkel and Ziem), or by the method of Bayer, who lays the patient on his abdomen and allows the head to hang over the edge of the bed, in order to effect more rapid discharge of the secretion; 3, flushing through the ostium or an accessory ostium (this is rarely possible); 4, exploratory puncture with subsequent flushing or

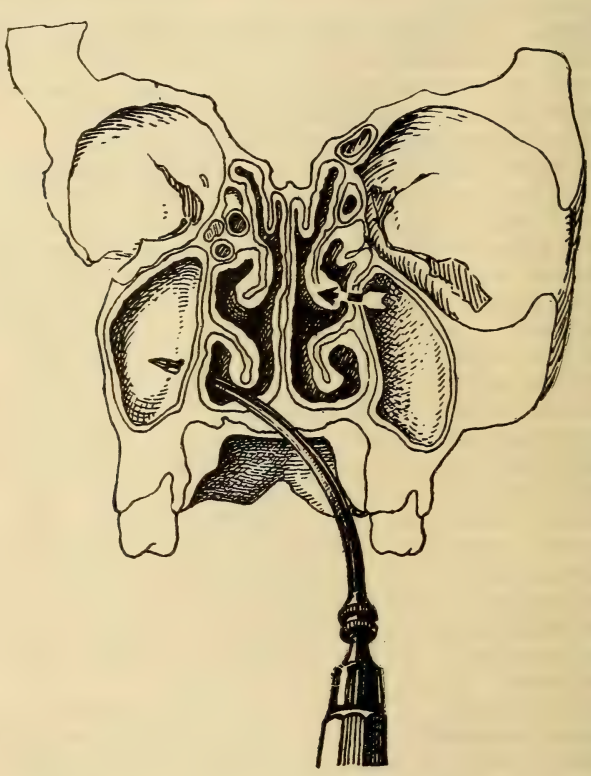

Fig. 366.—The location of the ostium maxillare and the exploratory puncture of the maxillary antrum.

aspiration (Fig. 366); 5, transillumination (Fig. 367); 6, radiographs of the head (Figs. 384 to 390) in the posteroanterior diameter give valuable diagnostic information, when properly interpreted.

Patients with a history of unilateral or bilateral nasal discharge, especially when it has existed for some time, should be subjected to a careful examination of all the accessory sinuses. As a rule it is possible to eliminate one sinus after another until the disease is definitely located. At the first examination the secretion may not be visible, for the reason that the patient naturally frees the nose of the discharge by blowing just before entering the examination room. In this event he should be requested to desist from blowing

Fig. 367.—Transillumination of the maxillary antra (antra of Highmore). *Right* side healthy, as shown by bright illumination underneath the orbit, and through the pupil. *Left* side diseased.

the nose for a short period of time, in order that a reaccumulation of secretion may take place. In empyema of the maxillary sinus the pus exudes into the middle meatus, flowing from about the centre of the under surface of the attachment of the middle turbinal toward the nasal floor, except in cases either of extreme atrophy or hypertrophy, when the flow may take other directions. In the morning, if the patient has not cleansed the nasal cavity, upon posterior rhinoscopy considerable secretion will be found in the nasopharynx. Pain upon pressure over the antral wall, when present, is of diagnostic significance.

Aside from the characteristic pain and discharge, transillumination is the most valuable diagnostic aid, especially when the disease is unilateral. If transillumination (hereinafter described)



Fig. 368.—The Coakley transillumination lamp.

reveals a dark area over the malar eminence and beneath the orbit upon the side which has been the seat of the characteristic pain and discharge, in contradistinction to the bright glow portrayed by the malar eminence, infraorbital space and pupil upon the opposite side (Fig. 367), the diagnosis of empyema may be considered sufficiently positive to warrant an exploratory puncture (Fig. 366) for the purpose of evacuating the pent-up pus.

The examination should be conducted as follows:—

1. Make a preliminary rhinoscopic examination of the nasal cavities and note the condition of the mucosa, the location and degree of inflammation and infiltration of the soft tissues. In acute maxillary sinusitis it is common to find the swelling so great as to produce complete occlusion of the affected side. Note the presence, location, character and quantity of the secretion.

2. Spray the nostril of the affected side with a 2 per cent. solution of cocaine, followed five minutes later with a spray of 1 : 5000 solution of adrenalin.

3. During the period required (fifteen or twenty minutes) for local anesthesia and shrinkage of the soft tissues to take place, the

sinuses should be transilluminated, in the following manner: Place the patient in a totally dark room in which the transilluminating apparatus is located. The direct current, controlled by a proper rheostat (Fig. 3), is preferable to storage batteries. The original instrument devised by Herying for this purpose was uncouth, unwieldy and expensive. The author modified and simplified the apparatus, but at the present time the lamp devised by Coakley (Fig. 368) is in general use for transilluminating the maxillary antrum (Fig. 367) and frontal sinus (Fig. 382). It is especially to be commended on account of the movable glass hood, which is easily sterilized. A good rheostat is necessary, and one which is suitable for the kind of current (alternating or direct) which is in use.

Placing the glass-covered lamp into the mouth, with the lips closed, the light is turned on and the results noted. The lower part of the face is not to be considered in a diagnostic sense, inasmuch as the cheeks show a glow of light up to the level of the antrum floor, even when the latter is the seat of disease. Normally there is a glow of light underneath the orbit, and usually a reflection through the pupil upon the healthy side, and darkness at the corresponding points upon the diseased side (Fig. 367). The degree of illumination depends both upon the thickness and density of the bones, and upon the candle power of the lamp. Should the patient wear any dental apparatus which might obstruct the light rays, it should be removed before attempting to transillumine the maxillary sinuses.

In cases of bilateral empyema of the maxillary sinuses transillumination is of less value. Under these circumstances, if the transillumination is negative on both sides, then bilateral sinusitis may reasonably be suspected.

4. Having completed and recorded the transillumination findings, a sufficient time has elapsed to obtain the full effect of the cocaine-adrenalin application. A flow of pus between the middle turbinal and the septum indicates disease of the posterior ethmoidal cells, or the sphenoid sinus, or both sinuses.

If the pus is exuding from the space between the middle turbinal and the outer nasal wall, the disease is located in one or more of the sinuses which form the anterior group—the frontal, the anterior ethmoidal or the maxillary.

Skiagraphs.—In skiagraphy we possess a valuable diagnostic measure, both in determining the size and shape of the accessory sinuses and their diseases. Skiagraphy is more fully described in the following chapter, on Diseases of the Frontal Sinuses. So far as the maxillary sinus is concerned the difference between the healthy and the diseased side is often well marked on the skiagraph (Fig. 384). Owing to the pathological changes in the diseased antrum in which the thickened lining membrane displaces the air, sometimes to complete rarification, the skiagraphic plate shows the diseased side with an ill-defined or blurred boundary, whereas

the healthy antrum shows a well-defined boundary. The X-ray also gives fairly good results, even where the bone is greatly thickened.

Prognosis.—The prognosis in chronic suppuration of the antrum depends largely upon the factors which enter into its causation and the form of treatment instituted. In mild cases warm saline or antiseptic irrigation, through the natural opening where that is possible, or else through an artificial puncture through the nasoantral wall underneath the inferior turbinal (Fig. 366), may effect a cure. When of dental origin the removal of the diseased tooth and irrigation through this opening will often cause an empyema to yield. Pyogenic or degenerative changes in the mucosa, causing polypoid or cyst formation, require some form of surgical procedure (usually radical) to cure the disease.

Treatment.—In the acute catarrhal inflammation of the antrum the nasal inflammatory condition must be treated the same as that described for acute rhinitis (Chapter XXXIII), and efforts made to facilitate drainage from the natural antral opening. For this purpose pledgets of absorbent cotton saturated with a 4 to 10 per cent. solution of cocaine or alypin, combined with a 1:5000 solution of adrenalin chlorid, are applied to the nasal cavity, in the region of the ostium maxillare, in order to contract the soft tissue and thus promote the drainage of the antrum. Warm saline douches to the nasal cavity, repeated at intervals of two or three hours, tend to allay the inflammatory process.

A marked improvement in the methods of non-operative treatment of purulent conditions of the nasal accessory sinuses has been achieved by the use of the suction pump apparatus devised by Dr. Lewis A. Coffin, of New York, and fully described in the Laryngoscope, December, 1915, page 832 (Fig. 369). By means of this instrument, attached to an electric pump, a sufficient degree of negative pressure may be induced to draw the accumulation of pus from the sinuses into the nasal cavity, and often into the reception bottle itself. It has an added advantage that by means of the spray attachment a nebula of any type of remedial agent may be forced into the vacuumized cavities. The change in the nose from the positive to the negative pressure may thus be alternated as often as necessary. In the experience of the author much benefit may be expected from the employment of the suction apparatus in a large majority of cases of both acute and chronic purulent sinusitis. Among the remedial agents recommended are 5 per cent solution of carbolic acid and Churchill's tincture of iodine. Solutions of Bulgarian bacilli have also been employed for the same purpose but the chief benefit seems to arise from the suction element in the treatment. Should these measures prove ineffectual in establishing free drainage, surgery must be resorted to.

Drainage being more effective from the most dependent part of a cavity, an artificial opening should be sought as near the floor of the antrum as feasible (Fig. 366). For the purpose of irrigation the nasal route, hereinafter described, is preferable to openings made through the canine fossa or alveolar process. The extraction of a

tooth to gain an entrance into the antrum the author condemns, unless a diseased tooth or necrosis of the alveolar process is responsible for the purulent condition. To enter through the alveolar process a drill is introduced through the root cavity of the second bicuspid or first molar tooth; the direction is upward and slightly inward to avoid puncturing into the nose or cheek. This opening may then be enlarged by chisel or bone-cutting forceps to facilitate examination and treatment of the sinus. Curettage, irrigation and gauze packing are then employed. The treatment may require a few weeks, during which time the opening can be covered by a dental plate. In irrigating by the intranasal route, after cleansing the nose by douche or spray, the inferior nasal meatus on the diseased side is thoroughly subjected to adrenalin and to cocaine an-



Fig. 369.—This instrument consists of two bottles mounted on the lower side of a tube one-half inch in diameter which terminates in an olive-pointed tip about three and one-half inches from the bottles. Between the bottles is a switch key by means of which the inside of either bottle may be connected with the lumen of the connecting tube, the inside of the other bottle being at the same time disconnected from the same. Between the bottles also is a small tube extending through the key sleeve for the attachment of rubber tubing which connects the apparatus with an exhaust pump. When the key is so turned as to connect the second bottle with the connecting tube one is able to create a vacuum in this bottle by working the exhaust pump. This bottle is five inches in length and one inch in diameter and is the vacuum bottle of the apparatus. This bottle connects with the nose by means of the olive point and when the nasopharynx is closed off from the oropharynx the nasal chamber and any cavities connecting with it are partially vacuumized when such a condition exists in the bottle. The nasal chamber may be closed either by instructing the patient to say ka, ka, ka, or the ballooning of a small rubber bulb in the chona.

esthesia, especially in the space between the inferior turbinal and the lateral nasal wall, where the puncture is to be made.

If the operation is chiefly exploratory or for the purpose of irrigating the antrum for a few days, the author recommends that a fairly large opening be made through the naso-antral wall by

means of the Weiner rasp (Fig. 371). Daily irrigations may be carried out by using the Myles irrigation tube and cannula (Fig. 370).

The antrum is entered below the inferior turbinal bone, about one inch from the inferior border of the nostril. Here the antral wall is comparatively thin, and the lachrymal canal lying anterior to this point is not injured. The rasp (Fig. 371) is pointed to the junction of the inferior turbinal with the outer nasal wall, and enters the antrum under slight pressure, in an outward and upward direction. If the antrum is filled with secretion it will readily flow out when the cannula is introduced or upon bending the head

Fig. 370.—Myles's antrum irrigation tube.

of the patient forward and toward the healthy side. Otherwise the secretion follows the return flow when irrigated.

Irrigation of the Antrum.—Having introduced the cannula with its rubber-tubing attachment, the head should be bent forward over a pus basin. Then with a large-sized piston syringe (Fig. 47) a warm solution (salt or antiseptic) is thrown into the sinus. A return flow follows through the normal ostium, consisting of the solution intermingled with the retained secretions of the antrum. The syringing should be continued until the return flow runs clear. Before removing the cannula the residual fluid should be blown from the antrum, using the syringe minus solution for this purpose. The irrigations should be repeated daily until all

Fig. 371.—Weiner's rasp for puncturing and enlarging an opening through the naso-antral wall.

symptoms abate and the antrum becomes clear under the daily transillumination. If found necessary the rasp opening may be enlarged by means of a burr, or preferably with some form of punch forceps. From time to time granulations forming about the opening may have to be cleared away by curetting. Laboratory examination of the antral secretion is advisable.

The pain attending the daily treatment is slight, providing local anesthesia is introduced about the orifice of the antral opening. One disadvantage of an opening through a tooth socket is the necessity of wearing a dental prothesis. Another disadvantage is that the opening through the canine fossa requires constant care

to prevent infection from the mouth or by aspiration of the buccal secretion into the antral cavity.

The above treatment is successful in the acute cases, and in the chronic cases which show no deep-seated pathologic lesions. While it is difficult, in a given case, to determine beforehand the exact condition of the sinus and the amount of benefit to be derived from the simpler treatment, nevertheless, a trial of these milder surgical procedures should be made before resorting to the more radical measures. In protracted cases of empyema with irreparable changes in the mucosa, palliative treatment is sufficient, and some form of radical operation becomes necessary.

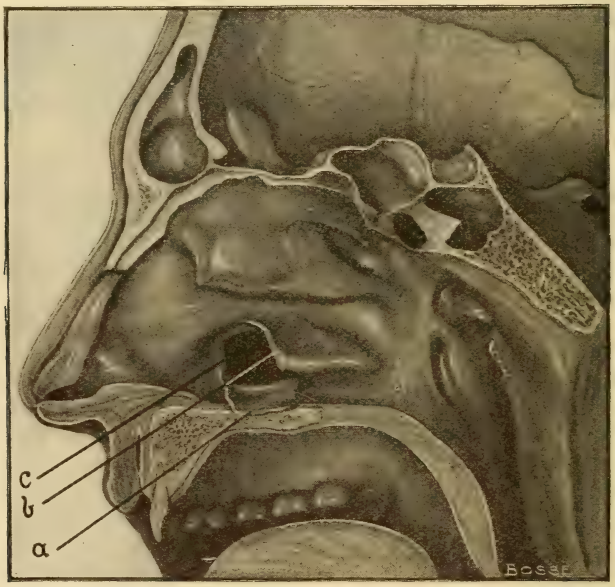

Fig. 372.—*a*, the flap of mucous membrane detached from the lateral wall of the nasal chamber under the inferior turbinate; *b*, the remaining portion of the inferior turbinate after the removal of the anterior third; *c*, the approximate size of the opening into the antrum Highmori necessary to evacuate the products of chronic suppuration. (*Harmon Smith*, with permission.)

Radical Operation.—Of the radical procedures the simplest is the removal of a section of the anteroinferior portion of the nasoantral wall, in order that permanent free drainage may thereby be secured. This operation is applicable to cases which have not progressed to the excessive formation of polypi in the antral mucosa, or to necrosis of the bony walls.

The steps of the operation are as follows: Under local anesthesia the anterior third of the inferior turbinal is first removed (Fig. 372). The nasoantral wall is then punctured and the opening enlarged with punch forceps of various types (Figs. 348, 373, 374)

until a permanent opening of at least five-eighths inch in diameter has been made, through which considerable curetment is possible, and polypi may be grasped and withdrawn (Fig. 372). With care a flap of mucous membrane may first be detached from the lateral wall. Packing of this wound is unnecessary and undesirable after two or three days, the purpose of this operation being to effect a cure of the disease by establishing free drainage. In the author's experience the results of this operation fully warrant its employment in simple forms of chronic empyema of the antrum.

Operation Through the Canine Fossa.—The facial or anterior wall allows a large opening, and has, therefore, long been a favored location for entering the maxillary sinus, as it seems best adapted



Fig. 373.—Wagener's forward cutting antrum forceps.

to the wide exposure of the antral cavity. This method was originally practised by Lamorier and after him by Desault; Küster later improved the technique, and the resection is often referred to as the Desault-Küster method.

The operation should be performed under general anesthesia, but local anesthesia may be substituted if necessary. After thorough scrubbing of the face and cleansing of the teeth and buccal mucosa, a gauze sponge should be inserted between the molar teeth, the cheek and gums, to absorb the blood which otherwise would run into the throat. An incision is then made through the mucous membrane and periosteum, following a line one-fourth inch above the free border of the gum from the molar to the canine teeth. The mucosa and periosteum are then lifted from the facial wall of the antrum with a periosteal elevator, and retained by retractors. With a small chisel the opening is effected through the bony wall of the canine fossa. It is usually advisable to avoid

wounding the underlying mucosa until a considerable portion of the bony wall has been removed. It is advisable to remove a large section of the anterior bony wall, both for the purpose of inspection and to enable the operator to freely remove all the diseased contents of the antrum. The further removal of the wall is best accomplished by rongeur forceps and strong curets. An incision may now be made through the antral membrane and the contents of the cavity evacuated. The sponge of gauze should be frequently changed during the operation and the blood-clots and *débris* cleared away.

Subsequent to the resection of the anterior wall the steps of the operation depend upon whether the entire mucous lining is to be removed. Many operators favor the removal of diseased mem-

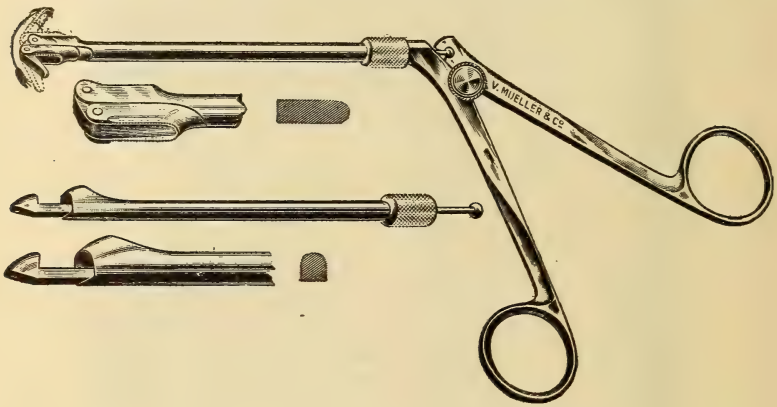

Fig. 374.—Ostrum's forward cutting forceps.

brane only; others prefer to eradicate the lining mucosa in its entirety and allow the cavity to granulate.

The author's experience leads him to favor a total eradication of the entire mucous lining, as he only resorts to this operation in the severest cases.

With either a brilliant headlight (Fig. 7.) or a small electric lamp the antrum may now be thoroughly illuminated and its cavity inspected, and under the guidance of the electric light the entire mucous lining and the pathologic antral contents are removed, by means of curets and forceps (Fig. 401).

Carefully performed, this operation is attended with few accidents and but little danger. In one of the author's cases the salivary duct (duct of Stenson) was injured, and later on much annoyance to the patient occurred from the excessive flow of saliva into the nasal cavity at meal hours. It finally became necessary to divert the mouth of the duct from the antral wound, and thus return the flow into the buccal cavity.

Having cleared the antrum of its diseased contents, the cavity is flushed with a normal saline solution and carefully packed with

strips of iodoform gauze. Likewise the external wound is tightly filled in order to prevent rapid contraction of the soft tissues. The original tampon should be allowed to remain undisturbed for about five days, unless the temperature rises or other untoward symptoms develop. More or less hemorrhage follows its removal. After the first dressing each packing should be allowed to remain one day, and should be sufficiently snug to prevent exuberant granulations. In from four to six weeks the cavity granulates and the external wound may be allowed to close. So long as any fistula remains, the patient should be instructed to introduce a pledget of gauze of sufficient size to cover its orifice whenever food is taken. Should proliferations of the mucosa or polypi spring up, either around the margin of the wound or in the region of the ostium maxillare, they should be removed with a snare or a sharp curet and the denuded area cauterized with trichloracetic acid. Necrotic changes in the bony walls never have been observed by the author, and but few have been reported in the literature.

This method of operating has been subjected to many modifications, both as to the size of the external opening and the measures instituted for the treatment of the diseased mucosa. Of the variations the most notable is the breaking down of the whole or part of the adjacent nasal wall after the Caldwell-Luc method, and subsequent treatment of the antrum through the nasal cavity, while the buccal opening is closed by sutures at the original operation. A counteropening into the nose is often of great service, especially when combined with frontal or ethmoidal operations. Furthermore, many advantages are obtained by the early closure of the buccal opening, particularly in relation to mastication, and the results, pertaining to the time required for final healing and to the cessation of discharge, favor the counteropening into the nose.

The Caldwell-Luc Operation.—Both of these operators described independently a similar procedure, Caldwell, in New York, in 1893, and Luc, in France, in 1897. In detail the operation consists in creating a counteropening into the antrum, through the outer nasal wall. After removing the anterior wall by entering through the canine fossa, and after removing the diseased lining membrane of the antrum, a plug of gauze is introduced into the nasopharynx, as described under the treatment of epistaxis (Chapter XL), to prevent the blood from trickling down the pharynx and into the lower respiratory tract. If the anterior third of the inferior turbinal has not previously been removed, it should now be done after the method described in Chapter XXXVI, Fig. 372. Through the area of the outer nasal wall thus exposed, we now gain entrance into the antrum. The opening is then enlarged by resecting with bone-cutting forceps (Figs. 348, 373 and 374), in order both to meet the demands for permanent free drainage and to overcome the tendency to contract during the after-treatment. During the intranasal manipulation the operator should carefully avoid injuries to the nasal septum.

Having created an ample opening the antrum is now cleansed, and the cavity tightly packed with strips of gauze (selvage-edged preferred). The mucoperiosteal flap of the canine fossa-opening is placed in position, and sutured with catgut. The plug behind the teeth and the postnasal plug are now both removed.

Jansen has devised a further modification of the radical operation which obviates the necessity of a preliminary opening through the canine fossa. The steps are as follows:—

1. Dilate the nostril widely.

2. Make an incision, following the line of juncture of the skin and mucous membrane of the vestibule through the soft tissues to the angle formed by the nasal and canine walls of the antrum.

3. Elevate the periosteum first toward the canine fossa, and



Fig. 375.—First step in the Jansen antrum operation.

afterward from the anterior portion of the nasoantral wall, but without penetrating the nostril proper or severing the inferior turbinal. Introduce the retractors (Fig. 375), one toward the canine fossa and the other along the nasoantral wall, and retract the wound widely. Then break through the angle above described, either with rongeur forceps or chisel, and gradually resect the bony walls in all directions until a large opening has been made (Fig. 376).

4. Remove the pathological contents of the antrum and flush with saline solution.

5. Finally, from the lower point of the primary incision, through the soft tissues extend a second incision backward along the nasal floor for the purpose of establishing a permanent communication between the antrum and the nasal cavity. The antral cavity is then packed with gauze.

6. This operation can be performed under local anesthesia.

The After-treatment.—Following the severe traumatism to which the antrum and the surrounding tissues are subjected, the cheek and lower eyelids may become swollen and edematous. This

troublesome complication may be controlled by the continuous application of ice-cloths over the swollen areas for from twenty-four to thirty-six hours.

The primary packing should remain undisturbed for about five days, after which the dressings should be changed daily. At each dressing the antral cavity should be flushed with lukewarm physiological salt solution. The gauze packing may be dispensed with after the third week, providing the granulations are healthy.

For the patient's comfort it is well to caution him to avoid masticating his food upon the side operated upon for the first few days. The further after-treatment aims chiefly at cleanliness and drainage. Strong antiseptics tend to irritate the denuded surfaces, and are, therefore, contraindicated.

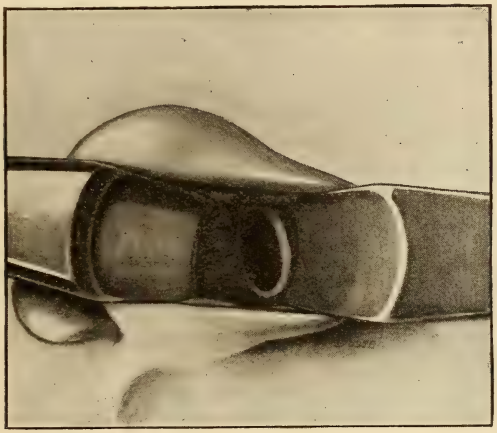

Fig. 376.—Second step (resection of bone) in the Jansen antrum operation.

The patient may be taught to flush his own antrum daily during the final stage of the treatment. As the secretion decreases the number of douches may be diminished, but it is advisable to continue at least one treatment each day until the discharge ceases.

In cases where the radical operation has been performed without the removal of the lining mucosa, and the secretion proves rebellious to gauze packing or flushing, local applications of silver nitrate increasing from 2 to 10 per cent. or of argyrol 25 per cent. solution will often be found of great benefit. The same measures are advised for reducing exuberant granulations in the wound cavity or around the orifice.

Cysts.—Cysts do not primarily spring from the antrum, but develop in the alveolar process of the superior maxillary bone, and either are closed or perforated by a dental root. Hence, they are commonly termed dentigerous cysts. They often proliferate toward and into the antrum, and may even push the antrum aside or project into the middle meatus of the nose. In one of the author's cases a large dental cyst was opened through the nasal

floor. The cyst extended downward into the alveolar process and a counteropening was made in the mouth. These cysts contain a hydropic fluid when non-infected and cholesterin crystals may be found; in infected cysts, however, the contents are mucopurulent in character, or else of a doughy or cheesy consistence. The occurrence of cysts has been ascribed to the retention or malformation of teeth, or to the suppuration of dentoblasts. These cysts often attain a considerable size.

TREATMENT.—Free evacuation through a large opening, irrigation and gauze packing are sufficient to effect a cure.

Osteomata.

Osteomata of the antrum are rare. They spring from the periosteum and probably are of congenital origin. They are of slow growth and may attain considerable size without causing symptoms. When encroaching on the nasal cavity the usual symptom is that of obstruction, with difficult nasal respiration. They seldom cause pain, and in this differ from the malignant growths.

TREATMENT.—The treatment is surgical (see New Growths of the Nose, Chapter XLII, for the treatment of osteomata of the antrum).

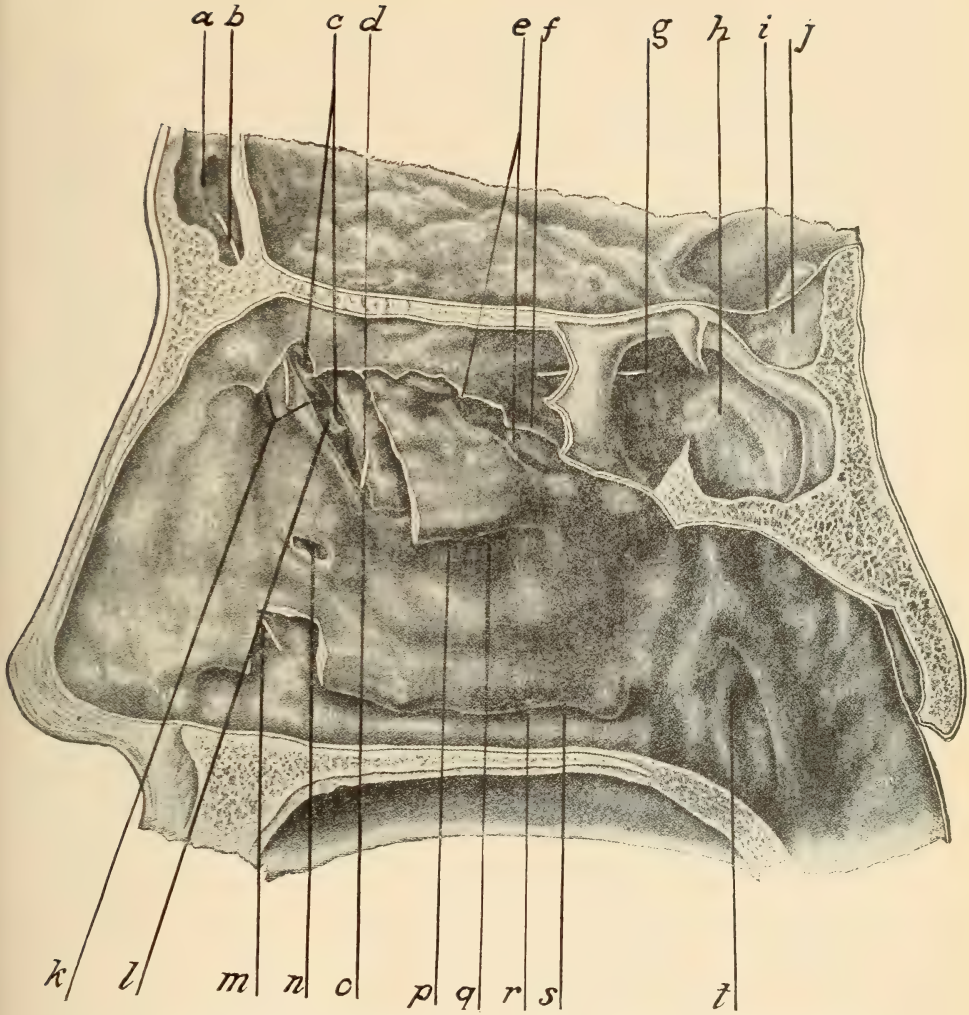

Fig. 377.—Orifices of the nasal accessory sinuses. (*Deaver*, with permission.)

a, Frontal sinus.
b, Straw in infundibulum.
c, Orifices of anterior ethmoidal cells.
d, Bulla ethmoidalis.
e, Orifices of posterior ethmoidal cells in superior meatus.
f, Superior turbinal (cut).
g, Straw in orifice of ethmoidal cell.
h, Sphenoidal cell.
i, Diaphragma sellæ.
j, Cavum sellæ.
k, Middle turbinal (cut).
l, Hiatus semilunaris.
m, Straw in nasal duct.
n, Additional orifice of antrum of Highmore.
o, Straw in orifice of antrum of Highmore.
p, Middle turbinal (cut).
q, Middle meatus.
r, Inferior turbinal.
s, Inferior meatus.
t, Orifice of Eustachian tube.

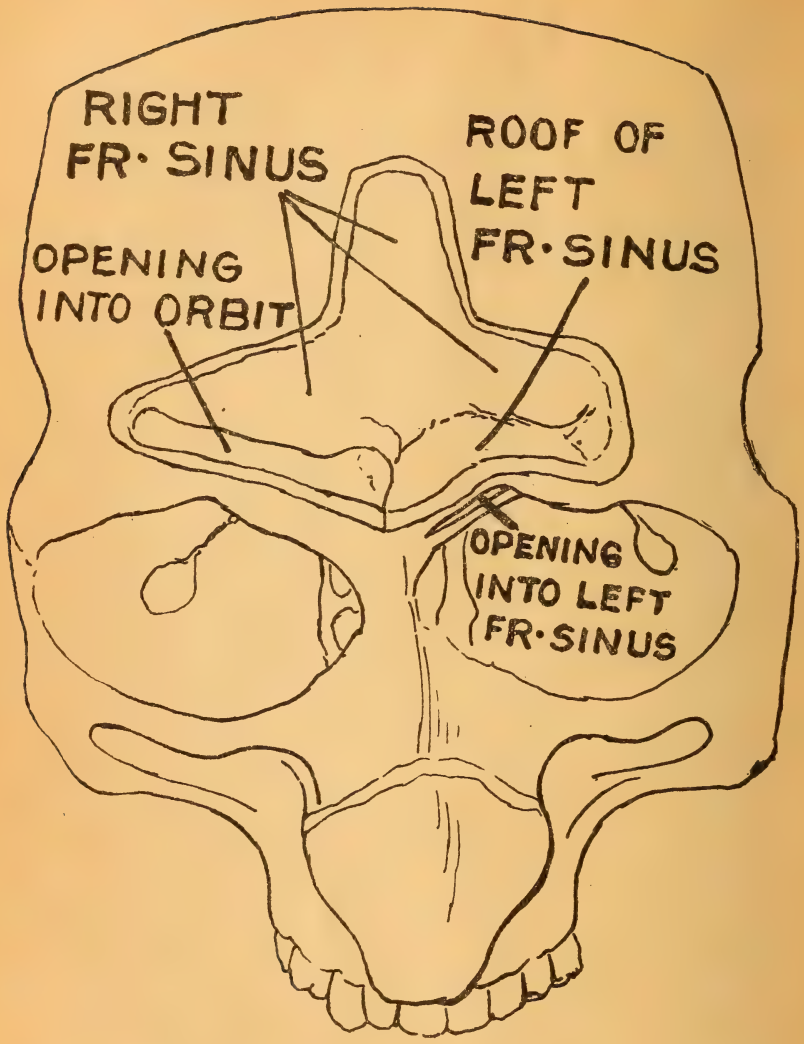

Key plate for Fig. 378.

Fig. 378.—The abnormally large right frontal sinus, minus septa, occupies the entire right, middle and the major portion of the left supra-orbital regions. The drawing represents the head tilted forward and downward. Note the extreme height of the sinus in the median portion and the anteroposterior depth over the right orbit. The inner wall on the left shelves forward and forms the roof of the small left sinus. The latter is more fully illustrated in the following cut, which represents another view of the same specimen. (From Dunning's collection.)

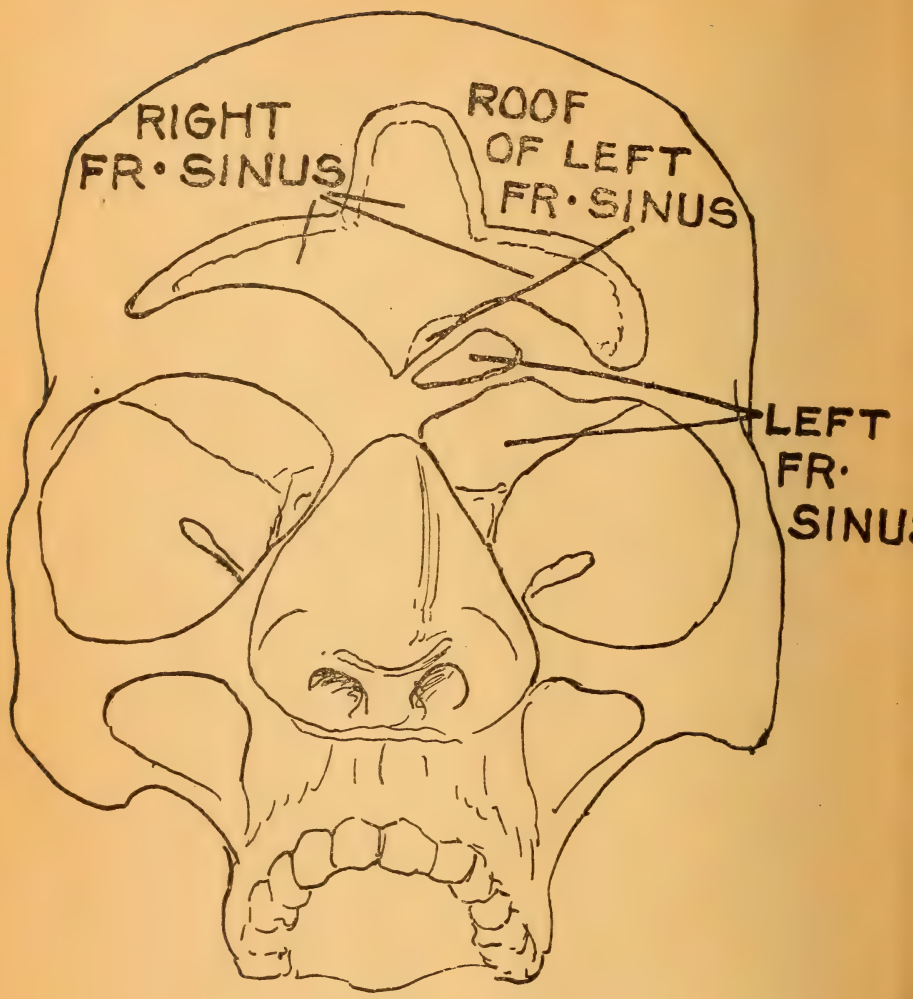

Key plate for Fig. 379.

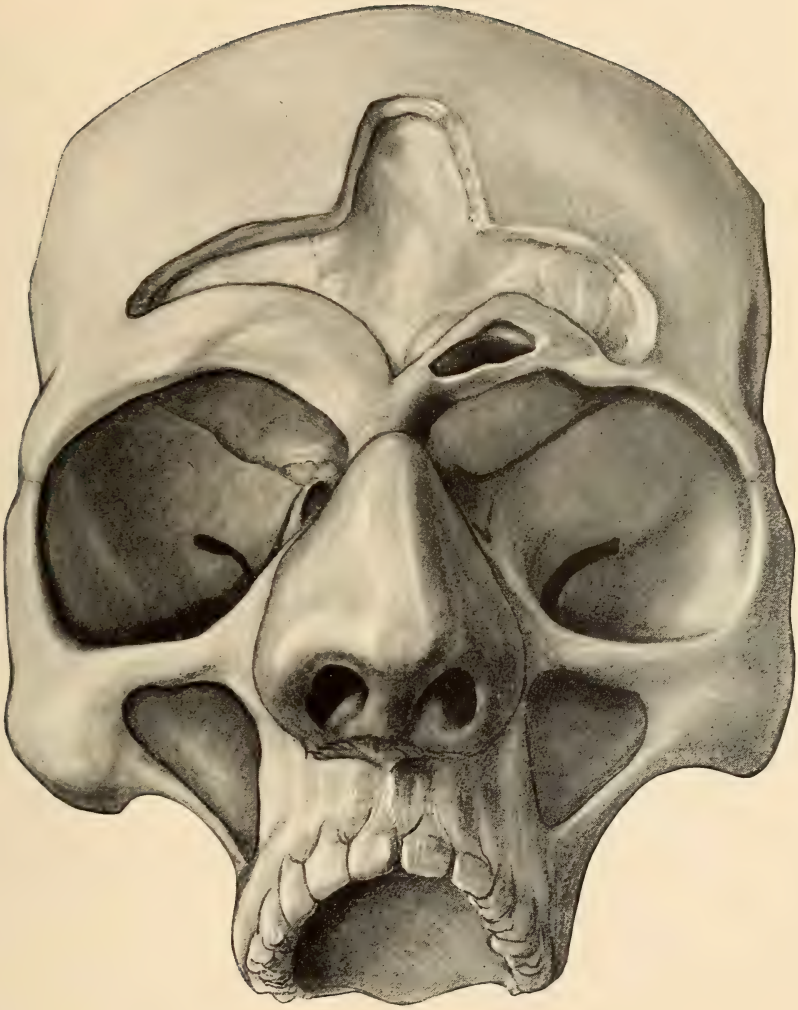

Fig. 379.—The same specimen viewed with the head tilted slightly backward. The dip of the abnormally large right sinus into the supraorbital space is shown, the bony wall having been cut away. Note the similar dip of the extremely small left sinus, which has been opened just above the supraorbital ridge. The left sinus is entirely within the confines of the frontal bone and opens directly into the nasal cavity. (From Dunning's collection.)

CHAPTER XXXVIII.

DISEASES OF THE NASAL ACCESSORY SINUSES.

(*Continued.*)

THE FRONTAL SINUSES.

Surgical Anatomy.—The frontal sinuses belong to the anterior group of the accessory sinuses. They are two irregular and somewhat pyramidal shaped cavities, located above the orbits and between the tables of the frontal bone, upon either side of the median line. The frontal sinuses are subject to wide variations, both in size and in conformation (Figs. 386 and 387). The sinus of one side often is much larger than the opposite (Fig. 378) or there may be but a single sinus, and in rare instances they are absent altogether.

The floor of the frontal sinus is formed mainly by the orbital plate. The balance lies posterior to the articulation of the frontal and nasal bones and the nasal process of the superior maxillary bone. The anterior wall is formed by the outer plate of the frontal bone, and the posterior wall by the inner plate of the frontal bone.

The frontal sinuses are lined by a continuation of the mucous membrane of the nose, minus the erectile tissue, and each sinus communicates with the corresponding nasal fossa by means of a passage known as the *infundibulum* or nasofrontal duct, which serves both for drainage and aëration. The upper portion of the *infundibulum* occupies a portion of the nasal part of the sinus floor, its posterior wall forming at the same time the anterior wall of the anterior ethmoidal cell. Unlike the sphenoidal and the maxillary sinuses, the openings (ostii) of the frontal sinuses lie in their most dependent portions (Fig. 345) and thus favor spontaneous drainage of the secretions. The ostium of a frontal sinus is rarely more than 3 mm. in diameter, and often it is less. From its commencement in the nose the nasofrontal duct passes upward, forward and very slightly outward. Hence a probe or cannula must be curved in conformity with its course in order to enter the frontal sinus.

The infundibulum terminates below in the *hiatus semilunaris* (Fig. 377), which lies in the middle meatus, between the *processus uncinatus* and the *bulla ethmoidalis.* Occasionally this duct opens directly into the antrum of Highmore or the *bulla ethmoidalis.*

The frontal sinuses are separated by a thin septum of bone, which occasionally is incomplete. This septum may be straight or deviated, and is deeply placed behind the nasal process of the superior maxillary bone and near the inner wall of the orbit. The termination of the nasofrontal duct in the middle meatus is about on a level with the palpebral fissure. Intermediary septa in one or both sinuses are common. Zuckerkandl has described the condition known as "bulla frontalis" an encroachment upon the lumen of the frontal sinus by an ethmoidal cell.

According to Morris, frontal sinuses of large dimensions may measure 2 inches from side to side, 1½ inches anteroposteriorly, and occupy a great part of the vertical portion of the frontal bone. When very small they may scarcely extend above the nasal process. In elderly people the sinuses tend to enlarge as a result of senile bone atrophy.

The frontal sinuses are absent before the seventh year, and they develop from a gradual extension or pushing upward of the *hiatus semilunaris.* With the progressive separation of the two tables of the frontal bone, the sinuses continue to enlarge until about the age of twenty. The variations in size, shape and position may be accounted for by this peculiar method of development. The anterior wall is comparatively thick, and in proportion to the size of the skull the sinuses are larger in men than in women. The bony walls are thinner in women than in men, and they may become extremely thin in old persons of either sex. The floor or *pars orbitalis* is the thinnest of the frontal sinus walls, while the anterior wall is the thickest.

DISEASES OF THE FRONTAL SINUSES.

Diseases of the frontal sinuses occur for the most part in connection with or as a result of inflammatory affections which have primarily attacked the nasal cavities. Rarely the frontal sinus may be primarily diseased. On account of their late development, diseases of these sinuses are uncommon under the twentieth year. The frontal sinus diseases herein described are classified as follows: 1, simple catarrhal inflammation; 2, purulent inflammation; empyema; 3, periostitis and necrosis. Cysts and mucocele are pathologic conditions rarely found in the frontal sinus. Osteomata and malignant neoplasms at times encroach upon the frontal sinuses, but as a rule they originate elsewhere.

Simple Catarrhal Inflammation.

Simple catarrhal inflammation usually occurs in connection with acute rhinitis, or "cold in the head."

Etiology.—Etiologically, simple catarrhal inflammation of the frontal sinuses is a progressive inflammatory condition which occurs in conjunction with acute rhinitis. It extends by continuity from the nasal mucous membrane to that of the sinus, and partakes of the characteristics of the intranasal inflammatory process. Hence the etiology corresponds with that of acute rhinitis (see Chapter XXXIII).

Symptoms.—It is comparatively a common affection, and in the milder forms is characterized by localized frontal headache, sensations of pressure in the frontal region and about the eyes. These phenomena are usually intermittent, and may be renewed with each attack of acute rhinitis. In the severe forms, especially when accompanied with temporary occlusion of the nasofrontal

duct, these symptoms become more severe and continuous. Pressure on the supraorbital plate or percussion over the sinuses during the early stages elicits considerable tenderness or pain. The interference with the air pressure within the sinus aggravates the symptoms and modifies the resonance (timbre) of the voice. Retained secretions, even in the catarrhal form, give rise to pressure and hence to severe, intermittent pain.

Diagnosis.—The diagnosis is based upon the nature of the intranasal inflammation, and the characteristic symptoms.

Prognosis.—The prognosis is good, barring the possibility of the inflammation assuming a purulent type. All symptoms usually subside in from two to three days.

Treatment.—The main indication for treatment is the relief of pain, and the maintenance of drainage through the nasofrontal duct. The cleansing and soothing measures outlined for acute rhinitis should form a part of the treatment of this affection. During the early stage considerable relief is obtained by the application of small icebags to the frontal region. If the icebag is not well borne, hot fomentations may give greater comfort. When the nasofrontal duct is obstructed as a result of the inflammatory process or from septal deflection, nasal polypi, or enlargement of the middle turbinal, the swelling and turgescence should be temporarily reduced by applications of suprarenal extract in the region of the infundibulum, thereby maintaining drainage of the pent-up secretions.

The disease subsides rapidly, providing ample drainage is maintained. It is inadvisable to attempt to wash out the frontal sinus by introducing a cannula, except when pus is present.

Purulent Inflammation of the Frontal Sinus (Empyema, Acute and Chronic).

The purulent form of frontal sinusitis, whether acute or chronic, is relatively rare, probably on account of the free drainage afforded by the favorably located and directed nasofrontal duct (Fig. 377). The acute form of the disease is more common than the chronic.

Etiology.—Purulent invasion of the frontal sinus does not occur primarily except in rare instances, as the result of external traumatism of the frontal bone, or by intranasal operative interference, which arouses the latent bacterial contents of the sinus to activity. The source of this affection is almost invariably found in some morbid process, either within the nasal passages or in the remaining accessory cavities, which has extended by continuity to the mucosa of the frontal sinus. Traumatic ulcerations of the nasal mucosa, foreign bodies in the nose, including maggots, centipedes and other insects, occlusion of the nasofrontal duct, either from tumors, polypi, septal deflections or enlarged turbinals, are among the causative factors of a more or less mechanical nature. Furthermore, acute or chronic purulent inflammation of the ethmoidal

labyrinth, sphenoidal sinus or the maxillary antrum often precedes the invasion of the frontal sinus. Of these, purulent ethmoiditis is the most prolific source of frontal sinusitis, especially in its chronic form. Acute attacks of purulent frontal sinusitis often arise from specific infections which have primarily invaded the nasal mucosa. Of these, la grippe and the exanthemata are types. Similarly, but less rapidly, tuberculosis, syphilis, ozena, and even neglected chronic rhinitis may extend to the frontal sinus. In any event, barring traumatism, the pathway of infection must be through the nasofrontal duct, and, so long as an infective or purulent process of any kind continues within the confines of the nasal cavities, the frontal sinuses may become infected.

Pathology.—The pathologic changes in acute frontal sinusitis are chiefly confined to the lining mucosa, which becomes inflamed, swollen and edematous. In severe cases, where the sinus is temporarily closed (closed empyema), localized hemorrhage into the tissue occurs, and pus fills the cavity.

In chronic empyema the inflammatory stage is followed by thickening of the mucosa and proliferations of connective tissue, with a continuation of the pus exudate. Polypoid degeneration of the lining mucosa is less common in the frontal than in the maxillary sinus. In the severer forms ulceration of the mucosa, periostitis, and even necrosis of the bony walls may ensue.

Symptoms.—During the acute stages of an attack the chief symptoms of empyema of the frontal sinus are pain and the discharge of pus. Pain, however, is the predominating symptom, and even in the chronic cases it is present, caused by the pressure of the pent-up pus. The pain varies in intensity from the severe, radiating, lancinating type to that of the dull, pressure-like sensation known as "brow ague." It is located chiefly in the supraorbital region, the forehead and the top of the head, and is limited to one side. It is often of a neuralgic character, and is usually worse upon arising in the morning. As the day advances it gradually disappears and the patient is comparatively free from pain the latter part of the day and during the night. This Hajek explains upon mechanical grounds; the lying position of the patient in sleep brings the natural exit for the secretions on a higher level and so causes pus retention. In the erect position drainage from the frontal sinus is favored and the pus slowly finds an exit into the middle meatus through the natural channel, with abatement of the frontal pain and headache.

The eyeballs occasionally become tender and painful. Tenderness either upon pressure or percussion upon the anterior wall, and more so upon the supraorbital plate, is a common symptom. In making pressure upon the supraorbital plate the thumb should be inserted deeply. This symptom is occasionally accompanied by nausea and vomiting. The flow of pus is usually yellowish at first; later it becomes lighter in color. It is generally constant unless the nasofrontal duct is temporarily occluded, and it is often extremely offensive. Increased nasal secretion, purulent or mucopurulent, is

observed in all cases. Aprosexia, anosmia, eczema of the nasal vestibule and occlusion are other discomforts complained of by these patients.

Orbital cellulitis is sometimes seen, and, more rarely periosteal abscess and perforation of the sinus wall. Whenever the nasofrontal duct remains occluded for a considerable period, an accumulation of pus results, which induces pressure symptoms, the chief of which are pain, erosions of the lining mucosa, necrosis of the sinus walls, or external deformity, often with more or less displacement of the eyeball. The latter symptom may be accompanied with diplopia or amaurosis.

In the cases where the severity of the infection or continuance of pressure gives rise to erosions, ulcerations or necrosis of the walls, an extensive infection usually ensues. The perforations occur through the anterior or outer wall, through the *pars orbitalis* or through the floor of the sinus, thus producing troublesome external discharge and considerable external deformity, including orbital cellulitis and displacement of the eyeball, with or without

Fig. 380.—Killian's frontal sinus cannula.

diplopia or amaurosis. But far more serious consequences arise when the posterior wall is the seat of a necrotic lesion, which permits an invasion of infection into the cranial cavity, with a subsequent development of either purulent meningitis or brain abscess.

The examination of the nares is conducted in precisely the same manner as for disease of the maxillary antrum (see Chapter XXXVII), and it is often necessary to eliminate the anterior ethmoidal cells by operation in order to determine fully whether the frontal sinus is the seat of disease.

Diagnosis.—Purulent frontal sinusitis is almost invariably accompanied by a similar invasion of at least the anterior ethmoidal cells.

The history of the case furnishes some very important data upon which to base a diagnosis of empyema of the frontal sinus. Thus the characteristic supraorbital, frontal and parietal pain, the flow of pus into the middle meatus of the nose, the tenderness on pressure and percussion over the supraorbital and frontal walls, and the external deformity when present, furnish presumptive evidence of frontal sinus disease, especially in cases wherein disease of the ethmoidal and maxillary sinuses can be excluded. The demonstration of maggots within the nasal cavities should always direct the observer's attention to the frontal sinuses. In a limited proportion of cases it is possible to insert a bent probe (Fig. 381) into the frontal sinus through the nasofrontal duct and observe a pus flow

upon its withdrawal, or to introduce a cannula (Fig. 380) and wash out the secretion (Fig. 381). The latter procedure is greatly facilitated by a preliminary removal of the anterior third of the middle turbinal and the anterior ethmoidal cells. A diagnosis should never be based on pain over the frontal alone, inasmuch as this symptom so frequently accompanies affections of the sphenoidal and ethmoidal cavities that it is not characteristic for any of the conditions.

Transillumination (Fig. 382) is less satisfactory in determining disease of the frontal sinus than of the maxillary antrum, inasmuch as these sinuses are so often unequally developed, varying in size

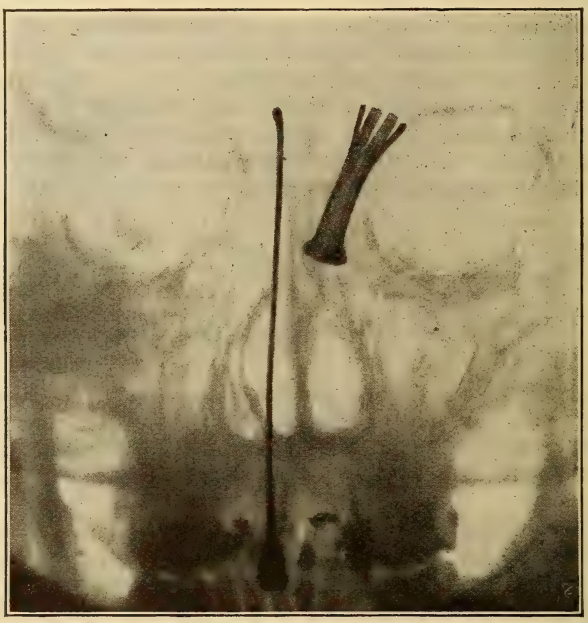

Fig. 381.—Intranasal drainage of the frontal sinus. From retouched negative showing drainage tube in position in the left frontal sinus, and cannula in position in the right frontal sinus. (*Ingals*, with permission.)

and conformity. Thus a dark area upon the affected side may indicate either the presence of secretion in the sinus, or an extremely small sinus may account for the phenomena. If possible the transillumination should be supplemented by a skiagraph.

Skiagraphy of the Accessory Sinuses of the Nose.—Skiagraphy of the accessory sinuses of the nose was first advocated by Killian, but it has been perfected in America, mechanically by Caldwell and clinically by Coakley.

According to Caldwell,[1] radiographs of the nasal accessory

[1] "Skiagraphy of the Sinuses of the Nose." American Quarterly Roentgenology, January, 1907. "Further Observations on the Roentgen-ray Examination of the Accessory Nasal Sinuses," Transactions of the American Laryngological, Rhinological and Otological Society, 1908.



Fig. 382.—Transillumination of the right frontal sinus.

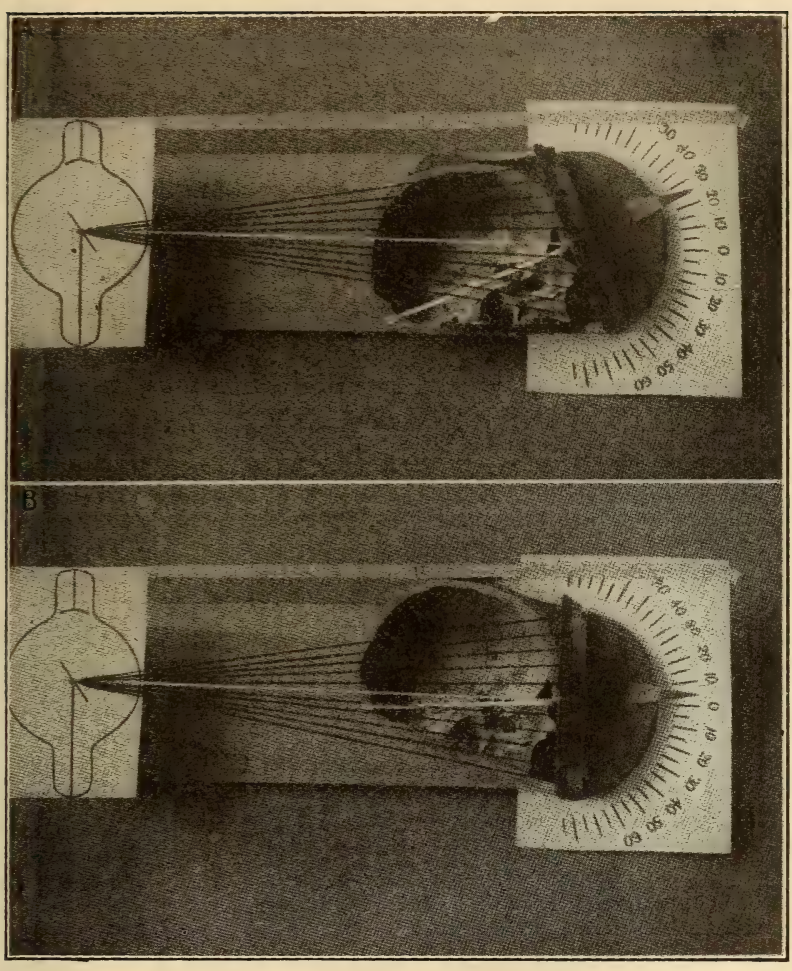

Fig. 383.—Two photographs of a model constructed for showing the effects of changing the position of the tube with reference to the skull. The direction of the rays in mesial plane is shown by stretched elastic cords passing from a point representing the target of tube to a bar placed in front of face and representing a line in the middle of plate. The principal ray is represented by a cord of lighter color than the others, and the basal plane is shown by a strip of tape fastened to the skull at its base. In *A*, the principal angle is approximately 25°, and it will be seen that the rays passing through frontal sinus are not obstructed by irregular parts of the base of skull. In *B*, the principal angle is too small (about 5°). In this position the shadows of parts of base of skull would be superimposed upon those of the sinuses. (*Caldwell*, with permission.)

sinuses require accurate calculations of the measurements of the skull, the best appliances obtainable, and especially to have tubes of high penetration (about nine or ten of the Benoist scale).

The plates should be correspondingly "fast," inasmuch as under the most favorable circumstances the tubes must be subjected to great strain in order to produce a good skiagraph of the accessory sinuses.

Furthermore every minute detail regarding technique must be observed—the angle of direction of the rays, the position of the head, the distance of the target of the tube from the head, and the length of the exposure are among the more important requirements.

Finally, the safety of the patient must be considered. He recommends that the target of the tube be placed at a distance of about 18 inches from the patient's head, and about twenty seconds as the usual time of exposure for the anteroposterior projection, and about ten seconds for the transverse projection. In the accompanying illustration (Fig. 383) both a correct and incorrect angle of projection are shown. The chief purpose of the transverse projection (Fig. 387) is to portray the depth of the frontal sinus for surgical purposes, but it often aids in interpreting the anteroposterior projection.

He deprecates the employment of the terms "X-ray photograph," inasmuch as the skiagraph projections do not portray an object as the eye would see it, and at best is but a composite shadow of the objects which intervene between the source of the rays and the photographic plate.

From the above comments it becomes apparent that Roentgen-ray specialists only are capable of producing reliable skiagraphs of the nasal accessory sinuses. From a pathological standpoint the skiagraphic plates are interpreted as follows: Upon examining a negative the outline of a healthy sinus is distinct, clearly defined, its septa are visible and its entire area is dark. In contradistinction the outlines of a diseased sinus are ill-defined, with a light, shaded cloudy area. Photographic prints do not reveal the full details which are protrayed in the original negatives. By placing the negative in a shadow box in a dark room the details are best revealed.

A good skiagraph of the frontal sinuses, the ethmoidal labyrinths and the maxillary sinuses is of inestimable diagnostic value. The skiagraph serves a double purpose, particularly in the frontal sinuses, inasmuch as the anteroposterior projection determines the probable pathological condition (Fig. 384) and the height, breadth and comparative size of both cavities and their septa (Fig. 385), while the lateral projection outlines their depth and height. Thus in Fig. 386 asymmetrical frontal sinuses are shown. In Fig. 387, a lateral view, the depth of the frontal sinus is plainly seen. Small asymmetrical frontal sinuses are shown in Fig. 388. In Fig. 389 the skiagraph shows an absence of both frontal sinuses. Fig. 390 illustrates slightly asymmetrical frontal sinuses, and the left frontal sinus, maxillary antrum and ethmoidal cells contain fluid.

RIGHT LEFT

Fig. 384.—The cloudy appearance shown in right frontal sinus, ethmoidal cells and maxillary antrum indicates empyema of these cavities. In contradistinction the clearness of the opposite sinuses indicates the healthy condition of these cavities. (From collection of the Manhattan Eye, Ear and Throat Hospital.)

RIGHT LEFT

Fig. 385.—The skiagraph shows nearly symmetrical frontal sinuses containing numerous septa. (From collection of the Manhattan Eye, Ear and Throat Hospital.)

Fig. 386.—The skiagraph shows a very large right and small left frontal sinus, both containing septa. (From collection of the Manhattan Eye, Ear and Throat Hospital.)

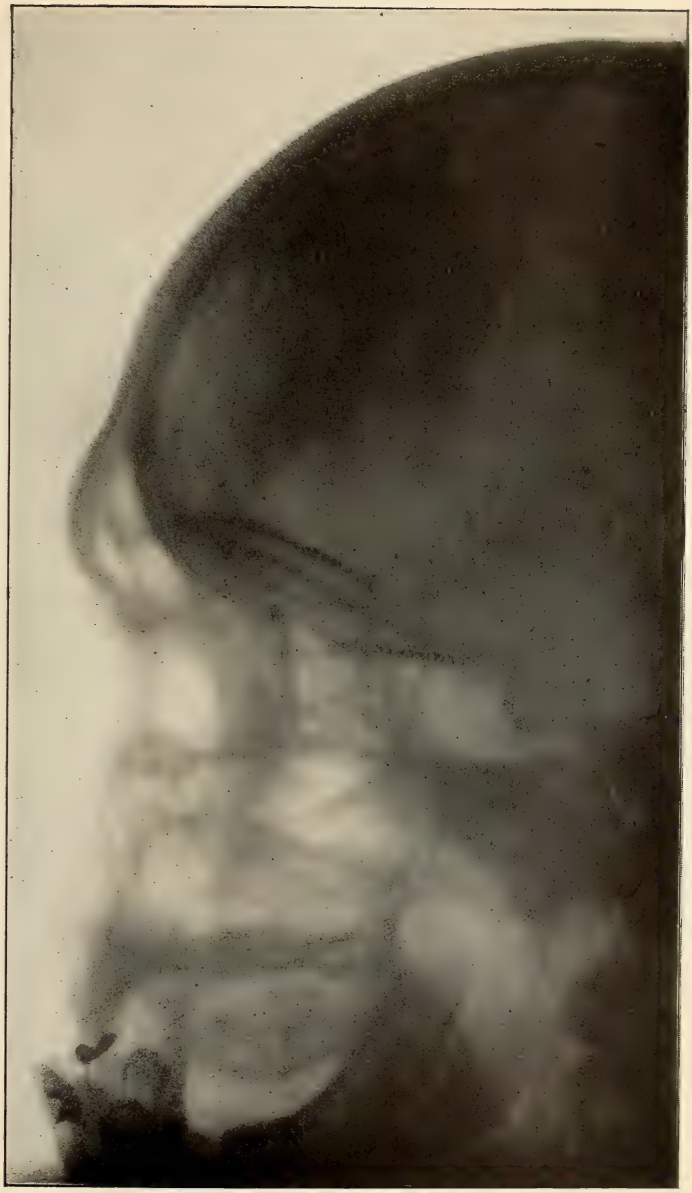

Fig. 387.—Lateral projection, showing the depth of the frontal sinuses. (From the author's collection.)

RIGHT LEFT

Fig. 388.—The skiagraph shows small asymmetrical frontal sinuses. (From collection of the Manhattan Eye, Ear and Throat Hospital.)

Fig. 389.—Total absence of the frontal sinuses. (From collection of the Manhattan Eye, Ear and Throat Hospital.)

RIGHT LEFT

Fig. 390.—The skiagraph shows slightly asymmetrical sinuses with empyema of the left frontal sinus, ethmoidal cells and maxillary antrum. (From collection of the Manhattan Eye, Ear and Throat Hospital.)

Treatment.—The treatment will be considered later, in conjunction with that of the third or necrotic form.

Periostitis and Necrosis.

While a periostitis of the frontal sinus usually is due to traumatism, necrosis of the frontal sinus walls may result either from traumatism or from extension of the pathological process from within. In rare instances a traumatism may induce a periostitis of the sinus walls which eventuates in necrosis. Syphilitic, tuberculous and diabetic subjects are more liable to necrosis.

Prolonged pressure from retention of the secretions as a result of occlusion of the *ostium* is a common cause of necrosis of the sinus walls. Necrosis involving the anterior wall, the orbital plate or floor, or some portion of the nasofrontal duct produces external swelling, periostitis, and eventually the formation of a fistula, which provides a means for the escape of the retained pus. Should the pressure be sufficient to displace the posterior wall of the sinus, obscure cerebral symptoms of meningitis or brain abscess ensue.

Diagnosis.—In the earlier stages the diagnosis may be somewhat delayed on account of the difficulties encountered in probing the interior of the cavity. After an external fistula has formed, simple probing will suffice to detect necrotic bone areas.

Prognosis.—While the mild attacks of frontal sinusitis tend to spontaneous resolution, especially when given the benefit of proper local medication, the more severe types are prone to persist indefinitely unless terminated by operative procedures.

The necrotic variety, especially when involving the posterior wall of the sinus, is grave and often terminates fatally.

Treatment.—(*a*) Of acute purulent frontal sinusitis. The measures heretofore advised for the treatment of the catarrhal form of the affection should be employed during the early stages of acute purulent frontal sinusitis, and such internal medication prescribed as the individual case may require for the relief of the underlying inflammatory process. A large proportion of all acute cases require no further treatment and recover in from two to seven days. These favorable results ensue generally in cases where drainage is not impeded by obstruction of the nasofrontal duct. Furthermore it is possible to effect a final cure, even when drainage temporarily is obtainable only by the employment of sprays and applications of adrenalin and cocaine.

When the pain is severe it becomes imperative to give temporary relief by administering opiates. Whenever these measures fail to relieve the pain and terminate the discharge, other procedures must be employed for the purpose of procuring more satisfactory drainage. If it is possible to insert a cannula into the nasofrontal duct, the sinus should be irrigated. The douching of the sinus may serve a double purpose, that of irrigation and antiphlogistic treatment. For simple irrigation warm physiological saline solution, approximately 1 dram of salt in a pint of warm water, is

sufficient. After applying cocaine and adrenalin to the tissues surrounding the ostium, the frontal sinus cannula should be introduced (Fig. 381). The solution is gently forced into the sinus by means of a piston syringe. Previous to irrigating the sinus all retained secretions should be removed from the nasal cavity. A reappearance of pus immediately after irrigation of the sinus is abundant evidence that the douching has been effective. The entrance of fluid into the frontal sinus produces an immediate sensation of fullness and pain in the supraorbital region. The return flow is immediate unless the cannula completely blocks the lumen of the duct, in which event the contents of the sinus may be withdrawn through the cannula, by means of suction.

Irrigation of the sinus is usually followed by a copious discharge of pus, mixed with the remains of the solution which has been employed, and it is quite common for comparatively severe attacks to subside under this form of treatment. Furthermore intelligent patients often are able to acquire the necessary skill to pass the cannula and irrigate their own sinuses.

Unfortunately, in many patients who suffer from acute empyema of the frontal sinus it is impossible to insert a probe or cannula on account of obstructions in the form of enlargement of the anterior end of the middle turbinal, swollen and edematous nasal mucosa, polypi which surround and block the nasofrontal duct, or an unusually large bulla ethmoidalis. Under these circumstances it becomes imperative to resort to surgical measures. These are fully outlined in the remarks upon the intranasal surgical treatment of chronic empyema of the frontal sinus, in the following paragraphs:—

Treatment of Chronic Empyema.—Two general methods are employed for the treatment of chronic empyema of the frontal sinus: (For description of suction treatment see page 577.)

(*a*) The intranasal treatment (local and surgical);

(*b*) Treatment by external (radical) operation.

The merits of both methods depend upon the duration and extent of the disease, the size of the sinus and the number of septa which it contains, and the presence or absence of similar involvement of the neighboring sinuses.

A sinus of moderate size which is free from septa, and without extensive pathological changes in the lining mucosa or osseous walls, is usually amenable to treatment by the intranasal route. This especially is true in cases of empyema of the frontal sinus which are complicated by purulent ethmoiditis, wherein by a preliminary excavation of the anterior ethmoidal cells the obstruction to the nasofrontal duct is overcome and access to the frontal sinus through its ostium is provided.

On the other hand, when deep-seated pathological changes have taken place in the lining mucosa or osseous walls of a sinus of large size and deep anteroposterior dimensions, and which contains one or more septa (Fig. 385), the more radical external operative procedures become necessary.

(*a*) The Intranasal Treatment.—The intranasal treatment of chronic empyema of the frontal sinus should be conducted about as follows:—

1. Resort temporarily to the simple measures heretofore outlined for acute frontal sinusitis, hoping thereby to establish drainage and a final cure.

2. When possible to insert a cannula (Fig. 381), irrigate the frontal sinus two or three times daily.

3. Whenever the ethmoidal labyrinth is the seat of a complicating purulent inflammation, the middle turbinal should be removed (Fig. 353) and the anterior ethmoidal cells excavated (see Chapter XXXIX), after which the daily irrigations of the frontal sinus are continued.

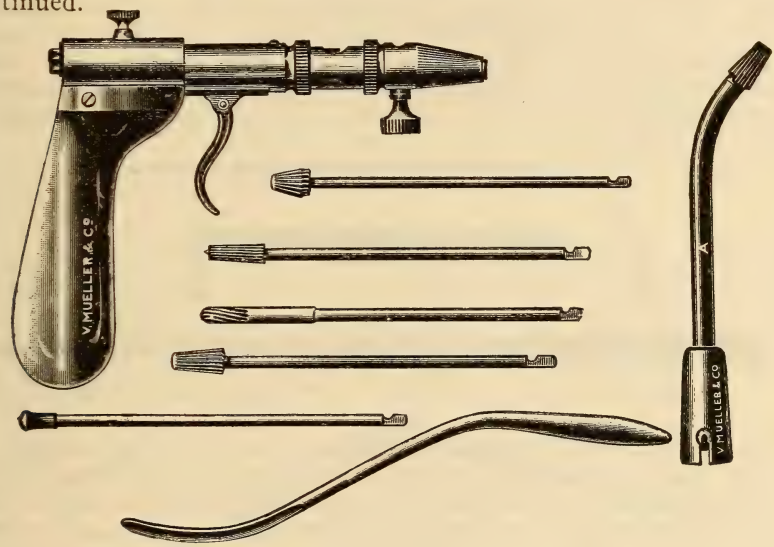

Fig. 391.—Halle's frontal sinus burrs and handle.

4. If a polypus protrudes from the exit of the nasofrontal duct, it should be seized and withdrawn.

5. It is feasible to curet (gently) the nasofrontal duct, providing it is easy of access, and even to enlarge it by curetting its anterior wall.

6. Surgical enlargement of the nasofrontal duct by the removal of surrounding bone.

Surgical enlargement of the nasofrontal duct throughout its entire course promotes drainage, permits a certain amount of curettage of the interior of the sinus, and renders it fairly accessible to lavage. Unfortunately, the procedure is attended by certain dangers, enumerated as follows:—

(*a*) The sinus may be absent, in which event the drill or trephine might penetrate the meninges.

(*b*) By wounding the olfactory fissure, which lies toward the median line, a pathway would be opened for infection to invade the meninges

(*c*) Injury to the inner plate of the frontal bone.

Halle employs a series of burrs and drills (Fig. 391) and by cutting forward removes a portion of the floor of the sinus. The posterior wall of the nasofrontal duct and the inner table of the frontal bone are guarded by a grooved protector which is previously introduced. The mucous membrane of the sinus is thus, to a considerable extent, exposed to view and may be subjected to further surgical treatment.

An ingenious method for enlarging the nasofrontal duct has been devised by Ingals,[2] by which a pilot probe is first passed through the duct into the sinus and left *in situ,* after which a hollow burr attached to a flexible sheath (Fig. 392) is slipped over it up to the nasal opening. The handle is then attached to the chuck of a dental engine or motor, by which means the burr is gradually forced along the retaining probe until it burrows its way into the sinus. The entire instrument is then withdrawn, and by means of a packer absorbent gauze medicated with 95 per cent. carbolic acid is introduced



Fig. 392.—Ingals's pilot burr. *A*, pilot; *B*, burr; *C*, shield.

through the enlarged canal and drawn backward, cauterizing its entire length. A permanent gold irrigating tube, the sinus end of which has received several longitudinal slits, producing a flare which is temporarily maintained at the size of the tube by means of a gelatin capsule (Fig. 393), is then introduced into the sinus. The gelatin soon dissolves and the free ends of the cannula spread and thus hold it in place. This method obviates some of the dangers and in favorable cases may effect a cure, without external deformity.

(*b*) Treatment by External (Radical) Operation.—Objects to be attained: Briefly stated the purpose of the external (radical) operation upon the frontal sinus is to eradicate the diseased mucosa which lines its walls, to excavate all necrosis of its bony walls and surrounding structures, to remove such portions of the anterior and inferior walls as may be necessary to carry out the operative technique and to insure drainage, and finally to obliterate the entire cavity, including its infundibulum, in the hope that by so doing the ramifications of the disease will be terminated once and for all.

Various methods of external operation have been devised. Owing to the marked variations and abnormalities in the frontal sinuses, both

[2] Transactions of the American Laryngological, Rhinological and Otological Society, 1905, p. 183.

as to size, shape and the presence or absence of septa, and to the variable character and extent of the disease, it is obvious that any external operative procedure must be the subject of accurate selection, based upon wise judgment and careful orientation regarding the anatomical relations in each individual case.

Indications.—External operative interference is indicated in acute purulent frontal sinusitis whenever the usual intranasal methods have



Fig. 393.—Ingals's frontal sinus drainage tube. Actual size. At the top is shown the tube open; at the extreme left, part of a capsule which is to cover it for introduction; between this and the tube the actual size of the tube, and at the right, the size and shape of the lower end of the tube. Below, the tube is shown with the capsule applied ready for introduction.

failed to check the pus formation, or the inflammatory conditions. Such conditions are evidenced by continued pain, failure to establish free drainage through the nasofrontal duct, external swelling, meningeal irritation, diplopia, or severe vertigo, and in chronic cases whenever curettage of accompanying diseased ethmoid cells, removal of polypi and irrigation have failed.

Fig. 394.—Killian's packing forceps.

In detail the indications for the external (radical) operation upon the frontal sinus are:—

(*a*) When associated with chronic purulent inflammation of the anterior ethmoidal cells, or of the entire group of accessory sinuses (pansinusitis), in which degenerative changes in the lining mucosa have taken place.

(*b*) When permanent remission of symptoms does not follow the intranasal procedures enumerated in the preceding paragraphs, especially the removal of the anterior end of the middle turbinal and irrigation of the sinus.

(*c*) When the skiagraph reveals not only empyema, but sinuses of large dimensions with multiple septa.

(*d*) When necrosis of the walls of the sinus and fistula are manifest.

(*e*) When the conformity of the nose renders intranasal treatment difficult or impossible, or when anomalies of drainage are suspected, *e.g.*, drainage of the frontal sinus into the maxillary antrum.

Until about twelve years ago the radical operative treatment of purulent frontal sinusitis was resorted to only in the presence of dangerous complications or *fistulæ*. The operative era was inaugurated in 1893 by Luc, Kuhnt, Jansen, Killian, and others.

Fig. 395.—Killian's operation. First step, showing line of initial incision with slight transverse cutaneous cuts. The initial incision is made through the soft structure to the periosteum. (*Harmon Smith*, with permission.)

The Luc Operation (*the Ogston-Luc procedure*).—In this operation the primary incision extends along the supraorbital ridge, over its inner one-third, comencing about 1 centimeter from the median line. After retracting the periosteum the anterior wall of the sinus is partially resected. Through this opening the cavity of the sinus is scraped and free communication established into the nasal cavity, through the nasofrontal duct. The entire external wound is then closed by sutures.

The Kuhnt Operation.—In Kuhnt's operation the anterior wall of the sinus is entirely removed, a vertical incision being carried upward from the mesial end of the primary incision along the eyebrow. The entire membranous lining and all bony septa are then removed from the

sinus. The anterior ethmoidal cells also are removed when diseased. Kuhnt personally advised that the external wound should not be closed, and that a wide communication with the nasal cavity as a septic centre should be avoided, providing the ethmoidal labyrinth is healthy. Luc and Hajek modified the operation by introducing a drainage tube from the sinus cavity into the nose and closing the external wound, thus securing far better cosmetic results. Lermoyez and Tilley follow practically the same procedure.

The Killian Operation.—The Killian operation is favored by a

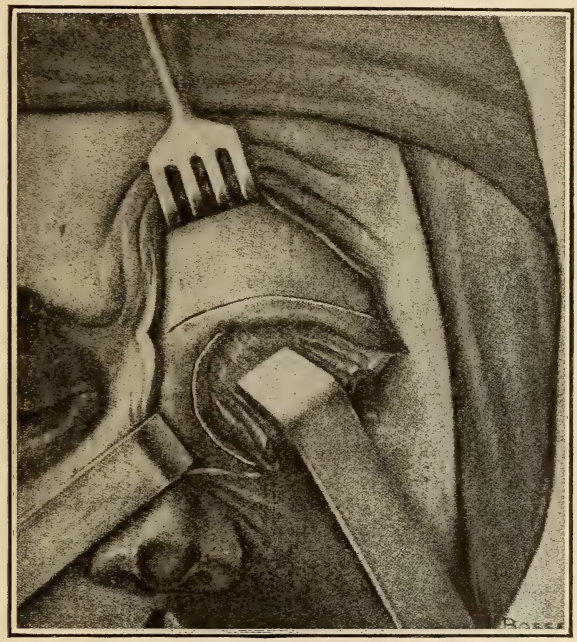

Fig. 396.—Killian's operation. Second step showing soft tissues retracted, and lines of periosteal incisions. (*Harmon Smith*, with permission.)

majority of rhinologists. It is somewhat complicated in technique, but the excellent cosmetic results attained, the wide-open drainage into the nasal cavity and the admirable opportunity which thereby is afforded to excavate the ethmoidal labyrinth and the sphenoidal sinus are strong arguments in its favor.

Technique.—The steps of the operation are as follows (Harmon Smith's description of the technique is herein adopted in part) :—

The patient is prepared in accordance with approved surgical requirements. The operation is performed under general anesthesia. At the time of operation, as soon as the anesthetic has been administered, the operative field should again be carefully scrubbed with ether solution, the eyelids covered with pledgets of sterile gauze, a

rubber cap so placed upon the head as to include all the hair, and this in turn covered by a moist bichlorid towel. If possible there should be two assistants besides the anesthetizer and nurses.

The eyebrow is not shaved, but, if the brow is "heavy" and the hairs long, they may be clipped. Three or four long tampons of absorbent cotton are then introduced deeply into the nasal cavity of the side to be operated upon, by means of the Killian forceps (Fig. 394).

The incision which divides the skin, subcutaneous and muscular tissues, but *not the periosteum,* is then extended from the outer third of the orbit, through the centre of the hair line to the root of the

Fig. 397.—The Killian protector.

nose and thence curved sharply downward and slightly outward to a point slightly below the inferior margin of the nasal bone (Fig. 395).

The line of incision is marked by several slight crosscuts for the purpose of perfect coaptation of the wound margins upon the completion of the operation. The soft tissues are then retracted from the periosteum to prepare the way for the periosteal incisions.

The Periosteal Incisions.—1. The periosteum is divided transversely, from the median line of the forehead to the outer extremity of the wound, parallel to but in a plane about 6 millimeters above the supraorbital ridge.

2. A second periosteal incision is commenced at a point underneath the supraorbital ridge and just internal to the attachment of the pulley

Fig. 398.—Killian's V-shaped chisel.

of the superior oblique muscle, and is extended downward along the line of the primary incision (Fig. 396). The periosteum is elevated upward from the transverse incision until the anterior wall of the sinus is fully exposed, and downward from the lower incision until the inner third of the supraorbital wall (floor of the sinus) is denuded. Meantime the eye should be protected by means of the Killian protector (Fig. 397).

This leaves a strip of periosteum undetached from the bridge of bone which is to serve the purpose of maintaining the contour of the parts.

3. The retraction of the periosteum from the supraorbital region gives rise to severe hemorrhage, and this space should be packed with gauze which has been saturated with adrenalin solution 1 : 5000, pending the removal of the anterior wall of the sinus.

4. Enter the anterior wall of the sinus by means of gouge and

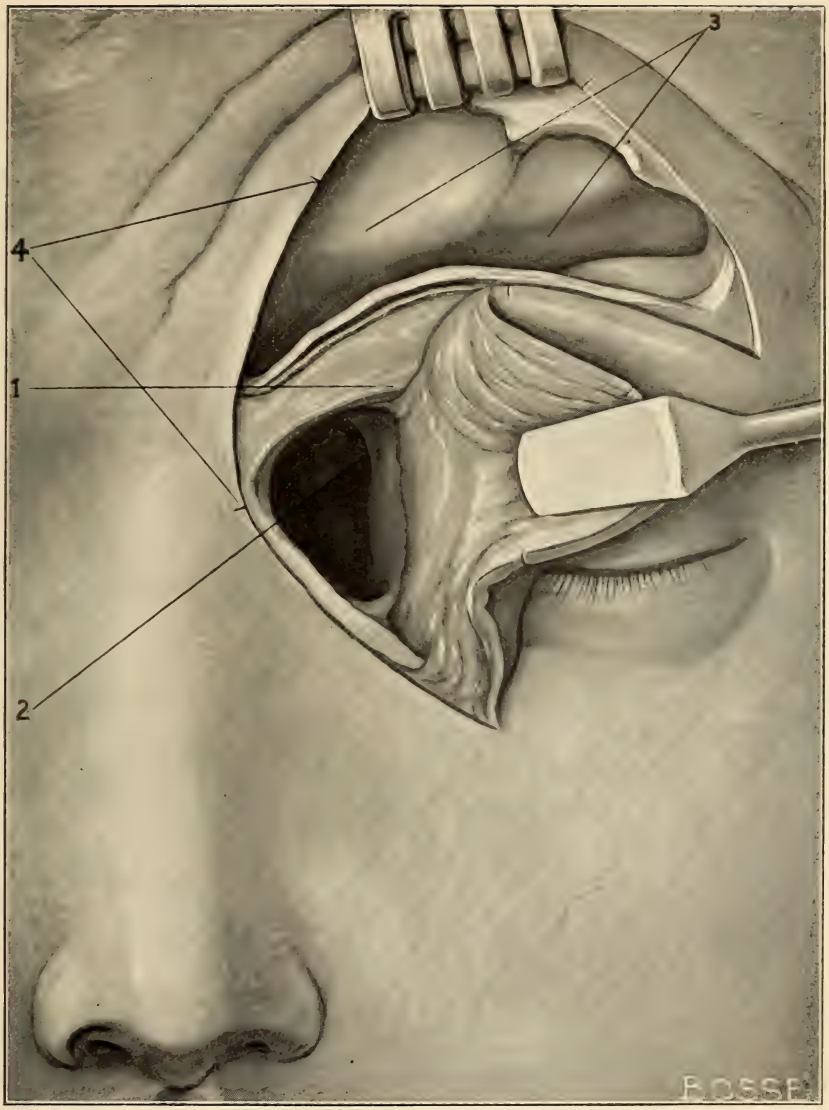

Fig. 399.—Killian's operation, third step. 1, The bridge of bone with its periosteal covering left in place for upholding the soft tissues upon closure of the wound. 2, The entrance through the os planum into the ethmoidal tract extending back into the sphenoid. 3, The size of the sinus in this case with its irregular outlines and deep sulci. 4, The little nicks in the initial incision which must be approximated in closing the wounds to preserve the integrity of the parts. *(Harmon Smith,* with permission.)

mallet, just above the bridge of bone lying between the periosteal incisions.

5. From this point, using the Killian V-shaped chisel (Fig. 398), excavate a groove of bone, following transversely from the primary opening along the line of the first periosteal incision to the outer angle of the wound. Remove a large section of the anterior wall of the sinus with rongeur forceps.

During the removal of the bone of the outer (anterior) wall it is unnecessary to break through the underlying mucosa. After sufficient bone has been removed, an incision should be made through the mucous

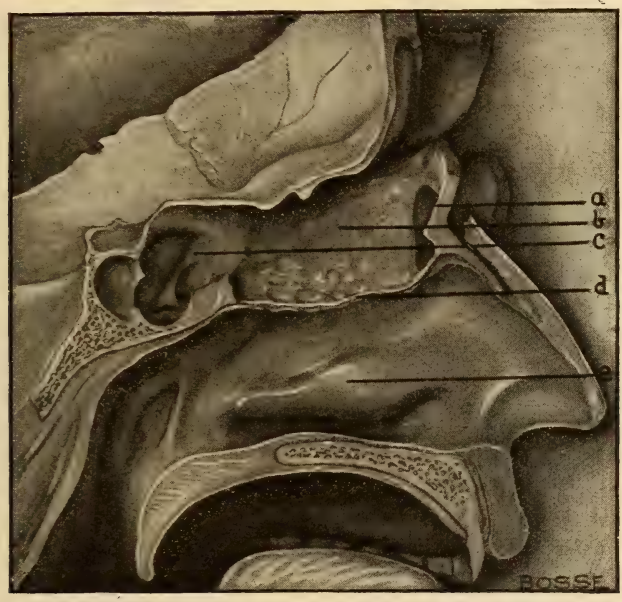

Fig. 400.—Killian's operation. Lateral appearance after dividing the head. *a,* Entrance through os planum and orbit into the ethmoidal tract. *b,* The ethmoidal tract. *c,* Sphenoidal sinus. *d,* Line of attachment of middle turbinate. *e,* Inferior turbinate. *(Harmon Smith,* with permission.)

membrane, and its thickness and general condition noted. It is not unusual to find diseased, edematous mucous membrane of a thickness of 1 centimeter. Pus in large quantities is not always present, but the space may be partially or wholly occupied by thickened membrane and edematous polypi.

6. Having probed the sinus to verify the skiagraphic estimate of its extent, the remaining portion of the outer wall should be removed with rongeur forceps and chisel.

7. Remove the entire contents of the sinus, including the lining mucosa, with a sharp curet, and break down all septa and smooth off all rough edges of bone (Fig. 399).

8. Return to the lower portion of the wound, withdraw the gauze packing, and then remove the inferior (supraorbital) wall of the sinus, meanwhile guarding the bridge of bone which is to be left *in situ.* This opening should be extended toward the nasal bridge and downward a considerable distance to facilitate further operative procedures. The latter requires the removal of the frontal process of the superior maxillary and the entire sinus floor (Fig. 399).

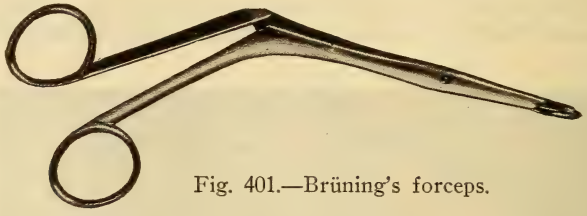

Fig. 401.—Brüning's forceps.

9. When the ethmoidal labyrinth is diseased the entire system of cells should be removed, one after another, including the middle turbinal (Fig. 400). In this procedure all careless manipulation of instruments should be avoided, especially when excavating in the region of the cribriform plate. The evulsion forceps (Fig. 401) is a remarkably effective instrument for removing the diseased ethmoidal cells and their retained polypi, and it is proportionately a safe instrument.

Fig. 402.—Grünwald's sphenoidal forceps.

Likewise remove the anterior wall of the sphenoidal sinus and curet its cavity (Fig. 400). The Grünwald bone forceps (Fig. 402) are most serviceable and effective for biting away the bony anterior wall. Complete the operation by carefully removing any remaining membranous lining of the nasofrontal duct. In case the inner (visceral) cranial table is eroded at any point, remove the necrosed bone and expose a considerable area of dura.

10. Irrigate the wound with a warm physiological salt solution, wipe the surfaces dry, and pack the wound lightly from the outer angle forward, with one strip of gauze, and push its remaining end downward through the frontonasal opening into the vestibule of the nose. Likewise pack the ethmoidal and sphenoidal regions. Close the external wound with sutures, which should include the perios-

teum, particularly about the inner angle of the eye. In closing the wound, advantage should be taken of the small cross incisions (Fig. 395) to insure perfect coaptation of the soft tissues.

Killian employs fine-wire sutures with excellent results. They are objectionable on account of the severe pain which is induced by their removal. The author commends silkworm gut for closing the external wound.

Before applying the external dressings the fatty tissues of the orbit should be carefully pressed upward into the sinus cavity. Pads of gauze are then placed over the closed eye, and loose gauze over the

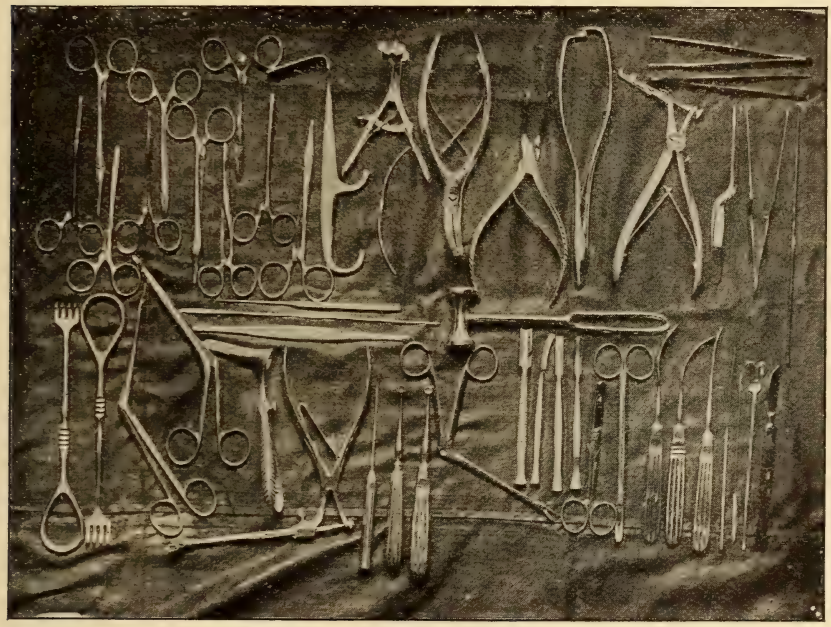

Fig. 403.—A complete set of instruments for operating upon the nasal accessory sinuses.

entire operative field, and a firm bandage applied. A complete set of instruments for performing the operation upon the nasal accessory sinuses is shown in Fig. 403.

After-treatment.—The patient should lie on the healthy side for the most part, and blowing of the nose should be forbidden. He must aspirate the secretions backward into the pharynx, and thus avoid inflation of the frontal sinus. Change the outer dressings daily and the inner gauze packing on the second or third day, and daily thereafter. Remove the sutures in from the fourth to the seventh day.

As a rule, irrigation should be dispensed with. The care of the internal wound may extend over a period of from one to three months. Exuberant granulations must be reduced by applications of nitrate of silver or fused chromic acid. The deformity gradually becomes less

noticeable as the sinus cavity becomes filled in with granulations and the orbital fat.

Finally, if a disfiguring depression results, it may be filled in by subcutaneous injections of paraffin.

Killian claims that this operation, when skillfully performed, results in but little external deformity, requires but a short sojourn in the hospital, and is adaptable to the majority of cases. In actual practice this claim is well founded.

Furthermore, the Killian operation is particularly applicable in cases which are complicated by ethmoidal and sphenoidal disease (Fig.

Fig. 404.—Photograph showing cosmetic results of a Killian frontal sinus and antrum operation upon the left side. (Author's case.)

400). Figures 404 and 405 are photographs of two cases of unilateral pansinusitis, where the author employed the Killian operation with but slight external deformity.

The External (Radical) Operation by the Open Method.—The radical operation by the open method is advocated by many American rhinologists. In this operation the entire anterior wall of the frontal sinus is removed precisely as in the Kuhnt procedure. The mucous membrane lining the cavity of the sinus and all septa are entirely removed. A strip of gauze is drawn downward through the infundibulum into the nose and "seesawed" back and forth until the mucous membrane of the frontonasal duct is denuded; when the neighboring ethmoidal cells are diseased they are broken down and removed.

The entire denuded cavity is then packed with gauze. Drainage into the nasal cavity is avoided by packing the wound externally from below upward, thus leaving the lower portion to granulate and close off. The first packing should both fill the wound in the bone and widely separate the skin wound. The wound cavity is thus allowed to granulate and heal from the bottom in the manner usually adopted in bone operations elsewhere, notably those upon the mastoid process. The entire wound and the surrounding area are covered with sterile dressings and a bandage is applied. Thereafter the wound is dressed as an open wound. The deep dressings are changed on the sixth day, providing no untoward symptoms arise. The outer dressings should be changed daily.

The granulations finally fill the wound cavity in about five or six weeks. In the meantime its communication with the nose will have terminated by the growth of granulations from below. On account of the scar, which is as a rule adherent, the deformity following this operation is more conspicuous than in that from the Killian operation. The deformity may be partially overcome by resecting the scar at a subsequent operation, or by a subcutaneous injection of paraffin.



Fig. 405.—Cosmetic results of a Killian frontal sinus operation upon the left side. (Author's case.)

Difficulties and Dangers Associated with the External (Radical) Operation upon the Frontal Sinus—1. It is difficult to obtain the patient's consent to so formidable a procedure, which may possibly disfigure the face. In the author's case hereinafter reported it was only after repeated warnings, covering a period of several months, that the patient finally submitted to operation.

2. It cannot truthfully be affirmed that the operation invariably is without danger, inasmuch as fatalities occur which are in no wise due to faulty technique. Tilly, St. Clair Thomson, Milligan, Lack, Turner and others of like skill and experience have reported fatal cases. It is to be regretted that so few operators publish the reports of their fatalities, five of which were reported by Luc out of his first thirty operations. The majority of fatal cases are those wherein the infection already has invaded the meninges, with resultant local or general meningeal inflammation, or brain abscess. One fatal case in the author's practice resulted from a sudden extension of a brain abscess which undoubtedly had existed, unaccompanied by serious symptoms, for some months.

For five months this patient repeatedly had been urged to submit to an external (radical) operation upon both frontal sinuses, on account of the apparent extensive changes which had taken place in the lining mucosa of these cavities. At times he had suffered from frontal headache, which was attributed to the pressure of the masses of polypi in his sinuses, and to exacerbations of the inflammation. During this

period his anterior ethmoidal cells had been excavated through the nares. The diagnosis was verified by a skiagraph. He finally gave his consent and the external operation was performed upon both sinuses. They were extensively diseased. The after-treatment was by the open method.

Several days after the operation the patient began to complain of headache, which was greatest in the frontal and occipital regions. He had one slight chill but no acceleration of temperature, and no choked disk or other ocular symptoms. His attending physician reported that a large amount of pus was flowing from his nose and considerable into his sinus wound. His weakness continued, the pain increased, and finally a swelling appeared over the right frontal region, extending 2½ inches above the eyebrow. Three days later he had become partially unconscious, his temperature was 101¾°, the pulse 106 and the respiration 28. At this time it was impossible to make a satisfactory examination of the fundi. There was slight muscular twitching and some rigidity of the neck. There was an enormous swelling over the frontal bone, toward the right side.

Second Operation.—The old scars were reopened and the scalp thrown upward, uncovering the entire lower portion of the frontal bone, the outer table of which was necrotic. At a point about one inch above the upper border of the frontal sinus there were two small fistulous openings communicating with the cranial cavity, from which there was a flow of pus apparently under pressure. The surrounding necrosed bone was quickly curetted and the exposed dura was covered with granulations, except at the point from which the pus made its exit. Upon enlarging the opening in the dura a large abscess was found in the frontal lobe. The abscess was treated in the usual manner, but the patient never regained consciousness and died two days later. The temperature following operation ranged between 104° and 106°. Had this patient consented to the operation four months earlier his life might have been saved.

3. Meningitis may be present either as a recognized state or in its incipient stage, even at the time of the operation, in which event the patient's life is jeopardized not by the operation, but by the accompanying meningeal involvement.

4. If, during the operation, the dura is exposed, either accidentally or by intent for the purpose of removing necrosed bone, the exposure should be enlarged sufficiently to permit free drainage from its surface. Otherwise there is danger from infection.

5. Finally, the lowered vitality and lack of resistance which result from the long-continued suppuration from the nasal accessory sinuses predispose to renewed infection.

CHAPTER XXXIX.

DISEASES OF THE NASAL ACCESSORY SINUSES.

(*Continued.*)

I. THE ETHMOIDAL SINUSES (ANTERIOR AND POSTERIOR ETHMOIDAL CELLS).

Anatomy.—The ethmoidal sinuses, usually described as ethmoidal cells, are practically absent at birth. They develop gradually during infancy and childhood, by a process of protrusion into the cartilaginous ethmoid (Lack). They lie within the two sides of the ethmoid bone, each set of cells having at least two subdivisions, which are termed the anterior and the posterior ethmoid cells (Figs. 363, 377 and 400). This classification is based upon their location in the ethmoid bone and upon the meatus into which they drain. The anterior ethmoidal cells, numbering from two to eight, are generally smaller than the posterior and they open into the middle meatus. The posterior ethmoidal cells, fewer in number and larger in size, are usually situated upon a plane slightly lower than the anterior, and open into the superior meatus. In general they occupy the region above and external to the middle turbinal. The orbital plate constitutes the outer boundary, and the cribriform plate the superior boundary of these cells, which rarely extend beyond the confines of the ethmoid bone. Sometimes an ethmoidal cell encroaches on the frontal sinus, when it is known as a fronto-ethmoidal cell. The cavities are asymmetrical and of irregular size and number, and together these are often spoken of as the ethmoidal labyrinths.

The separation of the ethmoidal cells from the brain is by means of thin, but rather dense bony walls, and a portion of the orbital plate is sometimes substituted by membrane. The optic nerve commonly lies in direct relation to the posterior group of ethmoidal cells (Fig. 406). A similar relationship exists between the ethmoidal cells and the remaining accessory sinuses (sphenoidal, frontal and maxillary), from which normally they are walled off by thin, bony septa. The latter readily become broken down as a result of prolonged purulent processes, and thus open up a direct pathway of infection to the neighboring sinuses. Each ethmoidal sinus as a whole varies from 2½ to 3 cm. in length and from 1 to 1½ cm. both in height and width. When healthy and but few in number each cell has a direct opening into the nasal cavity, but when diseased their septa are prone to break down, and as a result they open freely into each other.

The ethmoidal cells are lined by a mucous membrane which is much thinner and less dense in construction than that of the frontal and maxillary sinuses.

DISEASES OF THE ETHMOIDAL CELLS.

The affections of the ethmoidal cells herein described are:—

1. Acute inflammation.
2. Chronic purulent ethmoiditis.

Other lesions, particularly the neoplasms, are considered in the general chapter on Neoplasms of the Nose.

1. Acute Inflammation of the Ethmoidal Cells.

Definition.—An acute inflammatory invasion of the lining membrane of the ethmoidal cells, usually occurring as an extension

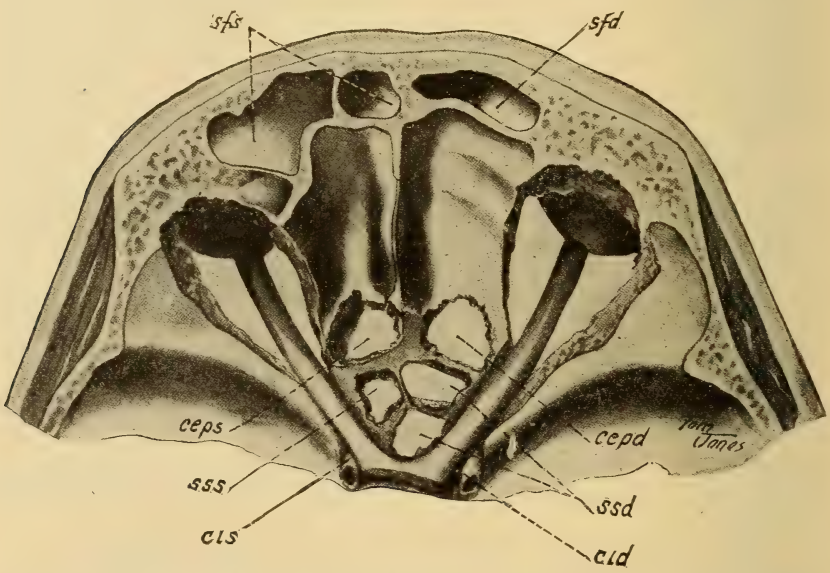

Fig. 406.—Left sphenoid (*sss*) small, not in relation with chiasm; right sphenoid (*ssd*) apparently double, on account of a ridge in relation with chiasm posteriorly; relation of posterior ethmoid cells (*ceps, cepd*) well shown at posteroexternal angle; *sfs, sfd,* frontal sinuses; *cis, cid,* internal carotid. *(Loeb,* with permission.)

from acute rhinitis, and accompanied by altered secretions, with or without retention.

Etiology.—The most common cause of acute ethmoiditis is acute rhinitis. Invasion of the ethmoidal cells is more likely to occur in cases wherein the accompanying rhinitis is the result of definite infections like the grippe, the exanthemata, typhoid fever, sepsis from intranasal operations, and tertiary syphilis. Furthermore, the ethmoidal involvement may occur by direct extension from that of a neighboring accessory sinus.

Pathology.—The pathological changes are characterized by turgescence of the mucosal lining of the cells involved, and more or less swelling and redness of the mucosa of the middle turbinal,

and a profuse outpouring of mucus, mucopurulent or purulent secretion. When retention of secretions occurs, the mucosa both within and surrounding the cells involved becomes edematous; meanwhile bulging of the cell walls and external swelling may ensue.

Symptoms.—The symptoms vary in accordance with the group of cells which are involved, the severity of the process and the degree of retention of the secretions. In its simplest form and when due to simple acute rhinitis there is a sensation of fullness between the eyes, and occasionally moderate pain in the ethmoidal region and about the nasal bones. Unless retention occurs the attack subsides with the cessation of the acute rhinitis. In cases wherein the sinus openings (ostei) become occluded as a result of inflammatory thickening, from polypi or other tumors, or as a result of intranasal obstruction (septal deflections, enlarged or deformed turbinals, etc.), the symptoms are proportionately more severe and prolonged.

The pressure of the retained secretions induces pain between the eyes, which may radiate to the orbital and frontal regions, and tenderness on pressure over the ethmoidal region. Nasal respiration becomes impeded and external swelling may ensue. During the early stages the secretion is mucoid or mucopurulent, but in severe types, especially when retention of the secretions is prolonged, it becomes purulent. In the majority of cases the pent-up secretions finally force an outlet through the normal openings of the cells, and relief immediately ensues. In others relief is obtained by appropriate treatment. But, if the disease is permitted to progress without either spontaneous recovery or relief by treatment, it may eventuate in chronic ethmoiditis.

Diagnosis.—The diagnosis of acute ethmoiditis when the disease is confined to the anterior group of cells is comparatively simple. The history, the symptoms, the swollen and inflamed appearance of the middle turbinal tissues, and the flow of secretions from the middle meatus, in the absence of positive signs of frontal sinusitis and maxillary sinusitis, is usually sufficient to establish a diagnosis.

Treatment.—Primarily the underlying acute rhinitis should receive prompt and vigorous treatment (see Chapter XXXIII), and measures should be adopted that will favor the customary free drainage of the ethmoidal cells. In case of retention of the secretions within the ethmoidal cells efforts should be made to establish drainage, and the following procedures are advised:—

After spraying the nostril with warm alkaline solution, a small amount of a solution of cocaine 4 per cent. in adrenalin 1 : 5000 should be sprayed directly upon the tissues of the middle turbinal and the lateral nasal wall of the middle meatus. After a few minutes small flattened-out tampons of absorbent cotton soaked with the same solution (Fig. 347) are gently crowded into the chink between the middle turbinal and the lateral nasal wall and allowed to remain for twenty minutes. The contraction of the swollen tissues following this procedure serves to open the ostei of the cells

and release the pent-up secretions. Several repetitions of this procedure covering varying periods, particularly in severe cases, are often necessary, both for the relief of symptoms and to establish an open drainage of the cells.

In case of obstruction of drainage resulting from polypi, enlarged middle turbinals, or deflections of the septum, it sometimes becomes necessary to resort to appropriate operative procedures in order to obtain relief. As the acute rhinitis and ethmoiditis subside, mild astringents may be applied to the mucosa of the ethmoidal regions. For this purpose an application of a 25 per cent. solution of argyrol is effective. The Douglas formula of benzoinol (see page 499) has a slightly astringent and at the same time a most soothing effect, and may be freely employed as a spray.

Local bloodletting, through a series of incisions into the mucous membrane, along the anterior and inferior surfaces of the middle turbinal and along the lateral nasal wall in the vicinity of the hiatus semilunaris, is recommended by Lake.

2. Chronic Purulent Ethmoiditis.

Definition.—This affection is characterized by a chronic inflammatory process which involves the mucosa of the ethmoidal cells, attended by a purulent discharge. When drainage is free and unimpeded the empyema is termed "open." Prolonged retention of secretion from closure of the openings of the cells is defined as "closed empyema."

Etiology.—Repeated attacks of acute ethmoiditis, superinduced both by acute and chronic rhinitis, account for a large proportion of all cases of the chronic form of the disease.

The contributing and often determining causes are:—

(*a*) Specific infections, such as influenza, measles, scarlet fever, diphtheria, and typhoid fever.

(*b*) The ravages of intranasal tertiary syphilis, and neoplasms.

(*c*) Exhaustion from disease, constitutional taint, perverted habits, bad hygienic surroundings, or overindulgence in tobacco and alcohol.

(*d*) Obstruction of the openings (ostei) of the cells from hyperplasia, edematous polypi, enlarged or cystic turbinals, or septal deflections.

(*e*) Concurrent empyema of the neighboring sinuses.

(*f*) Pathological changes in the structure of the mucosa of the cells and in their bony walls, which have resulted directly from acute attacks of purulent ethmoiditis.

Pathology.—Pathological changes in the mucoperiosteal lining of the cells, in the order of occurrence, comprise: 1, inflammatory thickening, edema and destruction of the ciliated epithelium; 2, as the hyperplasia extends to the submucosa and periosteum, edematous tumors (polypi) are prone to develop, and may protrude through the ostei of the cells; 3, in cases of closed empyema, pressure of the retained secretions may eventuate in destruction of the cell walls, and escape of purulent secretion, either into the orbit, the

nose, or the cranial cavity. It is quite common for the dividing walls between one or more cells thus to break down and form one large cell, which may become the seat of latent empyema or contain a mucocele. According to Hajek, the polypi, both within the cells and surrounding the middle turbinal, are the product of a chronic hyperplastic inflammation of the membranous covering of the ethmoid, the anatomical topography of the ethmoid bone being conducive to this edematous mucous-membrane degeneration.

The pathological changes may involve one or more cells of the anterior or the posterior group, on one or both sides of the nose.

Symptoms and Course.—Pain is not a constant symptom of chronic purulent ethmoiditis except during exacerbations. The pain is usually described as a dull, heavy sensation of pressure between the eyes, which often radiates into the frontal region. It is also experienced at the base of the skull when the posterior ethmoidal cells are involved. Tenderness on pressure is rare except during exacerbations, when it may be elicited by pressure inward and backward, at a point between the inner canthus of the eye and the nasofrontal and nasomaxillary articulations.

Pus discharge from the ethmoidal cells is the most prominent and constant symptom of this disease. Unlike the maxillary antrum, the discharge from the ethmoidal cells is more likely to be constant, and it is more profuse when the patient is in an upright position. Furthermore, there is a quick return of pus after wiping out the middle meatus. A single polypus may project from the ostium of the maxillary or the frontal sinus; but a pus discharge flowing over the surfaces of several small polypi, situated about the under surface of the middle turbinal, and the space between that body and the lateral nasal wall, is presumptive evidence of purulent involvement of one or more cells of the anterior group, which may or may not be independent of concurrent empyema of the frontal and maxillary sinuses.

The intimate relation of the outlets of the frontal and maxillary sinuses with those of the anterior ethmoidal cells renders it extremely difficult to determine the source of pus which accumulates or flows from the middle meatus external to the middle turbinal. By carefully plugging that part of the middle meatus lying above the ostium maxillare, it is sometimes possible to shut off the flow from the nasofrontal duct and the anterior ethmoidal cells, in which event, if the flow continues, it probably comes from the maxillary antrum.

It is more difficult, and often impossible, to differentiate between the flow from the nasofrontal duct and the anterior ethmoidal cells. In the former the pus usually is located high up and well forward in the hiatus semilunaris. Attempts have been made —and sometimes successfully—to shut off the opening of the hiatus semilunaris by inserting small plugs high up. A cessation of discharge following this procedure is evidence of frontal sinus empyema, and, per contra, a continuation of the flow would indicate empyema of the anterior ethmoidal cells or maxillary antrum.

The discharge from the posterior group of ethmoidal cells flows into the superior meatus, and may be seen in the olfactory fissure between the septum and the middle turbinal; but in the main it flows backward and downward into the postnasal space.

Open empyema of the ethmoidal cells, even when chronic, may pass through latent periods, the latent periods being characterized by a partial or complete cessation of pus flow and of the general symptoms of the disease, and also by the absence of visible and palpable indications of disease of the parts. This latent condition is possible only in cases where no deep-seated structural changes have taken place as a result of the prolonged infection. Necrosis of the middle turbinal and ethmoidal cells is rare. When present it may be determined by means of the examining probe. Further evidence of ethmoidal empyema is found in the structural changes in the middle turbinal, whereby its anterior and inferior portions become cystic. External swelling and protrusion of the inner wall of the orbit, pus sinuses in the region of the inner canthus, or flattening or enlargement of the side of the nose are the chief external evidences of extensive distention of the ethmoidal cells.

In chronic purulent ethmoiditis the discharge is commonly profuse, and during the night considerable collections both of fluid and inspissated pus accumulate in the postnasal space. Crust accumulations in the middle nasal meatus are common and may simulate ozena. Polypi, usually multiple, are a common complication, and they may occupy the cavities of the cells, protrude from their openings, or spring from the free surface of the middle turbinal. When polypi spring from the posterior third of the middle turbinal, strong presumptive evidence of empyema of the posterior group of ethmoidal cells is thereby furnished.

It is often difficult to differentiate empyema of the posterior ethmoidal cells from empyema of the sphenoidal sinus. More recent researches have shown that changes in the ethmoid bone (caries) are by no means rare in prolonged empyema of the ethmoidal cells. Grünwald demonstrated this condition in 31 out of 55 cases of ethmoidal suppuration.

As a result of prolonged pressure of the retained secretions, in retention cases, the cavities of the ethmoidal cells are liable to become distended, giving rise to the formation of mucocele. The most susceptible cell to mucocele development is the one situated at the anterior end of the ethmoidal labyrinth, but other ethmoidal cells are by no means exempt. These cysts may protrude either into the nose or into the orbit. They are differentiated from exostoses, which develop gradually and painlessly, while the former show a fluctuating contrast unless the abscess walls are intact.

Prolonged purulent ethmoiditis may finally lessen or pervert the sense of smell. The author has had a series of cases of chronic ethmoiditis of grippe origin which resulted in permanent anosmia. Chronic purulent ethmoiditis is a constant menace to the ears on account of the danger of middle-ear infection. Furthermore, the

obstructive character of the ethmoidal lesion tends to impede the normal aëration of the Eustachian tube. In the more severe cases, wherein the pus retention produces great pressure, the orbital plate of the ethmoidal bone breaks down and permits the escape of pus into the orbit, where it causes exophthalmos. General impairment of the health is not usually marked, although it may be present. Insomnia, aprosexia, mental depression and neurasthenic phenomena at times accompany ethmoidal sinusitis.

Diagnosis.—Method of examination: A complete history having been obtained, a painstaking rhinoscopic examination, under bright illumination, should be made as follows: 1. Caution the patient not to blow out the secretions until the first inspection is complete (it is natural for patients to blow the nose just before entering the rhinologist's office). 2. Note the amount, quality and location of the secretion, and the condition of the middle turbinal and its surrounding mucosa. 3. After spraying away all secretions, employ cocaine and adrenalin solutions for the purpose of local anesthesia and shrinkage of soft tissues. If pus is observed in the middle meatus external to the middle turbinal, it must come from one of three sources, viz., the maxillary antrum, the frontal sinus, or the anterior ethmoidal cells. Often two or all of these sinuses are involved. By washing out the maxillary sinus, preferably through an opening underneath the inferior turbinal (Chapter XXXVII), empyema of this cavity is determined, and transillumination (Fig. 367) is a valuable differential aid. Likewise, douching the frontal sinus whenever possible to do so aids materially in demonstrating whether or not this cavity is involved. Simultaneous flushing of the frontal and maxillary sinuses, when immediately followed by pus flow into the middle meatus, indicates empyema of the anterior ethmoidal cells. In typical cases the pus emerges from the point of junction between the bulla ethmoidalis and the middle turbinal. 4. It is often necessary to freely expose this point by resecting the anterior third of the middle turbinal (Fig. 353), and the removal of all polypi or other obstructing hypertrophies. 5. A cystic or otherwise enlarged middle turbinal (Fig. 346), particularly if accompanied by a pus discharge, or polypoid degeneration, is strong presumptive evidence of purulent ethmoiditis. 6. Transillumination possesses no value in the diagnosis of empyema of the ethmoidal cells. 7. *Skiagraphy* is a valuable means of determining purulent ethmoiditis. As heretofore remarked (Chapter XXXVIII), skiagraphy of the nasal accessory sinuses is a most difficult procedure, and only the most skillful roentgenologists are capable of producing reliable results. In Fig. 384 the skiagraph shows disease of the ethmoidal sinuses. 8. Finally, it is sometimes necessary to explore the cells in order to determine the character and extent of the purulent invasion.

Prognosis.—The prognosis in the more simple cases is favorable, especially when subjected to proper treatment. Closed empyemas are prone to result in extensive polypoid degeneration and in varying degrees of necrosis of the ethmoid bone, unless subjected to surgical

treatment. The necrosed areas may involve the orbital plate of the ethmoid, the lachrymal bone, or even the meninges, with fatal results.

Treatment.—The principles involved in the treatment of chronic purulent ethmoiditis are: 1, the removal of the diseased areas, and, 2, the establishment of ample drainage of the ethmoidal cells. (For description of suction treatment see page 577.)

Purulent disease of the ethmoidal labyrinth, except when the necrotic process has extended into or beyond the surrounding walls of the ethmoid bone, is usually amenable to intranasal surgical treatment. The anterior cells are sometimes most difficult to reach, but, according to Hajek, they can always be excavated, providing the middle turbinal has been resected. The complete labyrinth is shown in one of the superb sections prepared by Loeb (Fig. 407).

The various operative procedures are classified under three general headings:—

1. Partial excavation of the ethmoidal labyrinth by the intranasal route.
2. Complete removal of one or both groups by the intranasal route.
3. Complete removal by external operation.

1. Partial Excavation.—Partial removal of the ethmoidal cells is applicable to cases wherein the disease is more or less localized and confined to one or more of the larger anterior cells. All operations upon the ethmoidal cells require a more or less complete removal of the middle turbinal as a preliminary measure; hence the anterior end (Fig. 353) of the middle turbinal must be resected before attempting the operation for partial excavation of the diseased cells and their contents.

The preparations, both regarding local anesthesia and shrinkage of the tissues with adrenalin, should be carried out precisely as described for operations upon the middle turbinal (see Chapter XXXVI). By following the course of the pus flow or tracing the site of attachment of any polypi, the affected cells are discovered and entered one after the other, by means of a small, sharp, slightly curved curet (Fig. 403), or suitable punch forceps. The Brünings forceps (Fig. 401) is most adaptable and safe for the purpose of extracting granulation polypoid masses, and for detaching and removing the thin laminæ of bone. In other words, the operation consists in removing the obstructing lesion, and the establishment of free drainage, meanwhile depending upon intranasal washing or spraying to maintain cleanliness during the healing process. The galvanocautery is mentioned merely to be condemned as a measure for reducing the middle turbinal, since it may cause dangerous inflammatory reaction.

Hemorrhage during the operation is rarely troublesome, and is controllable by repeated applications of suprarenal solution or temporary packing with gauze.

2. Complete Removal of the Ethmoidal Cells by the Intranasal Route.—The indications for the intranasal method, according to Hajek, are: 1, in all cases of chronic latent empyema of the ethmoidal labyrinth, with or without extension toward the

nasal cavity; 2, in acute empyema of the labyrinth, in the presence of symptoms of imminent rupture toward the orbit.

The Surgical Procedure.—During recent years many operative methods and surgical procedures have been made use of and fully described. All of these procedures and particularly the thorough operation devised by Mosher have many followers. The author, however, recommends the operation devised by Coffin as a com-

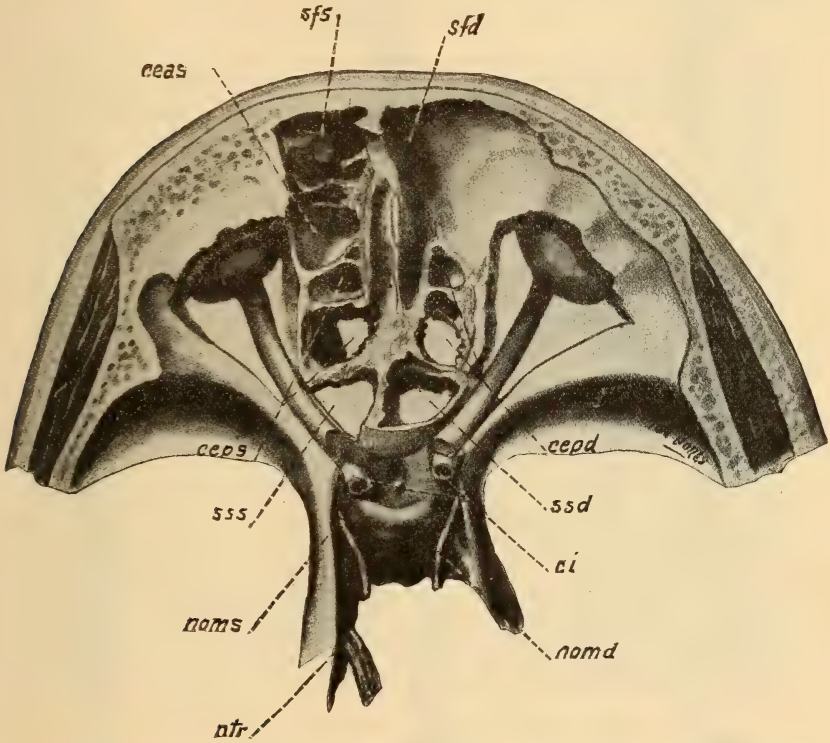

Fig. 407.—Whole left labyrinth exposed (*ceps, ceas*); each sphenoid (*sss, ssd*) in relation with corresponding optic nerve and chiasm; last posterior ethmoid cells (*ceps, cepd*) show usual relation with optic nerve at posteroexternal angle; *ntr,* trifacial nerve. (*Loeb,* with permission.)

paratively simple procedure attended with but little danger. Of the operation Coffin says: It should be constantly borne in mind that in chronically diseased ethmoid bones there frequently exists a more or less extensive necrotic condition of the bony cell walls as well as in the lateral walls which form the boundary of the body of the bone. For surgical purposes one should concern himself practically, not only with the body of the bone but with the middle turbinal, the cribriform plate and those bones with which the ethmoidal bone articulates. The last because many of these bones serve to cap or cover the open cells about the boundary of the

cuboidal body of the ethmoid bone. In fact in some instances the cells of the ethmoid push themselves well into the neighboring or boundary bones, in which event they are prone to become extremely large. This is especially so as to the horizontal plate of the frontal and of the lacrimal bones. These cells are generally

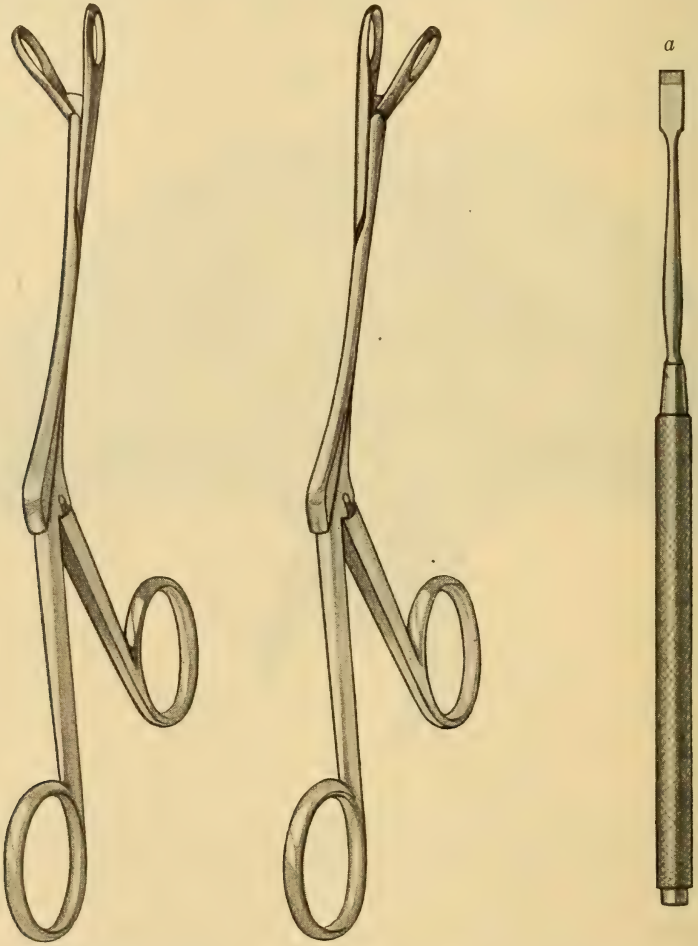

Fig. 408.—Coffin's right and left ethmoid forceps. (*a*) ethmoidal chisel.

spoken of as ethmoidal cells from their source and manner of development, even though from their position they might be called frontal or lacrimal cells. Of the surgery of these cells it is sufficient to say here that they cannot be reached and successfully treated intranasally. Intranasal exenteration of the ethmoidal cells is practically confined to those cells of the ethmoid which lie in the body of the bone posterior to the anterior border of the

infundibulum. The method of attack and operation is as follows: After thorough anesthetization of the parts with a 10 per cent. solution of cocaine packed under and over the middle turbinate bone, one places on the level or just above and immediately in front of the attachment of the middle turbinate bone a long, flat and thin chisel (Fig. 408*a*) and pushes or taps it through the internal lamina of the ethmoid. The chisel is placed at about a 45° angle to the bone (Fig. 409) and points towards the inner canthus of the eye. One appreciates easily when the chisel has pushed

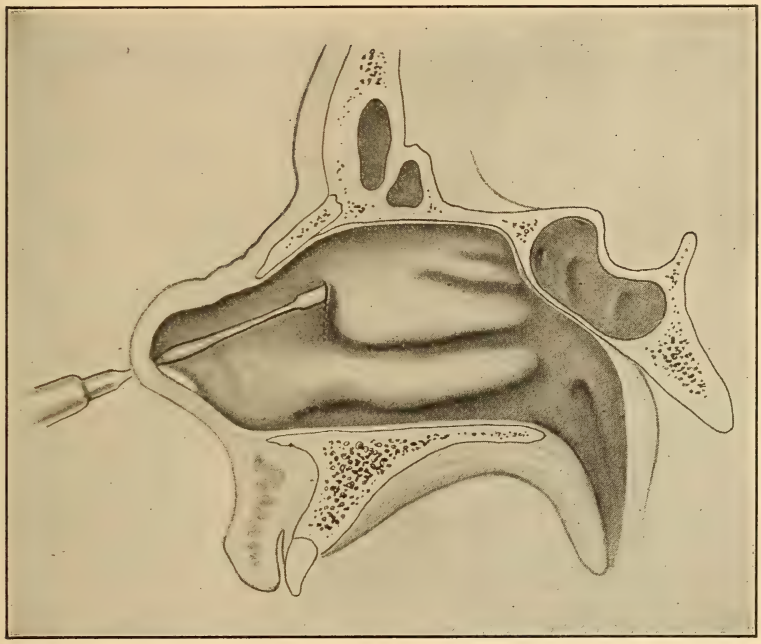

Fig. 409.—The ethmoid chisel entering the ethmoid labyrinth.

through the solid bone constituting the inner wall of the body. If this bone be thin or diseased the chisel can be carried vertically downward as a knife to near the elbow of the hiatus semi-lunaris. If one be unable, due to thickness of the bone, to make the above incision with the chisel, the opening may be enlarged by making several chisel cuts, one directly under the other. The chisel is now pushed into the labyrinth near the top of the incision for one-half to three-fourths of an inch (Fig. 410), the handle of the chisel being carried outward so that the blade may be more nearly parallel with the lamina of bone just cut through. The chisel is now moved parallel to itself toward the nasal fossa, thus widening the gap where incision was made. A flat bladed forceps of the Luc type or Coffin's right and left ethmoid forceps (Fig. 408) placed in the nose so that one blade shall enter into the now open ethmoid laby-

rinth while the other is in the nasal fossa (Fig. 411). The forceps are closed and a slight to and fro rotary motion of the hand enables one to remove a considerable portion of the ethmoid body. Two or three such bites and removals carries one to the face of the sphenoid bone where the ostium of that bone can generally be seen (Fig. 412).

The middle turbinate bone, if much diseased, may be included in the original grasp of the forceps, or it may be removed either previous to or following the attack upon the body of the ethmoid

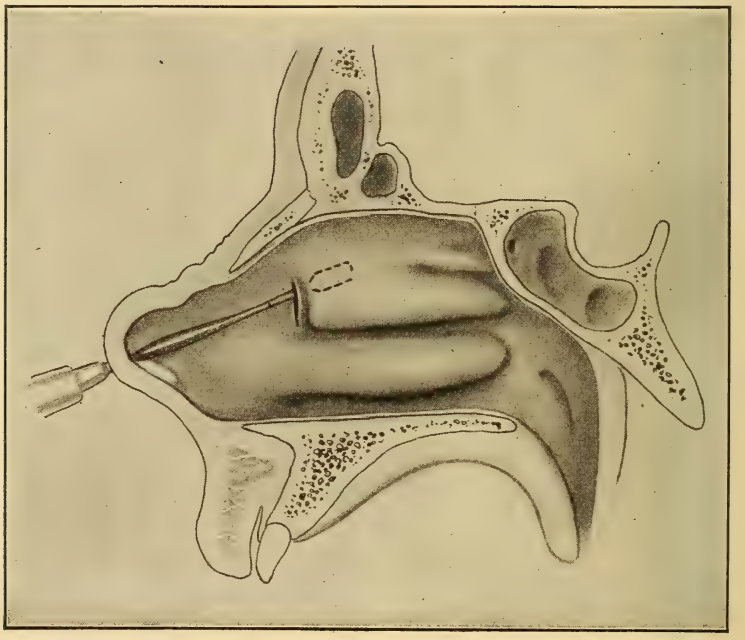

Fig. 410.—The dotted line indicates the position of the chisel within the labyrinth.

bone or at times left *in situ.* Injury to the cribriform plate and bordering bones of the ethmoidal labyrinth is to be most carefully avoided. Only by the most careless or bungling technique can the cribriform plate be injured. In fact by the above described method of opening the ethmoidal cells it is practically impossible to injure the cribriform plate. In using the forceps the handle should be kept as nearly parallel as possible with the floor of the skull. Actual pain is not great. Not infrequently the lining of two or three of the cells will be seen in the mass removed, looking like a small bunch of grapes. The hemorrhage as a rule is slight and at times almost *nil.*

The majority of operators, including Coffin, consider this or any other operation for the exenteration of the ethmoid cells in

adults under general anesthesia as dangerous. This operation is not applicable to children, whose ethmoids if operated upon should be done under general anesthesia and by the external route.

Mosher's ethmoidal operation is accomplished by the use of the curet (Fig. 413).

Complications.—The intranasal method of operation is occasionally followed by troublesome emphysema involving the orbit and eyelids, as a probable result of the forcible entrance of air through an accidental opening, or a pre-existing necrotic sinus through the

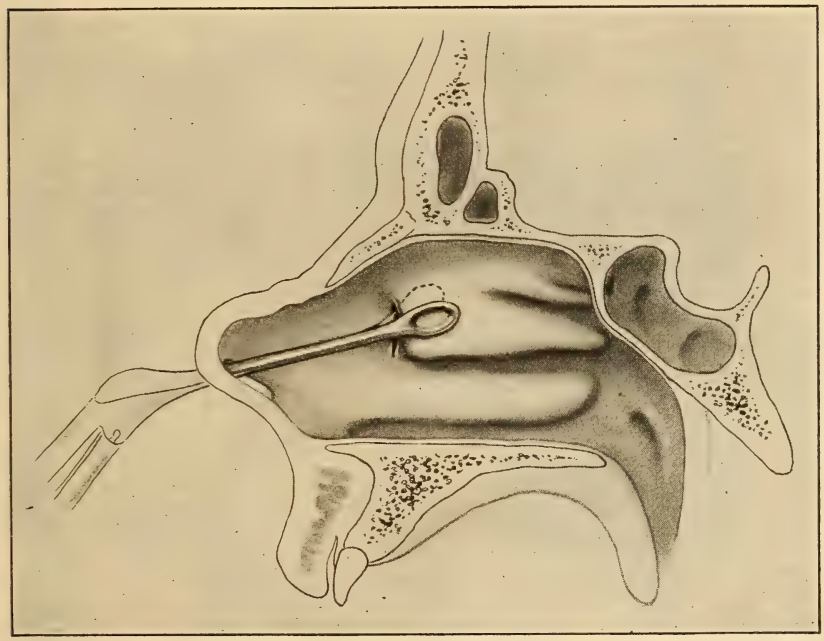

Fig. 411.—The forceps engaged in the ethmoidal mass.

orbital plate of the ethmoid bone. The above complication supervenes almost immediately upon the completion of the operation. From the same source infection and abscess of the orbit may follow. In the same manner injury to and infection of the meninges transpires. It is contended by some observers that intracranial complications may be induced by the shock and irritation of the operation alone. In a limited proportion of cases of purulent ethmoiditis there is a pre-existing latent meningitis or a circumscribed brain abscess, either of which may be excited to renewed activity by the manipulations incident to the operation, especially when carelessly or unskillfully performed.

3. Complete Removal of One or Both Groups by the External Route.—In the external operation the ethmoidal labyrinth may be reached in three ways—viz., (*a*) The direct route. (*b*) Com-

bined with the external operation upon the frontal sinus. (*c*) The maxillary route.

Of these the first named only is employed for purulent disease which is limited to the ethmoidal cells. The method of entering the ethmoidal labyrinth directly is depicted in Fig. 400.

By the direct route the ethmoidal labyrinth is entered through

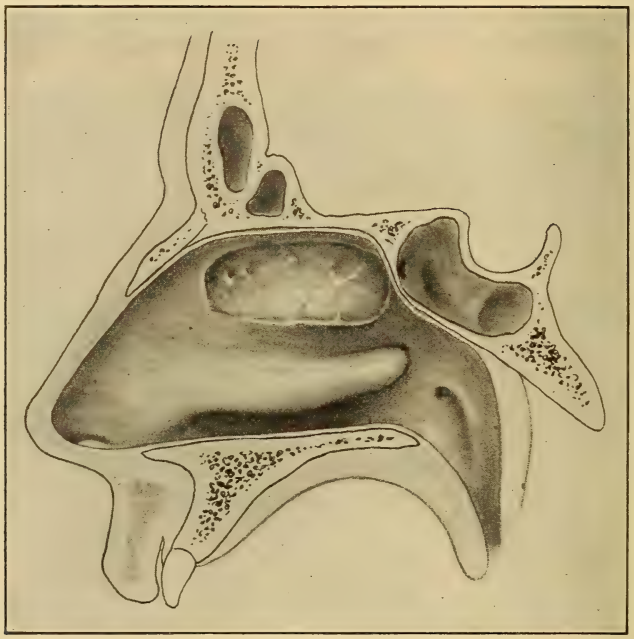

Fig. 412.—The completed ethmoidal operation.

that portion of the nasofrontal region directly anterior to the cells, the primary curvilinear incision being made midway between the median line and the inner canthus of the eye, and extending from a point just below the eyebrow near the supraorbital notch to a point about ½ inch beneath the level of the inner canthus. The

Fig. 413.—Mosher's ethmoid curet.

soft tissues, including the periosteum, are then retracted and all bleeding vessels tied off. When a fistulous opening is found it serves as a point of entrance to the cells, otherwise by means of a chisel a portion of the nasal bone and of the frontal process of the superior maxilla is resected, through which the labyrinth is reached. The opening may be gradually enlarged by careful removal of a

sufficient portion of the external bony covering, always using care to avoid the orbital plate externally and the cribriform plate above. The space is sufficient to permit a comparatively large external bony opening through which even the deeper cells may not only be explored, but thoroughly curetted.

The removal of the middle turbinal is a necessary step in the external operation. Hemorrhage into the pharynx is prevented either by tamponing the nares after the manner heretofore advised for the Killian operation or by means of a large tampon retained in the epipharynx by suitable forceps. Aided by direct illumination from a well-adjusted headlight (Fig. 7) it is possible to maintain continuous illumination of the operative field. The anterior ethmoidal cells are first broken down and removed. Again, the Brünings forceps (Fig. 401) are recommended as the safest and most effective instruments for engaging and removing the diseased soft tissue, and the thin walls of the cells. A liberal portion of the floor of the frontal sinus may also be removed at this operation if considered necessary. Continuing the operation the posterior cells should likewise be excavated and the sphenoidal sinus when diseased.

This method of entering the sphenoidal cavity is feasible and by many authorities is considered preferable to all others. In case the operation is to be confined to the ethmoidal cells, the final steps of the operation consist of packing the denuded cavity with sterile gauze and closure of the external wound. After packing the cavity with one long strip of gauze, the distal end of the section of gauze should be carried well down into the nasal cavity in order that the packing may subsequently be removed through the anterior nares. The external wound is then closed with sutures, which should unite both the skin and the denuded periosteum.

(*b*) Whenever empyema of the frontal sinus is combined with the ethmoiditis and the double operation is necessary, the combined operation (Killian) described in Chapter XXXVIII becomes feasible. Under these circumstances it is customary first to complete the operation upon the frontal sinus, after which the ethmoidal cells are reached through the floor or lower part of the inferior wall of the former (Fig. 400). The floor of the frontal sinus furnishes a guide to the upper surface of the ethmoidal cells.

(*c*) A third method of procedure is the antrum route, in which the cells are entered by breaking down the lamina of bone between the maxillary antrum and the anterior ethmoidal labyrinth. By this same method the sphenoidal cavity may also be reached.

Whenever orbital abscess is present care should be taken to curet the entire pus canal, and especially the portions of the necrosed orbital plate. The same holds true when the cranial table of the ethmoidal labyrinth is necrosed. In the latter it is preferable to expose a considerable area of dura and thus secure free drainage, in addition to the complete removal of all diseased areas of necrosed bone.

After-treatment.—Thorough surgical removal of the ethmoidal cells and all surrounding diseased tissue should put an end to the purulent process. As soon as the operation is completed the patient should be placed in bed. Edema about the eyelids should be controlled by the application of ice-cloths. The primary dressings should be removed about the third day. During a few days subsequent to the operation the lining of the nasal cavity in the vicinity of the ethmoidal cells is liable to undergo marked infiltration, a phenomenon of reaction on the part of the mucosa and periosteum which disappears in a short time of its own accord. It is doubtful whether continuous packing with gauze strips is advisable. Upon each redressing the wound cavity should be cleansed with sterile saline solution introduced either by means of douche or spray, under mild pressure, always avoiding violent blowing of the nose in order to prevent the entrance of infection into the middle ear. At every dressing it is advisable to remove any shreds or spiculæ of bone which may have been overlooked.

The granulations when healthy should be allowed to grow unmolested, but unhealthy and exuberant granulations may be reduced by applications of nitrate of silver, chlorid of zinc, or, best of all, by curettage. From this time on free drainage and cleanliness, together with control of granulations, should be the keynote in the management of the case. The patient should be taught to carefully cleanse the nasal cavities in order to insure continuous cleanliness of the parts. The after-treatment is always considerably prolonged and tedious both to the patient and to the operator, but its importance is usually justified by the results obtained.

II. THE SPHENOIDAL SINUSES.

Surgical Anatomy.—The middle portion of the body of the sphenoid bone is occupied by two cavities known as the sphenoidal sinuses, which are separated from each other by a septum. Each cavity opens into the corresponding naris, by the ostium sphenoidale. The sphenoidal cavities are not present at birth, but begin to develop after the seventh year. The dividing wall projects outward upon the anterior surface of the body of the bone, where it is designated as the sphenoid rostrum. This rostrum forms the posterior and uppermost portion of the nasal septum. The upper part of the sphenoidal septum is commonly asymmetrical to such an extent that one cavity may be three or four times larger than the other, and occasionally the septum is partially or wholly absent, in which event the two sinuses form one large cavity (Fig. 414). Under normal conditions the size of the sphenoidal sinuses is in inverse ratio to the thickness of their bony walls; hence a large sinus usually has extremely thin walls. The ostium or sphenoidal opening is located in the upper portion of the anterior sphenoidal wall rather close to the septum. It is invisible in the living subject, unless in atrophic rhinitis cases or after complete removal of the middle turbinal bone. It lies in the spheno-

ethmoidal recess. The level of the sphenoidal ostium is variable, however, as compared to the floor of the cavity. As a rule the orifice is placed above the middle of the anterior wall.

The walls may be described as a *roof,* which is a portion of the floor of the anterior cerebral fossa; the *external wall,* which is thin, separating the cavity from the cavernous sinus or the internal carotid artery and portions of the third, fourth, fifth and sixth cranial nerves, which lie between it and the dura; the *internal* (mesial) *wall,* which is the septum already described, and the *floor,* which is formed by a substantial portion of the body of the sphenoid bone. The relation of the nasal accessory sinuses, and particularly of the sphenoidal sinuses to the optic nerves (Fig. 406) is of considerable clinical importance. Loeb[1] has written an exhaustive thesis upon this subject, to which the reader is referred for details.

The *anterior wall* in its superior portion is composed of the posterior ethmoidal labyrinthine wall, and its remainder forms the nasosphenoidal partition and contains the ostium sphenoidale. Occasionally a small portion of the anterior wall forms a part of the orbit. Small accessory sphenoidal sinuses are occasionally present, being located in the lesser wings. According to Loeb, in bone sections the sphenoidal sinuses in the anteroposterior diameter vary from 2 to 42 mm.; superoinferior, 4 to 36 mm.; lateral, 2 to 35 mm.; averaging, respectively, 21.5, 22.8 and 18.4. The sphenoidal sinuses are sometimes entirely absent, and bony ridges and circumscribed excrescences are more common than in the remaining accessory sinuses. The mucous lining of the sphenoid sinuses forms at the same time the periosteal covering similar to that of the ethmoidal labyrinth (Hajek).

Pathological Anatomy.—The pathological alterations which invade the sphenoid sinus are: 1, changes in the bone, and, 2, inflammatory changes involving the lining mucosa. The changes in the bone commonly arise from a cortical osteitis which has originated in the mucosa of the sphenoidal sinus. The more destructive processes (caries) which involve the bony walls of the sphenoidal sinus are almost exclusively of syphilitic origin, but at times a tuberculous process affects this region. It is a mooted question whether this condition constitutes a direct pressure necrosis for which the pent-up pus is responsible, or whether it is due to an intermediate thrombophlebitis. Rupture of the walls of the sphenoid sinus may open up a pathway of infection into the nose, the orbit or the meninges.

The lining membrane of the sphenoidal sinus is less susceptible to inflammatory changes (hyperplasia) than the other accessory sinuses. In most cases of acute inflammation the mucosa becomes red, injected and slightly edematous. When severe the edematous infiltration is much increased, and secretion is profuse.

[1] "A Study of the Anatomic Relations of the Optic Nerve to the Accessory Cavities of the Nose." Transactions of the American Laryngological, Rhinological and Otological Society, 1909.

Occasionally ecchymosis, with a bloody secretion, may be observed. Many observers contend that even in severe acute inflammations of the sphenoidal sinuses the nasal mucosa may remain normal, the observation being interpreted as indicating the independent character of the inflammation, in contradistinction to its being transmitted from the mucous lining of the nose.

The changes incident to chronic inflammation of the sphenoidal mucosa are believed to correspond in every part to those observed in connection with the other accessory sinuses of the nose. There is, however, less tendency to the formation of polypi

Fig. 414.—Front view of a slightly slanting coronal section of the skull. The slant is downward and forward, and shows the posterior wall of a large single sphenoidal cavity, also the posterior ethmoidal cells. The lower larger opening is the nasal opening into the pharynx, on both lateral walls of which the pharyngeal orifices of the Eustachian tubes are seen. Below, the soft palate comes into view. With key plate.

and cysts, the pathological changes usually being confined to thickening, hypertrophy and sclerosis of the mucosa.

Method of Examination.—After wiping or spraying the accumulated secretions from the superior meatus, the tissues should be anesthetized and contracted by means of cocaine and adrenalin. Zuckerkandl has outlined the most accurate method to be followed in reaching the sphenoidal sinus. A probe (Fig. 415) following the continuation of a line connecting the inferior nasal spine with the middle of the free margin of the middle turbinal will strike the anterior wall of the sphenoidal sinus, and, in a few favorable cases, the sphenoidal *ostium* itself. The *ostium* is not always so readily reached, since it does not invariably occupy the same level.

Another reason for failure to enter the *ostium* is due to the difficulty in invariably directing the sound over the exact geometrical centre of the turbinal. Furthermore it is impossible to enter the sphenoidal ostium when the middle turbinal is enlarged. In the majority of cases the ostium is not visible by rhinoscopy; nevertheless often it is possible to enter and to explore the sinus even though the orifice remains invisible. In the absence of the middle turbinal the ostium is plainly visible.

If the point of the sound is slightly curved outward it is more likely to enter the ostium. Upon entering, the point of the sound first should be curved downward to prevent its impact against the roof of the sinus in case the ostium is situated at the highest part of the anterior wall.

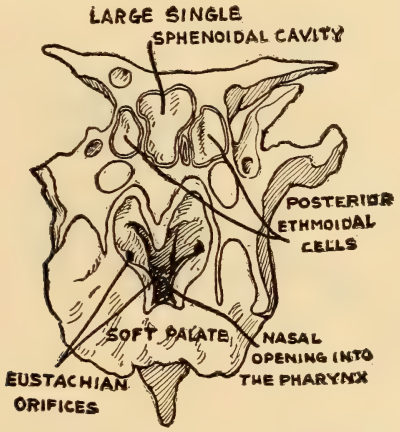

Key plate for Fig. 414.

When the probe is in the sphenoidal sinus its movements in every direction become restricted by the limited diameter of the ostium. Additional evidence is obtained by determining the distance between the inferior nasal spine and the anterior wall of the sphenoidal sinus. In the adult, according to Hajek, the measurements average from 6 to 8 centimeters, varying only within narrow limits, according to the age of the patient and the conformation of the skull. That an entrance has been effected may be determined whenever the sound enters 7½ to 8 centimeters in an individual with a small head, or 8½ or more centimeters in large ones. Occasionally it may enter a distance of 9½ to 10 centimeters, especially when the distal end of the instrument has been turned downward, in cases where the longitudinal diameter of the sinus amounts to from 2 to 3½ centimeters.

DISEASES OF THE SPHENOIDAL SINUSES.

Having considered the pathology of purulent diseases of the sphenoidal sinuses and the method of examination of these cavi-

ties, the symptoms, course and treatment of these affections are briefly outlined under two general subdivisions, as follows:—

(*a*) Acute empyema;

(*b*) Chronic empyema.

The etiology of empyema of the sphenoidal sinuses is so similar to that already defined in similar affections of the neighboring accessory sinuses of the nose that it is not repeated here. Nevertheless a few slight variations are enumerated as follows:—

1. Closed empyema is less common in the sphenoidal sinuses.

2. Excessive outgrowths of edematous polypi from the lining mucosa are infrequent.

3. Purulent involvement, both acute and chronic, is proportionately less common than in the neighboring sinuses.

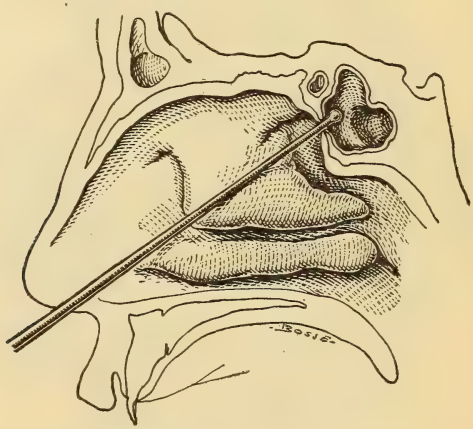

Fig. 415.—Probe in sphenoidal sinus.

4. Empyema of the sphenoidal sinuses is prone to occur concurrently with a like process in the posterior ethmoidal cells.

Symptoms.—The subjective symptoms of empyema of the sphenoidal cavities are extremely inconstant and unreliable. They consist essentially of: 1, headache; 2, disturbance due to abnormal secretion; 3, interference with the sense of smell; 4, vertigo.

The objective symptoms are: 1, the localization of the secretion in the nose and nasopharyngeal space; 2, the secondary changes in the lining mucosa; 3, the findings resulting from rhinoscopy and sounding.

Pain is not constant and may be absent altogether. The headache commonly is located at the base of the brain, the postorbital region, or in the region of the nasopharynx. Vertigo is of comparatively common occurrence, of varying intensity, and may either be constant or intermittent. Whenever, as a result of the purulent process, destruction of the bony walls of the sinuses ensues, dangerous sequelæ are likely to occur. Briefly enumerated, the complicating lesions are meningitis, brain abscess, thrombosis of the cavernous sinus, paralysis of the ocular muscles, and sudden

blindness. Even closed empyema has been known to produce paralysis of the ocular muscles, protrusion of the orbit, and sudden blindness. The affection so rarely exists uncomplicated by disease of the other accessory sinuses, notably the ethmoidal labyrinth, that great confusion is encountered in differentiating the symptoms.

The most prominent and constant symptom is the discharge which flows backward over the pharyngeal vault, and either escapes into the larynx or forms into crusts upon the posterior end of the middle turbinals, where it gives rise to irritation, to relieve which the patient "hawks" almost incessantly. In uncomplicated cases the secretion is observed in front of the olfactory fissure, but is more profuse posteriorly in the nasopharynx. The amount of secretion in sphenoidal empyema varies, depending upon the stage of the disease, its extent, and the size of the sinus. In chronic cases the sense of smell is materially lessened.

Prognosis.—In acute cases and in the majority of chronic ones, in individuals who submit to proper treatment the prognosis is good, the chief dangers arising from extension of the necrotic process to nearby structures.

Treatment.—In the treatment of the sphenoidal sinuses the following difficulties are encountered:—

1. The middle turbinal, particularly when enlarged, forms a barrier both to direct inspection and to instrumentation.

2. A deflected or thickened septum may encroach upon the lumen of the meatus of the affected side.

3. Extensive ethmoiditis, accompanied with polypi which fill the middle meatus.

These barriers do not exist in cases of extensive atrophic rhinitis wherein the middle turbinal has disappeared, or when the anterior portion of the ethmoidal labyrinth together with the middle turbinal have been removed.

Having ascertained that the sinus is the seat of pus, the simplest method of treatment, one that is applicable in acute cases, is by means of irrigation. A Myles sphenoidal cannula (Fig. 416) or an ordinary Eustachian catheter bent to a proper curve is introduced through the sphenoidal ostium and the sinus is cleansed with warm physiological salt solution. Before removing the cannula, air should be blown into the cavity in order that no residual secretion shall remain. In case the discharge persists a small amount of a 2 per cent. solution of silver nitrate or of a 25 per cent. solution of argyrol may be instilled into the sinus every second or third day, to be washed out after remaining from thirty to sixty seconds.

Whenever the irrigations fail to arrest the discharge, it becomes apparent that the lining mucosa of the cavity is the seat of hyperplasia and possibly of polypoid degeneration; hence the drainage must be accelerated and the polypoid excrescences removed. For this purpose surgical measures are necessary, both for the enlargement of the opening into the sinus, and for the

removal of any diseased mucosa or bone. (For description of suction treatment see page 577.)

Surgical Treatment.—Three general types of operation are employed: 1, the artificial enlargement of the sphenoidal *ostium;* 2, the making of a new orifice in the anterior wall of the sinus, irrespective of the normal opening; 3, the radical procedure whereby the entire anterior wall of the cavity is removed, together with thorough curetment of the lining mucosa and the diseased osseous walls. Any operation upon the sphenoidal cavity performed by the nasal route presupposes a preliminary removal of the middle turbinal. Previous removal of the ethmoidal labyrinth also greatly facilitates the operation upon the sphenoidal sinus. The intranasal route is preferable to any form of external operation, and the latter is feasible and advisable only in conjunction with external operations upon the ethmoidal labyrinth.

In operating upon the sphenoidal sinus by the nasal route local anesthesia is to be preferred, inasmuch as the upright position and better control of hemorrhage enables the operator to view each



Fig. 416.—Myles's sphenoidal cannula

step of the operation. A 1 : 5000 solution of adrenalin should be sprayed over the upper and posterior areas of the nasal cavities, for the purpose of enlarging the field of observation and to control the hemorrhage. A few drops of a 4 per cent. solution of cocaine may be instilled into the sphenoidal cavity. Pledgets of cotton soaked with the same solution should be packed over the anterior wall of the sphenoidal cavity and in the middle meatus. Fully twenty minutes should be allowed for local anesthesia to take place.

1. Simple Enlargement of the Osteum.—This is accomplished by introducing a curet which is slightly larger than the ostium and forcibly breaking down its borders. Further enlargement is obtained by the use of some form of punch or biting forceps (Fig. 417). This procedure may be followed by a period of irrigation after the manner described in the foregoing paragraphs. It often is possible to instruct the patient to irrigate his own sinus.

2. Perforation of the Anterior Wall of the Sphenoidal Sinus.—This procedure is advocated by many authors in extending an operation from the posterior ethmoidal cells. A strong but small-sized curet is introduced into the nasal cavity in an upward and backward direction, and at an angle of 45° to the nasal floor, until it comes in contact with the anterior sphenoidal wall, through which it is forced. From this point of entry the opening should be enlarged by punching out sections of the anterior wall.

Through this opening the sinus may be explored and curetted if necessary.

3. The Radical Operation.—The term radical operation in this connection implies the removal of the anterior wall of the sphenoidal sinus and the curetment of all polypoid tissue, diseased mucous membrane and necrosed bone when present, preferably by the intranasal route. Having removed the posterior ethmoidal cells and the middle turbinal, entrance is made through the ostium sphenoidale, or by puncture of the anterior wall (see former paragraph). Then with a forceps (Fig. 417) and a sharp curet the remaining portion of the osseous wall is removed piece by piece. With bright illumination a good rhinoscopic view of each step of the procedure is obtainable.

Having removed the anterior wall the interior of the sinus should be inspected and probed. If the mucous membrane is

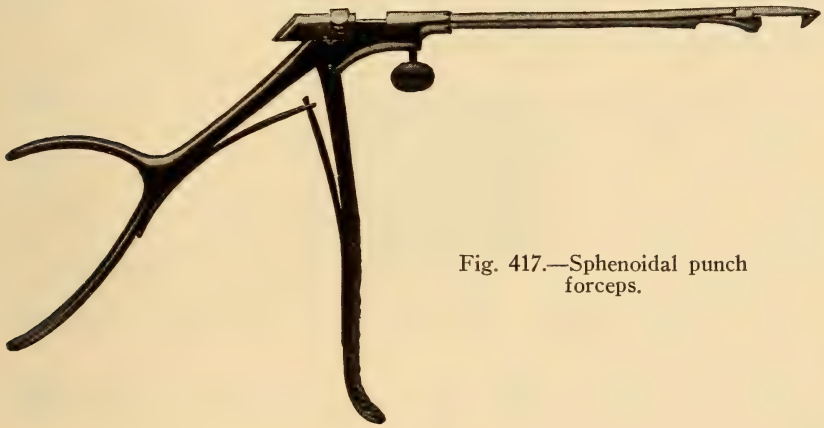

Fig. 417.—Sphenoidal punch forceps.

edematous with polypoid excrescences it should be subjected to vigorous curettement, always bearing in mind that the procedure is not devoid of danger if the outer lateral wall is broken through. In a considerable proportion of cases the polypi are confined to the areas surrounding the orifice, in which event the more healthy mucosa should remain undisturbed.

The final step of the operation consists in washing all mucus and shreds of bone and tissue from the sinus cavity, after which it should be lightly packed with a strip of iodoform gauze. On the following day the gauze may be removed and the wound irrigated with a warm saline solution. The further treatment consists in daily irrigation and the prevention of contraction and partial closure of the wound by exuberant granulations. It is often necessary to apply a 2 to 5 per cent. nitrate of silver solution every second or third day about the opening of the sinus in order to prevent contraction, until finally a permanent ample orifice is secured. A recurrence of polypi demands a secondary curettement and packing with gauze for a few days.

The results as a rule are satisfactory and the secretion ceases in a short time. Other cases prove to be refractory and recovery is protracted. In the protracted cases considerable annoyance is occasioned by the retention of scales and crusts.

External Operations.—The preliminary steps of the external operation through the ethmoidal labyrinth are described in the section on the Ethmoidal Sinuses.

After the excavation of both the anterior and posterior ethmoidal cells is completed, the sphenoidal sinus is entered by breaking through the anterior wall. The wall separating the sphenoidal cavity from the posterior ethmoidal cell is extremely thin and sometimes it has already broken down. Grünwald[2] states that 73 per cent. of his cases of sphenoidal sinus affections were complicated with disease of the posterior ethmoidal cells. Here cutting forceps or a curet, used with care, forced through the posterior ethmoidal wall, may easily enter the sphenoidal cavity, which may then properly be explored, flushed with proper solutions, or even packed with gauze (Fig. 400).

Jansen has advocated a method of approaching the sphenoidal cavity through the antrum of Highmore, the latter cavity being entered through a large opening in the canine fossa.

The ethmoidal cells are first entered at the inner and upper angle of the antrum, the direction being inward, backward and upward. Following the same direction the sphenoidal sinus is reached. Onodi has shown by measurements of skulls that the Jansen procedure is impossible in many cases, and furthermore it is not devoid of danger. There is no tangible advantage in the external operations over the intranasal procedures above described; hence they are not commended.

---

[2] Rapport présenté a l'Assoc. mèdic. britannique à Manchester, Juillet, 1902.

CHAPTER XL.

THE CORRECTION OF EXTERNAL NASAL DEFORMITIES, EPISTAXIS, FOREIGN BODIES IN THE NOSE, PARASITES IN THE NOSE, RHINOLITHS, NASAL FURUNCULOSIS.

External nasal deformities are characterized either by absence, in whole or in part, of the normal anatomical structures of the nose, or else an exaggeration of its natural contour. The intranasal deformities, usually of the septum, which are commonly concerned with the changes in the external shape of the nose, have been described in Chapters XXXV and XXXVI.

The common varieties of nasal deformities are: (*a*) the crooked or twisted nose; (*b*) the hooked or beaked nose; (*c*) the "saddle"

Fig. 418.—A twisted nose.

nose; (*d*) the flat nose; (*e*) the broad-bridge nose; (*f*) the pinched nose; (*g*) the "pound" nose; (*h*) partial or total absence of nose.

(*a*) The most common deformity of the nose is the *crooked* or *twisted* nose, bent to either side of the median line (Fig. 418). This type of external nasal deformity is caused: 1, by congenital asymmetry; 2, by external violence resulting in fracture of one or both nasal bones (Fig. 419), or fracture or dislocation of the bony or cartilaginous septum; 3, by disease of the soft parts; 4, by tumors.

(*b*) The *hooked* or *beaked* nose is really an exaggerated form of the so-called "Roman" nose, which naturally has an arched contour when seen in profile in contradistinction to the "Greek" nose, which presents a straight profile. The hooked nose is often associated with a heightening of the palatal arch, which causes the superior maxillary bones to recede, in consequence of which the nasal bones become more prominent. An unduly high palatal arch is either congenital or due to mouth-breathing and obstructed nasal respiration, brought about by a lymphoid hypertrophy or adenoids in the nasopharynx. Deflections of the bony or cartilaginous septum rarely are absent in these cases.

(*c*) The deformity known as saddle-nose (Fig. 422) is quite common.

It is characterized by a depression or absence of the natural nasal arch, and is due to external violence or disease. Syphilis (tertiary), in the majority of cases, is responsible for the necrosis of the nasal bones and cartilages which results in a sinking of the nasal bridge. Tuberculosis, lupus, and cancer are less common causes. Since the submucous resection of the nasal septum has come into popularity a few cases of saddle-nose have been observed where this operation has been undertaken during the active stage of a luetic infection, or the deformity has resulted from negligent or unskillful submucous surgery. Necrotic breaking down of the septal nasal cartilage from abscess is another cause of saddle-nose.

(*d*) The flat-nose deformity is usually due to direct violence; some cases are congenital, in which event there is either a defect or absence of some of the skeletal facial structures.

Fig. 419.—Dislocation of both nasal bones and transverse deflection of the cartilaginous septum caused by external violence.

(*e*) An opposite condition to the flat or saddle-nose is the broad-bridge nose, a rare condition in which the broadening and thickening is due to traumatism or intranasal inflammatory conditions, either of which can cause a periosteal inflammation with increased nutrition to the nasal bone and the nasal processes of the superior maxilla, resulting in an enlargement or spreading of the nasal bridge.

(*f*) The pinched nose (collapse of the alæ nasi) is a deformity of the ala cartilages proper, or else an atrophy of the muscular fibres surrounding these; often cicatricial bands from previous ulcerative disease cause permanent narrowing of the nostril.

(*g*) Enlargement of the bulbous portion of the nose is often found in such skin diseases as acne rosacea, and in the "pound" nose of the Germans. This deformity is also present in some cases of rhinoscleroma.

(*h*) Absence of the nasal appendage in whole or in part is due to the ravages of ulcerative diseases (cancer, lupus and syphilis), or else to criminal assault, and in semicivilized people it is inflicted as a penal measure, religious mutilation or brutality. It is included in the above list in order to complete the list of external nasal deformities.

Treatment.—Only within recent years has the rhinologist endeavored to devise efficient means of treatment for correcting the more formidable deformities. At present the treatment is based either upon prothetic, surgical or mechanical principles, and often combines any or all of these measures in individual cases. The Germans, French and Italians for some years past have done excellent work by way of plastic facial surgery, using the flap grafting method in most cases. They derive the tissue either from the finger, arm or forearm, or else from the adjacent cutaneous surfaces.

This plastic method is particularly serviceable in the cases where the ulcerative processes of the diseases mentioned above have destroyed the cutaneous or musculocutaneous soft structures covering the nose and its surrounding areas. The reader is referred to works on general surgery for descriptive detail of these plastic or grafting operations.

It need only be mentioned that, in the treatment of external deformities, the intranasal irregularities must be corrected either before or after the operation which is performed to relieve the external nasal deformity. The *crooked* or *twisted* and the *hooked* or *beaked* nose are treated either by the external method or by the intranasal subcutaneous method as practised by Roe.

In operating by the external method, a vertical or curved incision of varying length is made through the skin and the periosteum which covers the deformity and with an elevator the soft tissues are pushed to either side, thereby exposing the deformity, which is now reduced to the desired level either with a chisel or saw. The periosteum is then drawn over the denuded bone and closed by sutures of catgut, and a subcutaneous suture of catgut is used to close the external wound. With primary union an almost invisible scar results. This operation possesses the advantage of accuracy in technique and adequate asepsis.

Roe's method is intranasal and consists in making the incision in the nostril beneath and anterior to the deformity so that the skin and periosteum can be raised from the deformity, the latter then being ablated and removed, or else utilized in building up the depressed portion in order to make the nose symmetrical and give it the desired shape. Roe says: "Except in very large noses, it is rarely necessary or desirable to remove any portion of tissue, or even bone, for there is generally a correspondingly depressed portion that requires filling up to give the nose the proper shape. Particularly is this the case where the cause of deformity is traumatic, when we simply have a displacement rather than a destruction of tissue, which should be restored, so far as possible, to its former position."

A slender knife or saw is used to reduce the deformity, and the technique is difficult to describe, since it must vary in any given case. Slowness and extreme care must be exercised in the operation, and both the surgeon and patient need great patience, often more than one operation being necessary. Roe classifies nasal deformities schematically as follows:—

DEFORMITIES OF THE NOSE.

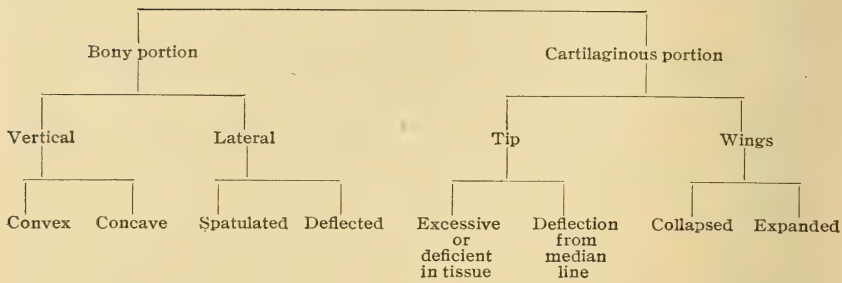

In cases of saddle-nose or flat nose the deformities may be corrected by the injection of paraffin to round out or fill in the deficiency in the contour of the nose, as first employed by Gersuny, of Vienna, in 1900, or surgical means may be employed.



Fig. 420.—Smith's paraffin syringe.

The prothetic method of subcutaneous paraffin injections is much favored by the author. Harmon Smith has improved the original technique, thereby lessening the dangers and ill effects of the paraffin injections. Three cases of amaurosis due to thrombosis of one of the ophthalmic vessels have been reported, which undoubtedly were the result of disregarding the caution to make firm pressure at the root of the nose in order to prevent particles of the injected paraffin from entering the circulation, or of using liquid paraffin or paraffin of a low melting point. Usually the remaining ill effects are abscess formation or sloughing due to infection at the site of injection, or to the poor constitutional condition of the patient who receives the injection. Patients who are victims either of syphilis in an active stage, diabetes or nephritis are unfavorable subjects for the paraffin operations.

Smith advises the use of paraffin with a melting point of 115° F., which he obtains by adding sufficient petroleum jelly or the liquid petrolatum known as albolene to commercial paraffin melting at 140° F., to bring it down to 115° F. This may be injected cold, and hence

reduce the danger of embolus formation. While many syringes have been devised for the paraffin injections, that of Smith (Fig. 420) seems the most practical and is the one the author has used. It has a screw piston which allows the paraffin to be injected cold, and the amount can be controlled to the fraction of a drop. The cup (Fig. 421) is for the purpose of preparing the paraffin. Smith lays down the following mode of procedure:—

Preparation of the Patient.—1. The nose and adjacent areas should be scrubbed with green soap and water. 2. The area should then be scrubbed with alcohol. 3. The head is then covered with a towel dampened with a 1 : 5000 solution of bichlorid of mercury, and the arms and shoulders are covered with a sterilized gown.

Preparation of Instruments and Operator.—Both the paraffin syringe, which is of metal, and the needle should be boiled. The paraffin, which comes in sterilized tubes, is again boiled in a metal cup,

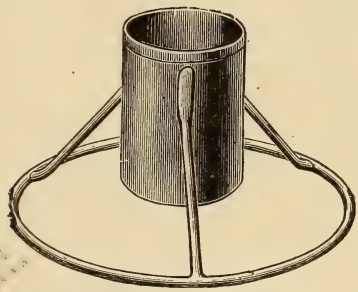

Fig. 421.—The paraffin cup.

which can be placed in any sterilizer, the bottom of the cup being raised sufficiently to prevent the paraffin from scorching. The paraffin is drawn up into the syringe in a liquid state, after which the syringe is dropped into a receptacle of cold sterilized water, which soon solidifies it. The hands of the operator and his assistant should be sterilized.

Methods of Injection.—No anesthetic is necessary, although some operators prefer cocaine locally injected. The injection of the cocaine is as painful as the paraffin injection. The patient should sit upon a stool of a height that, when the head is tilted backward, his nose is about on the level of the operator's elbow. The operator stands behind and to the left of the patient, and the assistant stands in front and slightly to the right of the patient. The assistant grasps the nose firmly with the balls of his thumbs pressed against the nasal bones, and with the tips touching only the root of the nose. In this way pressure is exerted along both sides of the nose and thus prevents the entrance of the paraffin into the areolar tissue around the eye, and also prevents it from entering the circulation, should the needle penetrate a small vein. The injection should be made from above downward, as this is the direction away from danger and toward nature's natural barrier, which is the adherence of the skin and cartilage of the tip and alæ of the nose.

Before introducing the needle, immerse it in hot water, and then give the piston several turns until the paraffin comes out in a hard cylindrical thread. The first few turns of the piston usually ejects an interrupted stream of paraffin mixed with oil and water, but, after a few turns, all the oil and water is expelled and the paraffin remains a solid block within the cylinder and needle of the syringe.

At the point of injection, the skin should be lifted high with firm pressure and the needle introduced beneath the skin and into the areolar tissue above the periosteum. The point of the needle is made to penetrate to a point just beyond the depression, where the injection

Fig. 422.—Photograph of a saddle-back nose, the result of external violence.

is begun slowly and is continued as the needle is gradually withdrawn. It is advisable to stop the injection from time to time and mold the paraffin to meet the requirements of the case. Meanwhile the needle is not withdrawn, but the syringe is held in place by an assistant. As a rule it is unwise to overcome the deformity with a single injection, but in many instances one injection proves sufficient. When anemia of the surface occurs, the injection should cease, as this is the danger signal that the tissue will stand no more.

The needle should be carefully withdrawn, and the hemorrhage, if there is any, controlled with adrenalin, after which the puncture point should be sealed with collodion. The patient should be advised to rest in bed for the remainder of the day, and to apply ice-cloths to the surface of the nose. When the paraffin melts at 115° F. and is injected cold, it enters the tissue as a hard mass, and cooling sprays are unnecessary.

A second injection should not be made under one month, inasmuch as nature can do no more than care for the first injection during this time, and any additional demand might result in necrosis.

In the author's opinion it is far preferable to inject too little paraffin than too much at the first sitting, inasmuch as an amount in excess of the requirements not only creates a new deformity, but is more liable to be followed by ulceration or other serious reaction.

Furthermore by injecting from above downward the paraffin is easily controlled and molded into its proper position with less danger of accidents.



Fig. 423.—The saddle-back deformity, shown in Fig. 422, has been corrected by an injection of paraffin.

A side-view photograph of a patient operated upon by the author by the paraffin method, in which the deformity was caused by external violence, is shown in Fig. 422. One injection proved sufficient to overcome the deformity (Fig. 423).

Carter, in correcting depressed or irregular deformities of the nose, makes a mechanical replacement by the use of a combined bridge and intranasal splint. The principle involved is mechanical and rests on the reconstruction of the broken-down nasal arch, the intranasal splints "one acting from within the nose at the apex, and the other from the outside of the base," thus restoring the former symmetry of a flattened nasal arch. Carter describes the apparatus and mode of procedure as follows:—

"The apparatus shown in Fig. 424 consists of a fenestrated steel bridge, the wings of which are connected by a hinge, and the

distance to which they can be separated is regulated by a thumbscrew. The edges of the wings are padded with rubber, and small holes near the edges permit the gauze padding to be stitched on. The second part of the instrument consists of two small, hard-rubber splints perforated by four small holes.



Fig. 424.—Bridge and intranasal splint for correcting depressed deformities of the nose. (*Carter,* with permission.)

"The application of the apparatus is as follows, assuming that there is a recent depressed fracture, or, in the case of an old deformity, that the tissues have been thoroughly mobilized by a previous operation to be described later: No. 14 iron-dyed silk is passed

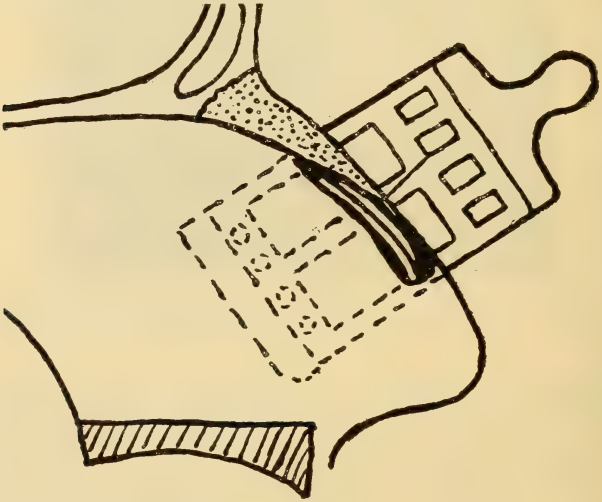

Fig. 425.—Sectional view of splint and bridge in place. (*Carter,* with permission.)

through one of the holes in the hard-rubber splint and knotted; the other end is threaded into a large curved needle; this is passed from within the nose through the cartilaginous dorsum just below its attachment to the nasal bones. This process is repeated on the opposite side. The bridge is then applied and the wings adjusted with the thumbscrews to give the proper support to the base of the

nasal triangle. The sutures are then run through the fenestræ in the bridge, corresponding vertically to their exit from the nose and drawn tight enough to lift the dorsum into its proper position. The sutures are then tied together over the hinge. There should only be sufficient tension to support the bridge. The diagram (Fig. 425) shows the bridge and splint in position. The splint rests partly un-

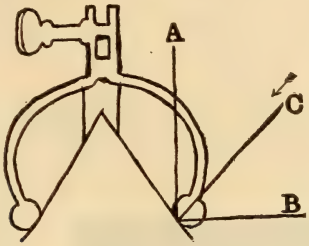

Fig. 426.—Illustrating the mechanics of the intranasal splint and bridge. (*Carter,* with permission.)

der the nasal bone and partly under the cartilaginous dorsum. The result of pressure and counterpressure keeps the apparatus in position; it should be worn for ten days or two weeks.

"The respiratory function of the nose is not interfered with after the first two or three days, and the patients do not complain of great discomfort while wearing the apparatus. It is better for

Fig. 427.—The primary incision for dissecting a flap from the floor and septal side of the meatus. (*MacKenty,* with permission.)

the patient to remain in bed during the treatment, but if the bridge is anchored to the forehead with adhesive plaster he may sit up.

"According to Treves, in uncomplicated fractures of the nose, there is fixation in eight days and bony union in two weeks.

"The mechanics of the apparatus is shown in the diagram (Fig. 426). *A* represents the downward pressure applied to the base of the nasal triangle and is produced by the tension of the sutures passing through the dorsum of the nose; *B* shows the horizontal pressure under control of the thumbscrew. The resultant force—that actually applied at the base—is represented by a line, *C*, bi-

secting the angle formed by *A* and *B*, and is the proper direction to support the base of the nasal triangle. A combination of this downward and inward pressure applied at the base and the balancing upward pull at the apex of the nasal triangle when applied to a nose in which the bony framework has been mobilized will tend to construct a normal symmetrical organ. This I have demonstrated on the cadaver as well as on the living subject."

The Carter operation is particularly applicable to cases where there is a tendency to broadening of the nose, owing to the spreading apart of the nasal bones.

Plates of rubber, silver and aluminum, etc., have been introduced surgically under the skin of the nose to correct the depressed or saddle-nose deformity, but usually they meet with little success on account of the unavoidable sloughing which ensues. Each deformity is a law unto itself, and no particular method is applicable to all cases. Refined surgical judgment is required to meet with success in any given case. In the *pinched-nose* deformity, paraffin injections along the floor of the vestibule have been recommended in Germany. The paraffin acts as a splint when set and so holds the wing of the nose outward.

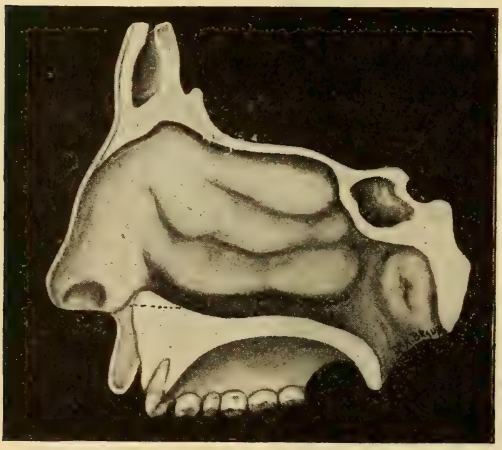

Fig. 428.—The dotted line illustrates the backward dissection across along the floor at the mucocutaneous junction. (*MacKenty,* with permission.)

The following operation for the *pinched nose* has been devised by Dr. J. E. MacKenty: "The operation aims to enlarge the anterior naris by lowering and widening its floor. This is done by dissecting up a flap (Fig. 427) from the floor and septal side, extending the dissection backward beyond the ridge of bone which crosses the floor at the mucocutaneous junction (Fig. 428).

"The bone ridge is then removed down to the level of the meatal floor behind. All redundant tissue is chiseled away from the base of the septum with scissors and forceps; all unnecessary tissue is removed from the flap, leaving only cuticle and mucosa. Then the flap is cut beginning high up on the septum and slanting backward to the floor (Fig. 429). This allows the flap to fall to the newly made floor, where it is stitched (Fig. 430). This leaves the denuded area (Fig. 430) on the septum, which reduces the subsequent contraction to a minimum. The air now freely passing

through the lower portion of the nostril obviates the valve action of the alæ nasi above."

In the "pound" nose deformity good results have been reported from the use of the high-frequency current and electrolysis. Where the nasal appendage is entirely wanting a false nose of rubber or celluloid, flesh tinted and held in place with spectacles (Fig. 431), affords such patients much satisfaction and comfort.

EPISTAXIS.

Epistaxis or bleeding from the interior of the nose is due to a variety both of local and constitutional conditions. It is common in children between the ages of five and fourteen, and rare during middle life. In old age it usually occurs as a result of some constitutional disease or local neoplasm. As a rule, when properly managed, nasal hemorrhage is not of serious import, except in

Fig. 429.—The flap has been dissected from the floor of the nostril. (*MacKenty,* with permission.)

Fig. 430.—The flap has been sutured to the line of the original incision. (*MacKenty,* with permission.)

hemophiliacs, in malignancy, or arteriosclerosis. According to Castlebury, in 90 per cent. of all cases of nasal hemorrhage the seat of the hemorrhage is in the anterior portion of the nasal septum.

Etiology.—The local causes of nasal hemorrhage are chiefly as follows: 1. Traumatism from intranasal operations; injuries both direct and indirect—falls, blows upon the nose, stab-wounds, etc. 2. Defects of the cartilaginous septum; contact of the dust-laden inspired air upon its convex surface, which in turn produces irritation and finally erosions and hemorrhage. 3. Atrophic rhinitis. Attempts to remove the inspissated crusts in this disease, by picking the nose, are prone to produce erosions upon the septum and turbinals and subsequent hemorrhage. 4. Acute rhinitis. In severe cases of acute inflammation of the nasal mucosa, hemorrhage is induced as a result of excessive blowing of the nose. 5. Varicose veins in the septal mucosa are prone to attacks of hemorrhage, even upon slight injury, or when acutely inflamed. 6. The presence of foreign bodies and sequestra in the nasal cavities is attended with varying degrees of hemorrhage. 7. Tuberculous or syphilitic ulcera-

tions and leprosy. 8. Malignant neoplasms, sarcomata and carcinomata (see Chapter XLII). 9. Perforating ulcer of the nasal septum. 10. Benign neoplasms, nasal polypi, fibromata, etc.

Epistaxis is of general or constitutional origin, as follows: 1. Febrile diseases: chiefly nasal diphtheria, scarlet fever, measles, pneumonia, typhoid and typhus fever, influenza, malarial and relapsing fevers. 2. Blood diseases: anemia, hemophilia, leukemia, purpura hæmorrhagica, chlorosis, scorbutus, and chronic malaria. 3. Diseases of the heart and vessels: valvular lesions, cardiac hypertrophy, Bright's disease, pulmonary emphysema, etc. 4. Cirrhosis of the liver. 5. The pressure of large tumors upon the blood-vessels of the neck. 6. Violent exertion. 7. Temporary sojourn in extremely high altitudes. 8. Vicarious hemorrhage from sudden suppression of the menstrual fluid.

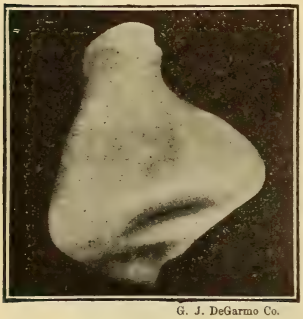

G. J. DeGarmo Co.

Fig. 431.—A false nose.

Diagnosis.—The diagnosis of nasal hemorrhage is based upon the appearance of a flow of blood from the anterior nares. Exceptions to this rule are found in those cases where hemorrhage which arises from the lungs, larynx, or pharynx, or from fractures of the cranial bones, flows from the nose. In patients recovering from anesthetics, or who for other reasons remain in a supine position, especially upon the back a continuous backward flow of blood, from the nasal passages into the pharynx, may be swallowed and discovered only upon the appearance of subsequent attacks of vomiting. More specifically, the diagnosis depends upon the discovery of the actual seat of the point of bleeding within the nasal cavities.

Treatment.—(*a*) *Local.* In a majority of the simpler cases sudden epistaxis is self-limited and no treatment is required. This is especially true of attacks which occur in young robust children. In cases of the above type the sudden attack is almost immediately followed by an equally sudden cessation of the flow of blood. Hence the loss of blood is immaterial. For some time subsequent to the attack, the patient should be advised against blowing the nose, or violent exercise. Prolonged hemorrhage, without evidence of constitutional disease or tumors, is usually amenable to local applications of adrenalin to the seat of the hemorrhage, or ice-packs placed upon the nose. Temporary pressure with tampons held tightly upon the bleeding point may control and terminate the hemorrhage. In severe cases a small syringeful of ice-water may be injected into the nostril, while at the same time the face is covered with a towel which has been immersed in ice-water, and the feet are immersed in hot water. Irrigations of hot water often are effective in controlling nasal hemorrhage. When due to a rupture of a septal blood-vessel and the attacks of hemorrhage are both frequent and prolonged, the bleeding vessel should be destroyed by means of an application of chromic acid

fused. Hypodermics of human or horse serum are now being employed for the control of persistent hemorrhage, especially in hemophiliacs. Thrombokinase, locally applied to bleeding surfaces, is employed at the Manhattan Eye, Ear and Throat Hospital.

Severe hemorrhage from blood-vessels which have been severed by intranasal operations, which do not subside in response to applications of adrenalin or the cold pack, require some sort of continued pressure. A small piece of Bernay's sponge or gauze packing usually is effective. A strip of gauze immersed in a solution of acetotartrate of aluminum of 12 per cent. and inserted into the nares not only induces pressure, but acts as an astringent upon the bleeding vessel. Furthermore, the antiseptic quality of the solution preserves the tampon, so that it may safely be left *in situ* for from twenty-four to forty-eight hours.

An available astringent to be applied is nitrate of silver in 5 to 20 per cent. solution. Violent nasal hemorrhage, when due to serious constitutional causes, and when not amenable to the above-



Fig. 432.—The Belocq sound.

named measures, requires a combination of postnasal and anteronasal plugging as a last resort. For this purpose a Belocq sound (Fig. 432) is introduced through the anterior nares and its spiral portion ejected into the pharynx. To the distal end of the latter a thread is tied and the sound gradually withdrawn with its thread attachment. A large tampon of absorbent cotton is then tied to the pharyngeal end of the thread, and the mass drawn upward into the epipharynx, and tightly against the choanæ. The anterior nares are then tightly plugged. This method of tamponing the nose and nasopharynx produces extreme discomfort to the patient and often induces attacks of purulent otitis media. Hemorrhage induced by the presence of foreign bodies in the nasal cavities usually subsides quickly upon their removal.

General Treatment.—Following a severe attack of nasal hemorrhage, or recurrent attack of epistaxis, especially when the loss of blood has been sufficient to produce extreme weakness and anemia, an enema or an intravenous injection of a warm saline solution should be administered and the patient should remain in bed for several days or weeks, depending upon the gravity of the symptoms. Fresh air, nutritious diet, and the internal administration of iodin combined with strychnia will hasten recovery. When due to grave constitutional diseases, such as Bright's disease, cirrhosis of the liver, or to malignant tumors, epistaxis becomes a grave and troublesome symptom, and special measures must be employed for its relief. In case of malignant growths, cauterization or the entire removal of the neo-

plasm offers the best results, while individuals suffering from the above-named constitutional diseases should be referred to internists for advice and treatment.

FOREIGN BODIES IN THE NOSE.

An almost endless variety of inanimate foreign bodies find lodgment within the nasal cavities. Young children are prone to insert small objects, such as shoe-buttons, pieces of cloth, peas, beans, seeds, hooks and eyes, pins, beads, etc., into the anterior nares. The most offensive foreign body which the author has removed from a child's nose was a section of school sponge, which had been inserted three months previously. Insane persons and idiots seem to possess an inordinate fondness for filling the anterior nares with any small objects or masses which may be at hand. A distinct type of intranasal foreign bodies is represented by bullets, shot, pieces of shells, the broken tips of knives, dirks and stilettos, and explosives. Finally, foreign bodies may find access to the nasal cavities by way of the nasopharynx as a result of vomiting, eructations, or sudden sneezing or coughing while in the act of swallowing.

Symptoms.—The symptoms are nasal hemorrhage (not constant), pain, nasal obstruction, dead voice, and, when the foreign body has remained for long periods, there is a unilateral, mucopurulent, fetid discharge, and excoriation of the borders of the nostril and upper lip. Upon examination the obstructive mass is observed in the nasal cavity.

Diagnosis.—In addition to the history and symptoms above described, the diagnosis depends upon the exclusion of nasal polypi, tumors, sequestra of bone, and indurated ulcerations. Rhinoscopic examination, with bright illumination, preceded by an application of adrenalin to the nasal mucosa, and aided by the touch of a probe, usually reveals the foreign body.

Treatment.—The following directions are recommended for the removal of foreign bodies from the nasal cavities, viz., spray the nasal mucosa with a solution composed of cocaine, 4 per cent., and adrenalin, 1:5000, twenty minutes before the operation.

Under ample illumination and with nostril widely dilated, grasp the object with strong forceps and carefully withdraw it. When the object has an oval smooth surface, pass a slightly curved ring curet or hook beyond the body, then tilt the handle upward and drag it out. In case a child is intractable, or an adult is hysterical or extremely sensitive, and in every instance when the foreign body is deeply inserted or imbedded in the soft tissues or bone, the operation should be performed under general anesthesia. External operations are sometimes imperative for the removal of large, deeply imbedded foreign bodies.

PARASITES (MAGGOTS, SCREWWORMS, FUNGI, ETC.).

The nose is rarely the habitat of parasites in temperate or cold climates, but in tropical countries a considerable variety of para-

sites, such as maggots, screwworms and various fungi are found in the nasal cavities of the natives, especially those of fifthy habits. From the cases reported by Goldstein, Foster and Steele, it would appear that larvæ in enormous numbers hatch from the eggs which are deposited in the nasal cavities by certain flies, and, furthermore, that the offending flies are usually attracted to the nasal cavities by the presence there of specific necrosis, ozena and similar affections. The screwworm and maggots are the chief varieties.

Symptoms.—The organisms give rise to sensations of heat, itching, pain and sneezing, and later to intense inflammation of the nasal mucosa, serosanguineous discharge, and, finally, in case they burrow into the tissues, to external swelling.

Treatment.—The larvæ must first be killed by injecting a dilute (25 per cent.) solution of chloroform into the nasal chambers, after which they should be removed by means of curet or forceps, and the nasal douche.

RHINOLITHS.

Rhinoliths generally depend upon some foreign body, which serves as a nucleus around which the concretion forms.

Treatment.—When of small size and conveniently located, the removal of a rhinolith is a simple procedure. Under cocaine anesthesia, aided by bright illumination, the mass should be grasped with a suitable forceps and withdrawn. Rhinoliths of large dimensions should be removed under general anesthesia. It is sometimes necessary to crush the mass and then remove the fragments piece by piece, in which event no portion of the rhinolith should be allowed to enter the larynx.

NASAL FURUNCULOSIS.

Furunculosis of the nasal cavities is characterized by the appearance of a circumscribed, painful swelling in some portions of the cutaneous lining of the vestibule, which eventuates in abscess formation.

Etiology.—They are caused by pyogenic micro-organisms, usually the Staphylococcus, which gain access into the subcutaneous tissues through the hair follicles, the sudoriparous glands, or from traumatism. Picking the nose is a prolific source of this affection. They are more commonly found among the ill-nourished and those who have become exhausted by overwork or disease.

Treatment.—In the author's experience it has been practically useless to incise these abscess formations about the nasal orifice, at least until they actually point. Even then the relief is not marked until the entire slough commences to separate and disintegrate. At the very commencement of abscess formation the entire surrounding surface should receive one thorough application of iodin in order to destroy surface infection and to prevent recurrence. During the entire course of a nasal furuncle an attempt should be made to preserve cleanliness of the surfaces. Whenever the abscesses persistently recur the author advises a thorough course of treatment by means of autogenous vaccine.

CHAPTER XLI.

NASAL NEUROSES.

Two general types of nasal neuroses are herein considered: 1, sensory (neuroses of olfaction); 2, reflex neuroses.

SENSORY (NEUROSES OF OLFACTION).

The various types and degrees of sensory neuroses are classified as, 1, anosmia; 2, hyperosmia; 3, parosmia.

ANOSMIA.

Anosmia is the term commonly employed to define a partial or total loss of the sense of smell.

Etiology.—Temporary anosmia is a common symptom of ordinary "cold in the head," in which event it is due to the swelling and engorgement of the intranasal mucosa and the consequent obstruction to the free access of air into the nasal passages. In the more severe types of intranasal inflammation, especially when due to grippe, measles, nasal diphtheria and scarlatina, the loss of smell may be prolonged and even permanent.

Any form of prolonged nasal obstruction may cause impairment of olfaction. Nasal polypi, septal deviations, enlarged middle turbinals, tumors and extensive hyperplasia are the chief obstructive lesions concerned in impairment of the sense of smell. Certain nasal diseases, by interfering with the nerve endings, are prone to induce anosmia.

The chief of these are atrophic rhinitis, purulent rhinitis, disease of the accessory sinuses, syphilitic and tuberculous lesions. Furthermore, anosmia may be induced by traumatism, noxious inhalations, and the use of harmful drugs. Usually it is bilateral, but it may be unilateral.

Prognosis.—The prognosis is favorable except in cases where the anosmia is the result of deep-seated pathological changes in the mucosa, or to lesions involving the trunk of the olfactory nerve. In recent cases, when due to intranasal obstructive lesions, full recovery may be expected.

Treatment.—The underlying cause should be determined and eliminated.

Obstructive Lesions.—The treatment of obstructive lesions, the different forms of rhinitis, and of the affections of the nasal accessory sinuses has been fully defined in the foregoing chapters.

The internal administration of strychnine sulph., gr. $\frac{1}{50}$, three times daily, and potassium iodid, gr. 15 to 30, daily, and local cleansing of the intranasal mucosa with bland alkaline solutions are measures deserving of commendation.

HYPEROSMIA.

The term hyperosmia is employed to denote a morbidly acute sensitiveness to odors, or, in exaggerated cases, to positive olfactory illusions.

The affection is usually a manifestation of hysteria, neurasthenia, and sexual or menstrual disturbances. In the treatment of these cases the aim should be to correct the underlying cause.

PAROSMIA.

The term parosmia denotes a perversion or hallucination of the sense of smell. There are two general types of the affection—one a perversion of a normal odor, and the other a wholly imaginary odor. Both are usually most disagreeable (cacosmia) and evoke serious complaint on the part of the patient. It is a common hallucination among the insane, and occasionally is observed in epilepsy and hysteria.

REFLEX NEUROSES.

1, Hyperesthetic rhinitis (hay fever); 2, asthma; 3, nasal hydrorrhea; 4, cerebrospinal rhinorrhea; 5, epilepsy of nasal origin.

HYPERESTHETIC RHINITIS.

Synonyms.—Hay fever, rose cold, vasomotor coryza, catarrhus æstivus.

This disease is commonly known as hay fever, hay asthma, June cold, rose cold, summer catarrh, etc. It is the chief of the respiratory neuroses and occurs principally in patients of the neurotic type. It may be defined as an inflammatory condition of the nasal mucous membranes, usually periodical in its advent, appearing at yearly intervals and is characterized by a severe coryza accompanied with asthmatic symptoms. Extremely hyperesthetic areas on the nasal mucosa can be localized.

Etiology.—This disease was well known in older medical times, but during the past century it has received much attention at the hands of both the general practitioner and the rhinologist, who have evolved many theories and speculations regarding its etiology. Without recounting the numerous experiments carried out the etiological factors may be divided into the predisposing and the exciting causes.

Pathology.—Other than the evidence of a catarrhal inflammation during the attack, no special lesion exists. The special hyperesthetic areas of the nasal mucosa are chiefly at either the anterior or posterior ends of the inferior turbinal bones and the adjacent septal regions, and sometimes along the median portion of the middle turbinals. At these points the terminal nerve filaments are closer to the surface of the mucosa, either anatomically or else as a result of epithelial desquamation. Hence, the exposure of the terminal nerve ends exposes them unduly to the excitants already mentioned.

Symptoms.—Most cases occur in the summer and fall, and usually are repeated annually. The psychological element or that of associate ideas is strong, and such patients can predict to the day the time of onset of an attack. The usual symptoms, viz.: a severe rhinitis, itching of the nose, violent sneezing followed by a profuse watery discharge from the nostril, which often excoriates the lip, are met with in all cases. The turgescence of the soft parts

blocks up the nose. Accompanying these nasal symptoms is a stinging and burning sensation of the conjunctiva, photophobia, lachrymation, puffing of the eyelids, with ocular or neuralgic pain chiefly in the back of the head. The nasal discharge later becomes mucopurulent, and at times a pseudomembrane forms which causes nasal bleeding upon its removal. The accessory sinuses possibly partake in this turgid condition of the mucosa, since the patients frequently have violent pain over the nasal bridge (ethmoid region) and over the frontal sinuses. Many have temporary loss of the sense of smell and taste, tinnitus aurium and temporary deafness from the extension of the catarrhal process to the Eustachian orifices and the nasopharynx. The system in general is involved by the interference in metabolism, by digestive and secretory disturbances, pyrexia and chills. Malaise and bodily prostration and mental hebetude have been known to accompany severe attacks. The onset is usually sudden, yet in some cases mild local premonitory symptoms arise. Asthma symptoms occur in about one-half of the cases, usually the severer ones, probably as a result of the turgescence of the laryngeal and bronchial mucous membranes. The asthma may either accompany or follow the catarrhal symptoms and in some of the severer cases the attacks may eventuate in true asthma. During an attack of hay fever the hypersensitive areas in the nose can be located with a probe.

Prognosis.—The disease of itself is not fatal, and a small proportion of cases recover as a result of treatment. In others the disease disappears after the fortieth year. After a severe and prolonged attack the patient may easily acquire any critical ailment.

ALLERGY AND POLLEN THERAPY IN HAY FEVER.

Seasonal hay fever has been grouped as an allergic disease due to pollen proteins. The disease manifests itself, therefore, whenever a patient receives a dose of pollens from pollenating plants. Blackley, in 1865, made the first skin test to pollens for hay fever, but could not progress because nothing was known of immune reactions. The work of Goodale, 1914, Selfridge, Scheppegrell, Oppenheimer, Gottleib, Hull, Walker, and Cooke, have shown the relationship of the pollens to the seasonal type of hay fever. Cooke and Cocoa were unable to prove this relationship as a form of anaphylaxis; however, Parker has recently shown that this relationship is in the form of anaphylactic shock. Hay fever is not a local disease of the ear, nose and throat, it is a general condition and operations upon the nose will not cure sensitization hay fever. Well advised operations will give relief in those cases where there is a nasal obstruction and poor breathing space. In these cases operation is always advised but the operation will not alter the general condition of pollen sensitization.

The symptoms of hay fever are usually manifested in the eye, ear, nose and lungs, because the pollen dusts fall upon susceptible mucous surfaces and does not effect the skin which is impervious. However, itching, redness and swelling can be produced in an open

skin wound upon any part of the body if the pollens come in contact with the wound, proving the disease is a general condition and not a local disease. This principle is used in determining which pollen is responsible in each individual case. Hay fever victims invariably manifest such general symptoms as nervousness, irritability, depression and weakness.

Hay fever may be of the early spring, late spring, and fall type and is usually due to some form of wind-borne pollen. In most instances the pollen responsible is easy to detect. However, in rare instances the problem is not so simple. When a patient has been tested and the pollen to which he is sensitive is found, the patient is desensitized. If several pollens are responsible for the disease they are combined in the proportion to which the patient reacted and the mixture is used in treating the case. Some observers recommend instead of an autogenous mixture a stock one or the use of the pollen giving the strongest reactions, which usually is timothy pollens in the late spring, and ragweed in the fall types.

Hay fever during May, June and July has incorrectly been called rose cold. Roses rarely cause this condition, as rose pollens are heavy and cannot be as easily transported by the wind. This is not true of the pollens of red top, timothy, orchard grass and June grass. These are the ones usually responsible for the summer hay fever. The August and September types of hay fever have popularly been accredited to goldenrod pollens, but tests show that 90 per cent. of the autumnal hay fevers in the Eastern States are due to ragweed pollens.

Diagnosis.—In the hay fever clinic at the Manhattan Eye, Ear and Throat Hospital routine tests are made for each patient at the beginning of his case using the dry pollens as suggested by the seasonal history of the patient. Tests are made by the cutaneous or intracutaneous application of the suspected pollen. The reaction produced, if the patient is sensitive, appears in about 10 to 20 minutes and consists of an ameboid urticarial wheel and an adjacent zone of erythema. When a patient has been tested and only one pollen is found responsible for the patient's disease, an extract of this pollen only is used in the desensitization of the patient. If the patient reacts to several pollens, an extract is made containing the pollens in the proportion as indicated by the reactions and this combination is used in the treatment.

Treatment.—The modern accepted way to treat these patients is by desensitization and immunization against the exciting pollens. The rationale of this is based upon the following fundamental biological test: A protein sensitive animal, when injected with a sublethal dose of protein, will manifest mild symptoms of shock and if it does not die will not react to a subsequent larger dose of the same protein. This refractive period has been called "the period of desensitization and anti-anaphylaxis." This period is temporary only, as the animal again becomes sensitive after an interval of time. This occurs in hay fever treatments, the patient will experience a brief period of relief from the injections. For this reason

the treatments should be so scheduled that a patient is getting injections up to the time of the hay fever season. If this brief period of relief were the only value of the injections it would hardly seem worth while. A dual effect is obtained from the injections, and this is in the nature of a permanent immunization to the pollens, as some of the hay fever cases are permanently cured with one series of treatment while in the remaining number there is a decreased sensitization to the protein and the patient can receive much larger doses in the treatment the second or third year.

Pollen extracts are prepared in the laboratory for the treatments and diagnosis of the hay fever cases. The technique used in preparing the pollens is briefly as follows: 1 gram of dried pollens is made into a paste with the aid of 6 drops of a 15 per cent. sodium hydrate solution, and placed upon a freezing microtome, frozen and cut with the microtome knife. This is repeated three times. The mass is then extracted for one week at 37° C. with 100 c.c. of sterile water. The sodium hydrate present in the paste results in a slightly alkalinized solution. After incubation the extract is neutralized and passed through a Berkefeld filter and enough phenol added to the filtrate to make a 0.25 per cent. solution. The filtrate obtained in this manner contains more pollen protein than we have been able to secure by any other technique. This gives a solution containing 0.1 to 0.4 milligrams of nitrogen per 1 c.c.

In the treatment of cases undiluted extracts are used. This is done by employing a tuberculin syringe, giving 0.01, 0.03, 0.05, 0.07 and upwards to 1 c.c. of solution containing 0.1 mg. or 100 units per 1 c.c. Injections should always be given in the same arm upon which the treatment was begun. The reason being that the earlier and smaller doses produce local tolerance and hence less reaction is experienced. Treatments are given intravenously to those cases that have been under treatment for some time and which have received the maximum dosage of 1 c.c. subcutaneously. The first dose intravenously being 0.01 of the same dilution used subcutaneously and the dosage increased as indicated by the reactions of the patient. The intravenous method is not without some reactions in some cases, but the results in these cases have been gratifying. The intravenous administration of antigens in desensitization treatments should not generally be advocated, and further experimentation is necessary with this method of treatment. The following results have been obtained in 130 cases of treatment as above indicated:—

	Total relief Per cent.	Some relief Per cent.	No relief Per cent.
1st year	7	63	30
2d year	11	64	25
3d year	21.6	69.4	9

Perennial Hay Fever.—Some patients give no history of seasonal periodicity, suffering at irregular intervals throughout the year. It requires real detective ingenuity to determine the cause in these cases. The causes are many; some are due to foci of infection, particularly the intestinal tract. Endocrine dysfunction is

the etiological factor in some cases while others are due to protein sensitization, the proteins and animal emanations. Occupation frequently gives a clue to the etiology. This is illustrated in the case of a man, age 35, who had been suffering from sneezing and itching, conjunctival and asthmatic attacks for years without seasonal recurrences. His occupation was that of a baker, but he had been unable to do his work for a year; the mere passing of a baker-shop would precipitate an attack of hay fever. With this history, food proteins were used in testing him. The patient reacted violently to wheat, rice, barley, rye, flour, oats and corn meal. The mere testing of the patient by the cutaneous method precipitated a violent attack of hay fever. In the above case search for the etiology was simple enough but not so in all cases, and not infrequently the cause is never found. Many cases of rhinorrhea are tested for sensitization at the hospital and sensitization is apparently responsible for about 10 per cent. of the cases examined.

Under the above caption (also see Asthma) the author presents a brief resumé of the results of the work being carried on at the laboratory of the Manhattan Eye, Ear and Throat Hospital under the supervision of Dr. Andrew A. Eggston. Dr. Eggston's recent publication[1] is herein freely quoted.

In the more obstinate cases it may be necessary to use cocaine or alypin in a normal salt solution from 4 per cent. to 10 per cent. combined with adrenalin chloride in 1:10,000 to 1:2000 dilution. When cocaine is selected it should be used by the surgeon at proper intervals, and should not be left in the hands of the patient on account of the danger of habit formation. In certain individuals who are suffering from hay fever, applications of adrenalin solution to the nasal mucosa induce violent sneezing and otherwise aggravate the disease. Insufflation of drugs in powder form is condemned; the drug particles act as irritant foreign bodies on the nasal mucosa, and increase rather than relieve the distress. Since hay-fever patients have a more or less neurotic taint, tonics must always be included in the general treatment. The author prefers a combination of iron, quinine, arsenic and strychnine, which may be dispensed either as an elixir or in pill or tablet form and in doses suitable to the case.

ASTHMA.

Asthma is described in Chapter XXXII, on General Diseases.

NASAL HYDRORRHEA (IDIOPATHIC RHINORRHEA).

The term defines a rare nasal phenomenon, the chief characteristic of which is a copious discharge of viscid, opalescent fluid which contains mucin. The fluid is usually intermittent and absent during the night. According to St. Clair Thompson, "the addition of either alcohol or acetic acid throws down a stringy precipitate like mucin. On boiling the precipitate with dilute sulphuric acid, a reducing sugar-like material, mucin is formed. The fluid contains a small

[1] Transactions of the Section of Laryngology of the New York Academy of Medicine.

amount of protein, coagulable by heat; it does not reduce Fehling's solution. Proteoses and peptones are absent. The alcohol extract of the fluid contains no reducing substance. The presence of mucin and the absence of the reducing substance are quite sufficient to distinguish this fluid from normal cerebrospinal fluid."

Etiology.—The cause is not well known, but it is probable that several conditions, mostly neuroses, are causative factors.

Symptoms.—There are no characteristic symptoms save the periodical flow of fluid from one or both nostrils, which reacts to the tests described above. Handkerchiefs soaked with the fluid become stiff upon drying.

The attacks are commonly accompanied by malaise, sneezing, and irritation of the skin about the nostrils.

Treatment.—There is no specific treatment. As a rule the disease is self-limited.

CEREBROSPINAL RHINORRHEA.

We are indebted to St. Clair Thompson (1899) for his analysis concerning the diagnostic character of the rare affection known as cerebrospinal rhinorrhea, or the escape of arachnoid fluid from the nose. He (Thompson) favors the theory that the phenomenon results from intracranial pressure. Out of 21 recorded cases cerebral symptoms were noted in 17 and retinal changes in 8. The flow usually is unilateral and exudes through the cribriform plate. The methods of testing the fluid in suspected cases are:—

1. The fluid is perfectly transparent, and contains no sediment. 2. It is faintly alkaline in reaction, and either tasteless or slightly salt. 3. The specific gravity is between 1005 and 1010. 4. It is not viscid, and gives no precipitate (mucin) on adding acetic acid. 5. On boiling there is not more than a trace of coagulum of serum globulin and serum albumin. 6. Cold nitric acid gives a precipitate which disappears on heating, and separates again on cooling. 7. Saturation with magnesium sulphate should give a precipitate. Saturation with sodium chloride should also produce a precipitate. Ammonium sulphate should be tried if the above salts fail. 8. The liquid should give a pink color with a trace of copper sulphate and excess of caustic potash. 9. When boiled with Fehling's solution there should be a reduction of the copper. 10. The reducing substance may be obtained by evaporating to dryness an alcoholic extract of the fluid. It is then found in the form of needle-like crystals. 11. The aqueous solution of this residue does not ferment with yeast. There is no definite treatment known.

EPILEPSY OF NASAL ORIGIN.

Cases of petit mal and of epilepsy of supposedly nasal or postnasal origin are reported in rhinological literature from time to time. In some cases the attacks date from some intranasal operative procedure, and others have been associated with various intranasal diseases. The author has reported one case of petit mal (see Chapter XLII) in a child, which subsided since the removal of a large polypus from the inferior turbinal.

CHAPTER XLII.

NEOPLASMS OF THE NOSE.

NEOPLASMS of the nasal passages, barring myxomata, are rare, but the usual varieties, both benign and malignant, occur in the following forms:—

BENIGN NEOPLASMS.—Myxomata, papillomata, fibromata, angiomata, enchondromata, osteomata.

MALIGNANT NEOPLASMS.—Sarcomata, carcinomata.

BENIGN NEOPLASMS.

MYXOMATA OR NASAL POLYPI.

Myxomata or edematous nasal polypi are the most common of all intranasal neoplasms. According to Woakes, the edematous mucosa is but a symptom of an underlying disease of the bone. Lack describes it as a "localized edematous infiltration of the nasal mucous membranes the result of osteitis of the underlying bone." Parker defines a nasal polypus as a "localized inflammatory edema of the mucoperiosteum of the ethmoid region inseparably associated with past or present disease of the bone" and questions the propriety of classifying them as new growths. They are oval, smooth, pedunculated or sessile gelatinous-appearing masses of varying size and contour. They are grayish or pink in color, and usually spring from the middle turbinal, the ethmoid, or more rarely protrude from the infundibulum, the sphenoidal ostium or the ostium maxillare. In rare instances they are attached to the inferior turbinal or the nasal septum. As a rule, nasal polypi are multiple. They may entirely fill the nasal cavity and even project into the postnasal space, where they are prone to reach enormous size (Fig. 355); occasionally they cause external deformity by spreading the nasal structures. The visible polypus often is but a portion of a general polypoid degenerative process, which has invaded the mucosa of one or more of the nasal accessory sinuses. It is now known that polypi which project through the nasoantral orifice have their primary seat in the mucosa of the maxillary antrum. The recent investigations of Killian bear directly upon the relation of this form of polypi to antral disease. The term "nasoantral polypi" has been suggested for this type. Furthermore, upon careful inquiry, a history of previous attacks of purulent sinusitis is obtainable. The symptoms of frontal headache and ethmoidal pain tend to verify this view. There are exceptions to this rule in which the pedicle of the polypus is attached to the inferior turbinal or septum.

Nasal polypi are rare under the age of puberty. In children they are usually located upon the inferior turbinal and are prone to recur. The author has reported the following case:—

W. A., aged 8, an undersized boy with a specific family history, had complained for some months of difficulty in nasal breathing, and his parents, deeming the cause to be adenoids and hypertrophied tonsils, sought relief. Upon examination it was found that he had a large tumor occupying the postnasal space, with an attachment at about the junction of the middle and posterior portions of the left inferior turbinal. Under ether anesthesia this growth was removed in the following manner:—

After several ineffectual attempts to surround the mass with a large wire loop, introduced through the nostril, a simpler procedure was employed, namely, with a pair of strong clipping forceps the pedicle of the growth was grasped and severed. The growth then fell backward into the nasopharynx, and was withdrawn through the mouth. The child was not well nourished, had Hutchinson teeth, and had been subject to frequent attacks of petit mal. The growth was examined by Dr. Jonathan Wright, who found it to be an ordinary edematous polypus. Dr. Wright further observed that, so far as he knew, it was the youngest case on record, and that recurrence was more frequent in the very young. After one and one-half years the growth had reappeared, and was fully as large as the former one. It was removed by the same method as that previously employed, with the exception that a considerable section of the inferior turbinate bone was cut away, hoping thereby to eradicate the source of the tumor and prevent its recurrence. The second removal was followed by a marked diminution in the frequency of his attacks of petit mal. After a lapse of two years there was no recurrence of the growth, his attacks of petit mal had disappeared, and his general health and appearance had improved.

Pathology.—Pathologically, nasal polypi are usually fibromyxomata rather than myxomata, inasmuch as they are composed of edematous mucous membrane, intermingled with inflammatory products. The surface or sac is covered with epithelium and is supplied with blood-vessels and scattered nerve filaments.

Symptoms.—The symptoms of nasal polypi are chiefly referable to the nasal obstruction which they produce. Inasmuch as these neoplasms are commonly associated with inflammatory affections of the nasal accessory sinuses, the symptoms are necessarily more or less complicated. Pedunculated growths, which hang more or less loosely in the nasal cavity and hence are movable, produce a sensation of a foreign body in the nose. As a rule they give rise to a watery discharge, especially in damp weather or during the course of attacks of simple acute rhinitis. The voice is materially affected, its timbre diminished, and when the obstruction is extensive it has a pronounced nasal twang. A variety of distressing reflex symptoms are provoked by polypi of large dimensions, especially when they are bilateral, the chief of which are mouth breathing, rhinorrhea, cough, asthma, anosmia, aprosexia and sneezing.

Diagnosis.—The diagnosis is never difficult, and is based upon the appearance within the nasal chambers of the gelatinous-like masses, which may be single, multiple, pedunculated or sessile. They vary in size from a millet seed to those which fill the nasal chamber and a large portion of the postnasal space.

Treatment.—The form of operative procedure required for the eradication of nasal polypi depends upon the location of the growth or growths, the activity of the inflammatory process, and whether these growths are a part of an associated osteitis or purulent sinusitis. A single, pedunculated polypus, unaccompanied by pus dis-

charge, thus indicating the cessation or absence of disease of the underlying bone, may be removed without the necessity of interfering with the bone to which it is attached. In case one or more edematous polypi are attached to the surface of the middle turbinal, or are found to project from the ethmoidal cells or one or more of the nasal accessory sinuses, a more radical procedure becomes necessary, which must include a complete removal of the associated disease of the bone and its coverings.

In order to clearly define the surgical significance of the more common locations of nasal polypi, it may be stated that (*a*) polypi having their origin upon the free surface of the middle turbinal indicate that at most the underlying disease does not extend beyond the anterior ethmoidal cells. Polypi which project from the spaces above the middle turbinal usually have their site of origin in the posterior ethmoidal cells. (*b*) Polypi which occupy a position between the inferior and outer surface of the middle turbinal and the outer nasal wall, originating in and about the region of the hiatus semilunaris, represent a type which usually springs from the frontal sinus, maxillary antrum, or anterior ethmoidal cells.

Finally, the rare locations are upon the inferior turbinal and nasal septum.

Surgical Technique. *Preparation of the Patient.*—The intranasal surfaces should be prepared for operation in a manner similar to that described for operations upon the middle and inferior turbinals (see Chapter XXXVI), except that the employment of adrenalin should be avoided on account of the remarkable shrinking of the growths which is caused by this drug. The employment of adrenalin is permissible during the later steps of the operation to control hemorrhage. Cocainization of the areas to be approached should be as complete as possible.

Operative procedures must vary in accordance with the site of the tumor, its extent and the nature of the underlying disease which latter is present in a large proportion of all cases.

Simple Operation.—This term is meant to define the operation which suffices for the removal of polypi alone, whether located in the nasal cavities or extending into the postnasal space. The wire snare (Fig. 351) is best adapted for the removal of polypi which are located in the nasal cavities. Numerous snares have been devised for this purpose since Jarvis first introduced this method of operation. The rhinologist should select the snare which is best suited to his mode of technic.

The snare loop should be introduced into the nasal cavity under bright illumination and so manipulated that its loop is carried around the tumor and made to engage the entire mass. An assistant may be instructed to hold the nasal speculum. When large tumors are encountered and the loop has been carried partially over the surface of the mass, that portion of the tumor which has already passed through the loop may be grasped with forceps, pulled forward and held firmly until the wire is thoroughly adjusted

around the pedicle. Thereafter the pedicle should be slowly divided by tightening the wire.

When it is known that the polypus projects through the orifice of an accessory sinus or from an ethmoidal cell, the snare may be adjusted around any portion of the growth so long as a firm hold of the tumor is secured. After tightening the wire upon the growth, traction should be made and the tumor mass pulled out. It often transpires that in so doing the mass finally pulled away from the cavities is far in excess of the small portion which has primarily been engaged in the loop (Fig. 433).

As a rule the operation is followed by slight hemorrhage, which quickly subsides. In case of multiple polypi the procedure should be repeated until all are removed.

Postnasal polypi are usually of large size and long standing. They are pedunculated, and as a rule spring from the mucosa of

Fig. 433.—The illustration shows the benefit to be gained by traction rather than by severing the polypoid mass.

the middle turbinal, but the site of origin may be upon the septum or the inferior turbinal.

In another method which has its advocates a large loop of wire is projected through the nostril into the nasopharynx. The loop is then manipulated by the index finger of the operator inserted into the postnasal space until it has been made to surround the growth. Still holding the wire loop in position, an assistant is instructed to insert the distal ends of the wire through a snare cannula and to tighten the wire until the pedicle has been severed. The author strongly recommends the method heretofore described, whereby the pedicle of the polypus is severed and the tumor withdrawn through the mouth. Fig. 434 illustrates a large gelatinous polypus which was removed from the nasopharynx by severing its attachment (pedicle) from the middle turbinal.

The Removal of the Polypi when Associated with Underlying Bone Disease or Polypoid Degeneration of the Mucosa of the Accessory Cavities.—These conditions have received due attention under the appropriate headings in the preceding chapters.

After-treatment.—When considerable hemorrhage follows the operation, it is usually easily controlled by slight pressure with a

section of sterile gauze which has been immersed in a solution of adrenalin 1 : 5000. Otherwise it is rarely necessary to leave any dressings in the nasal cavities. The subsequent treatment consists of cleansing alkaline sprays, night and morning, for eight or ten days. Before discharging the patient the nasopharynx should be carefully inspected by the surgeon, in order to determine that no recurrence has taken place.

PAPILLOMATA.

True papillomata rarely are found in the nasal cavities. They occasionally develop in the vestibule or the free surface of the inferior turbinal and the anterior and lower portion of the septum. On account of their small size they produce few symptoms.

Fig. 434.—Large mucous polypus, exact size, removed from the nasopharynx by severing its attachment (pedicle) from the middle turbinal.

Treatment.—A pedunculated papilloma, wherever located, should be excised by means of snare or scissors, and its base cauterized with fused chromic acid, nitric acid, or the galvanocautery. Occasionally they are sessile and extremely small, in which case they are conveniently destroyed by means of galvanocauterization.

FIBROMATA.

Intranasal fibromata are of exceedingly rare occurrence. Usually they spring from the septum, turbinate bodies, or the floor of the nares, but cases have been reported of fibromata arising from the periosteum in other portions of the nasal chambers, especially the lateral nasal wall. They occur as sessile growths or singly, and are made up of dense fibrous tissue which contains large blood-vessels.

Symptoms.—The chief symptom is nasal obstruction, which is usually attended with mucopurulent discharge. As the growth increases there is considerable pain, the discharge becomes mucopurulent, and external deformity of the nose may result. In extreme cases nasal respiration becomes impossible, and anosmia and headache appear. Ulcerations are common, and death may finally result from exhaustion, or on account of the extension of the growth into neighboring vital

structures. The latter symptoms are avoided by timely surgical interference.

Prognosis.—The prognosis is usually favorable in cases which are subjected to surgical interference, although recurrences are common.

Treatment.—Complete surgical removal constitutes the only feasible treatment for fibromata of the nasal passages. The method employed depends upon the character, location and size of the growth. The cold-wire snare is suitable for the removal of growths of small size. It is important that both the snare and the wire loop should be of sufficient strength to cut through the dense fibrous tissue. Advanced cases where the growth has become too extensive to be removed by means of the cold-wire snare should be removed piece by piece, or by some form of external operation. Of the external operations that known as Langenbeck's is the one in common use. The removal of fibromata is invariably attended by free hemorrhage, and in every instance the base of the growth should be thoroughly seared over with the galvanocautery. In the after-treatment the usual cleansing remedies should be employed.

ANGIOMATA.

Angiomata of the nasal cavities occur with extreme rarity. They are characterized by the appearance upon the nasal septum of vascular excrescences, which are usually sessile in character, of variable size, but rarely larger than a hickory nut. They are extremely vascular and hemorrhagic. They are rarely painful, and the chief symptoms are nasal obstruction and hemorrhage.

Treatment.—Two methods of treatment are in vogue: 1. Strangulation. 2. Enucleation.

Strangulation is produced either by means of a cold-wire snare or a galvanocautery snare. In the former the growth is enucleated by slowly tightening the wire loop. Sufficient time should be employed to strangulate rather than to suddenly sever the blood-vessels surrounding the growth. When the galvanocautery wire loop is employed, the same result is produced by coagulation from the heat.

Enucleation is accomplished by extending a circular incision through the mucochondrium, entirely around the growth. The incision should be made at a slight distance from the base of the growth. The entire mass, including the perichondrium, is then peeled away from the septum. During the time required for the subsequent healing the nasal passages should be kept clean by the use of alkaline sprays.

ENCHONDROMATA.

Cartilaginous tumors developing within the nasal cavities, barring septal spurs, are extremely rare. They spring from the septal cartilage and, when of large dimensions, produce nasal obstruction and pressure symptoms.

Treatment.—Surgical removal constitutes the only feasible treatment. Tumors of moderate size may be removed by intranasal

methods, but in rare instances external operation becomes imperative in order to enable the operator to expose and excavate the tumor.

OSTEOMATA.

Osteoma is a rare form of benign growth which usually develops in an accessory sinus and gradually projects into the nasal cavity. The frontal sinus is probably the most frequent seat of the disease, although cases have been reported of osteoma developing in the ethmoidal cells and the antrum of Highmore. Boenhaupt tabulated 23 cases of osteoma which developed in the frontal sinus. The growths may invade the cerebral, orbital or nasal cavities, and even cause marked external facial deformity. Osteomata are usually more or less pedunculated, of pinkish color, and are made up of dense, cancellous, bony tissue. In the spongy type there is usually a dense, bony surrounding capsule.

Symptoms.—Nasal obstruction is usually an early and prominent symptom. Pressure pains of a neuralgic character become prominent in proportion as the growth produces pressure upon the surrounding tissues. Finally secondary symptoms of deformity appear, chief of which are protrusion of the eyeball and widening of the nasal bones.

Treatment.—External operation offers the only hope of complete eradication of the disease. In rare instances wherein the growth is confined to the anterior nares it is possible to remove the growth intranasally, by means of chisel or drill.

MALIGNANT NEOPLASMS.

SARCOMATA.

Of the malignant neoplasms of the nose, sarcomata are the more common. They may develop in infancy, childhood or adult life. Rarely are they found in old age. The growths may spring from the turbinals, nasal septum, or the accessory sinuses. Of the latter the antrum is usually the seat of the disease.

Symptoms.—Mentioned in order, the symptoms are nasal obstruction and pain of neuralgic type, which usually manifests a tendency to radiate to the areas which surround the tumor. Recurrent epistaxis becomes a prominent symptom as soon as the surfaces of the tumor commence to ulcerate. A more or less continued purulent discharge accompanies the later stages of the disease. Finally, secondary symptoms appear, the chief of which are external deformities and intracranial involvement.

Diagnosis.—The chief diagnostic points are: nasal obstruction, the appearance in the nasal cavity of a large, broad-based fungus-like tumor of hemorrhagic type, moderate pain, and in advanced cases external deformities and symptoms of intracranial pressure. Finally, a positive diagnosis must depend upon a microscopic examination of a section of the growth.

Prognosis.—The prognosis is invariably grave, but less so than in carcinoma. Sarcomata in young children sometimes disappear

spontaneously. Early and radical removal of the growths constitutes the only known method for the eradication of the disease. So far the results of serum therapy (hereinafter mentioned) have remained unfavorable. In the majority of cases the disease terminates fatally.

Treatment.—As above mentioned, the treatment of this disease is essentially surgical. In rare instances only is it possible to successfully remove a sarcoma from the nose by intranasal operation. A small tumor springing from the anterior nares may be successfully extirpated intranasally. The removal of growths of larger size, especially when springing from the deeper portions of the nasal cavities or the accessory sinuses, requires extensive external procedures.

The removal of incipient small-sized sarcomata from the nasal septum or anterior portion of the lateral walls by the intranasal operation is prone to be followed by local recurrence. A recurrence of the growth should immediately be attacked with the dull curet or galvanocautery. While permanent recovery is not the rule, a small percentage of cases of sarcoma are curable.

Sarcomatous growths which have arisen from the deeper portions of the nares, or from the nasal accessory sinuses, are amenable to treatment only by external surgical operation. The Rouge operation heads the list of the external operations, and is favored because it produces no unsightly scarring of the face. It is performed by extending an incision along the line of junction of the mucous membrane of the under surface of the upper lip with the superior maxillary bone. The entire lip, together with the periosteum, is thus lifted upward with retractors. A second incision into the nasal cavities is then made, through the primary wound beneath the upper lip. Forcible retraction upward, together with a further separation of the periosteum from beneath, enables the operator to obtain a clear view of the nasal cavities, and to remove the entire growth. A considerable area of the surrounding healthy tissue should also be cut away, in order if possible both to eradicate and exterminate the neoplasm. The prevalence and severity of the hemorrhage during all operations for the removal of sarcomata requires the tamponing of the postnasal space as a preliminary measure.

Of the remaining external operations Ollier's, Langenbeck's and Dieffenbach's are worthy of mention. Ollier's operation consists in extending an incision to the bone along the line of attachment of the nose to the face, from the ala of one side upward, thence across the nasal bridge and downward to the ala of the opposite side (Fig. 435). The nasal bones are then divided from their attachment with a chisel or light saw, and forcibly turned downward, leaving a clear view of the deeper nasal regions. The growth is then removed as above described, after which the displaced bones and soft tissues are replaced and the external wound united with sutures. The bones should be protected from injury until readjusted by means of strips of adhesive plaster, or of suitable splints.

Treatment by the X-ray and by Serum Therapy.—The X-ray treatment of both carcinomata and sarcomata, when arising from the deeper portions of the nasal cavities, has proved most disappointing. A few favorable reports have appeared in literature, but authentic reports from authors of wide experience are almost invariably unfavorable. Furthermore there is abundant evidence that harm may be done by this measure by those who are inexperienced regarding its properties.

Serum Therapy.—Serum therapy has been advocated by Coley in inoperable cases, using for this purpose the mixed toxins of the *Bacillus prodigiosus* and *Streptococcus erysipelatosus.* His reports would indicate that in a limited proportion of cases of inoperable cancer the serum has been effective.

The enzyme treatment for cancer (trypsin and amylopsin) has been tested scientifically by Bainbridge, whose report[1] concludes

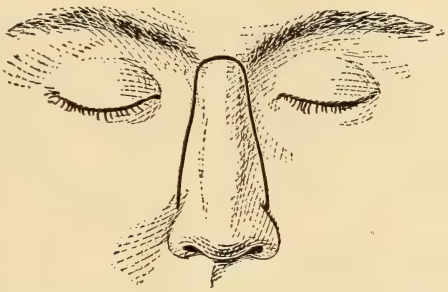

Fig. 435.—Ollier's incision for the purpose of obtaining a wide opening of the nasal cavities.

with this statement: "That the enzyme treatment as administered in cases reported and according to the suggestions of Dr. Beard plus extra details of *régime* does not check the cancerous processes, nor does it prevent metastasis."

Treatment of Inoperable Cases.—In inoperable cases it is important to maintain nasal respiration as long as possible by the removal of large sections of the growth and by cauterization. The secretions should be washed out with alkaline sprays, and the pain should be relieved by local applications. An application of orthoform three or four times daily will usually afford relief until the pain becomes unendurable on account of the encroachment of the tumor upon the more vital structures, when the hypodermic use of morphine should be resorted to. Ligation of the common carotid upon the affected side produces a marked remission in the progress of the disease, temporary relief from hemorrhage and many of the distressing symptoms. Unfortunately said relief is only temporary (two or three months).

---

[1] The Enzyme Treatment for Cancer. Final Report. Medical Record, July 17 and August 7, 1909.

CARCINOMATA.

Primary carcinoma of the nose and the nasal accessory sinuses is of rare occurrence. It is less common than sarcoma, and, unlike sarcoma, it usually occurs after the fortieth year. In this location the alveolar carcinoma and the epithelioma are found. The author has reported a case of primary epithelioma of the maxillary sinus which extended through a tooth-socket into the mouth.

Diagnosis.—The important diagnostic phenomena are: 1, gradually increasing unilateral nasal stenosis; 2, mucopurulent discharge; 3, persistent pain; 4, the appearance of an indurated ulcer; 5, epistaxis; 6, odor (due to necrosis of soft and bony tissues); 7, external deformity and impairment of vision as a result of extension of the disease into the ethmoid cells and orbit; 8, cachexia; 9, microscopic examination of a section removed from the growth.

Prognosis.—The prognosis is unfavorable, and recoveries are rare.

Treatment.—An early diagnosis, followed by complete surgical eradication of the growth, offers the only hope of cure for a carcinomatous neoplasm in the nose. In advanced cases operative interference is contraindicated. The surgical, postoperative and palliative treatment is similar to that of sarcoma, heretofore described.

SECTION II.

The Pharynx and Fauces.

CHAPTER XLIII.

DISEASES OF THE NASOPHARYNX.

SURGICAL ANATOMY.

THE nasopharynx is that portion of the upper respiratory tract which occupies the space bounded above and anteriorly by the choanæ (Fig. 436) and posterior surface of the velum, and below by a plane on a level with the nasal floor. It is a somewhat quadrilateral shaped cavity (Fig. 437), the roof of which is chiefly formed by the basilar process of the occipital and the posterior portion of the sphenoid bones. The spinal column supports its posterior wall. Where the posterior wall of the nasopharynx becomes continuous with the superior there is a rounded curve which is designated as the fornix pharyngi.

The fornix is the seat of the pharyngeal or Luschka's tonsil, a lymphoid glandular structure which exists in this region in the shape of a yellowish-red, soft, irregular swelling.

The lateral wall contains the pharyngeal opening of the Eustachian tube, which lies about 1 cm. behind the posterior border of the inferior turbinal bone. The tubal prominence is somewhat bulbous and triangular in shape, the opening of which is either round or slit-like (Fig. 437). Surrounding the tubal orifice is the torus tubulus, from the posterior part of which the salpingopharyngeal fold passes downward, carrying with it a portion of the palatopharyngeal muscles which arise from the tubal cartilage.

When the velum palati (Fig. 437) is relaxed the nasopharynx communicates freely with the oropharynx, and the nasopharyngeal space opens widely, laterally as well as forward and backward, into the oropharyngeal cavity.

The capacity of the space, according to Luschka, does not amount to more than 14 c.c., its width being subject to considerable individual variations, depending upon the size of the body in general. With the exception of the upper and posterior walls the surfaces are mucous and undergo considerable variations of shape during respiration, speaking, swallowing, etc. The superior wall is almost devoid of muscles, the mucosa being in direct contact with the tissues of the basilar fibrocartilage.

The lateral wall of the nasopharynx recedes so as to form a deep niche, which is called the pharyngeal recess of Rosenmüller or Rosenmüller's fossa. Merkel has made use of the term infun-

dibuliform recess for this fossa. The width of this recess is largely dependent upon the development of the adenoid layer between the pharyngeal tonsil and the tubal orifice. The recess is attached above to the lower surface of the temporal bone and is bounded behind by the solid connective tissue which covers the vessels and nerves of the neck. The arterial supply of the tissues of the nasopharynx comes from the external carotid. The veins empty into the external jugular and the common and posterior facial veins. The lymph-vessels are connected with the deep glands of the face. The nerve supply emanates: 1, from the trigeminus; 2, from the pharyngeal branch of the glossopharyngeal; 3, from several branches and the vagus and spinal accessory, and, 4, from the sym-

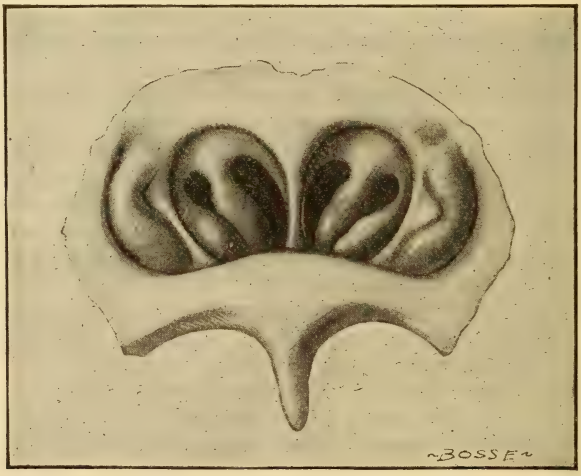

Fig. 436.—The choanæ.

pathetic. The fibres of the last three unite in a lateral plexus, from which the terminal fibres take their origin.

The mucous membrane of the nasopharynx normally is the seat of lymphoid (adenoid) tissue. These glandular structures are prone to undergo pathological changes, the chief of which is true hyperplasia of the lymphoid tissue.

A blind pouch sometimes found lying behind the adenoid substance, the pointed extremity of which becomes inserted into the outer fibres covering the occipital bone, has been termed the pharyngeal (Thornwaldt's) bursa. This bursa is rare and opinions are divided as to its significance. Killian regards it as a structure independent of the pharyngeal tonsil and originating through active proliferation of the mucosa. Histologically the pharyngeal tonsil consists of adenoid tissue imbedded into the tunica propria of the mucosa, and undergoing gradual retrogression after puberty, so that it is rarely met with after the thirtieth year. The areas above

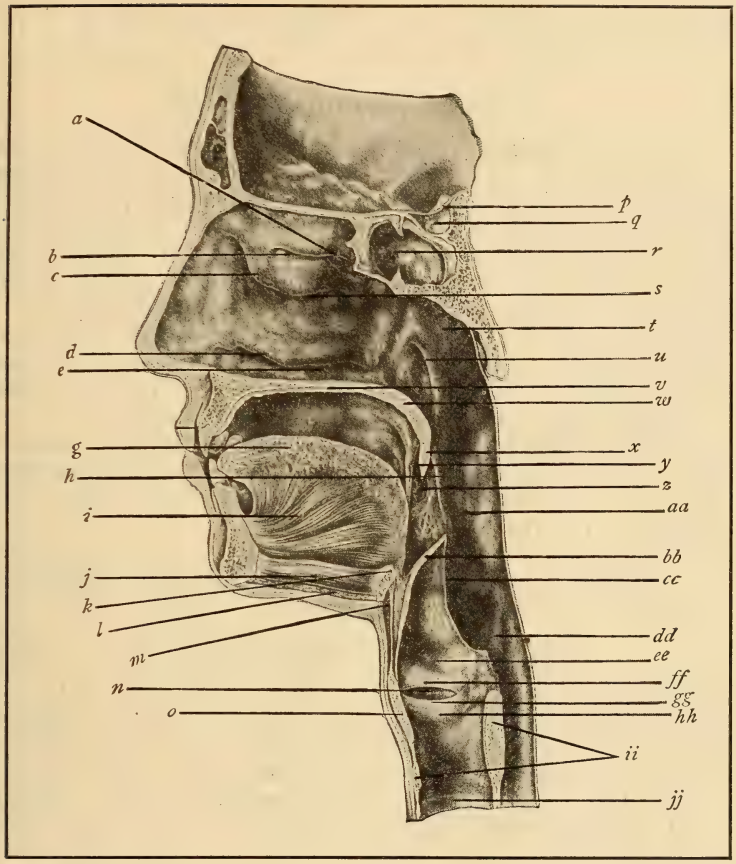

Fig. 437.—Lateral view of the anatomical conformation of the nose, nasopharynx, pharynx, and larynx. (From *Deaver*, with permission.)

a, superior meatus.
b, superior turbinate body.
c, middle turbinate.
d, inferior turbinate.
e, inferior meatus.
g, tongue.
h, posterior pillar of fauces.
i, geniohyoglossus muscle.
j, geniohyoid muscle.
k, hyoid bone.
l, mylohyoid muscle.
m, thyrohyoid membrane.
n, ventricle of larynx.
o, thyroid cartilage.
p, diaphragma sellæ.
q, cavum sellæ.
r, sphenoidal sinus.
s, middle meatus.
t, rhinopharynx.
u, Eustachian orifice.
v, hard palate.
w, soft palate.
x, uvula.
y, anterior pillar of fauces.
z, tonsillar fossa.
aa, oropharynx.
bb, epiglottis.
cc, aryepiglottic fold.
dd, laryngopharynx.
ee, suprarimal portion of larynx.
ff, ventricular band.
gg, vocal band.
hh, infrarimal portion of larynx
ii, cricoid cartilage.
jj, tracheal ring.

described are examined either by ordinary rhinoscopy or by means of the Hays pharyngoscope (Fig. 501).

ACUTE NASOPHARYNGITIS.

The mucosa lining the nasopharynx often becomes the seat of acute inflammation, and, while the inflammatory process usually occurs in conjunction with rhinitis and pharyngitis, cases are seen in which the nasopharynx is primarily the seat of an inflammatory process to which the symptoms are clearly referable. It occurs during seasons of dampness and sudden changes, and is invariably aggravated by the excessive use of tobacco and stimulants.

Etiology.—So far as known, exposure to cold, in a person otherwise predisposed by fatigue, ill health or some form of constitutional dyscrasia, is the prime etiological factor. In young children with diseased adenoid tissue it is extremely common.

Symptomatology.—The attack is usually sudden, often being first felt upon arising from sleep. There is a disagreeable sensation of irritation and dryness, with considerable pain, located in the upper part of the throat. A slight rise of temperature, with some increase in the pulse rate and more or less prostration, is usual. It is not unlikely that in certain cases the nasopharyngeal inflammation results from some disturbance of the digestive tract. After a day or two a mucopurulent discharge appears, which is sufficiently thick and tenacious to require considerable effort to dislodge. Persistent hawking is one of the marked symptoms of the second stage of the disease, and its indulgence often produces gagging and vomiting. The voice is usually impaired and metallic in quality. As a rule the oropharynx partakes of the inflammatory process, but the larynx and bronchial tubes do not become involved. Inflammation and swelling of the Eustachian tubes is a common symptom and it is prone to induce obstruction of the tube, which. in turn, causes acute catarrhal otitis media (see Chapter XVI).

Treatment.—As a rule the treatment employed should be the same as for acute rhinitis (see Chapter XXXIII).

SIMPLE CHRONIC NASOPHARYNGITIS.

Synonyms.—Nasopharyngeal catarrh; chronic postnasal catarrh; hypertrophic nasopharyngitis.

Chronic nasopharyngitis is an inflammatory process involving the mucosa of the nasopharynx and characterized by a secretion of tenacious mucus, sometimes mucopurulent, from the glandular structures.

Etiology.—Chronic nasopharyngitis rarely occurs independently of chronic hyperplastic rhinitis; hence the latter is the chief etiological factor (see Chapter XXXIV). Occupation, exposure and the dust which accompanies various forms of employment, in tobacco factories, clothing institutions, etc., also the various mechanical occupations, are contributing causes; meanwhile badly

nourished individuals who live under unhygienic surroundings are peculiarly liable to this disease.

Pathology.—In general the pathological changes in the mucosa are similar to those which occur in chronic rhinitis (see Chapter XXXIV). In addition there are marked changes in the lymphatic tissues, especially in Luschka's tonsil, which may become much enlarged.

Symptomatology.—The symptoms are chiefly referable to the annoyance associated with the constant sensation of dryness and the irritation produced by the retention of tenacious mucus upon the walls of the pharynx, the retained secretion often becoming inspissated, thus adding materially to the discomfort. The secretion should be differentiated from that which flows into this region from empyema of the posterior ethmoidal cells and the sphenoidal sinuses. The patients "hem" and "hawk" almost incessantly, much to their own annoyance and to that of their acquaintances. Upon examination the mucous membrane is inflamed and thickened. The secretions accumulate upon the posterior wall or flow down into the pharynx. With each exacerbation the Eustachian tubes are ex-



Fig. 438.—The author's flexible cotton carrier.

tremely liable to become involved in the inflammatory process and attacks of catarrhal otitis media result. Tubal obstruction, tinnitus and deafness may eventually result. The voice loses much of its timbre, and the prolonged efforts to release the retained secretion may result in relaxation of the soft palate and uvula.

Treatment.—The general treatment of this affection is similar to that of chronic rhinitis (see Chapter XXXIV) and includes the prohibition of tobacco, alcohol and irritant condiments, the regulation of diet and digestion, and the adoption of proper measures of hygiene. Furthermore it is imperative that intranasal diseases and defects should be eliminated.

Locally the first step is the careful and complete removal of all secretions. This is best accomplished by means of the postnasal syringe (Fig. 305), making use of the procedures and solutions recommended for atrophic rhinitis (see Chapter XXXIV). It is not difficult to train patients to wash out the nasopharynx by means of the ordinary nasal spray, directing that while spraying either nostril to throw the head backward and to breathe entirely through the wide-open mouth. By this procedure the velum is made to fit closely to the posterior wall, and the fluid collects in sufficient quantity to wash the mucous surfaces. The danger of middle-ear involvement is overcome by directing the patient to blow the nose without shutting off either nostril; in other words, to blow through both nostrils simultaneously, or to refrain from blowing until the

fluid has largely passed backward into the mouth. It is sometimes necessary to use a curved applicator (Fig. 438), cotton-tipped, in order to remove retained masses of secretion. After cleansing, the mucous surfaces of the nasopharynx may be painted with mild astringents. Argyrol in 25 per cent. solution, Mandl's solution (see page 518), nitrate of silver, 20 to 40 grs. to the ounce, or boroglycerid, 5 per cent., applied with a curved cotton-tipped applicator (Fig. 438), are useful.

Adenoids when present should invariably be removed. Likewise the pharyngeal bursa and adhesive bands whenever they are present.

ATROPHIC NASOPHARYNGITIS.

Synonym.—Nasopharyngitis sicca.

Atrophic nasopharyngitis is always identical with atrophic rhinitis, with the same etiological factors and pathology.

Symptomatology.—The chief symptom is a sensation of extreme dryness and the formation and retention of crusts, which usually cover the greater portion of the entire mucosa. The annoyance is so great with many patients that, in addition to the constant hawking and snuffing, they resort to the introduction of the finger into the postnasal space to get relief. Every two or three days large masses become dislodged, which often form almost a complete cast of the nasopharynx. Examination reveals the presence of these crust formations, with but little normal watery secretion. The atrophic process is prone to involve the middle ear. The disease is extremely obstinate and requires the most painstaking and long-continued treatment.

Treatment. — In addition to the treatment heretofore described for the associated atrophic rhinitis (see Chapter XXXIV), the nasopharynx requires frequent and painstaking treatment, commonly covering a period of many months or even years. The aim of the treatment largely should be to remove the crust masses with sufficient frequency to relieve the individual of the uncomfortable sensations which they induce, and to restore as far as possible the normal state of the mucosa. The postnasal syringe (Fig. 305) will usually suffice to dislodge the secretions, but in the more obstinate cases the entire removal of the crusts can be accomplished only by means of a curved cotton carrier (Fig. 438), aided by the rhinoscopic mirror. It is quite possible to train patients to relax and otherwise control the pharynx so that the operator, by employing a small rhinoscopic mirror, is able to observe the various steps in the treatment.

After thorough cleansing, the surfaces should be swabbed with ichthyol 25 per cent. The success of the treatment is largely dependent upon the frequency and thoroughness of the process of cleansing, and of the stimulating medicaments. It is often necessary to prolong the period of treatment from three to six months, and the fidelity and persistence of the patient should equal that of the surgeon.

ADENOIDS.

Synonyms.—Hyperplasia of the lymphoid tissue in the nasopharynx; hypertrophy of Luschka's tonsil; hypertrophy of the third tonsil.

The memorable day in 1870 when Wilhelm Meyer published his classic treatise giving to the world the results of his original researches in the realm of the glandular structures of the nasopharynx marked a distinct advance in our knowledge of the pathology and treatment of these structures, and thereby he bestowed a lasting boon upon child life.

The lymphatic tissues which bear the name "adenoids" are a series of lymph-glands which are superficially located in the mucosa

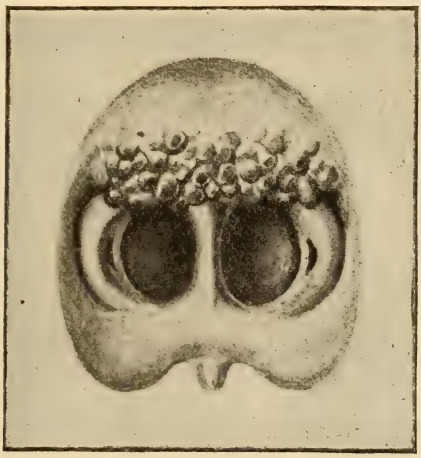

Fig. 439.—Sessile masses of adenoids in the vault of the pharynx.

of the vault and posterior wall of the nasopharynx. They form the upper segment of the chain of superficial lymph-glands which extends from the pharyngeal or Luschka's tonsil to the lingual tonsil and known as Waldeyer's ring.

The nasopharynx frequently is the seat of hyperplasia in which the normal lymphoid glandular structures become involved in this form of inflammatory process. It should be remembered that these lymph-glands in this locality are physiologically normal under healthy conditions, and require treatment only when they become the seat of hyperplastic enlargement (Fig. 455).

Etiology.—This affection is essentially one of child life and is more commonly observed between the ages of three and twelve years. In a small percentage of infants the disease appears soon after birth and seriously interferes with respiration and nursing. The author has found it necessary to operate as early as the fourth month. Heredity is an important etiological factor both in races and in families. One rarely fails to find a family history of adenoids

in one or both parents, and it is commonly necessary to operate upon an entire family of children. It is difficult to otherwise explain why hypertrophy occurs in some children and not in others, and why the disease is no respecter of persons, whether rich or poor. Climate exerts a marked influence upon this affection. Dampness and sudden changes, by inducing inflammation of the upper air passages, tend secondarily to favor hyperplasia in the lymph-glands of the nasopharynx. Bad hygiene, especially the inhalation of vitiated air and impurities, such as irritating gases, is a predisposing cause. Purulent rhinitis in its various forms is a common exciting cause of adenoids. Furthermore, the exanthemata, grippe and all infectious fevers, by their tendency to induce intense inflammation and engorgement of the nasopharyngeal mucosa and consequent alteration in the secretions, often mark the beginning of permanent hyperplasia of the pharyngeal tonsil (adenoids). Hence, the causes of the above-named affections must be considered predisposing causes of adenoids.

Glandular hypertrophy in the pharyngeal vault is usually associated with more or less hypertrophy of the faucial and lingual tonsils.

Nasal obstruction increases the tendency to hyperplasia of the lymphoid tissue in the nasopharynx. While adenoid hyperplasia is most commonly met between the ages of five and fifteen and somewhat more rarely between fifteen and twenty, it occasionally remains to old age. The affection occurs about equally in both sexes.

The growths occur in two chief forms—first, hyperplasia or uniform thickening of the pharyngeal tonsil, in which the mass appears as a globular or flattened tumor, and, second, diffuse hyperplasia, wherein the growths are sessile and mulberry-shaped without the appearance of being a uniform tumor (Fig. 439). The first-named variety is more common, but both forms may exist simultaneously. The consistency of these growths is extremely variable. They may be so friable as to be easily crushed by the finger, or so dense that considerable force is required to cut through the masses with sharp cutting forceps. They tend to become more dense in adult life. These differences probably result from the relative amount of connective tissue in the tumor masses. They are extremely vascular. In addition to the above-described etiological factors the existence of an underlying predisposition (lymphatic diathesis) is probable.

Pathology.—Under normal conditions the mucosa of the posterosuperior nasopharyngeal wall contains superficial lymph-glands. According to McBride and Turner, they consist of a meshwork of fibrous connective tissue, which supports the lymphoid cells, but on account of their superficial location they differ from the more deeply seated lymphatic glands by having an epithelial covering which is continuous with that of the surrounding membrane. The pathological changes which result in enlargement seem not to be those arising from excessive connective-tissue develop-

ment, but of excessive lymphoid development, although occasionally in the more dense varieties there is a true hyperplasia in which the lymphoid enlargement is associated with an increase of connective tissue. Where there is a considerable degree of redundance the mass appears in the form of folds with deep depressions or grooves (Fig. 455). In adults it is quite common to discover adhesive bands stretching from a central mass of adenoids to the tissues about the upper surface of the Eustachian orifice (Fig. 457).

The enlargement usually reaches its height before the fifteenth year, after which there is a moderate tendency to atrophy. Located deeply in the folds or recesses of the hyperplasia, cheesy masses made up of desquamated epithelium and other cell elements and bacteria are occasionally discovered.

Fig. 440.—A group of five New York City public school boys, all of whom had adenoids and hypertrophied tonsils. (Photo loaned by the officials of the Health Department.)

Symptomatology.—The clinical picture in typical cases is characteristic. The listless expression, open mouth, pinched nose, thick lips, depression of the superior maxilla about the nasal orifices (Fig. 442), are sufficient to make the diagnosis clear. The victims are liable to suffer from conjunctivitis and inflamed palpebral margins. The nostrils are usually filled with thick mucus or mucopus, which is difficult to remove on account of the inability of the patient to blow the nose. The lymphatic chain, either in front of or behind the sternocleidomastoid muscle, often becomes enlarged when the lymphoid structures of the oro- or naso-pharynx are infected. The chain in front of the sternocleidomastoid muscle draining the tonsil is perceptibly enlarged when the tonsil is infected, and the chain behind this muscle becomes enlarged when the adenoid structure of the nasopharynx is the seat of infection. The author has observed this particularly when either tonsil or adenoid is tuberculous.

Through the courtesy of the officers of the Health Department of New York City the author is permitted to publish a series of photographs secured from children attending the public schools. The group shown in Fig. 440 were typical cases. Numbers 1, 2 and 3 of this group are again shown in Fig. 441 after the removal of their tonsils and adenoids. The marked improvement in facial expression is well shown both in the above illustration and in Fig. 443.

A group of mentally defective children with adenoids is shown in Fig. 444, and it is affirmed that, after removal of their adenoids and tonsils and a short sojourn in the country, the entire number were able to keep up with their regular class work.

Fig. 441.—Same boys as Nos. 1, 2, 3 of Fig. 440, after operation.

There is a tendency to protrusion of the sternum, with more or less flattening of the chest walls. Subjectively, there is a history of mouth-breathing, snoring, restless sleep, night terrors, dull mentality, anemia, alteration in voice, frequent infections and colds which are prone to induce attacks of tracheitis, bronchitis, and recurrent purulent otitis media. In detail the symptoms are herein classified as follows: 1, symptoms resulting from the obstruction of nasal respiration; 2, symptoms resulting from inflammatory changes in the lymphoid tissue of the nasopharynx and secondarily involving the mucosa of the nasal cavities, the middle ear, the pharynx, larynx, and bronchial tubes; 3, reflex neuroses sometimes induced by adenoids.

1. Obstructed nasal respiration is present—at least to a mild degree—in all individuals who suffer from adenoids, and almost without exception they exhibit to a slight degree the typical changes in facial expression. Wide-open mouth-breathing during the waking hours occurs only in the severest cases (Fig. 442), but the lips and jaws are slightly separated most of the time in mild

cases. The nostrils are usually contracted and markedly depressed at the labial junction, and the labionasal fold is indistinct or absent. The upper lip usually protrudes. When asleep the mouth is widely open, respiration is labored, snoring is common, and night terrors, moaning and outcries are frequent. Adenoid patients are intensely restless during sleep; they roll and tumble about the bed and kick off the covers. They often lie upon the stomach and chest, with the knees drawn upward underneath. They are extremely liable to take cold under slight provocation, and their colds are prone to result in attacks of spasmodic croup, partially on account of the obstructed nasal respiration. The prolonged oxygen starvation which results from the abnormal and obstructed respiration is largely responsible for the retarded physical development, the

Fig. 442.—The typical adenoid facial expression. (Photo loaned by the officials of the New York City Health Department.)

Fig. 443.—Same boy as in Fig. 442, after the removal of adenoids.

persistent anemia, the apparent stupidity and lack of mental concentration (aprosexia).

Young infants find great difficulty in nursing and are obliged to drop the nipple at frequent intervals in order to breathe.

Disorders of digestion from swallowing the discharges, pyrexia from septic absorption from the growths, and anosmia and epistaxis are commonly observed.

The nasal obstruction induces marked alteration in phonation, both as to character and tone, the voice being similar to that which accompanies an aggravated cold in the head, so that the consonants, like *m* and *n*, are pronounced *eb, ed,* etc.

In severe cases which are unrelieved by timely operative interference, there is a marked tendency to deformity of the superior maxillary bone, the characteristics of which are recession about the nasal orifices, contracted V-shaped arches, and irregularities of the teeth.

2. Inflammatory symptoms and complications: Children who have adenoids are particularly subject to acute infections of the nasopharyngeal mucosa. All acute intranasal inflammations, especially those which accompany the exanthemata, grippe and other infections, are more deep-seated and prolonged. Furthermore such attacks may induce persistent and aggravating rhinitis, pharyngitis, laryngitis and bronchitis; catarrhal and purulent otitis media, and finally *chronic* pharyngitis, laryngitis and bronchitis, and deafness.

Recurrent colds and persistent cough in a young child should invariably lead to a suspicion of adenoids. A dull-red liver-colored membrana tympani is quite common and characteristic in children who have adenoids.

Fig. 444.—Group of "mentally defective children with adenoids." After the removal of adenoids and a short vacation in the country the greater number were thereafter able to keep up with their regular class work. (Photo loaned by the officials of the New York City Health Department.)

In the majority of cases middle-ear complications are present. In an examination of 307 cases of adenoids McBride and Turner found 255 who had middle-ear lesions. Of the 255 cases 144 were purulent and 111 were more or less deaf from catarrhal otitis media.

The attack upon the ear may be catarrhal or purulent. In either case the condition is serious, threatening partial or total loss of hearing, or some of the serious sequelæ of middle-ear suppuration. It is the invariable rule that all children who have recurrent attacks of middle-ear suppuration have adenoids. According to Frankenberger, the percentage of adenoids in deaf-mutes is much higher than in the general run of children. He found adenoids in 94 out of 159 deaf-mutes, or 60 per cent.

3. Reflex neuroses sometimes induced by adenoids: In addition to the nocturnal symptoms above described, epileptiform convulsions are occasionally noted and are more common at night. Daly and others have reported recoveries following operations for the removal of adenoids. Nocturnal incontinence of urine is also an occasional reflex disturbance. Stammering, chorea, hay fever, and asthma are aggravated if not caused by adenoids. Many adenoid patients are peevish, restless, and have marked inaptitude for mental activity (aprosexia). Mental sluggishness, however, is more apparent than real, often arising from the child's embarrassment at being gibed for his peculiar speech. A barking, croupy cough, worse at night, is a common complication of adenoids.

Diagnosis.—In addition to the manifest symptoms, the diagnosis of adenoid vegetations may be verified by one or more of the following procedures: 1, anterior rhinoscopy; 2, posterior rhinoscopy, and, 3, digital examination.

Anterior Rhinoscopy.—The nasal passages should always be scrutinized both for the purpose of ascertaining the extent of the inflammation and thickening of the mucosa, and also to exclude intranasal tumors, deformities or foreign bodies as a cause of the obstructed respiration. Occasionally it is possible to observe the masses of adenoids by anterior rhinoscopy.

Posterior Rhinoscopy.—For actual demonstration posterior rhinoscopy or digital palpation becomes necessary. Of the two methods the former is preferable and can usually be conducted without difficulty. It is accomplished without pain, but requires much tact and considerable manual dexterity. The patient's confidence should first be secured and the use of each instrument fully explained in the following manner: 1, attract the child's attention by asking him to see his face in the head mirror; 2, without instruments in hand ask him to open his mouth wide, keeping his tongue within; 3, before introducing the tongue depressor explain that it is simply to press down the tongue in order that the throat may be seen, and, if necessary, the examiner should illustrate by pressing down his own tongue. After a little the child submits freely to this manœuvre. The throat mirror should then be taken and the explanation made to the child that it is a looking-glass and is used only for the purpose of seeing; that it is warmed in order that the breath will not obscure the vision. The word "looking-glass" being fully understood even by very young patients, they permit its introduction without opposition. Now with the tongue depressed the patient should be encouraged at every step by saying, "You are doing well; I am beginning to see," etc., until the mirror falls well behind the velum (Fig. 18), when the adenoids come into view. The author rarely finds it necessary to make a digital examination.

Digital examination is an extremely painful process and forever destroys the confidence of the little patient. Occasionally, however, it becomes necessary to employ it. The operator should stand at the right side of the patient, with the left arm thrown around the side of his head, the latter being firmly pressed against the examiner's hip. The child is instructed to open his mouth widely, at which time the fore-

finger of the left hand should press the side of the cheek and lip well into the mouth between the teeth and hold it firmly in that position until the entire examination has been completed. The finger-tip of the right hand is passed quickly against the posterior wall and thence forced upward into the vault, where a spongy, velvety mass is felt. It is impossible for the patient to bite the examiner's finger, providing the lips and cheek are continuously pushed between the child's open jaws on the left side.

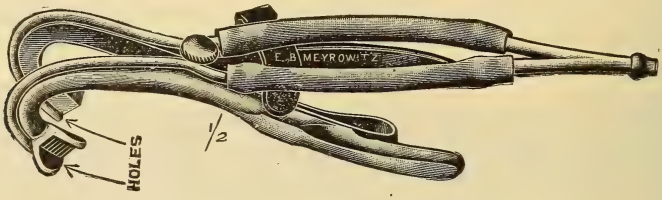

Fig. 445.—Denhart's mouth-gag with ether tubes.

Differential Diagnosis.—Obstruction to nasal respiration from foreign bodies in the nose may be mistaken for adenoids. Malignant growths, while obstructive, always present their characteristic symptoms of rapid growth, pain, cachexia, hemorrhage, etc. Fibroma in the region of Luschka's tonsil is occasionally observed. It is more dense in structure than adenoids, with a smoother surface, and tends to recur.

Prognosis.—When recognized early and promptly relieved by operation, the prognosis is good; on the other hand, if allowed to remain and become more and more diseased, serious results may be

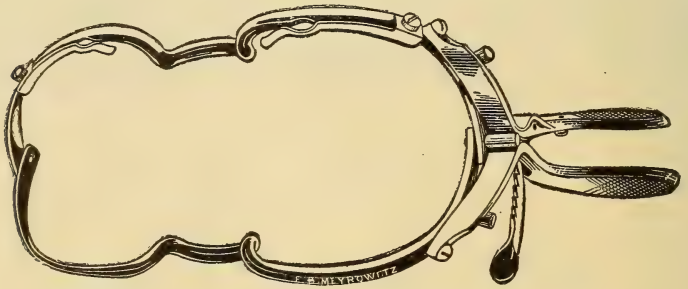

Fig. 446.—Jenning's mouth gag.

expected from the prolonged obstruction to nasal respiration as well as from the various infections which are prone to attack the nose and nasopharynx. Added dangers are attacks of purulent otitis media, acute infectious diseases, bronchitis, pneumonia, superior maxillary and chest deformities and deafness. If thoroughly removed by operation the tendency to recurrence is practically *nil,* less than 5 per cent. After the fifteenth year the growths tend to gradual atrophy, but too late to prevent the more serious complicating lesions.

Treatment.—The treatment of this affection is surgical. If the growths are present in sufficient amount to cause even one of the symptoms above enumerated, they should be removed. Often the ear symptoms seem to be more prominent than those associated with nasal respiration. In these cases also the operation becomes imperative. Early recognition and prompt and thorough surgical removal should be the invariable rule. Local applications and internal medication are palliative, but are applicable in that very small percentage of cases wherein the child has a catarrhal tendency, with

Fig. 447.—The Chapin tongue depressor.

but slight lymphoid hyperplasia. In such cases the internal administration of iron, cod-liver oil and arsenic, in conjunction with thorough daily cleansing of the nose and nasopharynx, may check the tendency to lymphoid hyperplasia. In like manner the hygienic and other measures recommended for acute rhinitis (Chapter XXXIII) are applicable here. In the majority of cases the operation is performed in conjunction with the removal of the tonsils. The tendency, both on the part of the medical profession and the laity, is to underestimate the gravity of the combined tonsil and adenoid operation when properly performed. It is attended with severe hemorrhage—more severe than that which occurs in many capital operations. The operation is also extremely painful. Local



Fig. 448.—The Brandegee adenoid forceps.

anesthesia, while never entirely relieving the pain, is sometimes feasible in adults. In children, however, the general anesthetic should be employed, except in cases where for cardiac, glandular or other reasons the anesthetic would be dangerous. Whenever possible the operation should be performed in a hospital, where the patient should remain for from twenty-four to forty-eight hours, thus avoiding the dangers from secondary hemorrhage or the complications arising from the anesthetic. The details of the operation are as follows:—

Preparation of the Patient.—The preparation of the patient consists in administering a mild cathartic on the previous night, and

the cleansing of the nose and nasopharynx with a saline solution twice daily for twenty-four hours. When the operation is to be performed in the afternoon the patient may be permitted to drink a glass of milk or take a small portion of soft food at breakfast time, but for morning operations no food should be taken. The anesthetic should be administered by one experienced in anesthetizing children for the adenoid operation, such experience covering the degree of anesthesia, the manipulation of the mouth-gag, maintaining the position of the head, the removal of blood, and the



Fig. 449.—The Stubbs adenoid curet.

necessary watch-care for the few minutes subsequent to the operation. It is inadvisable to allow inexperienced anesthetists to administer anesthetics for this operation.

Generally speaking, ether is the safest anesthetic. It is possible, and often feasible, to operate with nitrous-oxid-gas anesthesia in cases where the tonsils do not require attention.

With the mouth, nose and face thoroughly cleansed, a sterile-rubber cap should be put upon the head, over which should be pinned a sterile towel; otherwise the preparations are similar to those for all operations upon the nose and throat.

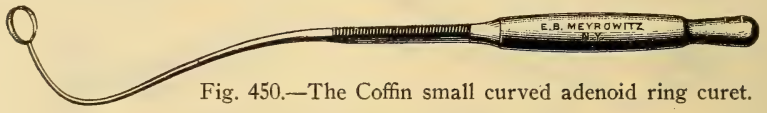

Fig. 450.—The Coffin small curved adenoid ring curet.

To cover all necessities and emergencies the following armamentarium of instruments and remedies should be at hand, in addition to those required by the anesthetist:—

Mouth gag (Figs. 445, 446); tongue depressor (Fig. 447); adenoid forceps (Fig. 448); adenoid curets (Figs. 449, 454); sponge holders (Fig. 456); small pair of forceps for removing adenoid from mouth; tonsil punch (Fig. 484); gauze sponges; adrenalin; ice-water.

Numerous instruments have been devised for the removal of adenoids, the two general types being the forceps and the curet, many varieties of each being extant. Of the various modifications of adenoid forceps that of Brandegee (Fig. 448) is the best adapted for the adenoid operation. The Stubbs modification (Fig. 449), by

possessing a downward curve at the junction of the shank and the cutting ring, enables the surgeon to reach and encircle the uppermost parts of the growth. The La Force adenotome is also recommended. (Fig. 454.) The small ring curet devised by Coffin (Fig. 450) is of great service in removing residual shreds, or small masses of adenoids which are beyond the reach of the larger curets or forceps.

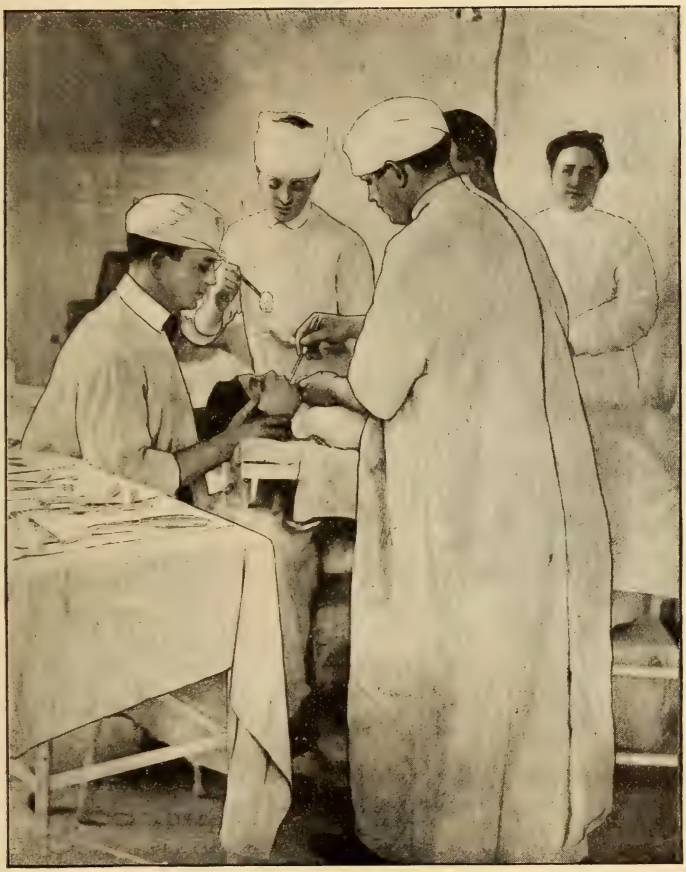

Fig. 451.—Position of patient, operator, and assistants for removal of adenoids and tonsils under general anesthesia. (Photographed in the Manhattan Eye, Ear, and Throat Hospital operating room.)

Position of the Patient.—The consensus of opinion among American rhinologists favors the dorsal position for adenoid and tonsil operations (Fig. 451), when general anesthesia is employed. The patient's head should be slightly lowered or turned to one side during the procedure in accordance with the adaptability of the individual surgeon. The upright position is preferable when local anesthesia is chosen, inasmuch as under these conditions the patient is able to avoid the inhalation of blood.

Furthermore the operation should be performed under bright illumination. The electric headlight (Fig. 7) is most satisfactory for operations upon adenoids and tonsils.

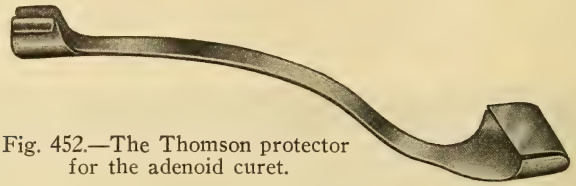

Fig. 452.—The Thomson protector for the adenoid curet.

Operation with the Curet.—In the majority of cases the curet should be relied upon for the removal of the mass of adenoids.

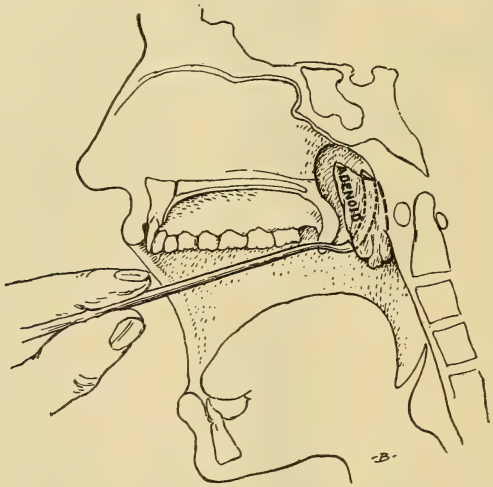

Fig. 453.—Schematic representation of the removal of adenoids by means of the curet.

With a sharp curet, well selected as to size and adaptability, the entire mass may be completely excised with a single sweep and

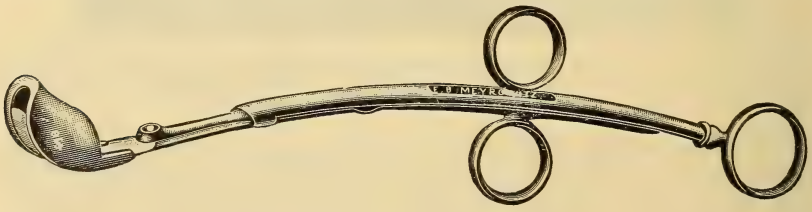

Fig. 454.—La Force adenotome.

without injury to the surrounding tissues. It is of the utmost importance that the curet should be sharp, and to this end the protector devised by Thomson (Fig. 452) guards the cutting edge

from contact with other instruments. The LaForce adenotome (Fig. 454) possesses many advantages, the chief of which is that the cut is made from below upwards while the mass removed is retained within the instrument instead of falling into the patient's throat.

Having selected the curet, it should be introduced behind the soft palate into the postnasal space. Some authorities advise the employment of a palate retractor (Fig. 19) during this procedure, but in skillful hands no retractor is needed. The curet should be carried upward and backward until it comes into contact with the posterior border of the choanæ, when, by tilting the handle upward and at the same time firmly forcing the blade into position against the upper line of the posterior wall, its ring is made to encircle the growth. With a firm, downward, sweeping movement the curet is made to sever the entire mass at its base of attachment (Fig. 453), but the cutting should terminate at the lowest point of attachment of the adenoids. Furthermore, the blade should not penetrate the submucous structures or denude the underlying bone.



Fig. 455.—Large adenoid, actual size, showing linear folds and deep depressions.

The severed mass of tissue (Fig. 455) usually falls into the mouth upon the withdrawal of the curet, but it should be carefully watched for and grasped with forceps in order to avoid being accidentally drawn into the larynx. Before concluding the procedure the postnasal space should be palpated with the finger, and any remaining shreds removed. Whenever such shreds are attached to the posterior pharyngeal wall, by lifting the soft palate they are easily cut away with a tonsil punch. It sometimes becomes necessary to employ the adenoid forceps (large or small) to complete the operation.

Operation with the Forceps.—The Brandagee forceps (Fig. 448) should be selected. There are two sizes. This instrument fits the vault, has a wide cutting surface, and with one cut it is usually possible to remove the mass. The anesthetist or assistant should hold the patient's head firmly and the adenoid forceps, closed, should be carefully introduced into the nasopharynx, and gently rotated to

free the jaws from possible attachment to the membrane of the velum. The distal end should then be carried firmly against the extreme portion of the vault and as close as possible to the choanæ. The jaws should then be widely separated and pressed against the vault with sufficient force to engage the growth. Before cutting, the shank of the forceps should be brought into a position touching the upper incisor teeth, exactly in the median line. This precaution prevents the accident of grasping the posterior border of the vomer. The jaws of the forceps should now be tightly closed. The closing of the jaws of the forceps does not fully cut through the mass, and one or two rocking movements should be made, with force sufficient to partly cut and partly tear off the adenoids, before it is drawn downward into the mouth; otherwise there is danger of stripping the membrane from the posterior pharyngeal wall. As a rule it is necessary to complete the removal with the curet or finger, preferably the former. The hemorrhage is profuse, but usually is not

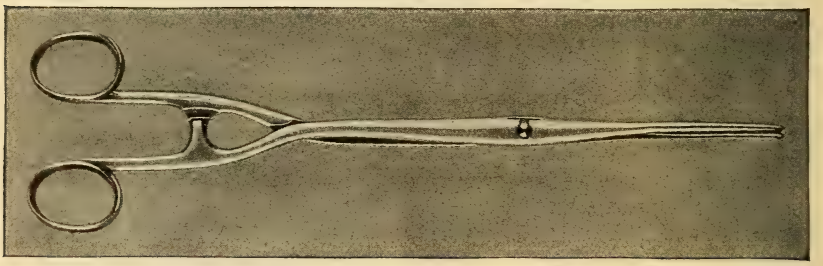

Fig. 456.—The Hunter sponge holder.

persistent. The patient should be rolled upon his side and under good illumination the blood should be removed by means of swabs held in large sponge holders (Fig. 456).

When the finger is introduced, either for the purpose of determining whether the removal is complete or to scrape away remnants of adenoids, it should be encased in a layer of sterile gauze, which may be saturated with alcohol, the latter being both astringent and styptic.

After completing the operation, the patient should be rolled upon his side and his face swathed with towels well soaked with ice-water until the hemorrhage has practically ceased. The hemorrhage is usually self-limited and rarely persists after the first few seconds. Several procedures have been devised for controlling the hemorrhage.

As the hemorrhage ceases, the mouth gag may be removed and the patient carried to his room, where he should be continuously watched until he recovers from the anesthetic and all danger of hemorrhage has passed. After returning the patient to bed, the position upon the side or stomach is preferred. Patients should lie upon the side for some time. If allowed to lie upon the back they may swallow blood without giving evidence of hemorrhage.

In case of severe and persistent postoperative hemorrhage pressure must be applied to the bleeding point. Masses of absorbent cotton or gauze dipped in adrenalin solution and grasped in strong curved forceps should be passed up behind the velum with sufficient pressure to control the hemorrhage. Persistent hemorrhage occasionally yields only to hypodermics of human or horse serum or to anterior and postnasal plugging. The latter procedure often induces attacks of purulent otitis media. In one of the author's cases it was necessary to resort to anterior and postnasal plugging on three occasions during the six days following an adenoid operation, and in spite of the utmost care the patient developed acute purulent otitis media, and, finally, an attack of acute mastoiditis.

After-treatment.—There is but slight pain following the adenoid operation unless a tonsillotomy has been performed, when the

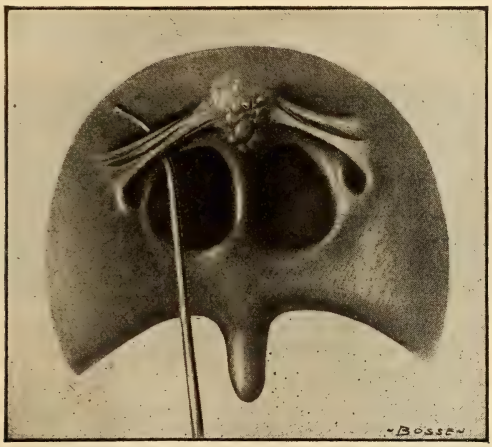

Fig. 457.—The adhesive bands pass from a central adenoid mass to the upper surface of the orifice of the Eustachian tubes.

pain is chiefly referable to the cut surfaces of the tonsils. There is but slight reaction and only occasionally any acute inflammatory stage, except in those rare cases where some latent infection is present, when there may be considerable discomfort. The patient should remain in bed for from twenty-four to forty-eight hours, and the temperature taken. If on the following day the temperature is normal and there is no apparent reaction, the patient may sit up in bed toward night, and the following morning be allowed to put on ordinary clothing and be up and about the house, but he should be restrained from overexertion of any kind and if possible from going into vitiated air or contaminated atmospheres. Children should not be allowed to return to school for several days on account of the danger of infection. Local applications are usually unnecessary, but, when some cleansing wash is required, a spray of an alkaline antiseptic solution will suffice. Medicaments locally applied should be avoided. The nasopharyngeal space should be carefully re-examined at the end of one or two weeks in

order to ascertain whether the entire growth has been removed. No subsequent treatment is required beyond the daily performance of intranasal hygiene (see Chapter XXXIII) whenever purulent secretions continue.

As soon as normal nasal respiration is established these patients even without internal medication, immediately begin to show the beneficial effects of proper oxygenation. The color improves, the anemia disappears and the bodily weight rapidly increases. In one of the author's cases which was complicated by deflected septum, in a stunted, anemic, pigeon-breasted boy of sixteen years of age, the septum was straightened, the adenoids and tonsils were removed, and during the following year he gained about forty pounds in weight.

Adhesive bands in the nasopharynx (Fig. 457) should be cut away or otherwise destroyed. The author has devised a guarded galvanocautery knife (Fig. 458), which may be introduced behind the adhesive band in a manner similar to that of the probe in Fig.



Fig. 458.—The author's galvanocautery knife for dividing adhesions in the nasopharynx.

457, after which the current is turned on and a segment of the band destroyed. These and other postnasal and nasopharyngeal growths are easily demonstrated by means of the pharyngoscope (Fig. 501).

Recurrence.—Adenoids rarely recur after complete removal. The so-called recurrences in the majority of cases occur where the primary operation has been incomplete. In infants and children under four years of age, additional lymphoid glands may undergo inflammatory changes, and coalesce into obstructive masses of sufficient size to require operation.

Syphilis of the Nasopharynx.—The phenomena of both secondary and tertiary syphilis are observed in the nasopharynx, in the form of mucous patches or gummata. Syphilis of the nasopharynx is fully described in Chapter XXX.

NEOPLASMS OF THE NASOPHARYNX.

Benign Neoplasms.

Benign neoplasms of nasopharyngeal origin are extremely rare. They are chiefly confined to the myxomatous and fibromatous varieties, but cases of papilloma, enchondroma and lipoma have been recorded.

Nasopharyngeal Polypi.

Primary nasopharyngeal polypi should be differentiated from those which have protruded into this space from their attachment in the nares (see Chapter XLII).

Etiology.—Nasopharyngeal polypi are commonly associated with nasal polypi, and are similar in pathology, etiology and symptoms. They are prone to appear in early life and are somewhat more common in males. They are usually denser in structure, hence are less edematous and often attain large size.

Treatment.—For treatment see Nasal Polypi, Chapter XLII.

Nasopharyngeal Fibromata.

Etiology.—The exact cause of nasopharyngeal fibromata is unknown. The typical nasopharyngeal fibroma springs from the basilar fibrocartilage, but may originate from the anterior surfaces of the upper cervical vertebræ and in the sphenopalatine fossa. The characteristics of these growths are: 1, extreme hardness, so that the knife or snare wire often cuts through them with difficulty; 2, tendency to extensive growth and to invade the surrounding tissues, especially the nasal cavities, the cheek or orbit; 3, nasopharyngeal fibromata are destructive, inasmuch as they push aside and erode the walls of the cavities in which they are lodged and ultimately reach the cranial cavity; 4, the continued pressure and friction result in rupture and, later on, cicatricial adhesions form between certain portions; 5, vascular erosion is a common result, and any violence, such as sneezing, blowing the nose, etc., is liable to be followed by severe hemorrhage; 6, tendency to recur after removal.

Symptoms.—The early symptoms are similar to those of nasopharyngeal polypi with the exception of their tendency to hemorrhage. When unrelieved by operation they cause erosions and pain by pressure, and later on deformity to the parts and free mucopurulent discharge.

When left to itself the disease usually terminates in death through asphyxia, inanition or cerebral lesions. Occasionally, however, spontaneous involution of the neoplasm has been observed, with complete subsidence. These tumors are benign growths, inasmuch as they do not give rise to metastases and do not destroy the neighboring tissues by a process of infiltration, but are harmful by causing mechanical displacement.

Prognosis.—When operated upon while small the prognosis is fairly good. There is a marked tendency to recurrence. Whenever the growth has extended to the surrounding cavities, especially to the brain, the prognosis is bad.

Treatment.—When of moderate size they should be removed with a cold-wire or galvanocautery snare. This method of treatment greatly simplifies the removal of fibromata, and furthermore possesses the advantage that general anesthesia is not required.

Removal with the snare is difficult on account of the density of the tumor and the tendency to violent hemorrhage.

Extensive surgical procedures under general anesthesia are necessary to remove large fibromata. Among the radical operations Kocher splits the entire roof of the mouth, separating the superior maxilla, and so gains room enough to remove the large neoplasm from the nasopharynx. Pharyngotomy sometimes becomes necessary.

MALIGNANT NEOPLASMS OF THE NASOPHARYNX.

Sarcomata.

Primary sarcoma of the nasopharynx is rare, but sarcomatous growths may spring from the roof of the pharyngeal vault; more rarely along the lateral or posterior walls. They usually extend from the nasopharynx into nasal cavities, and break through the walls of the orbit, antrum or cranial cavities. Sarcoma of the nasopharynx occurs in both adults and children.

Lymphosarcomata.

Lymphosarcoma also occurs primarily in the nasopharynx. At the onset it appears as a swelling of the adenoid tissue, but it rapidly degenerates and ulcerates. There is always marked anemia and cachexia, and the disease invariably terminates fatally in a few months from exhaustion, inanition or asphyxia.

Prognosis.—The prognosis is unfavorable.

Treatment.—The treatment of sarcoma and lymphosarcoma is palliative and is resorted to for the relief of distressing pressure symptoms. Surgical removal of portions of the growth is sometimes undertaken for the purpose of re-establishing drainage and the relief of pain. The internal administration of large doses of arsenic in the form of Fowler's solution has been recommended. Trypsin and other similar remedies (see Chapter XLII) have not produced encouraging results.

Carcinomata.

Primary carcinoma of the nasopharynx is exceedingly rare and much less common than sarcoma. The point of origin is usually in the superior pharyngeal wall, from which the growth extends to the surrounding structures, especially the soft palate and pharynx. They develop rather slowly, pain is not severe until pressure occurs, and hemorrhage is less common and constant than in sarcoma.

The diagnosis is dependent upon the microscopic findings, but the symptoms are fairly characteristic.

Prognosis.—The prognosis, even when operation is resorted to, is unfavorable, and recurrence is the rule. The patients usually succumb to exhaustion after months of intense suffering.

Treatment.—In the earlier stages radical removal may be attempted and may result in prolonging life, but the growths almost invariably recur. The pain should be relieved by morphine.

Teratomata.

Tumors of this class are congenital, and when occurring in the nasopharynx seldom attain any considerable size. Their attachment is sometimes so slender that they become detached spontaneously. One case has been reported in which the child swallowed the tumor, voiding it next day per rectum. They have been known to project into the floor of the pituitary fossa, thereby causing compression of the optic tract and nerves.

FOREIGN BODIES IN THE NASOPHARYNX.

Masses of food or of harder substances occasionally become lodged in the nasopharynx as a result of vomiting or regurgitation. This accident is particularly liable to befall those who have paralysis, especially children with postdiphtheritic paralysis. Bullets and other projectiles may also find lodgment in this location.

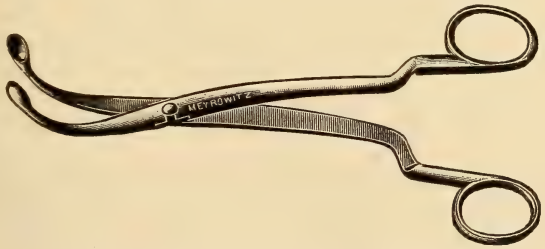

Fig. 459.—The Hooper adenoid forceps.

Symptoms.—Sudden obstruction to nasal respiration following an attack of vomiting is generally the first symptom noted. Smaller substances give rise to an uncomfortable stuffy sensation, the patient usually ascribing it to something in the upper part of the throat.

Diagnosis.—In addition to the characteristic symptoms, the diagnosis is made by rhinoscopic or digital examination. Cocaine should be freely applied to the surrounding tissues in order to allay the reflex irritation. Quite often the foreign body is visible below the border of the soft palate, or can be seen by introducing a palate retractor.

Treatment. — Removal with forceps is the usual method employed. The small Hooper adenoid forceps (Fig. 459) are adaptable for this purpose, inasmuch as this instrument conforms well to the pharyngeal vault. The procedure is usually comparatively simple in experienced hands, and can be carried out without the induction of general anesthesia.

CHAPTER XLIV.

DISEASES OF THE OROPHARYNX.

I. SURGICAL ANATOMY.

THE oropharynx or "pharynx proper" (Fig. 21) lies below the level of the soft palate and is thus distinguished from the nasopharynx. It has no anterior wall, inasmuch as this space constitutes its avenue of communication with the mouth (Fig. 437). The posterior wall is formed by a portion of the cervical vertebræ (chiefly of the body of the axis), and of the longus colli and recti capitis anticus muscles. It is nearly flat under normal conditions. The lateral walls are made up of loose connective tissue and the constrictor muscles of the pharynx, these structures at the same time protecting the large blood-vessels of the neck. The mucosa is similar to that of the nasopharynx, but is lined with stratified epithelium. Nodules of lymphoid tissue are scattered over the oropharynx, especially the posterior wall, and a chain of lymph-nodules on the lateral walls is continuous with the lymphoid tissue of the nasopharynx.

The **soft palate,** also known as the **velum palati,** is made up of two layers of mucosa, between which muscle fibres are interposed, and it is attached to the posterior border of the hard palate. A median, anteroposterior raphe marks the line of attachment of the two lateral halves. A conical-shaped prolongation of this line at the lower border is known as the uvula. The lateral portions of the free border arch downward and divide into two folds, one of which contains the palatoglossus muscle and is attached to the lateral margin of the tongue. This fold constitutes the anterior pillar of the fauces. The remaining fold contains the palatopharyngeus muscle, which is inserted into the lateral and posterior wall of the oropharynx. This fold forms the posterior pillar of the fauces.

The Tonsils.—The faucial tonsils, two in number, are deeply located between the anterior and posterior pillars of the fauces, on either side. They are largely composed of lymphoid tissue supported by a framework of connective tissue, and the exposed surfaces, even of the crypts, are covered with mucous membrane. The outer surface (base) is sheathed in a fibrous capsule which rests upon the superior constrictor muscle. Normally the tonsils do not project beyond the pillars of the fauces and are invisible by ordinary inspection. The tonsil receives its blood-supply chiefly from the tonsillar branch of the facial. It is further supplied by the dorsalis linguæ from the lingual, the ascending palatine, the ascending pharyngeal from the external parotid, and finally from the descending palatine artery.

When slightly diseased or hypertrophied, canals or crypts appear in the glandular substance. As the hypertrophy increases, the tonsil projects beyond the borders of the pillars into the pharyngeal space, the surfaces being studded with lacunæ, which serve as openings for the crypts.

The Lingual Tonsil.—Along the posterior border of the tongue, between the circumvallate papillæ and the epiglottis, is located the so-called lingual tonsil, which is made up of a conglomerate mass of lymph-glands. These are visible only when the lymphoid tissue is hypertrophied. Histologically, the lingual and faucial tonsils are identical. Occasionally a mass of distended and varicose veins occupies this site and is designated as lingual varix. Enlargement of the lingual tonsil and varix often gives rise to reflex throat symptoms.

The Tongue.—The tongue may present asymmetry, cicatrices, or impaired motility as a result of various neuroses, and it is also subject to a number of pathological conditions, such as ranula, lupus, cancer, syphilis and leprosy. It varies within wide limits in regard to size, surface, and firmness of texture, while its color and secretion afford a fair index to the general health of the individual.

The lingual artery passes forward on the tongue, close to the lower end of the faucial tonsil, where it may readily be compressed. In operations on the faucial tonsil, whether from within or from without, the direct vicinity of the carotid arteries as well as the ascending pharyngeal and ascending palatine vessels is of much surgical importance. The palatine muscles assist in the movements of swallowing and also participate in the production of the voice. The tensor and levator palati muscles influence the auditory function on account of their relation to the Eustachian tube.

An important function of the soft palate, aided by the palatine arches and the uvula, is the closing off of the middle pharyngeal space from the upper portion of the pharynx during the act of swallowing. The various diseases of the oropharynx and velum very commonly give rise to disturbances of swallowing; less frequently of speech, and rarely of respiration.

The oropharynx communicates with the buccal cavity through the faucial isthmus, the circular boundaries of which are represented by the velum palati, the faucial arches and the base of the tongue.

To inspect the entire oropharynx, including the posterior wall, the two lateral walls and the velum, involves the employment of a pharyngeal mirror and the tongue must be depressed and the velum relaxed.

The mucosa of the posterior and lateral walls is normally of a more vivid red than that found in the buccal cavity. As a rule it is smooth, moist and glistening, but it may present a somewhat roughened and uneven appearance without being diseased. A number of more or less distinct blood-vessels traverse the posterior pharyngeal wall. Pathological conditions involving this area tend to progress either toward the nasopharynx or toward the larynx.

Under normal conditions moderately enlarged pharyngeal tonsils begin to undergo involution about the age of puberty, the process usually being concluded at about the twenty-fifth year.

II. MALFORMATIONS AND DEFORMITIES OF THE OROPHARYNX.

The malformations observed in the oropharynx are: stenosis, dilatation (pharyngocele) or diverticula, and asymmetry. Of these the most common is stenosis, which may occur as a congenital condition or secondarily as a result of injury to or inflammation of the surrounding structures. Congenital atresia is very rare, and but few cases of complete atresia have been reported. Cases of partial atresia are more common. Reports of complete closure have shown that the atresia occurs in conjunction with pouches. Stenosis when following inflammatory diseases or injury is due to cicatricial contraction. Syphilis furnishes by far the larger proportion of this class of cases. Adhesion of the velum to the posterior pharyngeal wall (Fig. 285), with the attendant contractions, leads to a variety of pharyngeal deformities, many interfering with the act of deglutition, and all characterized by more or less interference with nasal respiration. These adhesions sometimes extend well up into the nasopharynx or downward into the laryngopharynx, where the scar tissue and adhesions prove most troublesome. Traumatism usually results from the accidental ingestion of scalding or caustic fluids. Cases of this class often result fatally before a permanent stenosis has developed, but edema is present during the acute inflammatory period. Spasm of the pharynx occasionally occurs in neurotic individuals or as a result of the bolting of food.

Another form of stenosis, described as the extrinsic variety, results from outside causes which produce a partial closure of the pharyngeal lumen. Diseases of the vertebral column, deformities or forward curvature of the spine or twisting of the vertebræ, are liable to infringe upon the pharyngeal space. In like manner retropharyngeal abscess, marked enlargement of the lateral lobes of the thyroid gland, peritonsillar abscess, together with Hodgkin's disease, rhinoscleroma and the various malignant growths, may produce the extrinsic form.

Diverticula or Dilatations of the Pharynx.

Unless congenital, these are usually found as a result of mechanical causes, such as distention from the bolting of large masses of unmasticated food. This form is rarely observed in early life; it comes on in consequence of the loss of teeth or the prolonged habit of bolting. Large pouches or dilatations are known as pharyngocele. The condition is occasionally congenital, when it is associated with atresia. In the author's cases the diverticula have invariably occurred in the upper portion of the

esophagus. Whenever a pharyngeal pouch is large and becomes temporarily filled it commonly produces a tumor-like external prominence which may be felt upon palpation. Patients are sometimes able to disgorge the contents of the sac by pressure from without. A form of treatment recommended in severe cases is the application of a properly fitted pad over the site of the tumor. In a case now under treatment the diverticulum is small, but it is still of sufficient size to interfere with "large masses of food when hurriedly swallowed."

Treatment.—The food should be largely of liquid or semi-liquid consistency and should be swallowed slowly. The occasional introduction of large esophageal bougies, by overcoming constriction above or below the pouch, is thereby of distinct advantage.

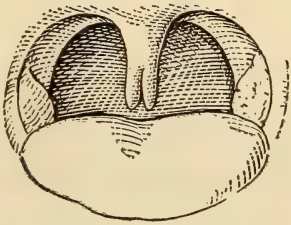

Fig. 460.—Bifid uvula.

Asymmetry of the Pharynx.

This usually results from some abnormal or unusual prominence of vertebra or from exostoses of underlying bone. Cervical curvature or twisting of the vertebræ may reduce the calibre of the pharynx and give rise to some distress upon swallowing. These conditions are only to be found with retropharyngeal abscesses, or some form of tumor. A digital examination is usually sufficient to make the diagnosis complete.

III. MALFORMATIONS AND DISEASES OF THE UVULA.

The uvula admits of considerable variation in size under normal conditions. Congenital malformations, however, do occur, the chief of which are known as *bifid uvula* (Fig. 460), wherein the median elongation is divided into two portions usually of equal size. The extent of the bifurcation varies, but may be sufficiently deep to give the appearance of double uvula. This condition is undoubtedly analogous to congenital cleft of the soft palate. The *rudimentary uvula* is a form of malformation in which the uvula is only slightly developed and occasionally is absent altogether. No special symptoms are manifest in either of these conditions, nor do they cause annoyance or discomfort to the patient.

Treatment.—If desired the bifid form may be operated upon by scarifying the opposing edges and uniting them by sutures.

Elongation of the Uvula.

Elongation of the uvula beyond the limitations of the normal may or may not be attended by pathological changes in the tissues and by characteristic symptoms.

Etiology.—The condition is sometimes congenital, consisting of a redundancy of apparently normal tissue. In other cases relaxation occurs, usually attended with anemia, which involves the soft palate as well. Partial paralysis occurring as a sequela of scarlet fever or diphtheria may give rise to the appearance of elongation of the uvula. Another form of elongated uvula is observed in connection with acute and chronic inflammations of the tissues of the upper air passages. Furthermore, elongation of the uvula, together with general relaxation of the soft palate, is commonly associated with the various digestive disturbances, which are grouped under the general heading of dyspepsia.

Abscesses or other tumors, when they develop in the surrounding

Fig. 461.—The McKenzie uvulotome.

tissues, may force the uvula downward, and in so doing the latter usually becomes edematous.

Symptoms.—The chief symptoms induced by elongation of the uvula are a tickling sensation in the fauces, cough, and in extreme cases considerable interference with deglutition. Where the elongation amounts to two inches or more (Fig. 494) the patient literally swallows the uvula. The cough is aggravated by the recumbent position.

Diagnosis.—Upon examination the uvula may be simply elongated, without much change in its lateral dimensions. The tip often extends downward into the glossoepiglottic space.

Treatment.—When the elongation is considerable and gives rise to the symptoms above mentioned, the rational treatment consists in the surgical removal of the redundant portion. Astringent sprays or applications of adrenalin chlorid sometimes produce a temporary retraction. In every instance a careful examination of all adjacent tissues should be made in order to ascertain any primary cause other than congenital. Relaxation associated with temporary paralysis requires the benefits of the internal administration of blood-building agents, together with outdoor life and the most nutritious food.

Surgical Removal.—Excision is accomplished as follows: After carefully cleansing the entire mucosa of the oropharynx, the uvula should be anesthetized by painting with a 10 per cent. solution of cocaine. It is never wise to remove the entire uvula, the removal of the redundancy being all that is required. While several instru-

ments have been devised for this operation, notably the uvula scissors or some form of uvulotome (Fig. 461), the procedure is quite as well accomplished with a pair of ordinary long-handled scissors slightly curved upon the flat, the tip of the uvula meanwhile being grasped with suitable forceps. The tongue should be depressed, and the cut should be slightly slanting, the anterior portion of the uvula being left longer than the posterior. Less pain and irritation follow this form of excision, for the anterior dependent membrane serves to protect the wound during the act of swallowing. Stitches are of no benefit. As a rule, but slight hemorrhage is encountered, although at times bleeding persists for some time. Cases of alarming hemorrhage have been reported. A gargle or the application of adrenalin chlorid is usually sufficient to control ordinary hemorrhage. If it should persist, temporary clamping with forceps, ligation or cauterization may be resorted to. These procedures are not difficult.

Fig. 462.—Edema of the uvula, with small punctures for the removal of serum.

After-treatment. — Considerable inflammatory reaction follows the operation, and severe pain ensues, which is aggravated during deglutition. Soft food with but little seasoning should constitute the diet for a day or two following the operation. The surfaces may be kept clean by means of warm gargles of normal salt solution or a weak solution of formaldehyd.

Acute Uvulitis.

Etiology.—The texture and exposed location of the uvula render it peculiarly liable to injury, inflammation and edema. These affections commonly result from extension of adjacent inflammations or from such injuries as cuts from sharp objects, such as fishbones, or from scalds or burns. Specific ulceration is not uncommon, and the edematous variety (Fig. 462) sometimes occurs as a result of the pressure from the encroachment of tumors. These may be benign, in the form of abscess or specific gummata, or malignant. Certain cases seem to occur as a result of diathesis or errors of digestion.

Symptoms.—A tickling, stinging, painful sensation, aggravated by attempts at swallowing, is the first symptom observed. As the

swelling and edema increase, owing to the infiltration of serous exudate into the soft, yielding tissues, the uvula tip becomes bulbous, elongated, and impinges upon the base of the tongue and epiglottis. The irritation thus induced evokes a persistent cough. In extreme cases respiration may be seriously obstructed, especially when in the recumbent posture.

Diagnosis.—On the site of the uvula a large, boggy, inflamed, often edematous pendant mass will be observed, partially filling the oropharyngeal space. The edematous portions are usually found about the tip and posterior surfaces.

Treatment.—In moderate cases during the early stages before edema appears, frequent gargling with glycerid of tannin, 1 dram to the ounce, is advisable. In edematous cases topical applications are without avail, and serum should be removed by simple puncture (Fig. 462) of the tissues, under cocaine anesthesia. In puncturing, care should be taken to avoid injury to the posterior pharyngeal wall. A sharp-pointed bistoury is the most convenient instrument. With this, from five to fifteen punctures are often necessary in order to drain the tissues, relieve the pressure, and thus enable the blood-vessels to carry off the remainder of the exudate. Before making the incisions the entire oropharynx should be thoroughly cleansed by means of sterile salt douche or gargle. It is sometimes necessary to repeat the punctures daily for two or three days. A gargle containing 1 to 3 grains of sulphate of copper to the ounce of water or a hot normal salt solution is beneficial. These tend to aid in the process of repair, and at the same time maintain proper cleanliness. When associated with abscesses, inflammations or tumors of the surrounding tissues, the latter affections must also be subjected to appropriate treatment.

Free catharsis at the commencement of the attack tends to lessen its severity, shorten its course and minimize the edema. Whenever the disease is due to errors of digestion or assimilation it is incumbent upon the surgeon to submit the patient to a thorough examination of the entire digestive tract, the heart, blood-vessels and kidneys.

IV. ULCERATIONS AND ADHESIONS.

Ulcerations and adhesions of the uvula and soft palate usually result from tertiary syphilis. The superficial ulceration of the mucous patch occasionally involves this region, but without destruction of the deeper tissues. The ulcerations associated with tertiary syphilis are most destructive not only in the loss of tissue, but from the ravages of the cicatricial tissue, which is prone to bind the remaining portions of the uvula and soft palate to the posterior pharyngeal wall (Fig. 285). When observed early the gummatous ulceration yields to the usual specific treatment. But after adhesions have formed they remain and stubbornly resist treatment. Occasionally some relief may be obtained by dividing the cicatricial bands. The adhesions vary in form and extent, from a partial adhesion of one pillar, to a complete attachment of the soft palate which

closes the nasopharyngeal channel. While for the most part these adhesions occur as a result of specific ulceration, lupus and extensive burns may occasionally cause them. The voice becomes affected in proportion to the extent of the adhesions and the obstruction of the nasopharyngeal space. Occasionally perforations directly through either the soft or hard palate are observed.

Attempts to relieve by operative procedure usually end in failure on account of the tendency of syphilitic adhesions to recur.

V. RETROPHARYNGEAL ABSCESS.

This is due to an accumulation of pus in the submucous connective tissue of the posterior wall of the pharynx.

Etiology.—As the name implies, any formation of pus, from whatever cause, developing in the posterior pharyngeal space would necessarily be considered a retropharyngeal abscess. The disease occurs with greater frequency in young children and the exciting cause, which is an invasion of the pathogenic micro-organisms into this space, is often difficult to discover. In a small proportion of cases the disease arises from caries of the cervical vertebræ and is either syphilitic or tuberculous. The infectious diseases of childhood probably furnish the larger proportion of all cases. Ulcerations of the postpharyngeal mucosa from any cause furnish a pathway for infection to enter.

Symptomatology.—The symptoms show marked variations between children and adults. In young children the process develops rather slowly and, as a rule, is not noted in the early stages, during which the chief symptoms are lassitude, fretfulness and loss of appetite. After a few days considerable cough appears, with the marked changes in the character of the voice described by Regnier[1] as *"le cri de canard."* As the disease progresses, deglutition becomes difficult and painful. Examination of the pharynx at this time will show bulging of the posterior wall largely unilateral, and the pus burrows in all directions, but chiefly downward. The surface becomes extremely tense and inflamed, but fluctuates under pressure. In adults the onset is usually more sudden, and is characterized by pain, similar to that experienced in an attack of quinsy, by difficult deglutition, partial loss of voice and moderate rise of temperature. The pain and dysphagia increase until relieved by rupture of the abscess or by incision.

Diagnosis.—Inspection and palpation furnish the necessary information. There is bulging of the posterior pharyngeal wall with displacement of the soft palate and uvula and a sensation of fluctuation.

Differential Diagnosis.—In young children the objective symptoms of the disease somewhat resemble those of croup, which must be eliminated by inspection and palpation. In adults a large syphilitic gumma or other form of tumor unattended by ulceration might

---

[1] Concours méd., 1882, vol. 4, p. 578.

be mistaken for abscess. Here also palpation serves to differentiate.

Prognosis.—When discovered early and evacuated promptly the prognosis is good, but the cavity tends to refill, often requiring a second or third incision. The prognosis is less favorable in cases arising from caries of the cervical vertebræ. Fatalities have occurred from strangulation due to filling up of the larynx from the sudden rupture of a large abscess.

Treatment.—The abscess cavity should be evacuated by free incision. In order to prevent suffocation from the flow of pus into the larynx the head should be lowered and held in the lap of the assistant, and the operation should be performed without an anesthetic, on account of the attendant dyspnea. The mouth should be forcibly opened with a retractor and the tongue firmly depressed. The pointed bistoury should be introduced as low down as possible upon the posterior pharyngeal wall, and a free incision carried well through the entire abscess wall. Following the incision, sufficient pressure should be made on the walls of the cavity to express all the retained pus, much of which will flow through the nostrils as well as the mouth. Immediate relief follows this procedure. For several days subsequently the throat should be carefully examined and the abscess reopened whenever pus reaccumulates.

Whenever the retropharyngeal abscess results from caries of the cervical vertebræ it should be approached externally, the abscess evacuated and all necrosed bone curetted away.

As a rule, the recovery of these patients is facilitated by the internal administration of some form of iron or cod-liver oil, by nutritious diet and by a prolonged period of life in the open air.

CHAPTER XLV.

DISEASES OF THE OROPHARYNX.
(*Continued.*)

ACUTE INFLAMMATORY DISEASES.

I. SIMPLE ACUTE INFLAMMATIONS.

1. Simple Acute (Catarrhal) Pharyngitis.

ACUTE catarrhal pharyngitis is an acute inflammatory process involving the mucous membrane of the pharynx, which gives rise to congestion and, in severe attacks, to infiltration of the tissues, with hypersecretion. The pharynx may be the chief seat of the attacks, or merely a part of a general attack of "acute cold" involving the upper respiratory tract.

Etiology.—Acute pharyngitis is dependent upon no single etiological factor, but is due to a wide variety of causes and conditions best described under the headings *predisposing* and *exciting.*

Predisposing Causes.—Predisposition to the affection is based largely upon: 1. Lowered vitality resulting from unhealthy surroundings, sedentary occupations, living in badly ventilated quarters and in poisonous or dust-laden atmosphere, and from excessive or insufficient clothing. Chronic pharyngitis predisposes to acute attacks. 2. Constitutional disorders, whether of digestive or assimilative nature, or with a gouty or rheumatic diathesis, occasionally the menstrual epoch in women. 3. Catarrhal inflammations of the nose, nasopharynx and larynx. 4. Excessive indulgence in stimulants, especially alcohol and tobacco. 5. Physical exhaustion.

Exciting Causes.—Sudden or prolonged exposure to cold, especially when the body is freely perspiring, is the most frequent exciting cause, particularly in individuals who are predisposed to the disease. In weakened individuals draughts of air upon the back of the neck or head may give rise to the affection. Inflammation of the adjacent structures usually accompanies this disease, and it commonly occurs in conjunction with acute catarrhal rhinitis or laryngitis. It is more prevalent during cold weather, and especially during prolonged periods of extreme dampness of the atmosphere.

Symptomatology.—While the symptoms vary considerably as the result of the variation in the predisposing causes, the actual attack is sudden, with a marked sensation of dryness and considerable pain and soreness about the pharynx, which is aggravated during phonation and deglutition. The inflammation is usually extensive, involving the posterior pharyngeal wall, the uvula, soft palate, and pillars of the fauces. These become markedly congested, and in severe cases the stasis is sufficient to evoke

edema of the uvula and soft palate. The continued inflammation and swelling of the posterior pharyngeal wall give rise to a sensation similar to that of a foreign body, and the patient attempts to relieve the dryness by frequent swallowing. There is rarely a distinct chill, although chilly sensations may be complained of. There is some rise of temperature, varying from 99° to 103°. Pain is usually complained of and is more severe in patients who are victims of the gouty or rheumatic diathesis. In severe cases there is considerable difficulty in swallowing and a consequent disinclination to partake of solid food. Cough is usually present, but it is usually referable to the accompanying laryngitis. When edema is present the symptoms are sufficiently annoying to disturb sleep. There is but little secretion at first, but after exudation begins it becomes profuse, being at first serous, but gradually becoming mucopurulent. There is considerable interference with the timbre of the voice.

Diagnosis.—Visual inspection alone cannot always be relied upon to differentiate between simple acute pharyngitis and the pharyngeal inflammations which accompany the exanthemata or epidemic infections like *la grippe*. A positive diagnosis should not be made until sufficient time has elapsed to make sure that one of the acute infectious diseases may not be the primary cause. There is always the possibility that the acute inflammation is the forerunner of a syphilitic pharyngitis. Ordinarily, however, the history, examination and accompanying nasal and pharyngeal inflammatory process are sufficient to render a diagnosis comparatively easy.

Prognosis.—The prognosis is good, complications are rare, and recovery takes place in from two to ten days.

Treatment.—In the matter of treatment each case must be a law unto itself, on account of the variety of causes.

The requirements of local treatment are first that the mucous surfaces should be thoroughly cleansed and all tenacious mucus removed. This is best accomplished by means of alkaline sprays, which both soften and detach the secretion. This should be followed by an oily medicated spray like the O. B. Douglass formula of benzoinol (see page 499). During the acute stage no stimulating applications should be made to the mucous surfaces, but soothing remedies only are indicated. Iodin compounds, strong solutions of nitrate of silver, ichthyol, tannin, etc., are contraindicated during this stage, but as soon as the acute inflammatory process commences to subside, mildly stimulating applications may be employed with benefit. As a rule, all preparations of this kind are too severe and are employed in solutions too strong. Sprays are preferable to gargles, but direct application by means of the cotton-tipped applicator is an effective method of employing these remedies. It is difficult for the majority of persons, especially children, to employ gargles thoroughly and intelligently, inasmuch as the pharyngeal muscles are contracted rather than relaxed and the remedy does not come into contact with all the surfaces. The pain and irritation may be considerably alleviated by the use of some soothing

remedy in the form of tablets or lozenges, which may be allowed to dissolve slowly in the mouth, and which are composed of small quantities of menthol, camphor, and codeine. A lozenge composed of:—

℞ Menthol ..... gr. 1/20.
Ol. eucalyptus ..... *m* j.

is effective in relieving pain and irritation. Among the milder astringent applications are the so-called Mandl's solution (see page 518), a 25 per cent. solution of argyrol, or a spray containing 10 grains of tannic acid to the ounce. A useful astringent gargle is one composed of:—

℞ Potassii chloratis ..... gr. xxx.
Ferri chloridi ..... ʒij.
Glycerini ..... ʒiv.
Aquæ .....q. s. ad ℥iv.
M. Sig.: One dram in water as a gargle every two hours.

When swabbing or spraying the pharynx, the tongue should be well depressed and the patient instructed to utter sounds like *a* or *ah,* in order to expose the posterior pharyngeal wall to free view.

Cold-water compresses or coils about the neck, especially at night, prove grateful to many patients, and seem to diminish the tendency to pain and swelling. Compresses should not be employed except during the early acute stage.

Internal Treatment.—A great variety of internal medications have been recommended. Their employment, however, should be based upon the constitutional conditions which are present in the individual case. As a rule, a cathartic when administered at the commencement of the attack lessens its severity and shortens its duration. Experience has shown that calomel produces the best results. For an adult the dose should be 5 or 6 1/4-grain calomel tablets, administered at intervals of about one hour, preferably during the evening, and followed by a liberal draught of a saline early in the morning. In young children from 5 to 10 1/10-grain calomel tablets, according to age, should be given. If for any reason calomel is contraindicated, other forms of cathartics may be employed. The rheumatic patient should be given salol or salicylate of soda, 10 grains, every three or four hours, until the symptoms disappear. These remedies may be combined with phenacetin, 5 grains every four hours in cases of unusual pain. Large doses of bicarbonate of soda, 10 to 20 grains in 1/3 glassful of water, every two hours during the day, or until the urine shows an alkaline reaction, will be found of great benefit. The so-called uric acid diathesis, in which the urinary secretions show an excess of acid, is also benefited by this procedure. Bodily resistance is aided by the administration of quinine during the early stages. The dryness of the membranes of the pharynx complained of during the early stages requires the administration of some form of drug to stimulate the secretions. Aconite, in minim doses three or four times an hour, has this effect,

but should be discontinued as soon as the result is obtained. The treatment of colds is described more fully in Chapter XXXIII.

2. Simple Acute (Catarrhal) Tonsillitis.

Definition.—The catarrhal form of tonsillar inflammation is rarely an independent disease, but is a part of a general acute inflammation of the upper respiratory tract, in which the tonsil is the primary seat of the onslaught.

Etiology.—This condition is more commonly observed among children, probably on account of the tendency to an increase in the lymphoid structures at this period of life. It usually develops as a result of exposure to cold or dampness; occasionally, however, it is due to mechanical irritation from the inhalation of irritating vapors or fumes.

Symptoms.—The symptoms are similar to those observed in attacks of catarrhal inflammation of the upper air passages in ordinary cold in the head. The burning and painful sensation during deglutition is similar to that of acute pharyngitis, with additional stiffness and fullness about the tonsils. The mucous membrane covering the tonsil appears turgescent and swollen, and there is considerable serous exudate. In severe cases the pain radiates toward the ear and is often mistaken for otalgia. A rise in temperature from 100° to 103° is noted, especially in children. The alteration in voice and other symptoms, such as sneezing and coughing, result from the more general inflammatory process.

Diagnosis.—The absence of deposits in the tonsillar crypts, the superficial nature of the inflammation and its association with a cold are sufficient to point to its acute catarrhal character.

Treatment.—In addition to the treatment for acute pharyngitis, described in the previous paragraph, the inflamed tonsil should be treated as follows: Painting the acutely inflamed tonsil with a solution of nitrate of silver, 20 to 40 grains to the ounce, often aborts the attack or else limits its duration. The ammoniated tincture of guaiac, recommended by Sajous, a teaspoonful to a cup of cold milk, stirred well, of which mixture a mouthful is used as a gargle every ten or fifteen minutes, will often shorten the attack. The author believes that a tonsillitis is many times the local manifestation of some systemic intoxication or diathesis (the uric acid, gouty or rheumatic) and in these conditions the appropriate constitutional treatment should be added to the local applications.

II. ACUTE INFECTIOUS INFLAMMATIONS.

The pharynx, tonsils, larynx and the glandular structures of the neck are subject to local infections of an inflammatory character, in which a systemic involvement usually accompanies the local condition. While there is considerable variation in the clinical manifestations of these affections, the etiological factors are the same, the variations being due to the virulence of the primary infection and the location of the disease.

1. Acute Infectious Pharyngitis.

There are two chief varieties of acute infectious pharyngitis, viz.: (*a*) acute parenchymatous pharyngitis; (*b*) acute membranous pharyngitis.

(*a*) **Acute Parenchymatous Pharyngitis.** *Definition.*—The infectious form of pharyngitis is an acute inflammation of bacterial origin which invades the tissues of the pharynx. A variety of clinical manifestations has been described as septic pharyngitis. In its simplest form it is characterized by severe superficial inflammation of the pharyngeal mucosa similar to that of simple acute pharyngitis, but in the severe forms it attacks the submucous tissues and assumes the form of erysipelas, phlegmon or gangrene. It often occurs superficially in connection with infectious tonsillitis.

Etiology.—Bacterial invasion through the mucous membrane is the exciting cause, and the streptococcus is the usual organism found. Among the many predisposing causes are: grave systemic diseases, especially diabetes, Bright's disease, infectious fevers; exhaustion, chronic alcoholism, exposure to cold, traumatism, etc., while simple ulcerations or abrasions of the mouth or pharynx are contributing causes.

Pathology.—The pathological changes depend upon the virulence of the pathogenic organism and the general condition of the individual at the time of invasion. In the milder cases rapid and intense infiltration of the tissues of the pharynx occurs. The mucous membrane becomes tense, glistening and of a dark-red hue. The tonsils and uvula rapidly become inflamed and edema of the latter is common. The general appearance of the pharynx is that of erysipelas. Exudation is scant in the early stages; later, however, a serous exudate flows both from the pharyngeal mucosa and the lacunæ of the tonsils. In the severe types the tissues of the pharynx or the uvula may become necrotic and occasionally gangrenous. There is a marked tendency for the disease to spread, either downward to the larynx or to the lymphatic glands about the neck.

Symptoms. — The general symptoms are those common to sepsis: remitting temperature, chills and general malaise. There is a sudden onslaught of intense pain in the throat. As the swelling increases, a sensation of fullness, dysphagia and voice changes rapidly ensue. If sloughing or gangrene is present the breath becomes extremely fetid, and, in grave cases, delirium and coma occur. Whenever the disease spreads to the glands of the neck, local symptoms—swelling, pain, and abscess—occur.

There is an acute throat infection involving either the pharynx or tonsils, entirely due to streptococci, which is undoubtedly a streptococcemia and is not usually mentioned in text-books. The author has observed two cases in children, eight and ten years old, respectively.

Locally, the pharynx and tonsillar region were reddened. The patient complained of some pain on swallowing, had headache,

malaise, chills and a rise of one to four degrees of temperature. Vomiting and diarrhea persisted on and off for three days. The temperature was typhoid in character, remitting; the pulse was weak, at times irregular, and increased with each rise in temperature. Prostration was pronounced. Both developed a septic endocarditis, which cleared up and left no permanent cardiac damage. A slight albuminuria persisted for eight days. Under mild antiseptic alkaline gargle (sodium chlorid and borate) the inflammation of the throat cleared up in a few days, but the general systemic condition yielded only after three weeks, and both made a good recovery.

They were treated with guaiacol carbonate, 5 grains every four hours, and inunctions of unguentum Credé, 20 grains rubbed into the skin for ten minutes three times a day. The recumbent position, sponge baths, good nursing and restricted dietary were resorted to.

Diagnosis.—While the disease is comparatively rare, the local manifestations are usually sufficient to establish a diagnosis, retropharyngeal abscess of the region being the only affection with which it may be confounded.

Prognosis.—When severe the disease places the patient's life in danger, and a fatal issue may result from the overwhelming effects of the septic poisoning on either the heart or kidneys, or from pharyngeal edema.

Treatment.—At the outset free calomel purgation is essential. A bacteriological examination of the secretions should be made in order to determine the nature of the infecting organisms. Quinine in 5-grain doses three times daily during the first two or three days and large doses of perchlorid of iron, 20 to 30 minims every four hours, are recommended. The antistreptococcic serum has been recommended, and Dr. Santi reports three recoveries where he employed this remedy in doses of from 10 to 20 c.c. During the early stages some benefit may be obtained from the use of applications or gargles containing formaldehyd. Unfortunately, formaldehyd, unless largely diluted, causes pain, but is better borne about the throat than in either the nose or larynx. The inhalation of vapors of benzoin or creosote are soothing. The pain attending swallowing is relieved by spraying the pharynx with a 2 per cent. solution of cocaine ten minutes before eating. Sloughs and gangrenous masses should be removed and the surfaces cleansed by applications of alkaline solutions or peroxid of hydrogen. Bearing in mind the septic nature of the affection, every effort should be made to conserve the patient's strength. Raw eggs, milk and strong broths are indicated. When swallowing becomes difficult, nutritive enemata may be employed. Stimulants in the form of strychnia or alcohol are recommended whenever the pulse becomes weak. The kidneys should be carefully guarded throughout the illness.

(*b*) **Acute Membranous Pharyngitis.**—The etiology, pathology and treatment of membranous pharyngitis is similar to that of membranous tonsillitis and membranous laryngitis, to which the reader is referred.

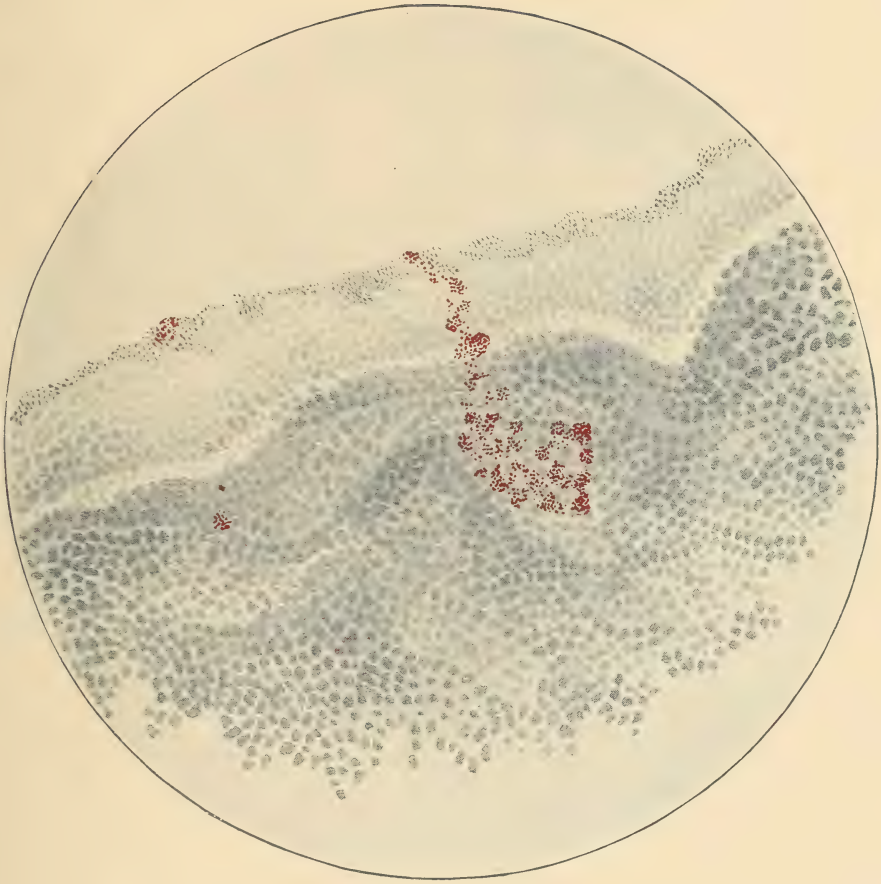

Fig. 463.—Carmine granules passing the epithelium of the tonsil from without, bacteria remaining on the surface. *(Jonathan Wright,* with permission.)

2. Acute Infectious Tonsillitis.

Comments upon the Function of the Tonsil.—Wright[1] (in several publications) gives his views concerning the function of the tonsil and asserts that we are unable to describe the function or physiology of the tonsil as these terms are ordinarily used, but rather to speak of the tonsil in its relation to the process of immunity and infections. His reasoning is based upon deductions drawn from his own experimental studies in the domain of pathology compared with similar phenomena in the realm of biology and physics. He contends that the selective action of the epithelium of the tonsil upon dust and bacteria (Fig. 463), whereby the latter at times is prevented from passing and at others is allowed to pass freely into the lymph channels, is not fully explainable from the laws of immunity, but rather that we are dealing with living matter which obeys the laws of heredity and of evolution, and that adaptation by natural selection is the only explanation why the protoplasm of the epithelial cells of the tonsillar crypts acts in the way it does.

Clinically, it has long been known that infectious germs, especially streptococci, are commonly found in the tonsillar crypts of healthy individuals, and that autoinfection is probably essential in order to induce follicular tonsillitis. Wright believes that associated with the autoinvasion there is the antecedent etiological factor of a molecular disturbance of the sympathetic, induced by exposure, fatigue and various functional and systemic disorders and diseases; and further that there is a wide difference in the surface tension, depending upon the physicochemical state of the fluids in which the epithelial cells are bathed. He concludes that, with our present knowledge, it is not accurate or proper to consider or discuss the physiology or the function of the tonsil. He adds the significant comment that it is a highly interesting sequence of events which takes place between the time the germ floats on food or in the air into the tonsillar crypts and the time it reaches the deep lymphatics which drain the tonsil. He regards it as a biological process of a physicochemical nature, affecting the surface tension of the colloids of which the cells and bacteria are composed.

The Tonsils as Portals of Infections.—Stöhr and others have defined the peculiar arrangement of the epithelial lining of the tonsillar crypts wherein dehiscences exist which are believed to permit the entrance of micro-organisms and foreign bodies into the subepithelial strata. Goodale, Kayser, Wood and others have demonstrated that foreign bodies and bacteria actually do pass through the epithelium of the tonsil.

Strassmann examined the tonsils from 21 cases of tuberculous cadavers and found tuberculous tonsils in 13. Wright and Walsham found no tuberculous process in a series of removed tonsils, but

[1] Laryngoscope, May, 1909.

this fact does not preclude the possibility that they may be avenues of infection.

Primary tuberculosis of the tonsils is believed to be comparatively rare. On the other hand, it is probable that in many cases the secondary invasion of the tonsil is never recognized, especially when it appears as a late manifestation.

Williams contends that even "primary tuberculosis of the tonsil is less rare than is generally believed, and the failure of the faucial tonsils to arrest the development of the bacilli results in tuberculosis of the cervical glands so commonly observed in weakly children."

Concerning the "difference in the behavior of dust from that of bacteria in the tonsillar crypts," Wright[2] experimented with carmine powder dusted upon the tonsils after the manner followed by Goodale and others (Fig. 463) and states that "there is a striking differentiation in the behavior of carmine granules as distinguished from those of bacteria, both on the surface and in the crypts." In the specimen from which the illustration was made but ten minutes elapsed between the dusting on of the carmine and the extirpation of the tonsil and still the carmine had penetrated through the epithelium and the bacteria remained upon the surface. Furthermore, it is apparent, as shown by Wright, that in passing the epithelium into the deeper spaces, the carmine granules did not carry any of the surface bacteria with them. "This is in direct accord with the idea that, at the surface exists adaptative responses requisite to meet those exigencies of habitual environment which do not exist more deeply, and that it is not so much the character of the tissue as its situation which counts in the function of resistance to infection, nor does so much depend upon the violence of the initial insult to the tissues as upon its depth."

A different series of results followed traumatism (curetment of the crypts, puncture of the tonsils, etc.), for bacteria entered the deeper spaces to a limited extent, through the wounded surfaces. In this connection he (Wright) states that: "In several cases the patient, having an enlarged tonsil on each side, was subjected to the curetment of the crypts of one tonsil, leaving the other untouched. Sufficient force was used only to insure the removal of at least some of the epithelium. At the end of two days to one week, both tonsils were removed by the guillotine at one sitting. Hardened, blocked and stained in various ways, it was noticed that both the amount of dust and the number of bacteria were very largely increased within the crypts of the previously curetted tonsil, and, to some extent, in those of the other side there were more bacteria and dust than usual. The histological evidence of inflammation was very marked in the one and present in the other tonsil. Many large round cells (lymphocytes?) were seen along the injured surfaces. The dust seemed to be passing in increased amounts, but bacteria, even at surfaces denuded of epithelium, had

[2] New York Medical Journal, January 6, 1906.

penetrated only a very small distance. In one or two cases long, deep incisions were made through the substance of the tonsil. Subsequently amputated, on one of them small cocci colonies were seen growing at the edge of the cut surface. This was also observed once in the more numerous scraped tonsils. In one case small bacilli colonies were seen growing on the cut surface. These evidences of proliferation, however, were very small in extent and very infrequent in occurrence. In the scraped tonsils many red blood-cells had been effused and still existed in the tonsillar crypts. Often, in such a blood-clot, many bacteria would be growing, in marked contrast to the adjacent tissue, also suffused with blood-cells. In studying the stroma of inflamed tonsils I have been struck with the swollen condition of the endothelium of the lymph channels.

In several cases one of a pair of tonsils was pierced by a sterile stylet of small calibre thrust in several directions. In each of these cases, in the pierced tonsil, small colonies of bacteria were found growing around solutions of continuity at a distance from the epithelium. This would seem to indicate that deep infection of the lymphoid tissue, even with surface bacteria carried in by the stylet or slender knife, without great disturbance of tissue and without much resulting inflammation, meets with less resistance to growth than near the surface, even when the epithelium is partially removed."

Dr. Wright, in a personal communication, summarized his views as follows:—

"My experiments seem to furnish conclusive evidence that under normal conditions bacteria do not penetrate the epithelial layer of the tonsil in sufficient numbers at least to set up disease. Yet we know from clinical experience that nerve shock from fractures, hemorrhage, nasal operations, uric acid (?), sudden cold, etc., produces systemic changes whereby infection is more easy and more dangerous. I believe that the mechanism causing surface infection is a chemicophysical change set up by impulses carried along the sympathetic nerves. This produces an alteration in the surface tension existing normally between the bacterial denizen of the tonsillar crypt and the epithelium which lines it. By virtue of this change the living pathogenic agent enters the system. It is probable that the change in surface tension does not affect the relation of the epithelium to dust."

Acute infection of the tonsillar and peritonsillar tissue may be described under four headings, depending upon the specific locality involved and the clinical manifestations, viz., 1, acute lacunar (cryptic or follicular); 2, acute peritonsillitis (quinsy); 3, acute ulcerative tonsillitis, and, 4, acute membranous tonsillitis.

Etiology.—While the clinical manifestations differ in the above-mentioned varieties, the same etiological factors are more or less common to all. The invariable exciting cause is direct infection with pathogenic micro-organisms. No distinct type of organism is peculiar to tonsillar infections, although the streptococcus pyogenes

is most common. The severity of the attacks and the location of the disease depend upon the patient's general condition, the virulency of the infection, and the condition of the tonsillar and peritonsillar tissue at the time of the attack. A predisposition to the disease exists in certain individuals, especially those who have enlarged tonsils of the chronic lacunar variety. No one, however, is immune.

It is more common between the ages of four and thirty, but it may occur at any period of life. The rheumatic diathesis as a causative factor has been overrated. The disease sometimes attacks even normal tonsils. General lymphoid hyperplasia is a predisposing cause. Shock, overwork, anemia, mental anxiety, constitutional disease, and sojourn in vitiated or damp atmospheres, sudden bodily exposure, especially of the feet, may so lower the vitality as to predispose the individual to this form of tonsillitic inflammation.

Tonsillar infection is a common complication of grippe. It is more prevalent in the winter months and often occurs in epidemic form. This results partially from sudden atmospheric changes, but chiefly from the fact that the dust becomes unduly laden with pathogenic bacteria as a result of epidemics of grippe, scarlet fever and other infectious diseases. The continued presence of bacteria in other portions of the upper respiratory tract predisposes to tonsillar infection.

Pathology. (*a*) *Lacunar Variety.*—As a rule, this variety is bilateral, one tonsil becoming infected some hours before the other, and the pharyngeal mucosa also is inflamed. Primarily there is a marked engorgement of the blood-vessels of the tonsil and inflammatory exudate into both the parenchyma and the crypts. This accounts for the tonsillar enlargement. The lacunæ rapidly become completely filled with a septic exudate composed of epithelium, leucocytes and micro-organisms. These masses are yellowish in color and project from the lacunar openings. Occasionally the lacunar deposit rapidly becomes mucopurulent and overflows the whole surface of the tonsil, to which it gives the appearance of a false membrane, which is sometimes mistaken for diphtheria. After the lapse of twenty-four to forty-eight hours the lacunar secretion is dislodged.

(*b*) *Peritonsillitis.*—In acute peritonsillitis the infection chiefly attacks the peritonsillar structures, in which a violent septic inflammation develops, which generally ends in abscess formation. The affection is usually unilateral, and the tonsil generally participates in the inflammatory process. As the swelling increases, the soft palate and uvula become swollen, congested, and often edematous (Fig. 462). In severe cases the swelling becomes so great as to interfere with both swallowing and respiration, and meanwhile it impedes the mobility of the lower jaw. The inflammatory process usually eventuates in abscess formation, and the pus collects in the supratonsillar tissue and gradually burrows forward and produces tension upon the anterior pillar and the velum (Fig. 466). Spon-

taneous rupture may take place at this point or through the supratonsillar fossa or the posterior pillar.

(*c*) *Acute Ulcerative Tonsillitis.*—Occasionally the tonsils become the seat of an acute ulcerative process. While the ulcerations are not deep-seated or attended with extensive parenchymatous involvement, they should not be confounded with mucous patches or herpes. It is probable that in the majority of instances the ulcerative process is due to Vincent's bacillus, which attacks the tonsil and gives rise to ulcerations in which the peculiar fusiform bacilli and the spirilla of Vincent, characteristic of this affection, are present in the pseudomembranous exudate. The ulcers vary in number, they are oval and are covered with a slough.

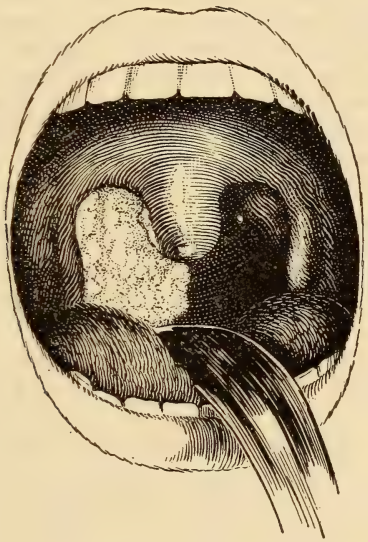

Fig. 464.—The exudate of Vincent's angina upon the tonsil. (*Arrowsmith,* with permission.)

(*d*) *Membranous Tonsillitis.*—The pathological changes are similar to those which occur in membranous laryngitis (see Chapter XLVIII).

Symptoms.—(*a*) Of the *lacunar* variety: 1. Short prodromal period of malaise, headache and chilliness. 2. Rise of temperature to from 102° to 105°. 3. Rapid pulse. 4. Usually bilateral. 5. Inflammation and swelling of tonsils and exudate from the mouths of the crypts, lasting for from one to four days. 6. Pain in back and legs. 7. Pain in tonsil, which radiates to the ear. 8. Painful deglutition. 9. Coated tongue. 10. Fetid breath. 11. Albuminuria (occasionally). Loeb[3] reports four cases and contends that acute nephritis is a frequent sequel of tonsillitis, and that it is frequently overlooked in practice by the majority of practitioners.

[3] Journal of the American Medical Association, November 12, 1910.

(*b*) Of the *peritonsillar* variety: 1. Onset sudden. Chills and moderate rise of temperature. 2. Usually unilateral. 3. Sharp and steadily increasing pain in region of tonsil. 4. Dysphagia. 5. Impaired mobility of the lower jaw. 6. Dribbling of saliva. 7. Coated tongue. 8. Inability to swallow and impeded respiration during later stages. 9. Rigidity of muscles of the neck. 10. Gradually increasing swelling of the peritonsillar tissues. 11. Edema of the uvula. 12. Abscess formation. 13. Physical exhaustion. 14. Otalgia. 15. Impairment of voice.

(*c*) *Ulcerative.*—(See Vincent's angina.)

(*d*) *Membranous.*—(See membranous pharyngitis and laryngitis.)

(*e*) *Vincent's Angina:* 1. Membranous exudate upon one or both tonsils, which is easily removed, but generally returns (Fig. 464). 2. Erosions or ulcerations which extend to the submucous tissues. 3. Involvement of the submaxillary and cervical lymphatic glands. 4. Dryness of throat. 5. Headache, lassitude, foul breath and salivation. 6. The presence of the typical fusiform bacillus and the spirilla of Vincent. 7. Impairment of phonation. 8. Severe pain. 9. Moderate rise of temperature.

Diagnosis.—The diagnosis of all the forms of acute infectious tonsillitis is usually made without difficulty, each presenting its peculiar characteristics. Bacterial examination is necessary in Vincent's angina, also when diphtheria is suspected. Mucous patches and syphilitic gummata must be excluded.

Finally, peritonsillar abscess formation must be distinguished from retropharyngeal abscess. The cervical glands may become secondarily infected.

Prognosis.—In ordinarily healthy individuals the prognosis in every variety is good, the disease running its course in from three to fourteen days, proper treatment early instituted tending to curtail its duration. Fatal cases of Vincent's angina have been reported. A case reported by Held resulted in an attack of acute purulent otitis media, meningitis and death. One of the larynx and trachea was reported by H. W. Bruce. The patient died on the sixteenth day of the disease, the sloughing involving the fauces, pharynx, larynx and trachea.

Complications.—Among the troublesome and often serious complications the following may be mentioned: Acute purulent otitis media, which is always of a severe type, owing to the virulence of the infection; mastoiditis, which is not uncommon; suffocation from the sudden rupture of peritonsillar abscess while sleeping; large abscesses in the neck due to burrowing downward of the pus; septicemic involvement of veins and joints, and bacterial invasion of the submaxillary and cervical lymphatic glands. The majority of all cases of chronic abscess of the tonsil result from acute attacks. The popular theory that rheumatism is closely associated with infectious tonsillitis is probably based upon the fact that acute arthritis so often occurs intercurrently with this disease. Septic

arthritis, endocarditis and pericarditis also occur as sequelæ of influenza, scarlet fever, gonorrhea and other infectious diseases. The characteristic micro-organisms of some of these diseases have been found in the joints and pericardium, and these discoveries strongly tend to corroborate the theory advanced during recent years that the majority of all cases of so-called rheumatism are of bacterial origin and therefore septic, the infection being conveyed by the blood from some primary focus.

Treatment. *Prophylactic.*—No one is immune and those who have suffered previous attacks of the lacunar or peritonsillar variety are especially liable to recurrence. Peritonsillar abscess is an annual or semiannual visitation in some individuals. Recurrence should lead to a careful interval examination for predisposing causes. Hypertrophied tonsils, especially those with lacunar exudate, strongly predispose to lacunar tonsillitis and peritonsillar abscess, and such tonsils should be removed. If chronic nasal accessory sinusitis exists the disease should be eradicated. Any serious infection about the nose or mouth should receive attention and all safeguards relating to the general health, especially the sanitary surroundings, should be employed in order to prevent a lowered state of vitality.

General Treatment.—Rest in bed in a well-ventilated room of moderate temperature conserves the patient's resisting power, guards him from the development of complications, and tends to modify the severity of the attack. Nutritious fluid diet of milk, with raw eggs or Vichy, warm and concentrated beef broth or gruel, are well borne and easily swallowed except in cases of advanced peritonsillar abscess, when for a few days almost all food is refused. A brisk cathartic at the outset is of great benefit. For this purpose 2 to 5 grains of calomel should be administered to adults, either at one dose or in divided doses covering four to six hours, to be followed several hours later by a large dose of saline. Jacobi was the first to extol the merits of perchlorid of iron administered internally as a means of controlling the severity of the infectious process in tonsillitis and diphtheria. For this purpose the remedy should be administered in doses of from 1 to 5 minims to the teaspoonful of water every hour, and during the more acute stage every half hour. The local action of the iron upon the membranes is also beneficial. Quinine, the salicylates, phenacetin and aspirin are useful here as in other septic infections. Sulphate of quinine, 5 to 10 grains twice a day, should be given during the first forty-eight hours. As pain increases, aspirin, in 5-grain doses three or four times a day, affords great relief and reduces the temperature. A good combination for the relief of pain and fever is found in a tablet containing 2½ grains each of salol and phenacetin, with 1 grain of caffeine citrate, to be administered per os each hour until relief is obtained. The pressure pain of a peritonsillar abscess, however, is relieved only by opiates. None of these drugs need interfere with the regular doses of perchlorid of iron. While relief may be obtained by the administration of drugs, it must be remem-

bered that in cases of peritonsillar abscess the disease steadily progresses to abscess formation (Fig. 466).

Local Treatment. (*a*) *Acute Lacunar Tonsillitis.*—During the early stage of acute lacunar tonsillitis, applications of nitrate of silver in solutions of 30 to 60 grains to the ounce directly to the surface of the tonsil are of marked benefit, and often succeed in aborting the attack. The surgeon should observe the precaution to squeeze the surplus silver solution from the cotton swab in order to prevent it from dropping into the larynx, an accident which induces alarming laryngeal spasm.

The doses of perchlorid of iron advised for the general treatment also produce a favorable local effect upon the mucosa. The mucous surfaces of the tonsils should be cleansed at frequent intervals with the alkaline sprays heretofore advised for simple acute pharyngitis (see Chapter XLV).

As the disease subsides and the crypts become emptied of secretion, mild astringent applications should be made. For this purpose, a solution of argyrol, 25 per cent., or ichthyol, 25 per

Fig. 465.—Suitable bistoury for incising peritonsillar abscesses.

cent., in glycerin, or Mandl's solution No. 2 (see page 518) may be applied two or three times a day.

(*b*) *Acute Peritonsillitis.*—In a small proportion of cases peritonsillar infection resolves without the formation of abscess, this result being secured either in response to the general and local measures heretofore outlined or, more probably, for the reason that the infection is mild in type. All others develop abscess (Fig. 466). No relief is obtained from the severe suffering until the abscess is evacuated, either spontaneously or by incision. The local treatment advised for the lacunar type during the early stages is applicable in peritonsillitis. Gargling, however, soon becomes extremely painful and should be abandoned. Cracked ice slowly dissolved in the mouth, or steam inhalations medicated with compound tincture of benzoin, 1 dram to a pint of boiling water, are soothing. Considerable relief from the painful deglutition is afforded by painting the tonsils and pharynx with a 5 per cent. solution of cocaine about ten minutes previous to eating or drinking. Hovell has ingeniously suggested that the pain of swallowing is lessened by placing the hands over the ears and pushing the auricle upward during each attempt at swallowing.

As soon as the character of the swelling indicates the formation of abscess, relief should be obtained by means of incision into the cavity, a procedure which often saves many weary hours of suffering, and at the same time prevents such complications as the burrowing of the pus and the extension of the infection to the surrounding parts. Preliminary scarification of the tissues for the

purpose of local bloodletting is of no avail, and the fresh cuts add fuel to the flame of the burning, lancinating pain. The operation should be preceded by thorough cleansing of the oral cavity and an application of a 10 per cent. solution of cocaine to the point to be incised. The cocaine should be applied in such a manner as to prevent the swallowing of the drug. A long-handled bistoury with a short cutting surface (Fig. 465) is convenient for the operation. The blade should be wound with damp cotton to within 1 inch of the point. The mouth should be opened as widely as possible, and the tongue depressed. With bright illumination the knife is then introduced at the most prominent point of the abscess, which is generally about on a level with the base of the uvula, and about

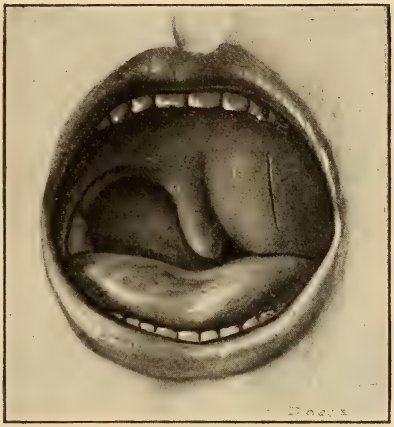

Fig. 466.—The general appearance of a peritonsillar abscess, and the line of incision for its evacuation.

midway between the uvula base and the upper wisdom tooth of the affected side. The incision should be carried from above downward (Fig. 466), but many operators advise that it should be carried horizontally, and from without inward toward the uvula. If the cavity is thus reached a free gush of pus will follow the withdrawal of the knife. Failing to reach the pus sac with the knife, a stiff, blunt probe carried through the incision with considerable pressure will often enter the cavity, which may then be enlarged by introducing a pair of slender artery clamps, to be widely opened upon withdrawal. Some laryngologists operate upon these abscesses by plunging a closed forceps, like Lister's sinus forceps, through the wall directly into the cavity, and opening the blades vertically before withdrawal. The procedure, although attended by undue pain, obviates the danger of wounding blood-vessels. The ascending pharyngeal artery is the vessel most likely to be injured during the incision. The pus is usually offensive.

After-treatment.—The cavity should be thoroughly syringed either with a normal salt or boric acid solution, and then gently curetted with a small ring curet. Recovery is rapid and recurrence unusual, although multiple abscesses sometimes occur. Whenever the pus has burrowed its way downward along the lateral pharyngeal wall it may become necessary to incise through the posterior pillar or even lower down. Obviously the incision never should be through the tonsil.

Bilateral peritonsillitis is not uncommon, but fortunately one abscess is usually well on toward recovery before the other develops. Convalescence is hastened by tonics, free diet and change of air.

(*c*) *Ulcerating.*—Cleanse the surface of the ulcer before making applications. In case the ulcer is covered with a slough, the latter may be removed by rubbing with dilute peroxid of hydrogen or by the curet. After cleansing, the ulcer should be painted with nitrate

Fig. 467.—Extensive involvement of the pharyngeal walls with Vincent's angina. (*Arrowsmith,* with permission.)

of silver solution, 10 to 60 grains to the ounce, or argyrol solution, 25 per cent.

(*d*) *Membranous Tonsillitis.*—(See Membranous Laryngitis.)

(*e*) *Vincent's Angina.*—This disease is usually contagious and has neither geographical nor time limitations. There is no known specific. While the tonsil seems to be the favored site for its development, it may extend to the walls of the pharynx, the larynx (Fig. 467) and the buccal cavity. Bayer reported a case that lasted four months, upon which local measures of the most radical character, including curetment and the galvanocautery, produced no effect. Vincent recommends applications of iodin to the ulcerated surfaces. Others have advocated chlorate of potash in saturated solutions as an application to the ulcers. The dry powder may be rubbed in.

Arrowsmith has reported three cases, in one of which the disease extended over the soft palate and epiglottis (Fig. 468), and in another the submaxillary glands became intensely swollen.

His treatment consisted of cleansing the ulcers with enzymol followed by a boric acid wash and a final application of a 10 per cent. solution of trichloracetic acid, the latter being gratefully borne and at the same time effective in terminating the disease.

Richardson treated fifteen cases successfully by "curetting out the slough, cleansing with antiseptic solutions and daily applications of 5 per cent. solution of nitrate of silver."

In the author's experience thorough scraping of the ulcerated

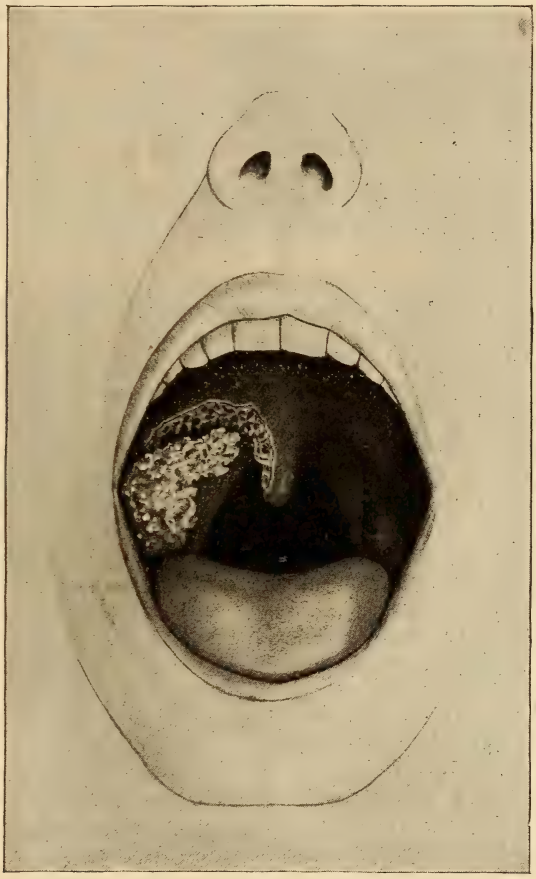

Fig. 468.—The exudate of Vincent's angina has extended over the tonsil, velum, and a portion of the buccal cavities. (*Arrowsmith,* with permission.)

surface, followed by an application of tincture of iodine, well rubbed in, has produced the best results. Salvarsan has also been employed with beneficial results.

III. TRAUMATIC PHARYNGITIS.

Etiology.—The exposed location of the pharynx, especially its posterior wall, renders it peculiarly liable to injury from inhalation of steam, flame or superheated air, scalding from the ingestion of hot

fluids or foods, from excoriation by corrosive poisons, and from injuries resulting from stab wounds, pencils, pipestems, splinters, broken glass, fishbones, and other foreign bodies. It is also liable to become injured from swallowing rough or hard substances.

Pathology.—When caused by flame, escharotics, scalds or other burns, rapid infiltration of the pharyngeal mucosa takes place, the membrane at first assuming a dark-red color. Edema when present extends to the glottis and intralaryngeal spaces. The mucous surfaces later on assume a grayish color, with a tendency to erosion and superficial sloughing. In severe cases phlegmonous-like ulcers result. Ordinary wounds of the pharynx, providing no infection takes place, heal rapidly and leave no permanent injury. If foreign bodies become impacted in the soft tissues, deep-seated inflammation, ulceration and suppuration may ensue. Retropharyngeal abscesses occasionally occur in this manner.

Symptoms.—The marked symptoms are severe pain and soreness in the pharynx, but these are usually overbalanced by the dysphagia and often alarming dyspnea referable to the accompanying esophageal and laryngeal inflammation. Healing is usually rapid unless the abrasions become infected, in which event the symptoms are similar to those of peritonsillar and retropharyngeal abscess.

Treatment.—Foreign bodies should be located by means of the probe or X-ray and removed. The suturing of deep wounds facilitates healing. Superficial burns or scalds require soothing applications. It is often necessary to spray the surfaces with a solution of cocaine, or apply orthoform in order to control the pain. Cleansing sprays or gargles are required to keep the surfaces clean and free from secretions. Inhalation of steam, medicated with compound tincture of benzoinol, 1 dram to the pint, relieves the tension and pain. If sloughing, ulceration or gangrene ensue, it then becomes necessary to remove the sloughing tissue by means of the curet or scissors. When corrosive poisons have been taken, proper antidotes are to be employed, providing too much time has not elapsed. When carbolic acid has been swallowed its caustic effects may be prevented by gargling and swallowing pure alcohol, providing it can be applied within ten minutes.

Alarming dyspnea indicates pharyngeal or laryngeal edema (Fig. 503), and rapid tracheotomy may become imperative. Traumatic abscesses should be promptly incised under strict asepsis. When severe ulceration intervenes, the period of convalescence is slow, often requiring watchful care during several months to prevent adhesions and deformities.

IV. TOXIC PHARYNGITIS.

The internal administration of drugs may induce inflammation of the mucous membranes of the pharynx and mouth. Certain individuals seem to possess idiosyncrasies in this respect, and, in these, the toxic symptoms are liable to develop from even small doses. Mercury, iodid of potash, arsenic, lead, antimony, copper, zinc, and belladonna are the chief drugs in this category. Mercury absorbed as a medicinal agent, or in occupations where quicksilver is used, a peculiar

form of inflammation, involving the pharynx, mouth, tongue and gums. Calomel, even in small doses, has been known to produce this toxic effect. Salivation and superficial ulceration, with dysphagia, are the chief symptoms. The tongue is coated and the breath foul.

Treatment.—Cessation from contact with the drug and the internal administration of iodid of potash or chlorid of potassium are indicated, the mouth and throat meantime being frequently cleansed with dilute peroxid of hydrogen. Iodid of potash, when administered in large doses, causes marked redness and often inflammation of the mucosa, a symptom which indicates the necessity for reduction of the dose for a few days. A dose of sulphate of magnesia will relieve the congestion.

The use of drugs like belladonna, iodid of potash, etc., should be suspended as soon as their physiological symptoms appear.

CHAPTER XLVI.

DISEASES OF THE OROPHARYNX.

(*Continued.*)

CHRONIC INFLAMMATORY DISEASES.

I. CHRONIC HYPERPLASTIC PHARYNGITIS.

In this disease the inflammatory process varies from a chronic inflammation of the entire mucosa with swelling of the tissues to a hyperplasia which involves the glandular structures of the membrane, these variations depending upon the severity or chronicity of the disease, or upon the particular tissues involved. For convenience of description two general subdivisions are made: (*a*) simple chronic pharyngitis; (*b*) granular pharyngitis.

Simple Chronic (Hyperplastic) Pharyngitis.

This is a chronic inflammation of the pharyngeal mucosa resulting in hyperplasia. When associated with impairment of the elasticity of the pharyngeal tissues, the affection is termed "relaxed throat."

Etiology.—The causative factors include: 1. Frequent attacks of acute pharyngeal inflammation. 2. Errors in digestion and assimilation, notably in gouty and rheumatic subjects, especially when accompanied by asthma, chronic bronchitis, cardiac or kidney disease. In this class the clinical appearance and symptoms are always exaggerated. 3. Debility, anemia and plethora. 4. Climate, hygiene and surroundings are often responsible for the affection, as may be observed in those who reside in a damp or changeable atmosphere, or who work or sleep in overcrowded or badly ventilated rooms, or who neglect needed intranasal hygiene. 5. Intranasal diseases. Obstructive lesions in the nose, whether inducing postnasal secretion or mouth-breathing, and chronic accessory sinusitis are common etiological factors. Of the latter the posterior ethmoidal cells and sphenoidal sinuses more commonly induce chronic pharyngitis because their secretions flow backward into the pharynx and give rise to hawking. 6. Misuse of the voice, whether from strain, undue or faulty production (commonly observed in public speakers, singers, hucksters, etc.). 7. Local irritants, like dust and fumes from stone-cutting, tobacco factories and chemicals of various kinds, or the excessive indulgence in alcohol and tobacco, tend to cause chronic hyperplastic pharyngitis. The latter act both as local irritants and by dilating the blood-vessels.

Pathology.—In the early stages the membranes usually become symmetrically hypertrophied, and of a dull red hue due to the inflammatory exudate into the submucous tissues. As the disease progresses there appears upon the posterior wall a network of blood-vessels. At the same time small lymphoid nodules may appear upon the posterior pharyngeal wall. The secretions are altered and the surface may be covered with a film of tenacious mucus.

Symptoms.—The chief symptoms are dryness and soreness of the pharynx, which are more noticeable in the morning. The secretions gradually become less fluid and less in quantity. To dislodge the tenacious secretion requires almost constant hawking efforts on the part of the patient. There is some loss of vocal resonance, and the throat tires easily. Singers feel this more keenly. Frequently there is a sensation of a foreign body in the throat. Relaxation of the uvula, when sufficient to cause a tickling sensation at the base of the tongue, gives rise to an irritating cough.

General Treatment.—The preliminary examination should be exhaustive and should include the intranasal region, digestive system, and a careful search for any organic disease or diathesis, especially gout and rheumatism. The habits, especially those relating to hygiene, alcohol, tobacco and narcotics, should be investigated. Plethoric individuals, if possible, should sojourn at some watering-place where cathartic and pure spring waters may be employed, and the diet regulated according to the patient's needs. Anemic persons are greatly benefited by life in the open air, tonics, full diet, the administration of iron and strychnia, while such sedatives as valerianate of zinc and the bromids afford added relief in neurotic patients. Pure spring water, taken in liberal quantities between meals, is beneficial. Overuse or misuse of the voice requires rest of the vocal organs, to be followed by proper voice training. It is important to adopt all reasonable measures to prevent colds. These measures have been described in Chapter XXXIII. In young children the disease may be prevented by the removal of diseased adenoids and tonsils.

Local Treatment.—A thorough daily cleansing of the mucosa of the nasopharyngeal tract with bland, alkaline, non-irritating solutions, such as normal salt solution or biborate of soda, preferably by means of coarse sprays, is of much benefit. The spraying should be partly through the nostrils, with the head held well backward. This effectually softens and removes the retained secretion. In large cities wherein the inhabitants are unduly exposed to dust and other irritants, the daily cleansing of the pharynx and nasal cavities with bland solutions is a most beneficial measure. Gargles may be substituted for sprays in patients who are trained in their use. Solutions containing glycerin or strong alkalines are irritant and should be avoided, inasmuch as they tend to drain the tissues of needed fluids. Astringents are sometimes useful for the purpose of reducing the local inflammation. Applications of Mandl solution No. 1 (see page 518), argyrol, 25 per cent., nitrate

of silver, 20 grains to the ounce, or ichthyol, 25 per cent., may be applied to the surface daily. Medicated oily sprays, preferably the Douglass formula of benzoinol (see page 499) applied two or three times a day or in the night, if necessary, for the relief of the cough, are soothing and allay irritation. The oil spray should follow the preliminary cleansing.

Chronic Granular Pharyngitis.

Synonyms.—Clergymen's sore throat; chronic follicular pharyngitis; chronic hypertrophic pharyngitis; pharyngitis hyperplastica lateralis.

The majority of authors describe this form of pharyngeal inflammation under several headings, but in the opinion of the author the variations in the clinical manifestations relate to differences in habits, occupation and diathesis. For instance, the granular or follicular variety is more common among those who habitually use the voice to excess, or who have previously shown a tendency to lymphoid hyperplasia; individuals who habitually use alcohol and tobacco to excess, or who possess a tendency to gout, rheumatism or allied diseases, furnish a larger proportion of the general hyperplastic type. Anemic persons or those whose occupations expose them to vitiated air, dust, fumes, etc., are more likely to develop the simple inflammatory form with but little hyperplasia or other tissue changes.

Etiology.—The disease results chiefly from frequent attacks of acute pharyngeal inflammation. Long-continued, improper, or excessive use of the voice, especially in outdoor speaking to large audiences or in badly ventilated theatres or public buildings, interferes both with muscular control and with the circulation of the pharyngeal tissues. The result is stasis, which is followed by congestion and inflammation. The nutrition of the parts is thus interfered with, and if persisted in the follicles finally become diseased and enlarged and the mucous membrane of the posterior pharyngeal wall more or less granular. These symptoms are aggravated by constitutional conditions, particularly digestive disturbances, and affections of the heart, liver, kidneys and lungs. Rheumatism and gout or overindulgence in stimulants and narcotics add to the severity of the affection. Obstructed nasal respiration, undue exposure to dust, the irritation of gases or from vitiated air are also contributive causes.

Pathology.—The pathological alterations in the mucous membrane and submucosa vary. In the severer forms there is at first an increase in the connective-tissue elements, with corresponding thickening. The long-continued intumescence irritates the glandular structures of the mucosa and true lymphoid enlargement results. The granular masses appear upon the posterior pharyngeal wall and vary in size from a millet seed to a bean. Usually but one or two are present, but occasionally the posterior wall is thickly dotted with small glands and with dilated veins, which

radiate over the intervening spaces (Fig. 469). Occasionally the lymphoid masses are observed only along the lateral wall (pharyngitis hyperplastica lateralis), parallel with the posterior pillar and extending into the nasopharynx.

Symptomatology.—The chief symptoms are a sensation of tickling in the throat, cough, alterations in the voice, and partial loss of control of the muscles of phonation. The burning, tickling sensation in the pharynx is persistent; it is much worse upon lying down, and is relieved temporarily by hawking or by coughing. The efforts to relieve the tickling sensation and to clear the throat of the accumulation of thickened mucus not only produce hoarseness or loss of voice, but irritate the inflamed pharyngeal mucosa.

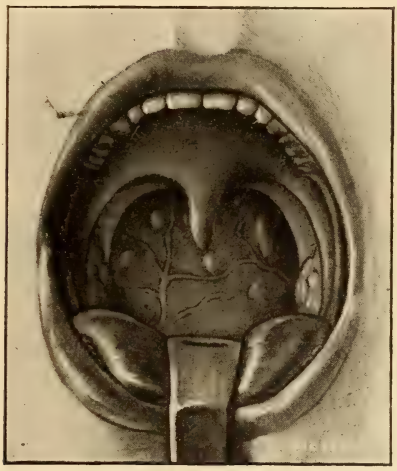

Fig. 469.—The glandular enlargement and dilated veins which accompany chronic granular pharyngitis.

Singers under these circumstances complain of throat tire, loss of flexibility and difficulty in placing tones. This state is frequently accompanied by nerve exhaustion and great depression. Deglutition is rarely painful. Laryngitis in varying degrees usually accompanies the affection.

Diagnosis.—The diagnosis is never difficult. The history of the case furnishes important data, while the examination reveals inflammation and thickening of the mucosa, upon the surface of which glandular nodules are scattered.

Prognosis.—If the original cause of the difficulty can be determined and remedied and the hypertrophied masses removed, a favorable prognosis may be rendered.

Treatment.—The instigation of local treatment should be antedated by a thorough examination of the nose and nasopharynx and a careful study of the general health of the patient. All intranasal deformities and diseases should be remedied and such opera-

tive procedures instituted as the case demands. Attention should be given to any constitutional disorders which may be present. Whenever alcohol or tobacco are used to excess they should be interdicted. For those cases which have resulted from improper use of the voice intelligent vocal training should be sought. Acute exacerbations are greatly relieved by cathartics. Moderate doses of calomel or cascara are favored for this purpose. Locally the destruction of diseased follicles is an important measure. For this purpose the galvanocautery electrode heated bright red is effective. When large blood-vessels radiate across the posterior pharyngeal wall it is sometimes necessary to destroy them by means of the galvanocautery puncture. It is unwise to destroy large numbers of follicles at a single sitting on account of the troublesome reaction which follows. The granular masses may be clipped off with a tonsil punch (Fig. 484). Curetment of the entire posterior pharyngeal wall, including the enlarged glands, is effective. For this purpose Mayer's pharyngeal curet (Fig. 470) is a convenient instrument, and there is less reaction than from the galvanocautery. The surfaces should be thoroughly cocainized previous to operative attempts of any kind. During the interval between these operations

Fig. 470.—Mayer's pharyngeal curet.

the pharyngeal wall should be kept clean by gargling or spraying with normal salt or other alkaline solution. Excessive lateral hyperplasias may also be removed by means of the cutting punch forceps, care being exercised to avoid wounding the posterior pillars. Parker suggests that by introducing the point cold into the space between the glands and the pillar, and forcing the mass toward the median line before turning on the current, then burning through laterally, the posterior pillar may be avoided.

These operations are followed by considerable pain and soreness, which last from twenty-four to forty-eight hours, during which the patient should be directed not to use the voice, and for the relief of pain and soreness plain hot-water gargles and applications of orthoform should be employed. If swallowing is unduly painful the pharynx may be painted twenty minutes before meals with a 4 per cent. solution of cocaine.

After the operative procedures have been completed and the wounded surfaces healed, marked benefit is obtained from the daily local application of mild astringent preparations. Mandl's solution No. 2 (see page 518), solutions of nitrate of silver, gr. 10 to 30 to the ounce, and argyrol, 25 per cent., are useful astringents. Adults and older children may be taught to apply these remedies to their throats. The internal administration of appropriate remedies is of service in patients whose pharyngeal symptoms are aggravated by constitutional disorders. The reader is referred to Chapter XXXIII for a description of useful preventive measures.

II. CHRONIC ATROPHIC PHARYNGITIS.

Definition.—Chronic atrophic pharyngitis is due to a chronic inflammatory process which results in contraction of the mucosa and obliteration of many of the secreting glands and blood-vessels, with consequent atrophy.

The disease occurs in two distinct forms, which are termed simple atrophic pharyngitis and fetid pharyngitis.

Simple Atrophic Pharyngitis.

Synonyms.—Dry pharyngitis; pharyngitis sicca.

Etiology.—As a rule, this disease occurs in conjunction with atrophic rhinitis and arises from the same causes. Primary atrophic pharyngitis is rarely observed. Nasal obstruction and empyema of the accessory sinuses, with or without such local irritants as the inhalation of irritating fumes and bad hygiene, is the primary cause in the larger proportion of cases; all others result from digestive disorders or from grave constitutional affections, such as diabetes or cirrhosis of the liver and kidneys.

Pathology.—The chief pathological changes in the mucosa are the gradual obliteration of the glands and to a less degree the destruction of blood-vessels. This interferes with the nutrition of the parts and alters the character of the secretions. There is a marked diminution in the quantity secreted, with a tendency to become thick and tenacious. In severe cases the secretion becomes inspissated and adheres closely to the surfaces of the mucosa.

Symptomatology.—The chief symptom is a disagreeable sensation of dryness in the back of the throat, accompanied by more or less burning or itching. These symptoms often become almost intolerable, requiring strenuous hawking in order to remove the thickened secretion. The large collections of secretion produce changes in the voice, and hoarseness is common. The color of the secretion varies from light yellow to brown or even grayish or greenish crusts. The general appearance of the membrane is thin, and the breath is affected by the odor from the retained secretion.

Diagnosis.—The disease is based upon the history of the case and the symptoms above described.

Prognosis.—The prognosis depends largely upon the stage of the disease. The pathological changes in the mucosa are permanent and unalterable, but great relief is obtained from arrest of the process and local treatment.

Treatment.—Whenever the disease is caused by intranasal obstruction or empyema of the accessory sinuses, these diseased conditions and deformities should be thoroughly eradicated by operation. Any associated constitutional disorders should receive appropriate treatment and proper hygienic surroundings should be maintained. Aside from this the general treatment outlined for chronic atrophic rhinitis (see Chapter XXXIV) and simple chronic pharyngitis (above described) should be employed.

Fetid (Atrophic) Pharyngitis.

Etiology.—The fetid variety differs from the simple in the character of the secretion, which is thick, tenacious, and extremely offensive. It invariably accompanies fetid rhinitis and has the same etiological factors and pathology. It occurs in the young—more often in girls than in boys—and is always accompanied by anemia.

Symptoms.—The symptoms are similar to those of simple atrophic pharyngitis with the addition of fetor and a greater tendency of the secretions to adhere to the posterior wall of the pharynx.

Treatment.—The measures recommended for the simple variety are applicable here. The removal of the crusts requires daily treatment by the physician until the patient becomes expert in removing them, and in the application of proper local remedies. For a description of the general and local measures of treatment the reader is referred to the treatment of fetid rhinitis (Chapter XXXIV).

III. CHRONIC TONSILLITIS.

(*a*) Chronic hyperplastic tonsillitis.
(*b*) Chronic lacunar tonsillitis.
(*c*) Lingual tonsil hyperplasia.

There are two general varieties of chronic inflammation of the faucial tonsils, viz., the hyperplastic and the lacunar. The lingual tonsil also is subject to chronic hyperplasia.

Chronic Hyperplastic Tonsillitis.

Synonyms.—Chronic hypertrophic tonsillitis; hypertrophied tonsils.

This is a chronic inflammation of the parenchyma of the tonsil resulting in hyperplasia. In young children the tissue increase is largely lymphoid, while in adult life there is a continual increase in the connective-tissue stroma.

Etiology.—It is essentially a disease of childhood, but may continue to adult life. It rarely commences in adult life except as a result of syphilis or some other specific infection. The affection usually is associated with adenoids, and the etiological factors are similar to those which induce hyperplasia of the lymph-glands of the nasopharynx. The usual exciting causes are the acute exanthemata and other acute fevers, grippe, etc., frequent colds and long-continued inflammations of the upper respiratory tract. There is a hereditary tendency in many families which predisposes to lymphoid hyperplasia.

The Adult Tonsil.—During recent years a more careful investigation has been made regarding the various general affections which may occur as a result of retained secretion in the tonsillar tissue of adults and of chronic peritonsillar abscesses. These

[1] The reader is referred to Chapter XLV for general remarks upon the function of the tonsil and the tonsils as portals of infection.

studies have definitely proven that general infections heretofore considered to be neuralgic, rheumatic or gouty, are now known to result directly from foci in the tonsil or peritonsillar spaces. Other affections like acute endocarditis, acute nephritis and even appendicitis, have been ascribed to this cause. In the author's experience so many cases have occurred wherein a tonsillectomy has been followed by a complete relief of the symptoms above mentioned that he has come to advise the removal of the tonsils in every instance where definite evidence is obtained that retained secretions are permanently present in the individual case. In other words, whenever it is possible to press secretion from the tonsillar space after one or more tests, the removal of the tonsil is unhesitatingly advised.

Pathology.—There is a marked increase in the lymphoid tissue and a gradual accumulation of new connective-tissue deposit in the tonsillar stroma. When the connective tissue predominates the tonsil becomes fibrous and therefore harder than when lymphoid tissue is in excess. The tonsillar hyperplasia sometimes reaches enormous proportions, causing them to project across the pharyngeal space, where they lie in contact when the throat is in repose. The shape is generally ovoid (Fig. 483), with marked variations. The enlarged tonsil may chiefly project toward the median line, or an ear-like enlargement may drop downward into the glosso-epiglottic fossa. In other cases the enlargement is chiefly in an upward direction and fills the supratonsillar fossa, or the rounded tonsil may lie buried beneath the faucial pillars, which are adherent to its surface. The surface in general is smooth, but is usually honeycombed by the lacunar openings. More or less inflammation of the pharyngeal mucosa accompanies this affection.

Symptoms.—The symptoms are so closely allied to those produced by adenoids (see Chapter XLIII) that it is difficult to differentiate one from the other, and in most cases both affections are present. The chief symptom is interference with respiration. Mouth-breathing, restless sleep with snoring and nightmare, open mouth with a dull, expressionless countenance, aprosexia, etc., are more particularly the result of adenoids, but difficulty in swallowing and obstructed and imperfect phonation and respiration may be of tonsillar origin. Children with enlarged tonsils are especially liable to colds, which are characterized by acute inflammation of the pharynx and tonsils. During these attacks the patient becomes more restless at night and the persistent hacking cough prevents continuous sleep. The cervical glands are frequently enlarged. With each acute exacerbation, especially when infectious, there is a marked tendency to attacks of middle-ear suppuration. Enlarged tonsils predispose to attacks of acute lacunar tonsillitis, scarlet fever and diphtheria. Pain and discomfort are induced by the traction which occurs upon the inflammatory adhesions which unite the body of the tonsil and the faucial pillars. As adolescence approaches, the tonsils become more fibrous and contraction may take place and reduce the lymphoid tissue, with a corresponding

decrease in the size of the tonsil. This termination is by no means the invariable rule, inasmuch as the enlargement in many cases persists through life.

Diagnosis.—The diagnosis is never difficult and is based upon an examination of the oropharynx, combined with digital manipulation. It is sometimes necessary to differentiate benign or malignant tumors of the tonsil.

Prognosis.—With proper treatment the prognosis is good.

Treatment.—During the examination the size, shape and density of the tonsils should be noted, and the crypts probed in order to determine whether they contain pus or other degenerative material. In adults firm pressure upon the anterior pillar or just above the tonsil will usually cause an expulsion of retained secretion when present. A curved probe, passed between the faucial pillars and the tonsils, will reveal adhesions when present, and no examination should be considered complete until the pharyngeal vault has been explored for adenoids and the base of the tongue examined for lingual tonsil hypertrophy. The treatment of the hyperplastic tonsil is essentially surgical except in cases of slight enlargement when uncomplicated by lacunar secretion. Local applications have but little effect in reducing the hypertrophy.

Indications for Removal.—When associated with adenoids, which require removal, the tonsil, even moderately enlarged, should be removed at the same time. The necessity for the removal of the diseased tonsil is not to be measured by its size. Any visible enlargement is an indication of disease. We have heretofore stated (Chapter XLVI) that there is strong presumptive evidence that the tonsil crypts not only harbor micro-organisms, but furnish a pathway for the entrance of bacteria into the deeper tissues. The chief indications are:—

1. Recurrent attacks of acute tonsillitis. 2. Faucial obstruction. 3. Otalgia, otorrhea and deafness. 4. Impairment of voice and speech. 5. Systemic infection. 6. Anemia, cough, bronchial affections and arrest of physical development. 7. Enlarged cervical glands. 8. Every adult tonsil should be removed when it is the seat of chronic infection or chronic peritonsillar abscess.

In singers with enlarged tonsils who have already learned their art there is some danger that the operation may alter the action of the pharyngeal muscles and thus, temporarily at least, impair the quality of the voice. This never has happened in the author's experience, for in all cases the voice has improved, both in quality and resonance. In order to avoid such complications pupils should undergo a thorough examination by a competent rhinologist before commencing the vocal training, and submit to such operations as may be required to render the upper respiratory tract healthy and free from abnormalities.

During recent years the medical profession, and to a large extent, the laity, have come to regard the tonsil as the chief portal of entry of various systemic infections. Especially has there arisen a growing demand for the removal of tonsils in adults. Internists

as a rule refer these patients for operation. This is recommended for the relief of rheumatism and other systemic infections in the belief that the focal point is located in the tonsil. It is not uncommon for laymen to request that the tonsils be removed. It is a fact that chronic abscesses and other foci are often present in and around the tonsil, making necessary their removal, and with entire relief of the secondary infections, but the author here ventures a

Fig. 471.—Points for injecting cocaine to induce local anesthesia of the tonsils.

word of caution against the indiscriminate removal of the tonsil in adult persons in cases where no positive evidence of infection exists. All other possible causes should be eliminated before resorting to any operative procedure upon the tonsil. Among these may be mentioned chronic middle ear suppuration, nasal accessory sinusitis, the teeth, gall bladder, appendicitis and seminal vesicles.

Methods of Removal.—Of the various operative procedures which have been devised for removing the tonsils, only one is

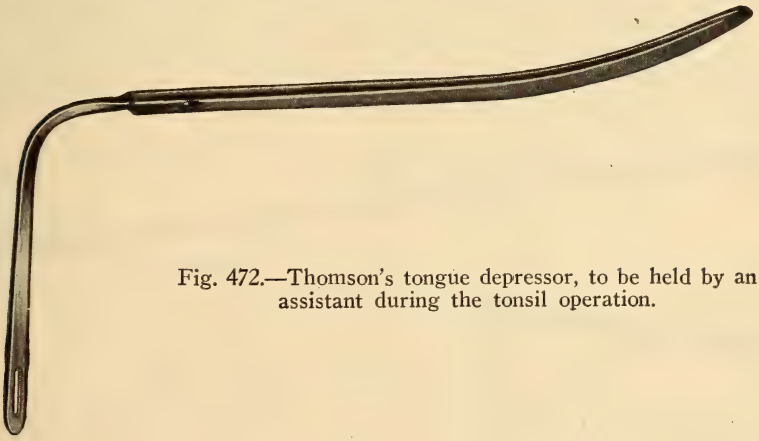

Fig. 472.—Thomson's tongue depressor, to be held by an assistant during the tonsil operation.

worthy of adopting, viz., complete removal (tonsillectomy), including the capsule.

There are numerous variations in the technique, and numerous instruments have been devised for the operative procedure.

Complete Removal (Tonsillectomy), Including the Capsule.—This operation may justly be termed the *radical tonsil operation.* Regarding the merits of complete eradication, the vast majority of American rhinologists favor the procedure for the reason that, unless the

entire tonsil is removed, full benefit of the operation is not secured. It is known that, if the base of the tonsil is left intact, acute infections, peritonsillar abscess and even recurrence of hyperplasia are likely to occur. The credit for placing the tonsil operation upon a rational and scientific basis by insisting upon the complete removal of the diseased tissue is due to American rhinologists, and in the author's opinion there no longer exists any doubt as to the merits

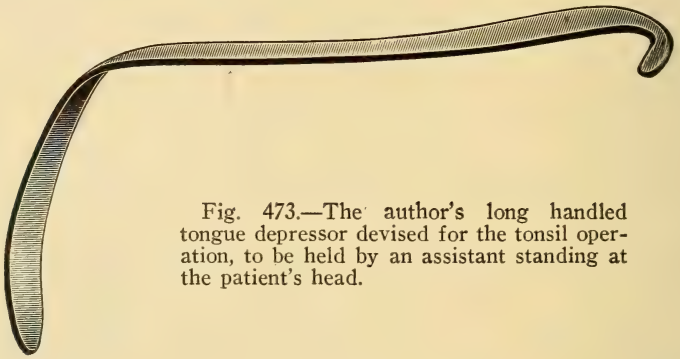

Fig. 473.—The author's long handled tongue depressor devised for the tonsil operation, to be held by an assistant standing at the patient's head.

of these more radical, but at the same time more reasonable procedures. There is by no means unanimity of opinion regarding the removal of the tonsillar capsule, but the majority of those who favor the complete operation remove both the tonsil and the capsule. Myles and others do not favor removing the capsule, and contend that its removal is unnecessary and more liable to be followed by wound infection. It is true that the reaction is more severe and prolonged when the capsule is removed, but the



Fig. 474.—Thomson's tenaculum tonsil forceps.

published reports have not as yet shown serious complications or sequelæ.

There are two arguments which favor the removal of the capsule: 1, it insures the total ablation of the tonsil; 2, the operative technique is greatly facilitated thereby.

Operations upon the tonsil should be performed in a hospital if possible, especially when performed upon young children and under general anesthesia. It is even safer for adults upon whom the operation is performed under local anesthesia to remain in the hospital for twenty-four hours.

The complete operation upon the tonsil should not be considered a simple or mere minor operative procedure unattended by danger. Unfortunately, the older operation of partial removal or "clipping" has created in the minds of the laity a general impression that the tonsil operation is insignificant, and may be safely performed at any time or in any place.

The reasons which favor the hospital as a place for this operation are real and tangible:—

1. Asepsis is more easily maintained.

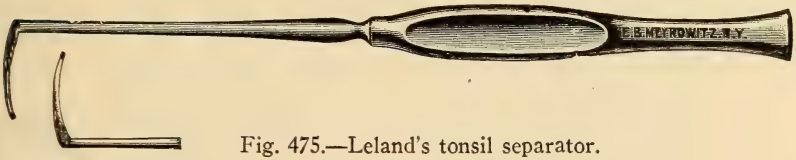

Fig. 475.—Leland's tonsil separator.

2. A well-equipped operating room inspires the confidence of the surgeon and thereby favors his technique.

3. The facilities of the operating room are helpful in controlling temporary hemorrhage.

4. The continuous rest in bed for from twenty-four to forty-eight hours minimizes the shock resulting from the anesthetic, the operation itself, and from the loss of blood.

5. Finally, the dangers of secondary hemorrhage are overcome, inasmuch as trained attendants are at hand and no time is lost in the application of hemostats or other means of control.

Next to operating in a hospital, the most favorable place is the patient's home, where he can be placed in bed as soon as the operation is completed. If possible a trained nurse or attendant

Fig. 476.—Douglass's tonsil knife.

should remain in charge for one night. The portable operating table (Fig. 153) is convenient for operating at the patient's home. It is sometimes necessary and even feasible to operate upon adults under local anesthesia in the surgeon's office, but never when a general anesthetic is employed.

The Anesthetic.—Ether, preceded by nitrous oxid gas, is the favored anesthetic except in very young children, when ether alone or chloroform may be employed. In general, ether is the safest of all anesthetics, and fewer fatalities have been reported than from the use of chloroform. Furthermore it is a distinct advantage both to the operative technique and to the safety of the patient if the anesthetist has had considerable experience in anesthesia for tonsil and adenoid operations.

Local Anesthesia.—Local anesthesia of the tonsil is obtainable by means of deep seated injections of a 1 or 2 per cent. solution of

novocaine. Cocaine should never be employed hypodermically for this purpose. The solution must be injected into the deep areas about the tonsil capsule, and a large quantity of a weak solution is more effective than a smaller qauntity of the strong solution of novocaine. The author advises against the hypodermic injection of any adrenalin for the reason that in one or two instances he has observed rather alarming collapse, characterized by violent pain at the base of the brain and rapid respiration. Local anesthesia for the removal of adult tonsils has strong advocates. There is probably less danger of subsequent lung abscess formation when local anesthesia is employed. This complication, however, may easily be overcome by the constant use of suction over the tonsillar surface while operating under general anesthesia. It is the author's belief

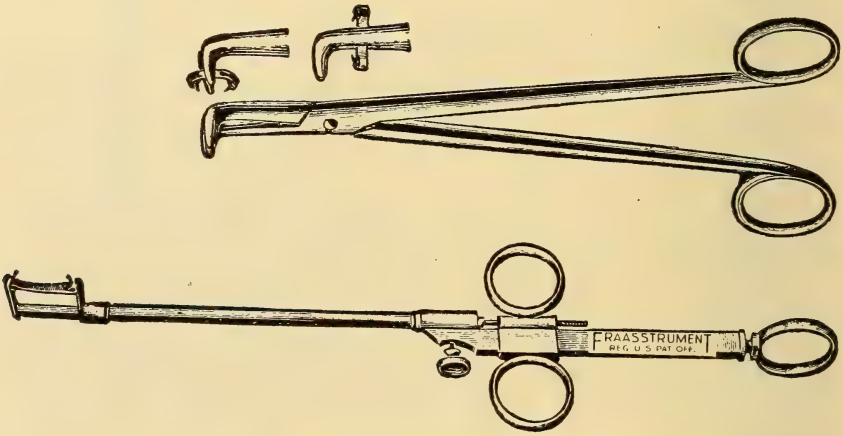

Fig. 477.—The Wagener modification of the Michel clamp suture for control of tonsillar hemorrhage.

that fatal complications occur with less frequency when general anesthesia is employed.

The Operation.—When operating under general anesthesia the surgeon should have the aid of one assistant and if possible a nurse. The chief duty of the assistant is to depress the patient's tongue, sponge the throat, and to constantly employ the suction tube both for the purpose of removing infective material and to keep the operative area free from blood. This duty may be assumed by the anesthetist or by a well-trained nurse. Under local anesthesia the patient may be instructed to depress his tongue. The patient should lie upon his back, with the head slightly lowered when operating under general anesthesia. When a local anesthetic is employed the semi-reclining position is preferable.

Having completed all arrangements, including anesthesia (Fig. 451), a bright electric headlight (Fig. 7), worn by the operator, furnishes the most satisfactory illumination. A specially constructed tongue depressor with a long handle (Figs. 472 and 473)

should now be introduced by the assistant, whose position should be at the patient's head, while the operator stands at the patient's left side. In this position the assistant's hand and arm do not interfere with the operator. The tonsil is then seized by means of a curved long-tined tonsil forceps (Fig. 474) and drawn forcibly toward the median line of the pharynx. This procedure brings the free borders of the faucial pillars into full view. The primary in-

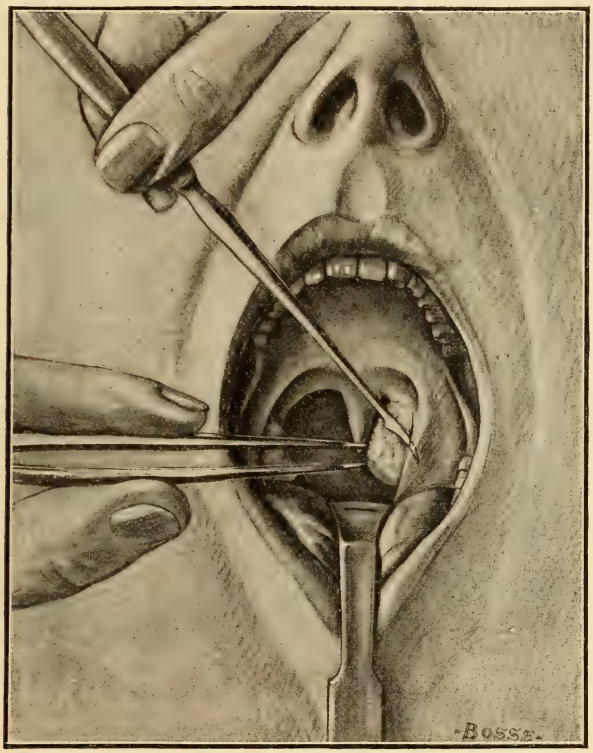

Fig. 478.—The primary incision for separating the hypertrophied tonsil from its attachments.

cision is then made, preferably through the line of attachment of the anterior pillar with the tonsillar capsule, by means of a long-handled curved bistoury (Fig. 478), a tonsil separator (Fig. 475), or the Douglas knife (Fig. 476). Having separated the anterior portion (Fig. 478), the tonsil is rotated outward and a similar incision is extended through the posterior attachment and thence upward and around the supratonsillar fossa, the tonsil meanwhile being rotated downward in order to bring its velar lobe into view. A separator, preferably Hurd's (Fig. 479), is then employed to further release the tonsil from its attachments. A Moseley tonsil snare (Fig. 480) threaded with No. 8 piano wire is then thrown over the projecting tonsil and the tenaculum again applied.

Forcible traction is made in the direction of the median line until by manipulation and gradual tightening of the loop the entire mass becomes engaged (Fig. 482). The wire loop is then gradually

Fig. 479.—The Hurd tonsil separator.

tightened until the mass is removed (Fig. 483). The opposite tonsil is then removed in like manner. The denuded space should



Fig. 480.—The Moseley tonsil snare.

then be carefully searched for any remaining shreds of tonsil tissue, and if found they should be snipped off with Hartmann's tonsil

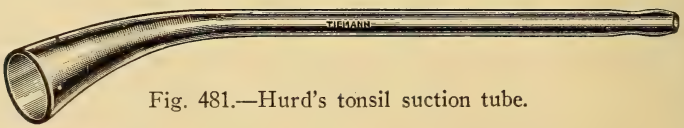

Fig. 481.—Hurd's tonsil suction tube.

punch (Fig. 484). If hemorrhage persists a gauze sponge attached to the sponge holder (Fig. 456) should be pressed into the tonsillar fossa. In case pressure fails to control the hemorrhage, the bleed-

ing point should be located and grasped with long hemostatic forceps. The vessel may then be twisted or ligated. A variety of ligature needles (Figs. 486, 487) have been devised for control of tonsillar hemorrhage, and for ligating bleeding vessels a small curved needle carrying a long ligature is introduced deeply into the submucous tissue surrounding the bleeding vessel. The same being tied off by means of an ordinary slip-noose is an effective method. Another plan is to plug the tonsil cavity and hold the plug by means of a suture carried through both pillars by means of a long-handled, curved needle (Fig. 486). A still further useful method is found in the employment of a special adaptation of the Michel clamp suture (Fig. 477). This may be employed by actually

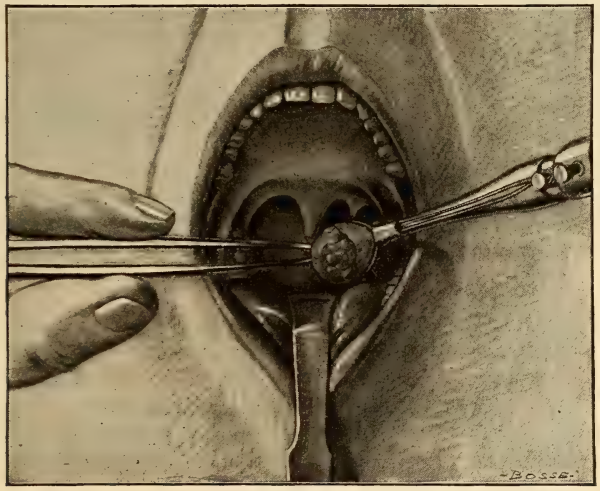

Fig. 482.—The tonsil snare applied to the loosened and evulsed tonsil.

suturing the pillars together or by first introducing a gauze tampon into the tonsil cavity and then maintaining pressure by means of the application of two or three Michel sutures over the tampon with sufficient firmness to suppress the hemorrhage. Rosenheim has devised an ingenious ligature carrying hemostatic forceps (Fig. 488) for grasping and ligating the tonsillar blood-vessels. Occasionally it becomes necessary to apply the tonsillar hemostat (Figs. 489 and 490) for a short period. After the removal of the tonsil a large oval cavity between the tonsillar pillars remains (Fig. 491), which contracts and fills in with granulations.

The Sluder Operation.—Sluder[1] has devised a unique method for the removal of the faucial tonsils. For this purpose he em-

[1] Paper read before the American Medical Association, June 9, 1910, and published in the Journal of the American Medical Association, March 25, 1911; Journal of the Missouri State Medical Association, March, 1913; Trans. Academy of Ophthalmology and Otolaryngology, 1912.

ploys a specially constructed dull-bladed Mackenzie tonsillotome, which both crushes and cuts when the blade is forced against the copper lining of the ring. The guillotine is passed backward from the opposite side of the mouth and the tonsil is engaged in a manner exactly opposite to that of the old method of removing tonsils

Fig. 483.—Tonsils removed by dissection and snare, actual size. The capsule is intact.

with this instrument. Force is applied behind and below the tonsil and the latter is then pulled forward and upward about three-fourths inch against the alveolar eminence of the lower jaw. The latter acts both as resistance and at the same time forces the tonsil more completely into the ring of the guillotine. The unemployed hand is then used for the purpose of more thoroughly en-

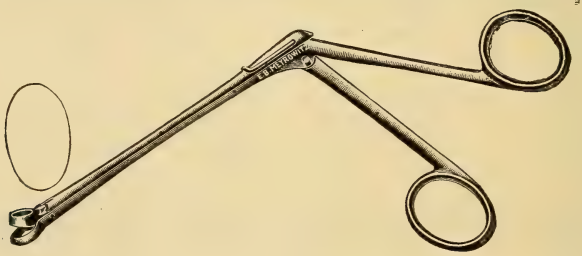

Fig. 484.—Hartmann's tonsil punch.

gaging the tonsil into the ring of the guillotine when the blade is driven home. As a rule, more or less of the tissue of the anterior pillar is cut away in the Sluder operation. The advantages claimed are rapid execution, minimum surgical violence, and less hemorrhage. The method of application is illustrated in Fig. 485. Various modifications of the Sluder tonsillotome have been devised.

Dangers.—The chief danger attending operations upon the tonsil is hemorrhage, which arises from anomalous arterial dis-

tribution, or as a result of the accidental wounding of some artery in the surrounding tissues. Secondary hemorrhage is not common, but when it does occur it is usually profuse and persistent. Fatal secondary hemorrhage is rare, and almost invariably it occurs in patients who are allowed to go to their homes soon after the oper-

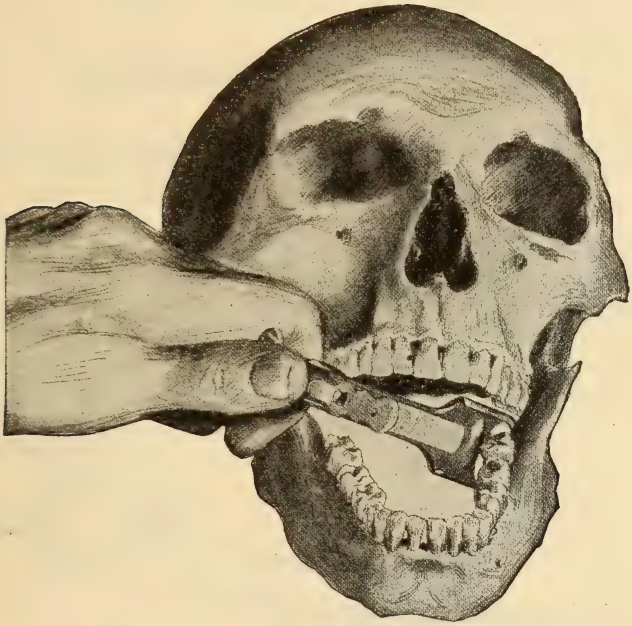

Fig. 485.—Sluder's method of removing the tonsil.
(*Sluder,* with permission.)

ation is completed. An ingenious method of controlling tonsillar hemorrhage is to pack the denuded cavity between the pillars with gauze. The packing sometimes is retained by the pressure of the faucial pillars; otherwise a suture may be carried through the borders of the pillars and be drawn taut across the space. The Michel

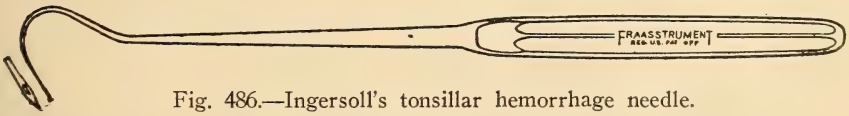

Fig. 486.—Ingersoll's tonsillar hemorrhage needle.

clamp suture (Fig. 477) is ideal for this purpose. The Miculicz-Stoerck hemostat (Fig. 490) produces great discomfort, and if left too long *in situ* troublesome sloughing may occur. Hypodermics of human or horse serum may also be employed in severe cases.

After-treatment.—The after-treatment is similar to that heretofore described for adenoid operations (see Chapter XLIII). It is advisable, even when a local anesthetic has been employed, to

recline for the balance of the day, and to avoid hot food or drinks. Cool drinks and cracked ice may be taken in moderation, and are gratefully borne.

Adults usually complain of severe postoperative pain. Some relief may be obtained from the application of orthoform to the denuded surfaces. The complete operation is followed by more or less local infection, which is more severe in adults. The soreness



Fig. 487.—Spiral tonsil suture needle, right and left.

and dysphagia continue for several days, during which time soft food only can be taken. There is but little rise in temperature and alarming secondary symptoms are exceedingly rare.

The cut surfaces soon become covered by a grayish-white slough which has a membranous appearance. After the second day it is advisable to cleanse the throat at intervals with alkaline sprays or gargles.



Fig. 488.—Rosenheim's tonsil ligature carrying hemostat.

Chronic Lacunar Tonsillitis.

Synonym.—Chronic follicular tonsillitis.

This is a chronic, hyperplastic inflammation of the tonsil characterized by accumulations of caseous material in the crypts.

Etiology.—The disease probably occurs as a result of a series of attacks of acute lacunar or septic tonsillitis in which the epithelium of the crypts is the chief seat of the disease. It is commonly associated with chronic peritonsillar abscess, and it may be caused by unhealthy and insanitary surroundings, or by chronic infection

involving any portion of the upper respiratory tract. It is more common in adults than in children.

Pathology.—In chronic lacunar tonsillitis the tonsil as a whole may not be extensively enlarged, but the crypts are usually quite numerous, and one or more are filled with secretion. Retention of secretion is more likely to occur in the crypts which open into the supratonsillar fossa.

The so-called caseous material consists of a series of yellow masses or plugs which are located in the tonsillar lacunæ. It is composed of desquamated epithelium, cholesterin, leucocytes, fatty material, a variety of micro-organisms and particles of food. The masses are sometimes visible to the eye, but more often they are partially hidden by the pillars or wholly buried from sight and are discovered only by probing. They are malodorous and of cheesy consistency.

Symptoms.—Locally there is a sensation of fullness, roughness and irritability about the tonsil, with slight pain. Neurotic

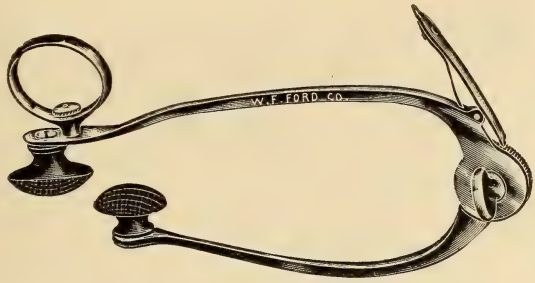

Fig. 489.—Hurd's tonsil hemostat.

patients often are peculiarly susceptible to the slight pain and irritation, even when there is retention only in one or two crypts. Others are conscious of an offensive taste and odor and seek treatment chiefly for relief from these symptoms. Many patients are able to squeeze out these masses by pressure with the fingers. The largest aggregation is usually in the supratonsillar region and here the symptoms are pronounced. Acute exacerbations of lacunar tonsillitis are common.

Diagnosis.—Lacunar tonsillitis is likely to be mistaken for keratosis. The latter is rarely confined to the tonsil; the masses project beyond the surface and are denser. Furthermore the deposits are firmly adherent and are whiter than the caseous accumulations in lacunar tonsillitis.

Treatment.—Radical removal of the tonsil (described above) is the only method which promises permanent relief. Other measures only afford amelioration of the symptoms. In patients who refuse operation and demand temporizing measures, two or more of the diseased crypts should be opened into each other by incising their dividing walls. In this manner the lacunar openings are

enlarged, and retention is less likely to occur. After the incisions have been made the retained secretion should be removed by means of a ring curet and the cavity swabbed with a solution of argyrol, 25 per cent., or a 20 per cent. solution of trichloracetic acid (Kauffmann). Temporary relief is obtained from removal of the retained secretion, either by means of the ring curet or by syringing out the crypts with a small cannula attached to a syringe. Pressure or squeezing with the finger also is an effective method.

Cyst of the Tonsil.

Tonsillar cysts usually result from inflammatory closure of the lacunar mouths, beneath which collections of caseous matter



Fig. 490.—The Miculicz-Stoerck tonsil hemostat.

become encysted. They are also believed to result from traumatism and from the use of the galvanocautery.

Symptoms.—When the cysts are of small size the symptoms are *nil*. Whenever the accumulation is sufficient to cause the tonsil to project into the oral cavity, a sensation of fulness results. Occasionally the cysts are sufficiently large to make pressure upon the posterior pharyngeal wall and the base of the tongue, in which event the sensation becomes that of a foreign body with considerable irritation.

Diagnosis.—The diagnosis is usually made without difficulty, inasmuch as pressure reveals the fluctuating character of the tumor. When the parietal wall is sufficiently thin the yellowish color is characteristic.

Treatment.—The cyst should be freely incised, its contents scraped out, and the denuded surface painted with iodin, argyrol, 25 per cent., or a solution of nitrate of silver 60 grs. to the ounce. As a rule, a tonsil which is the seat of a cyst is sufficiently diseased to require removal.

Tonsilliths (Calculi of the Tonsil).

Etiology.—Tonsilliths probably occur in a similar manner to that of tonsillar cysts, except that a deposit of lime salts becomes mixed with the retained caseous material. These deposits increase and solidify until calculi, or tonsilliths, of considerable size are formed. They are chiefly composed of calcium phosphate and carbonate, with some organic material. They invariably occur in tonsils which are the seat of chronic lacunar inflammation.

Symptoms.—Until considerable size is reached no special symptoms are produced. The larger ones induce considerable inflammation of the surrounding tissues, and sometimes ulceration, in which event pain and dysphagia are experienced.

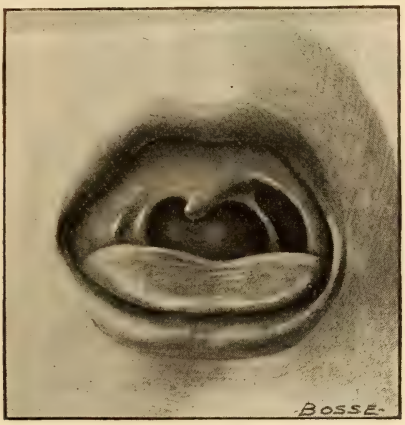

Fig. 491.—On the left side the cavity from which the tonsil has been removed is shown between the faucial pillars.

Diagnosis.—The diagnosis is based upon the characteristic hardness of the tumor, which is conveyed to the probe or to the finger.

Treatment.—The tonsillith should be removed through an incision of sufficient size to permit the introduction of a pair of strong forceps. The tonsil should also be removed.

The Lingual Tonsil.

The lingual tonsil, being a part of the so-called Waldeyer's ring of lymphoid glands, is located behind the circumvallate papillæ, at the base of the tongue (Fig. 492) and above the epiglottis. It is subject to both acute and chronic inflammation and it sometimes becomes permanently enlarged, in which event it gives rise to characteristic symptoms. The hyperplasia is usually bilateral, and large veins may radiate between the lymphoid masses.

Symptoms.—The chief symptoms are a sensation of tickling, and irritating cough and impairment of voice. In singers and public speakers all the symptoms are aggravated, especially the interference with tone production. The sensation of a foreign body causes constant annoying attempts at swallowing, without relief.

Treatment.—Excision is the only effective treatment, and is best accomplished by means of the Myles lingual tonsillotome (Fig. 493). Local anesthesia is easily produced, providing a drop or two of a 1 per cent. solution of cocaine is injected directly into the mass ten minutes before operating, or a 10 per cent. solution of cocaine may be applied locally. The arrangements for operating are

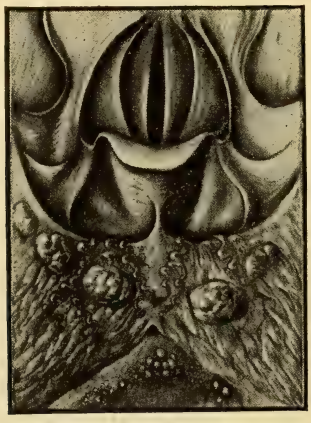

Fig. 492.—The lingual tonsil and lingual varix.

similar to those for intralaryngeal work, the patient holding his own tongue, and the operator, under bright reflected illumination, introducing the laryngeal mirror (Fig. 22) with his left hand, thus bringing into view the entire mass to be excised, and with the right hand guiding the instrument until a portion of the mass protrudes through its fenestra. Considerable hemorrhage may follow the removal, but it is controllable by pressure with adrenalin-soaked swabs. Care should be taken not to cut into the underlying cellular tissue. Removal may also be accomplished with a snare.

After-treatment.—The patient should avoid hot drinks or the swallowing of coarse or solid food for twenty-four hours, after which the soreness rapidly subsides without further treatment, except that he should gargle with a cleansing solution immediately after taking food. Public speakers and singers should refrain from their usual occupations during the healing process, thus avoiding undue muscular strain.

IV. LINGUAL VARIX.

Lingual varix is made up of an aggregation of varicose veins located at the base of the tongue, between the circumvallate papillæ and the epiglottis (Fig. 492).

Etiology.—They are commonly observed in connection with hyperplasia of the lingual tonsil, but generally are due to some disease in which there is obstruction to the return circulation. In plethoric and alcoholic individuals, who suffer from cirrhosis of the liver, the disease is common. It may be caused by excessive use or improper production of voice. It is more common in males than in females and does not occur in childhood.

Fig. 493.—The Myles lingual tonsillotome.

Symptoms.—Lingual varix gives rise to a sensation of fullness in the throat and a tendency to cough. There is a sensation of dryness, with an almost continuous effort to relieve by swallowing or coughing. In rare instances the small veins rupture, but severe hemorrhage rarely occurs. Upon examination with the laryngeal mirror the varicose veins are plainly visible.

Diagnosis.—The diagnosis is made by simple inspection, which reveals the dark-blue distended veins running anteroposteriorly in fan-shape, from the base of the tongue.

Treatment.—Obliteration of the enlarged veins affords the only relief, and this is best and most safely accomplished by the galvanocautery puncture, under local anesthesia. The electrode, at a cherry-red heat, carefully guided into position by means of a laryngeal mirror, should be made to sever two or three of the large veins at a single sitting. With the cautery at a cherry-red heat there is less danger of subsequent hemorrhage. Should excessive hemorrhage result it is best controlled by pressure.

CHAPTER XLVII.

DISEASES OF THE PHARYNX.

---

1. NEOPLASMS OF THE PHARYNX.

1. BENIGN NEOPLASMS.

THE principal non-malignant growths observed in the pharynx are papillomata, fibromata, angiomata, adenomata, dermoid cysts and ranula.

Papillomata.

Of the benign neoplasms the papilloma is the commonest. The usual site is upon the uvula, but occasionally they develop upon the pillars, the soft palate, or the posterior and lateral pharyngeal walls. They are pedunculated, pale in color and occasionally sessile. They give rise to no symptoms, and usually do not grow larger than a pea. In rare instances they grow rapidly, reaching a size sufficient to produce a tickling sensation and paroxysmal cough.

Treatment.—When they are of small size and produce no symptoms they may safely be allowed to remain. Otherwise they should be promptly removed under local anesthesia. The tumor should be firmly grasped with forceps, drawn away from its attachment and severed by means of scissors, knife, snare or cutting forceps. By including a small area of surrounding membrane, recurrence is prevented. Hemorrhage is never excessive, and no after-treatment is required, except that relating to cleanliness.

Fibromata.

Fibromata are rare in the oropharynx; they occur during full adult life, and are more common in males. They are usually sessile, but may be pedunculated and may appear upon the velum, the faucial pillars, or the posterior pharyngeal wall. They are dense, solid to the touch, and light pink in color. When of large size they gradually become lobulated. Small ones produce no symptoms, but those of large dimensions give rise to functional disturbances, especially dysphagia and dyspnea.

Treatment.—The treatment is removal by operation. Small pedunculated growths are easily removed by means of the cold-wire or galvanocautery snare. When the attachment covers a large surface a circular incision should be made through the membrane surrounding the base of the growth; the latter is then grasped with strong forceps and its attachment severed by means of snare or scissors. Considerable hemorrhage may be expected, but it is easily controlled by pressure. Healing is facilitated by closing the wound with sutures. For the removal of fibromata of extreme size extensive surgical measures are sometimes required.

Angiomata.

Angiomata occur with about the same frequency as fibromata, and are made up of a network of blood-vessels, whose walls are

held loosely together by connective tissue. There is no known cause. They usually appear upon the uvula, velum or faucial pillars. In a case reported by the author[1] (Fig. 494) there was a very large angioma involving the uvula and a portion of the velum. The patient was a male, aged 31. The uvula was enormously elongated and enlarged laterally, being made up of a mass of dilated blood-vessels. The tip extended well down into the glosso-epiglottic space and seriously interfered with deglutition and respiration. He was constantly trying to swallow his uvula. At the time of operation extensive preparations were made to control hemorrhage, which, it was feared, might be excessive. The entire mass was removed with a galvanocautery snare and with no hemorrhage whatever.

Treatment.—Whenever feasible the growth should be removed, even at the risk of troublesome hemorrhage. When peduncular the galvanocautery snare is the ideal method. Those with broad attachments are amenable to the galvanocautery puncture, from three to five blood-vessels being destroyed at each sitting. Strangulation by means of a series of ligatures and destruction of the growths by electrolysis have been advocated.

Adenomata.

Adenomata may appear upon the soft palate, uvula, tonsil or the pharyngeal walls. They develop only during adult life and are difficult to distinguish from fibromata. Adenomata develop slowly, are less dense and less painful than fibromata.

Treatment.—The only rational treatment is removal by surgical operation under general anesthesia, first dividing the membrane sufficiently to allow the operator to gradually enucleate the growth. In smaller growths a single primary incision over the central portion of the growth is sufficient.

Dermoid Cysts.

These are congenital and due to abnormalities of development. They are usually pedunculated and consist of a covering of ordinary integument, with hair follicles. Within the growth are found fatty matter, intermingled with portions of muscular fibre, cartilage and bone.

Treatment.—They should always be removed. The operation is simple. The mass is grasped with strong forceps, while the pedicle is clipped off close to its attachment.

Ranula.

Whenever a cystic tumor occurs underneath the tongue it is termed ranula, for the reason that these cysts were orginally supposed to originate in the duct of the sublingual gland. Experience, however, has shown that they may arise from a dilatation of the sublingual duct, submaxillary duct, racemose glands, thyroglossal duct,

[1] New York Medical Record, March 12, 1887.

or they may be dermoid in character. They vary in size from that of a walnut to tumors of enormous dimensions. Immediate relief may be obtained from evacuation, but a cure can only be accomplished by surgical removal of the sac.

2. MALIGNANT NEOPLASMS.

Sarcomata and carcinomata of various types, both primary and metastatic, occur with comparative frequency in the oropharynx. Unfortunately, the etiology of malignant neoplasms has not yet

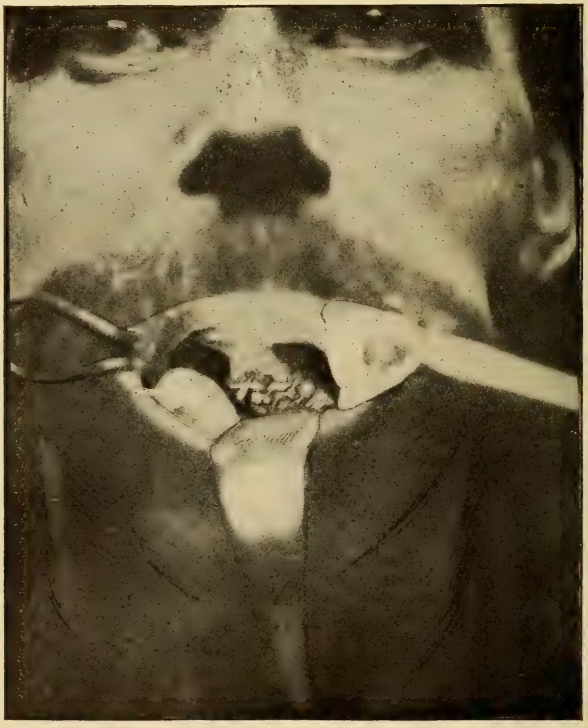

Fig. 494.—Large angioma of the uvula removed by the galvanocautery snare without hemorrhage. (Author's case.)

been determined. The pathology, symptomatology, diagnosis and treatment, being similar for both types of malignant diseases of the pharynx, will be described together.

Sarcomata.

Sarcomata of all types are found in the fauces and pharynx, and any portion of the pharynx may become the primary seat of the disease. Primary sarcoma of the pharynx usually runs a rapid course, with a fatal issue. In exceptional cases the progress is slow, and six or eight years may elapse before the disease terminates.

Ulceration occurs early and it is invariably followed by enlargement of the neighboring lymphatic glands and general metastasis. The author has recorded two cases of melanotic sarcoma with deposits in the mouth, nose, pharynx and larynx.

Carcinomata.

Carcinomata rarely occur in the pharynx under the fortieth year, after which the ratio increases with age until advanced life. The disease is more common in males than in females, and the epithelial variety is the rule.

Pathology.—The reader is referred to the numerous extensive treatises extant for the pathology of malignant neoplasms of the pharynx.

Symptoms. — The symptoms of malignant neoplasms of the pharynx are dependent upon the location and extent of the growth. Pain is the most common of all symptoms, but may be absent during the earlier stages and it is more severe in carcinomata. As the tumor increases in size or when ulceration is present the pain becomes severe and lancinating, and deglutition becomes difficult. Dyspnea is marked whenever the tumor encroaches upon the lumen of the respiratory tract. As a rule, the earliest symptom complained of is a sensation of fullness and swelling in the throat. The later symptoms are severe pain, dysphagia, dyspnea, fetid breath, cachexia, cervical lymphatic enlargement, emaciation and hemorrhage.

Diagnosis.—During the early stages it is often extremely difficult to differentiate malignant from non-malignant growths, especially tertiary syphilis. In case syphilis is suspected large doses of iodid of potassium should be administered in order to verify the diagnosis. A microscopic examination of a section of the growth furnishes the most reliable diagnostic data. Early diagnosis is of the utmost importance, inasmuch as the early and complete surgical removal of the growth offers the only hope of cure.

Prognosis.—Without treatment malignant neoplasms of the pharynx terminate fatally. The prognosis is slightly favored where early and complete removal of the growth has been accomplished. The prognosis in sarcoma is slightly more favorable than in the other forms, but under all circumstances is grave.

Treatment.—Radical surgical removal of the growth, instituted early in the history of the disease, is the only known means for terminating its ravages. The location and extent to which the growth has progressed are the chief determining factors regarding the advisability of even attempting any operative procedure. Under the most favorable circumstances recurrence usually takes place. Unfortunately, the majority of malignant tumors of the pharynx when first seen have already passed beyond all hope of benefit from surgical interference. Under these circumstances the tumor must be considered inoperable, and palliative measures only are admissible.

If an operation is undertaken it is important that a considerable area of the sound tissue surrounding the tumor should be included in the excision, and that all infected glands should be dissected out. Providing the diagnosis is made sufficiently early, and the growths are confined to the soft palate, the faucial pillars, the tonsil or peritonsillar tissue, it is possible to successfully operate within the mouth. General anesthesia is necessary. If the area of the disease includes the epiglottis, or the laryngopharyngeal space, with or without lymphatic gland enlargement, and in all cases of metastasis, the external operation is required. The external operation is a serious procedure not only because of the dangers which usually accompany operations in this field, but for the further reason that in the majority of cases the disease has extended beyond the areas which the symptoms have indicated. Recurrence is the rule, yet the span of life may be prolonged for at least a few months, unless the patient succumbs to the shock or other dangers incident to operation.

The incisions and methods of removal must be suited to the individual case, inasmuch as variations are made necessary by the location and extent of the disease. It is beyond the scope of this work to describe and to illustrate in detail the technique of the various operations, for which the reader is referred to works on general surgery.

After-treatment.—The after-treatment includes simple measures for maintaining cleanliness until healing has been complete.

Treatment of Inoperable Cases.—Inoperable growths often require surgical interference for the relief of urgent and dangerous symptoms. Encroachment upon the lumen of the larynx or the pharyngoesophageal opening may be relieved, temporarily, by the removal of a large section of a projecting tumor, this procedure being best accomplished with the galvanocautery snare. Later developments may require tracheotomy or gastrotomy, the latter procedure being necessary for the purpose of feeding. The same procedure may be resorted to when recurrence has taken place. When the pain becomes intolerable, sufficient morphine should be given for the relief of this distressing symptom, and the surface of the tumor should be kept clean by proper sprays and washes. Various non-surgical methods have been advised for the relief or cure of inoperable cases.

The value of treatment by X-ray, serum therapy (Coley's mixed toxins of bacillus prodigiosus and streptococcus erysipelatis), etc., and the enzyme treatment (trypsin and amylopsin) have already been defined in Chapter XLII.

2. NEUROSES OF THE PHARYNX.

1. MOTOR NEUROSES.

Neuroses of the pharynx are of two general varieties, the motor and the sensory. Motor neuroses appear in two general forms: (*a*) spasmodic affections; (*b*) paralysis.

(*a*) Spasmodic Affections.

Spasm of the pharynx is observed with hysteria, chorea, tetanus, hydrophobia, epilepsy and in certain forms of nystagmus.

1. **Globus Hystericus.**—This occurs, as a rule, in women who have deep-seated irritability of the central nervous system. In rare instances it seems to be a reflex irritation caused by inflammatory changes in the tissues of the pharynx. The sensation is that of a lump rising in the throat, with spasm of the pharyngeal muscles. It is greatly aggravated by lingual varix or hypertrophy of the lingual tonsil.

2. **Chorea (Choreic Movements).**—Spasmodic twitchings of the muscles of the soft palate and pharyngeal walls are often symptoms of chorea, and, occasionally, of paralysis agitans. Similar contractions may occur in neurotic patients who are suffering from pharyngeal inflammation, foreign bodies, or tumors.

3. **Nystagmus.**—Pharyngeal nystagmus, with rare exceptions, is a manifestation of some serious central lesion like brain abscess or tumor, meningitis, general paralysis or tabes dorsalis, and is never confined to the pharynx or larynx. In rare instances a rhythmical muscular movement of the velum palati accompanies local lesions in the upper respiratory tract.

Treatment.—Before instituting treatment a general examination of the patient should be made in order to determine if possible the exact cause of the affection. Some form of general treatment is usually required. Rest, improvement of the diet, change of location and general tonics are indicated. In globus hystericus the bromids, asafetida and valerianate of zinc are useful in controlling spasm. Some benefit is claimed from applications of the faradic current to the back of the neck, and interiorly to the pharyngeal walls. Diseased conditions within the pharynx should receive attention and full advantage should be taken of all slight operations or applications to secure the benefits of suggestive therapy.

For the treatment of chorea, hydrophobia, and epilepsy the reader is referred to works on diseases of the nervous system. Nystagmus of central origin is always a grave condition.

(*b*) Paralysis.

Paralysis affecting the pharyngeal muscles is usually confined to those of the soft palate, but it may involve the constrictors. The affection may be of central origin, resulting from cerebral embolism, cerebral tumors, tabes dorsalis, and bulbar paralysis. It also arises from pressure upon the nerve trunks, either in the form of gummata or new growths. A third and common form of paralysis of the pharynx is of peripheral origin, resulting from the toxins of diphtheria and influenza, and from mineral poisons. When bilateral the entire velum and uvula drop downward and forward away from the posterior pharyngeal wall, and do not give motor response to voice and other sounds. In young persons the com-

monest form is that which follows as a sequela of diphtheria and streptococcic infection. In unilateral paralysis, upon examination the uvula is drawn toward the non-affected side, while the paralyzed half of the velum palati drops into the pharyngeal space (Fig. 495). There is a nasal quality to the voice and during deglutition a portion of the fluids passes into the nasopharynx and out through the nose.

Treatment.—The treatment of cases of central origin should be advised by a competent neurologist, inasmuch as the pharyngeal paralysis usually is but a part of a more general paralysis. Gummata respond to the internal administration of potassium iodid. Other tumors if possible should be removed. The paralysis of

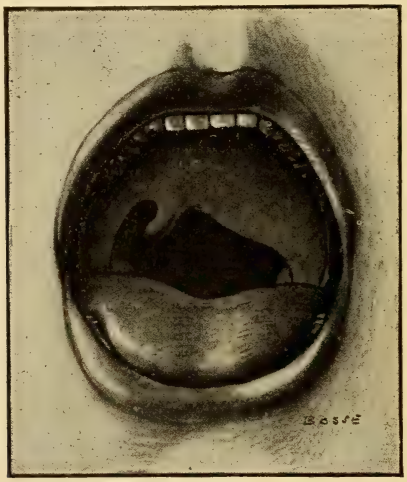

Fig. 495.—Unilateral paralysis of the velum palati.

diphtheria disappears without treatment after an interval of about one month, but tonics should be administered. Locally, some benefit may be expected from the application of the faradic current. Outdoor life, simple but liberal diet, and freedom from all depressing influences are of great benefit.

2. SENSORY NEUROSES.

Sensory neuroses of the pharynx occur in the form of anesthesia, hyperesthesia, paresthesia and neuralgia.

Anesthesia.

Anesthesia, whether complete or partial, unilateral or bilateral, usually accompanies motor paralysis; but it may be a symptom of hysteria or insanity, resulting from pressure upon the glossopharyngeal nerve.

Hyperesthesia.

Hyperesthesia accompanies a large proportion of all cases of acute and many cases of chronic pharyngeal inflammation. It is invariably bilateral, and is aggravated in alcoholic, tuberculous and dyspeptic individuals.

Paresthesia.

Perversions of sensation, designated as paresthesia of the pharynx, are of neurotic origin. Parker has noted the affection as an accompaniment of sexual hypochondriasis in the male and the climacteric period in the female. The affection is characterized by a sensation of suffocation, itching, hawking or a barking cough, and tickling as of a foreign body in the throat.

Treatment.—The conditions above described usually require internal medication in the form of tonics (iron, strychnine, and cod-liver oil). Sedatives also may be required (bromids, valerianate of zinc, asafetida). Local treatment in the form of mild astringents and sedatives is helpful. In neurotic patients it often is wiser to desist from all local treatment in the pharynx in order to divert attention from the trouble. The underlying cause of the particular symptoms should be sought and if possible removed. It is especially important to divert the patient by change of scene, rest, cessation from pernicious habits, and avoidance of worry and care.

3. UNCLASSIFIED AFFECTIONS OF THE PHARYNX.

FUNGOID GROWTHS IN THE PHARYNX.

Fungoid affections occurring in the pharynx are of two varieties: (*a*) thrush; (*b*) keratosis.

(*a*) Thrush.

Thrush is an affection of the mouth and pharynx, resulting from yeast fungi which are termed saccharomyces albicans or oïdium lactis. It is more common in infants and in the aged, but is sometimes observed in adults during the later stages of typhoid fever and other severe and prolonged illnesses.

Pathology.—The pathogenic species under consideration induce a growth of thrush upon the surface of the mucosa of the mouth and pharynx, which is characterized by the appearance of white cylindrical or oval cells about the size of a small bead. They sometimes form into long filaments or gradually coalesce into small patches.

Symptoms.—There are no characteristic subjective symptoms. There is but little pain, but the affection is usually accompanied by digestive disturbances.

Treatment.—Whenever the disease is local and unattended with severe symptoms, relief will usually follow a thorough clean-

ing of all implements of the dietary, especially the nursing bottles. At the same time the mouth should be thoroughly sponged with boric acid solution after each feeding. Regulation of diet and hygiene are important.

(*b*) Keratosis.

Synonyms.—Hyperkeratosis (Wood), mycosis of the pharynx, pharyngomycosis, mycosis leptothrix.

According to Wood, keratosis of the pharynx is an affection characterized by the development of white horny masses, which project chiefly from the orifice of the tonsillar crypts, but which may project from the orifices of any lymph follicles situated in the pharynx. This affection is more common between the ages of twenty and forty.

Pathology.—Examination of the pharynx reveals an aggregation of whitish conical excrescences standing out well beyond the orifices of the lymph follicles, to which they are firmly adherent. In the tonsils the crypts become distended with a horny mass which is arranged in layers, and between which various organisms multiply and grow. They vary in size from a pinhead to a kernel of rice. The parts affected are usually the faucial and lingual tonsils, lateral pharyngeal walls, and base of the tongue.

Symptoms.—As a rule, there are no symptoms and the disease is accidentally discovered while inspecting the throat. At the base of the tongue they are liable to irritate the epiglottis and produce a sensation of roughness and tickling in the throat.

Diagnosis.—Keratosis may be mistaken for chronic lacunar tonsillitis. In keratosis the masses are tough, firmly adherent, and difficult to remove. Furthermore, keratosis is not invariably confined to the area of the tonsil.

Treatment.—The symptoms are rarely of sufficient severity to necessitate treatment, and spontaneous recovery usually takes place after a considerable period of time. Forcible removal of the masses is usually followed by recurrence. In cases where the symptoms are annoying to the patient it is feasible to destroy the offending masses by means of the galvanocautery puncture, the process requiring penetration through the mass into the lymph follicles for a distance of at least four millimetres. The inflammatory reaction from the galvanocautery is considerable; hence, but few punctures should be made at one sitting.

SECTION III.

The Larynx.

CHAPTER XLVIII.

ACUTE INFLAMMATORY DISEASES.

Anatomical Points of Interest.—The anatomical landmarks of the larynx of interest to the surgeon are depicted in the accompanying illustrations from Deaver's "Surgical Anatomy of the Head and Neck." Anatomy of the superior aperture of the larynx is shown in Fig. 496; that of the external anterior surface in Fig. 497; that of the external posterior surface in Fig. 498 and the interior lateral view in Fig. 499.

1. ACUTE INFECTIOUS EPIGLOTTITIS.

Synonyms.—Acute epiglottitis; angina epiglottidea anterior (Michel).

The term acute infectious epiglottitis is used to define a primary acute infection which is limited in area to the epiglottis. Cases of this type have been reported by Michel and Theisen, wherein the inflammatory process was confined to the anterior surface of the epiglottis and usually with edema. Kyle does not believe that the disease under consideration exists except in conjunction with an associated laryngitis. The author has observed one case of this type in a man forty years old who apparently had developed a primary local edema of the anterior surface of the epiglottis, but upon close inspection congestion of the intralaryngeal mucosa was evident.

Hajek has shown that the mucous membrane of the anterior surface of the epiglottis is less adherent than on the posterior surface; for this reason edema of the anterior surface is more common.

Diagnosis.—The diagnosis is based upon the characteristic symptoms, viz.: a sudden attack of inflammation of the tissues overlying the epiglottis, attended with fever, swelling and edema, which is limited chiefly to its lingual surface, and painful deglutition. It should be differentiated from angioneurotic edema, which develops without fever, the edematous tissue of the latter being a grayish color, and from acute infectious laryngitis, by the absence of laryngeal symptoms.

Treatment.—At the outset the patient should be placed in bed with the head elevated. The administration of calomel and salines produces a favorable effect. The chief indication for treatment of

the local lesion is to relieve the edema. This is best accomplished by a series of incisions of sufficient depth to afford drainage to the waterlogged tissues. The scarifier devised by Tobold (Fig. 502) is a safe and convenient instrument for this purpose.

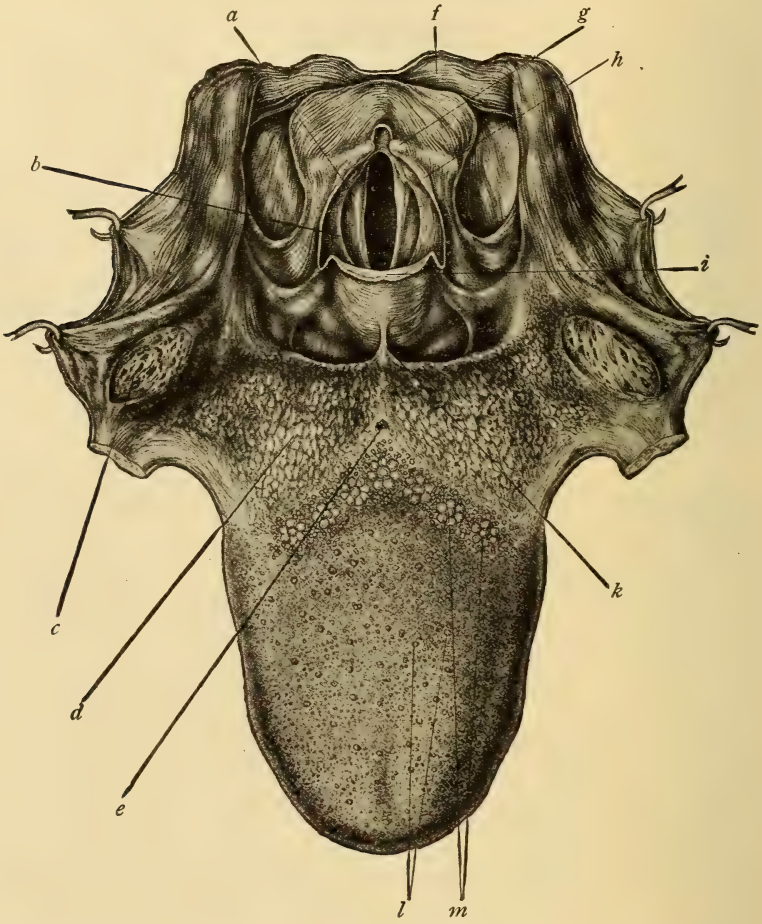

Fig. 496.—Superior aperture of the larynx. *(Deaver,* with permission.)

a, vocal band; *b*, ventricular band; *c*, tonsil; *d*, adenoid tissue at base of tongue; *e*, foramen cecum; *f*, posterior wall of pharynx; *g*, corniculum laryngis; *h*, cuneiform cartilage; *i*, epiglottis; *k*, median glossoepiglottic fold; *l*, fungiform papillæ; *m*, circumvallate papillæ.

Relief by means of scarification is not invariably permanent, and it is often necessary to repeat the scarification at intervals. A patient suffering with this disease should not be left unattended by the surgeon or his assistant until the edema has sufficiently subsided and all danger of suffocation has passed, inasmuch as fatal cases have been reported. A tracheotomy tube should be at hand in order to meet the emergency of urgent dyspnea. Ice-bags

applied over the anterior surface of the neck have been recommended, and iced sprays containing ichthyol have been used with success by Meyjer, while Tyson used a ½ per cent. solution of ichthyol applied locally to the epiglottis every half hour during the acute stage. A spray solution of the following ingredients is of great benefit:—

℞ Tannin glycerid,
Lemon juice,
Sol. adrenalin chlorid, 1: 10,000,
Normal salt solution.....āā ʒij.

Sig.: Keep in cold place and spray larynx every half hour or every hour.

2. SIMPLE ACUTE LARYNGITIS.

Synonyms.—Acute catarrhal laryngitis; laryngorrhea. In young children the disease is termed spasmodic croup, or spasmodic laryngitis.

AS OBSERVED IN ADULTS.

This disease is characterized by an acute inflammatory process involving the laryngeal mucosa. It rarely occurs as a purely local affection, the laryngeal inflammation being merely part of a more general attack which involves the upper respiratory tract and often the trachea and bronchi as well. While annoying on account of the attendant dryness and hoarseness, it is usually trivial in its consequences, except to singers, teachers and public speakers, who become temporarily incapacitated thereby. Certain individuals are subject to recurrent attacks, especially during the spring and fall change of seasons.

Etiology.—Simple acute laryngitis is caused in exactly the same manner as that more common affection, simple acute rhinitis (see Chapter XXXIII). The chief predisposing factors are chronic rhinitis, obstructive nasal lesions, chronic laryngitis, abuse of alcohol and tobacco, eruptive fevers, bodily fatigue, and certain systemic disturbances, especially those of vasomotor, digestive and toxic origin; while overwork, sedentary habits and bad hygiene, by lowering the bodily resistance, become causative factors. Of the exciting causes, undue bodily exposure, especially of the feet, the inhalation of noxious gases and emanations, and bad ventilation are the chief.

Pathology.—The pathological changes are identical with those observed in other portions of the respiratory tract under similar conditions and heretofore described (Chapter XXXIII), with the same stages, but with less secretion, owing to the fact that glandular development in the larynx is meagre. During the initial stage there is congestion and engorgement of the blood-vessels, followed by infiltration of the mucosa with leucocytes and round cells, the latter condition tending to diminish the lumen of the larynx. This stage is soon followed by the appearance of exudate, the character

of which is thin and watery at first, but, owing to the desquamation of epithelium, it gradually becomes denser and lighter in color. Occasionally the inflammatory process extends to the muscles, when the movements of the arytenoids and vocal cords become impaired.

Symptoms. — At the commencement there is slight chilliness, lassitude and some rise of temperature, with a distinct sensation of burning, itching or tickling within the larynx. This is soon followed by hoarseness and a dry, hacking cough. During the second stage the symptoms are all aggravated, phonation often becoming painful, hoarseness marked, and complete loss of voice may ensue.

Cough continues, expectoration is scanty, and dysphagia may be complained of. The temperature rarely rises above 102°. The inflammation is general throughout the entire mucosa, with sufficient swelling to interfere with the mobility of the parts. Edema is rare. At the commencement of the third stage a mucopurulent secretion appears, which relieves the dryness. The cough becomes less rasping, pain subsides, and recovery gradually ensues. Slight hemorrhages sometimes occur as the result of the severe strain produced upon the congested membranes by the par-

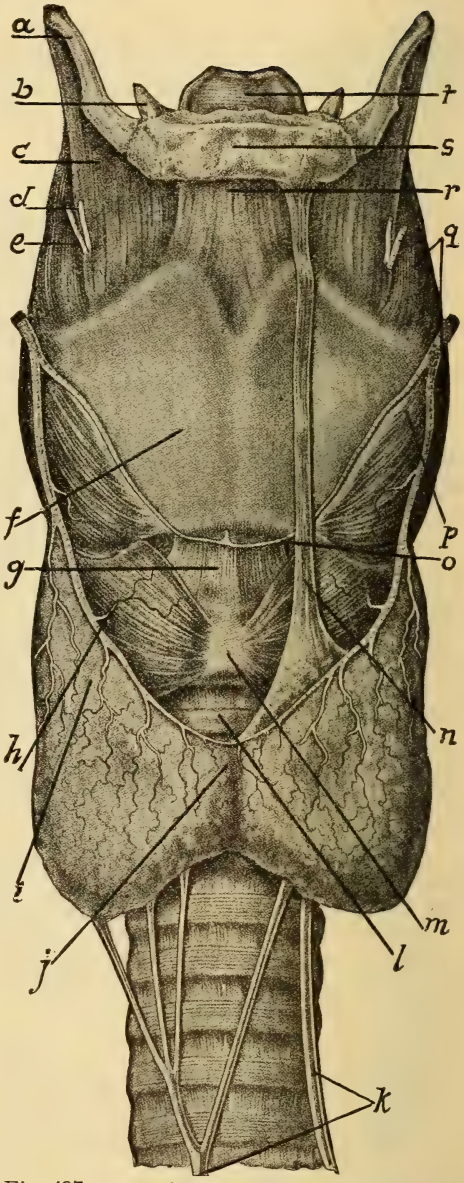

Fig. 497.—Anterior external structures of the larynx. *(Deaver,* with permission.)

a, greater cornu of hyoid bone; *b*, lesser cornu of hyoid bone; *c*, lateral portion of thyro-hyoid membrane; *d*, internal laryngeal nerve; *e*, superior laryngeal artery; *f*, thyroid cartilage; *g*, crico-thyroid membrane; *h*, crico-thyroid muscle; *i*, lateral lobe of thyroid gland; *l*, trachea; *j*, isthmus of thyroid gland; *t*, epiglottis; *s*, hyoid bone; *r*, central portion of thyro-hyoid membrane; *q*, inferior constrictor muscle of pharynx; *p*, superior thyroid artery; *o*, crico-thyroid artery; *n*, levator glandulæ thyroideæ muscle; *m*, cricoid cartilage; *k*, inferior thyroid veins.

oxysms of coughing. Objectively, the laryngeal mucosa appears intensely inflamed, the vocal cords are red and sometimes dotted with small areas of ecchymosis. The infiltration, which involves the arytenoids, ventricular bands and rim of the epiglottis, interferes with the free movement of the vocal cords. Accumulations of secretion are visible, especially in the posterior commissure.

Prognosis.—With proper care and treatment the disease is not serious and recovery takes place in from four to seven days. In neglected cases occurring in persons with lowered vitality from any cause, or those who suffer from chronic laryngitis, the inflammation and infiltration may persist for some time. Repeated attacks tend to establish a chronic laryngeal inflammation.

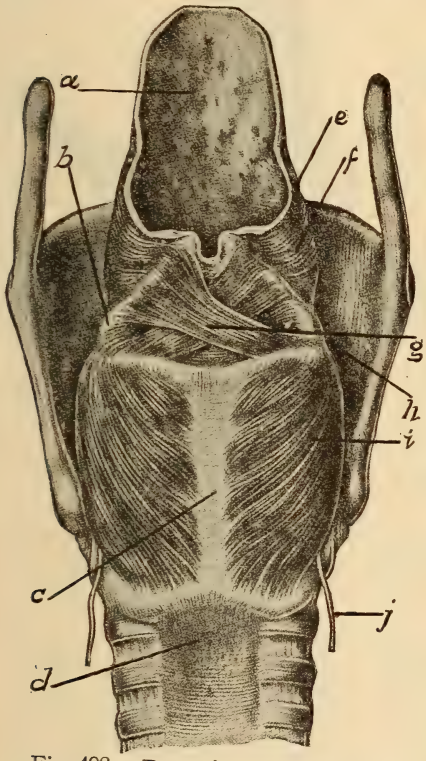

Fig. 498.—Posterior external structures of the larynx. *(Deaver,* with permission.)

a, laryngeal surface of epiglottis; *b,* muscular process of artenoid cartilage; *c,* cricoid cartilage; *d,* trachea; *e,* aryepiglottic fold; *f,* aryepiglottic muscle; *g,* arytenoideus muscle; *h,* thyroid cartilage; *i,* posterior cricoarytenoid muscle; *j,* recurrent laryngeal nerve.

General and Preventive Treatment. — The necessary measures for general treatment are those already described for acute catarrhal rhinitis (see preventive treatment of acute rhinitis), and if instituted early terminate the attack.

Local Treatment. — If severe, with rise of temperature, the patient should be advised to remain in a warm room, and in the case of singers and public speakers the voice should be given complete rest. All conversation should be in whispers. Free calomel and saline purgation is of inestimable value. The application of a cold compress or an ice-coil to the larynx for a few hours during the early stage of the disease tends to retard and diminish the inflammatory process. Cough should be controlled in order to minimize the muscular movements of the larynx. A useful sedative will be found in codeine, gr. ¼ to ½ every four hours, or heroin, gr. 1/24 every three hours. The intralaryngeal applications of strong astringents sometimes advised are harmful, since they cause severe pain, aggravate the symptoms, and never are beneficial. Applications to the membranes should invariably be of a soothing nature. Insufflations are likewise ill-advised on account of the paroxysms

of cough which they produce. The diaphoretic effect of a hot mustard footbath in conjunction with a hot draught of lime or lemonade is soothing and hastens the stage of exudation.

The following may be administered as an expectorant:—

℞ Ammonii chloridi ..... ʒss.
Syr. scillæ,
Syr. Tolutani,
Spr. æth. nitrosi .....āā ʒj.
Elix. simp. .....q. s. ad ℥iv.
M. Sig.: Teaspoonful every four hours.

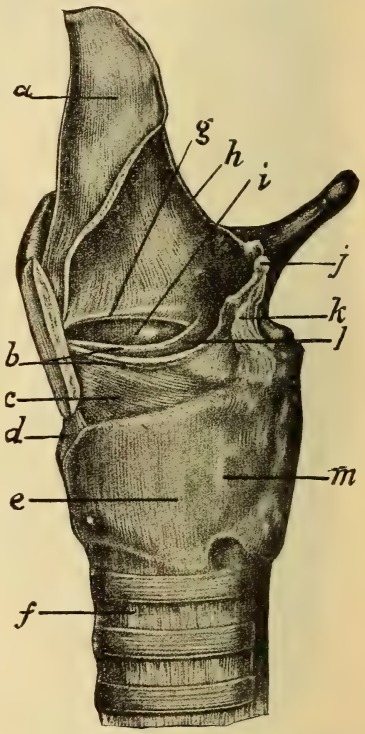

Fig. 499.—View of the internal lateral structure of the larynx. (*Deaver*, with permission.)

a, epiglottis; *g*, false vocal cord; *i*, ventricle of larynx; *b*, true vocal cords; *c*, lateral portion of crico-thyroid membrane; *d*, central portion of crico-thyroid membrane; *e*, cricoid cartilage; *f*, trachea; *h*, aryteno-epiglottidean fold; *j*, corniculum laryngis; *k*, arytenoid cartilage; *l*, rima glottidis; *m*, facet for inferior cornu of thyroid cartilage.

Much relief to the dry, inflamed membranes may be obtained from medicated steam inhalations. Any reliable form of inhaler (Fig. 504) will suffice. To the boiling water may be added 10 drops of spirits of camphor, 10 grains of menthol, or a dram of compound tincture of benzoin to the pint. The inhalations should continue about ten minutes and be repeated every two hours. Vapors of creosote and eucalyptol have likewise been recommended, but are less efficacious. Mild counterirritants over the larynx in the form of sinapisms, or rubbing with a mixture of equal parts of turpentine and olive-oil, may allay the cough during the second stage, and at night it may become necessary to relieve the tickling sensation in the larynx by the use of some form of lozenge, to be gradually dissolved in the mouth. One composed of codeine, gr. $\frac{1}{10}$, and camphomenthol, gr. $\frac{1}{20}$, has proven most efficacious in the author's practice.

By promptly resorting to the foregoing measures an acute attack may be partially aborted, with complete recovery in from thirty-six to forty-eight hours. Immediate relief, in order that an engagement may be filled, is often demanded by persons professionally engaged—singers, public speakers, etc. Such individuals should be strongly advised against singing or speaking when the larynx is acutely inflamed, and warned that the attempt is fraught with considerable danger of producing a long-continued laryngitis, prolonged weakness and inefficiency of the laryngeal muscles, and possible sufficient damage to the voice to

require prolonged rest. Should a patient, in the face of such advice, insist upon an attempt to fulfill the engagement, it becomes imperative to afford him as much aid as is possible while so doing. To this end Watson Williams advises strychnia, gr. 1/30, administered by hypodermatic, and twenty minutes preceding the engagement to atomize the throat with deep inhalations of a solution composed of the following:—

℞	Menthol	gr. vj.
	Morph. sulph.	gr. ss.
	Cocainæ hydrochl	gr. ij.
	Acidi oleici	♏xv.
	Olei vaselini	ʒss.

A small amount of a 1:5000 solution of adrenalin chlorid sprayed directly into the larynx produces contraction of the tissues without ill effects. During the engagement the codeia lozenge above mentioned may be allowed to dissolve in the mouth. Patients are sometimes temporarily benefited by the employment

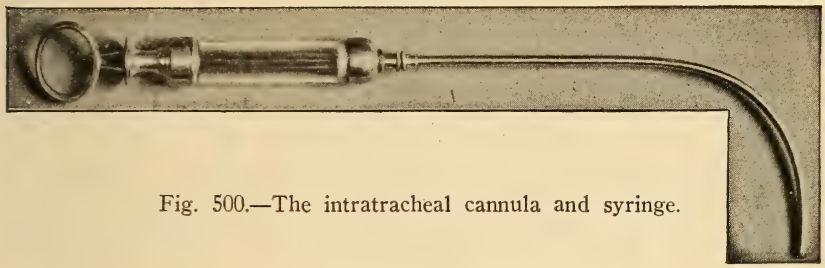

Fig. 500.—The intratracheal cannula and syringe.

of mild astringents. A spray of chlorid of zinc, 10 grains to the ounce of water, is usually employed when an astringent is indicated. An intratracheal injection (Fig. 500) of a 2 per cent. solution of camphor and menthol in benzoinol, at least ten minutes previous to singing or speaking, gives much relief and is of material aid to the voice. Intratracheal injections employed three or four times daily produce great relief of the distressing dry cough and laryngeal irritation. The injection should be carried into the larynx through a long curved cannula attached to a syringe. The patient withdraws the tongue and the surgeon introduces the laryngeal mirror, and, as soon as he obtains a view of the interior of the larynx, the cannula is guided into position. The patient is then instructed to inhale and the remedy is slowly instilled into the larynx. The smarting and discomfort is momentary, and it is followed by immediate relief. A few drops of a 15 per cent. solution of argyrol slowly instilled into the larynx produces great relief in severe cases. When argyrol is employed its application should be preceded by the instillation of a few drops of a weak solution of cocaine, in order to prevent a spasm. Many of these cases are complicated by more or less tracheitis. When this complication is present the author strongly advises the intratracheal use of a formula made up of—

℞ Menthol,
Guiacal .....āā 1 per cent.
Sterile olive oil, ... q. s.

Sig.: About one-half a dram of this mixture should be introduced into the trachea two or three times a day for several days.

When hemorrhage occurs the patient should be placed in bed and the larynx carefully sprayed with a 1 : 5000 solution of adrenalin chlorid, an ice-coil should be placed upon the neck and ice administered by the mouth. Edema is a rare occurrence in uncomplicated simple acute laryngitis. Should it occur, prompt surgical interference becomes necessary and the edematous tissue must be incised after the manner described for œdema glottidis (page 763).

SIMPLE ACUTE LARYNGITIS IN CHILDREN.

Synonyms.—Spasmodic croup; spasmodic laryngitis; false croup; laryngitis stridulosa.

In young children from one to five years of age simple acute laryngitis is more serious, owing to the smaller calibre of the larynx and the comparatively greater amount of intralaryngeal swelling. These give rise to additional symptoms of extreme dyspnea, with stridulous respiration. The temperature is higher than in adults, often reaching 104° to 105°, and the dry, metallic cough may be accompanied by alarming embarrassment of respiration. The paroxysms are usually nocturnal and are aggravated by the accumulations of thickened mucus which are retained during sleep.

Enlarged tonsils and adenoids strongly predispose to the attacks.

Symptoms.—The spasmodic attack is usually preceded by a day or two of hoarseness and a croupy cough, during which the child is cross and restless, and the skin is dry and hot. The typical paroxysm comes on during the early part of the night, when the child awakes suddenly with alarming dyspnea, stridulous breathing and a frantic struggle for air which continues without abate until the retained secretions are dislodged. Recurrence may take place several times during the night, and the attacks may be expected to recur for at least three nights.

Diagnosis.—The diagnosis is based upon the absence of the typical symptoms of diphtheria, membranous laryngitis, pressure from neoplasms, abscesses, or glandular enlargement in the immediate vicinity.

Treatment.—Laryngitis, even in slight form, occurring in infants calls for prompt measures in order that the nocturnal paroxysms of croup may be prevented. A brisk cathartic, castor-oil preferred, rest in bed and the employment of steam inhalations, medicated with compound tincture of benzoinol, a dram to the pint of water, administered under a tent; hot fomentations applied to the neck and brisk rubbing of the neck and chest with camphorated oil, are the remedies usually employed. For internal medication the following expectorant formula is recommended by Parker:—

℞ Vini ipecacuanha ..... ♏ij.
Solution of ammonium acetate ..... ♏xv.
Ammonium carbonate ..... gr. ss.
Syrup of Tolu ..... ♏x.
Aquæ .....q. s. ad ℥j.
M. Sig.: Every four hours.

Minute doses of codeine, gr. 1/20 every three hours, for a child of three years of age, may be given when the cough is severe and the child sleepless therefrom. Bosworth administers codeine in the following formula:—

℞ Dilute hydrocyanic acid ..... ♏ij.
Codeine ..... gr. iss.
Carbonate of ammonium ..... gr. xv.
Cherry laurel water .....q. s. ad ℥ij.
M. Sig.: A teaspoonful every two hours to a child of seven years, and less in proportion for younger children.

The nose should be kept free from accumulated secretion by spraying with an alkaline solution. For the paroxysm a hot mustard bath composed of 1 dram of mustard to the gallon of water, at a temperature of from 100° to 110° F., may be given with much benefit. The child should remain immersed in this solution for eight or ten minutes and then be wrapped in blankets and placed in bed underneath a tent in which a steam kettle is in constant use. If emesis can be induced the relief will more quickly ensue. This may be accomplished by tickling the patient's fauces with the finger. The administration of emetics is slower in action and often induces severe indigestion, which may persist for several days.

It may here be stated that measures so serious as tracheotomy and intubation are rarely required for the relief of the paroxysms of spasmodic croup. Should the symptoms remain obdurate and emesis imperatively demanded, a dose of one dram of the wine of ipecacuanha, or sulphate of zinc, grs. 10 to 20, dissolved in milk, should be administered at one dose.

Subsequent to the attack the child should be examined for diseased tonsils and adenoids, placed under proper hygiene surroundings, and his clothing, diet and habits should be regulated to meet the conditions of climate, season of the year and his state of health. Children who are free from diseased tonsils and adenoids, who are kept much of the time in the open air, and are not "coddled" or overclothed, especially about the throat, are rarely subject to spasmodic croup.

3. ACUTE INFECTIOUS LARYNGITIS.

Synonyms.—Acute edematous laryngitis; œdema glottidis.

DUE TO GENERAL INFECTIONS.

Acute infection of the laryngeal mucosa occurring in the course of the exanthemata and other specific fevers are described in Chapters XXXI and XXXII.

DUE TO LOCAL INFECTIONS.

(*a*) Acute Edematous Laryngitis.

Acute edematous laryngitis is an acute inflammatory process of septic origin, involving the laryngeal mucosa and occurring sometimes primarily, but more often in conjunction with pathogenic inflammations of nearby structures. The infection may involve the mucous membrane alone, the submucous tissues, and it may invade the perichondrium of the laryngeal cartilages. In the superficial form, wherein the mucous membrane only becomes inflamed, the symptoms are similar to those of simple acute laryngitis, but with a higher range of temperature and longer duration.

A *B*

Fig. 501.—The Hays pharyngoscope and laryngoscope. *A,* First position in inserting the instrument. *B,* The pharyngoscope in place with the mouth closed. (*Hays,* with permission.)

When the infectious process invades the submucous areas the attack is characterized by sudden and severe inflammation of the larynx, with edema, and distressing dyspnea.

Etiology.—The excitant is always some form of pathogenic micro-organism, of which the streptococcus in the most common. It is more common in males and is essentially a disease of middle life. The disease rarely occurs as a primary affection, but is secondary to septic tonsillitis, pharyngeal phlegmon, peritonsillar abscess, erysipelas, or angina Ludovici. Systemic affections, especially the specific fevers, diabetes, Bright's disease or alcoholism, are contributing factors.

Pathology.—Primarily the attack induces rapid and severe inflammatory changes in which the laryngeal mucosa becomes intensely congested, swollen and infiltrated with serous exudate. Edema rapidly supervenes and may involve the entire larynx, but

it is usually confined to the epiglottis and the tissues surrounding the arytenoids. As the edema increases, the epiglottis entirely loses its normal outlines and becomes a large, bulbous mass (Fig. 503). In like manner the mucosa in the region of the arytenoids may become edematous. Subglottic edema is rare except in the severest cases. The process usually resolves without tissue necrosis, but severe cases are likely to terminate in large sloughs or abscesses.

Symptoms.—The symptoms are somewhat varied. In mild cases the patients complain of sore throat, with dryness and fullness. As soon as the epiglottis becomes congested, dysphagia appears, while, with the development of edema, dyspnea may be expected. Mild cases with low temperature and little edema are unaccompanied by severe symptoms, except some hoarseness and hawking attempts to relieve the sensation of fullness. When the

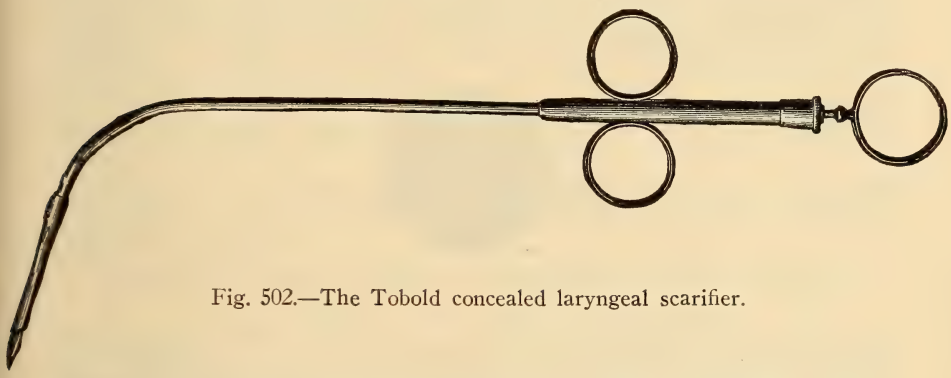

Fig. 502.—The Tobold concealed laryngeal scarifier.

disease is more severe it is ushered in by rigors, moderate rise of temperature, and intense pain and discomfort in the larynx, partially from inflammation and partially from pressure. This is accompanied with dysphagia and often urgent dyspnea, which in many patients produces a fear of impending suffocation. For about thirty-six hours the symptoms continue to increase in severity, after which the crisis may be expected. When abscess develops there is no definite time of crisis and all symptoms may be alarming for several days, during which the temperature curve will indicate sepsis, and pain will be severe. This affection occurring in weakened individuals who have diabetes or Bright's disease, or during convalescence from any of the infectious fevers, or when complicated with general infection of the upper air passages, leads to other and more alarming symptoms and complications, the chief of which are great prostration, septic pneumonia and extreme dyspnea. A fatal issue sometimes ensues from exhaustion or cardiac failure.

Diagnosis.—Examination of the larynx either by the laryngeal mirror or by the Hays pharyngoscope (Figs. 22 and 501) reveals intense engorgement and edema. This condition in a patient giving a history of dyspnea, dysphagia and severe, irritating cough of short duration is sufficient to establish a diagnosis. It may be confounded

with foreign bodies, traumatism, burns and scalds, or with cancer, syphilis and tuberculosis.

Prognosis.—In the simpler cases, under proper treatment, the prognosis is good. Death may occur from suffocation, exhaustion, general sepsis, or from cardiac or pulmonary complications.

Treatment.—At the onset the patient should be instructed to remain in bed in a well-ventilated room of even temperature.

General Treatment.—The patient's strength should be sustained by the free use of plain, wholesome, soft diet, consisting of meat broths, milk, eggnog, etc. Stimulants are admissible, especially after symptoms of exhaustion appear. The medicinal treatment should be commenced with a brisk cathartic, calomel preferred. If grippe, rheumatism or gout be present, phenacetin and salol, in doses of 2 to 3 grs. each, every three hours, or of aspirin, 5 grs. every four hours, will relieve pain and shorten the duration of the disease. Strychnia is often required to sustain the heart. Many authors recommend the internal administration of large doses

Fig. 503.—Edema of the epiglottis and arytenoids relieved by incisions.

of tincture of perchlorid of iron. This drug never has produced marked relief in the author's experience. Free doses of codeia, from ¼ to 1 gr. every four hours in adults, relieves the cough, pain and irritation, and this, in turn, tends to relieve the edema. The bromids are beneficial in extreme dyspnea, especially when complicated with pulmonary affections or exhaustion (Parker). Semon recommends the frequent inhalation of oxygen, provided any pulmonary complication arises.

Local Treatment.—During the early stages relief follows the application of the ice-coil to the neck, and the administration of ice by mouth. Spraying the larynx with a 2 per cent. solution of cocaine has been extolled and is admissible except to those possessed of an idiosyncrasy, or who are exhausted from wasting diseases. An intratracheal injection (Fig. 500) of a small quantity of a solution of suprarenal extract, 1:5000, with or without the addition of cocaine, is most efficacious and may be applied hourly if the symptoms demand.

The lemon-juice and adrenalin spray (see page 753) applied to the swollen and edematous tissues at frequent intervals produces an astringent effect and at the same time reduces the swelling.

Abscesses, wherever located, should be promptly incised. Local bloodletting, whether by leeches or incisions, is of questionable efficacy. Whenever edema occurs, especially with sufficient

severity to cause dyspnea, the edematous tissue should be scarified without delay. It is always dangerous to leave a patient in this condition unattended by the surgeon, because of the danger of suffocation, and a sterile tracheotomy outfit should be at hand in case a tracheotomy becomes necessary.

The operation of scarifying should be preceded by an application of a 10 per cent. solution of cocaine over the edematous surface. After a delay of ten minutes, with a curved concealed laryngeal knife (Fig. 502) the parts most distended should be incised to the depth of about 5 millimeters, and 5 to 10 millimeters in length (Fig. 503). From two to five such incisions may be made at one sitting, with great relief. A free flow of blood and serum follows, and in order to prevent it from entering the larynx the patient's head should be bent forward and downward.

Large abscesses are sometimes encountered, the opening of which may be followed by alarming suffocation, and immediate tracheotomy may become necessary. In those cases wherein the edema is general throughout the larynx, tracheotomy, (Chapter XXXI) offers the only relief.

Scarification of the tissues should be followed by continuous medicated steam inhalations. Occasionally these are not well borne.

MacEwen's suggestion that a soft-rubber catheter be passed through the larynx and left *in situ* until the edema subsides is worthy of mention.

(*b*) Acute Infectious Perichondritis.

Etiology.—It is a rare affection in which the bacterial invasion of the perichondrium occurs as a complication of acute infectious fevers, chiefly typhoid, typhus, diphtheria, erysipelas, and pyemia, or from traumatism.

Pathology.—The disease is usually local and confined to one cartilage, and the infection enters through an abrasion or ulceration, or through the blood or lymph channels. The invasion is characterized by swelling, inflammation, edema and more or less loss of motility. If resolution does not take place the deeper structures become involved, necrosis of the soft tissue takes place with abscess formation, or the necrotic process may invade the cartilage and finally result in sloughing, ankylosis, adhesions, laryngeal deformities, and occasionally, stenosis of the larynx.

Symptoms.—Localized pain in the larynx, moderate fever, and chilly sensations are the first symptoms complained of. As the disease progresses and the swelling encroaches upon the lumen of the larynx, the patient complains of suffocation, the voice becomes impaired, and the general appearance is that of extreme anxiety. Meanwhile there is no cessation of the pain, and there is marked impairment of the movements of the cartilage. The great prostration and exhaustion which marks the accumulation of septic products may be of sufficient severity to cause a fatal issue. In more

favorable cases, with proper treatment, where the necrosed tissues either slough or are removed by surgical means, and where the abscesses are freely opened and properly drained, recovery is the rule.

Diagnosis.—The diagnosis is based upon the appearance and the history of localized pain, fever and abscess. The condition should be differentiated from chronic perichondritis (syphilitic, tuberculous, cancerous).

Prognosis.—The majority of patients recover, but troublesome sequelæ in the form of impairment of the voice and partial laryngeal stenosis may persist through life.

Treatment.—The general and local treatment is similar to that for acute edematous laryngitis heretofore described. All phonation must be prohibited except by whispering. In advanced cases surgical measures furnish the only means for relief. The edematous tissue within the larynx should be incised at several points, under cocaine anesthesia, using for this purpose the curved, concealed laryngeal knife (Fig. 502). In a similar manner abscesses should be evacuated. When the swelling fluctuates externally, free incision should be made through the skin and down to the seat of the disease, in the cartilage. If possible this operation should be done under local anesthesia.

Alarming dyspnea calls for prompt tracheotomy unless relief is obtained by an intralaryngeal injection (Fig. 500) of a mixture containing cocaine, 4 per cent., and adrenalin, 1:5000, or the astringent spray (page 753). Parker recommends the following:—

℞ Potassii iodidi ..... gr. xv.
Ammonia carbonat ..... gr. iij.
Ferri citratis et ammonia ..... gr. x.
Aquæ .....q. s. ad ℥j.

(*c*) Membranous Laryngitis.

Synonyms.—Membranous croup; croupous laryngitis; pseudomembranous croup; diphtheritic laryngito; idiopathic membranous croup; true croup.

There are two general varieties of membranous laryngitis, viz., the diphtheritic and the non-diphtheritic. The former (laryngeal diphtheria) is fully described in Chapter XXXI, and is a separate and distinct affection from the type which is herein defined. In each there is an obstructive inflammation of the laryngeal mucosa, with an outpouring of fibrinous exudate.

Membranous laryngitis is idiopathic, non-contagious and non-communicable; it is local in its course and the membrane is confined to the laryngeal region. The Klebs-Loeffler bacillus is never found, and it does not terminate in paralysis or renal complications.

Etiology.—Lowered resistance from any cause predisposes to this affection. The disease is rare, occurs only in childhood, and is not common after the seventh year. It is often difficult to determine the exciting cause, but it is known that the affection may be induced by applications or inhalations of irritants, burns and

scalds from inhalations of steam or smoke, caustics accidentally applied, or traumatism from cuts, falls and fractures. There is considerable evidence that the disease develops secondarily to scarlet fever, small-pox, pneumonia, and other virulent infections, esepecially the streptococcus.

Pathology.—The characteristic pathological alteration is the appearance of a true fibrinous membrane on the laryngeal mucosa similar in appearance to that of diphtheria, but without the Klebs-Loeffler bacillus. The exudate is fibrinous and is located upon the epiglottis, arytenoid cartilages, and ventricular bands, often extending into the subglottic space. Occurring in children, it is difficult to inspect the larynx and watch the development of the membrane. The exudate is yellowish, less adherent than in diphtheria, and does not penetrate as deeply into the mucosa as the lesion of the diphtheria.

Symptoms.—There are no prodromal symptoms. The disease comes on suddenly and at the commencement there is hoarseness of a peculiarly metallic quality, associated with some malaise and rise of temperature. Cough soon ensues and is low-pitched, metallic and extremely croupy in character. In severe cases dyspnea, dysphagia and finally complete aphonia are among the early symptoms. Dyspnea is a continuous and often an alarming symptom. Its onset is gradual and it is characterized by stridulous, crowing noises, both with inspiration and expiration, and it produces the clinical picture of impending suffocation.

Whenever portions of the membrane come away as the result of paroxysms of coughing or from medication, the symptoms partially subside. During the paroxysms there is extreme restlessness, cyanosis, the head is thrown backward, and usually abdominal recession occurs with each respiratory act. Unless relieved by expulsion of membrane, by tracheotomy (Fig. 299) or by intubation (Fig. 292), the patient gradually succumbs and death from asphyxiation ensues.

Expulsion of the membrane invariably brings relief. Furthermore it is a favorable symptom, even though the membrane reforms. In favorable cases the membrane exfoliates spontaneously, and after a period of from three to five days the exudate disappears. Extension of the membrane and the development of pneumonia are unfavorable complications.

Diagnosis.—The disease may be mistaken for spasmodic croup, edema of the larynx, diphtheria, or foreign bodies in the larynx. In spasmodic croup there is more pain, the respiratory disturbance is less prolonged, and there is no membranous exudate. Laryngeal edema, while accompanied by cough and labored respiration, the cough is less metallic and usually is moist and accompanied by expectoration. Diphtheria (see Chapter XXXI) has many symptoms in common, but there is usually a pharyngeal deposit of membrane, a history of contagion, more constitutional disturbance, and, finally, the bacterial examination shows the presence of the Klebs-Loeffler bacillus. Foreign bodies in the larynx may cause stridulous respira-

tion and cough, but it is less metallic, less hoarse, there is no fever and a change in the position of the patient's body often causes a change in the character of the symptoms.

Prognosis.—The prognosis is always grave. In fatal cases death results from immediate suffocation, carbonic acid poisoning (asthenia), or pulmonary complications. Intubation has materially lowered the death rate.

Treatment.—During the early stages, previous to the formation of the membranous exudate, all measures heretofore recommended for acute laryngitis in children should be employed. In addition, the patient should be kept in a warm, well-ventilated room, the



Fig. 504.—Croup kettle or steam inhaler.

atmosphere of which is constantly charged with steam. The steam may be generated from several "croup kettles" (Fig. 504) in the absence of a stove. If necessary the patient may be kept underneath a tent surcharged with steam, and with only a small opening for ventilation. Relief is sometimes obtained from impregnating the steam with camphor or menthol. Steam impregnated with unslaked lime has been advocated for inhalations. It is generated by placing a large lump of lime in a wooden bucket containing four or five quarts of boiling water. The effect of the menthol may also be obtained by burning crystals in a spoon or other receptacle over a flame. These remedies are all employed for the purpose of decreasing and dislodging the membranous exudate.

Emetics sometimes afford temporary relief but they are extremely depressing. Wine of ipecacuanha is effective for this purpose. Calomel is a most efficacious remedy for the relief of the ur-

gent symptoms of membranous laryngitis. At the commencement of the disease a liberal dose should be administered internally. Calomel inhalations also produce marked relief of the dyspnea. The method of employment is as follows: With the patient underneath a tent, the fumigations should be administered every two hours, by subliming 5 to 20 grains of calomel. After one day the intervals may be prolonged, providing relief has been obtained; otherwise, the calomel sublimations should be abandoned. Should the dyspnea increase, threatening suffocation, in spite of all efforts to relieve by general and local treatment, tracheotomy or intubation should immediately be resorted to, before the symptoms of exhaustion have appeared. Intubation skillfully performed is preferable and gives better results.

4. ACUTE LARYNGITIS DUE TO TRAUMATISM.

Etiology.—Acute laryngitis of traumatic origin is similar to ordinary acute laryngitis unless infection ensues. The following accidents or injuries are among the etiological factors. The inhalation of irritating gases or steam fumes; the inhalation of foreign bodies; the injuries which result from swallowing rough or jagged bodies; the intralaryngeal application of caustics; rupture of blood-vessels; external injuries from blows, strangling or cut-throat.

Symptoms.—The symptoms vary with the cause and extent of the injury. When this is slight and no sepsis supervenes, the wounds will heal promptly and there is only slight discomfort. When the area of injury is extensive, as from scalds or corrosive poisons, the inflammation is prone to induce edema and great discomfort results. When infection ensues, abscesses are likely to form, and the large sloughs which may form sometimes eventuate in gangrene.

Treatment.—The treatment for acute laryngeal inflammations and for acute edema is described under the appropriate headings. When the laryngeal lesion is due to foreign bodies, cut-throat, fractures or other injuries, prompt surgical measures are indicated.

CHAPTER XLIX.

CHRONIC INFLAMMATORY AFFECTIONS OF THE LARYNX.

1. CHRONIC HYPERPLASTIC LARYNGITIS.

It is convenient to study this subject under the following headings, which are based largely upon the clinical manifestations: 1, simple chronic catarrhal (diffuse) laryngitis; 2, chronic subglottic laryngitis; 3, pacchyderma laryngis; 4, chorditis nodosa (singers' nodes).

Following the plan adopted by Parker, in order to avoid needless repetition, the etiology, symptoms, diagnosis, prognosis and general treatment of the various types are considered together. Following this, a detailed description of the distinctive characteristics of each type will receive consideration.

Etiology.—Chronic laryngitis is rarely, if ever, a primary affection. It occurs chiefly as a result of a succession of acute inflammations, either of the entire upper respiratory tract, or of the laryngeal mucosa alone. These attacks are superinduced by a series of contributing causes which act both directly and indirectly.

Contributing Causes.—Among the contributing causes are nasal stenosis, which gives rise to mouth-breathing, and robs the inspired air of the sifting and moistening process ordinarily furnished by the nasal erectile tissue. The purulent and otherwise unhealthy secretions emanating from purulent affections of the nasal accessory sinuses, from chronic pharyngitis, from chronic lacunar tonsillitis, and from specific ulcerations, accumulate about the laryngeal orifice and thereby induce severe local irritation. In order to relieve this, the patient almost constantly coughs and hawks in his effort to dislodge the retained secretion, and this act tends to produce intralaryngeal congestion.

Laryngeal inflammation associated with acute infections, especially grippe, may be sufficiently serious and deep seated to become chronic. Prolonged sojourn in damp, cold atmospheres, or in air laden with smoke, dust, irritant fumes, etc., is extremely deleterious to the laryngeal membranes.

Chronic laryngitis is common in alcoholics, excessive smokers and certain occupations. Thus smokers, street cleaners, cigar, snuff, wood, stone, metal, and chemical workers become easy victims.

Exacerbations of laryngeal inflammation are more common in damp climates and during the winter months.

Another common cause is overuse or faulty production of the voice, observable in public speakers, singers, and hucksters. In singers this may produce nodes upon the vocal cords, while violent efforts at speaking or screaming by one whose laryngeal membranes

are already inflamed and engorged, may cause rupture of small vessels in the submucosa and give rise to a condition which is generally termed hemorrhagic laryngitis.

Chronic laryngitis, in common with a general relaxed and inflamed condition of the mucosa and muscles of the upper respiratory tract, may be induced by gastric and intestinal disorders. It also occurs in individuals who are victims of gout, rheumatism, anemia and cardiac disease. It is often associated with chronic pulmonary diseases, notably tuberculosis, chronic bronchitis, asthma and emphysema, in which it is aggravated by the accompanying cough.

A further contributing cause is found in new growths and chronic lesions about the throat, neck and thorax, lupus and syphilis.

It is essentially a disease of adult life, and is more common in males probably on account of occupation. The excessive use of tobacco is also often a contributing cause.

Symptoms.—The objective symptoms are pathological and need not be defined here. The subjective symptoms are referred chiefly to the alterations in the voice and to changes in the quality and character of the secretions.

The symptoms which particularly refer to the voice are "tired voice," aphonia, and "breaks" during phonation. Hoarseness is most marked during the early morning hours, but the voice usually becomes more clear as the day progresses unless it is overused. Forced speaking, however, becomes difficult and often impossible, and any prolonged vocal effort will give rise to a sensation of tickling and often strangling cough, to relieve which speakers resort to the frequent drinking of water.

In singers the voice can never be depended upon; it breaks or tires quickly, vocal efforts require forced muscular strain and produce more or less pain within the larynx. There is a sensation of dryness and irritation in the larynx, and a constant, though not increased, exudate of thick, mucopurulent secretion. In severe cases with extensive infiltration in the submucosa there may be complete aphonia for considerable periods. There is an almost constant desire to relieve the dryness, the irritability and the accumulated secretions by hawking or coughing.

The secretions are mucopurulent, often scanty, and laden with particles of dust or other *débris* significant of the patient's occupation. Excessive secretion is rare, and when present should lead to a careful examination of the trachea, bronchi and lungs.

Diagnosis.—The diagnosis, never difficult, is based upon the alterations in the voice, the changes in the laryngeal mucosa, the scanty but thick secretion, and the history of exacerbations of acute laryngitis.

Prognosis.—Aside from the greater susceptibility to acute infections and to local complications, syphilis and tuberculosis, the danger to life is slight. In simple cases wherein the structural changes are slight the disease is curable, providing the underlying cause can be discovered and removed. When the hyperplasia has

extended over large areas the prognosis as to final recovery is less favorable. In these it is often possible to relieve the aggravating symptoms, except in advanced pacchyderma, where only partial recovery may be expected. In singers and public speakers a guarded diagnosis should be given regarding the full recovery of the staying qualities of the voice.

General Treatment.—To discover and eradicate the underlying cause is the first essential in the treatment. Predisposing and contributing factors also should be outlined and given due consideration. If the disease has resulted from a succession of attacks of acute laryngitis, a rigid enforcement of the means of prevention, such as have been outlined for acute rhinitis (Chapter XXXIII), should be inaugurated. Obstructive lesions within the nose and nasopharynx must be removed by appropriate operative procedures, in accordance with the rules laid down in the chapters on the nose, nasopharynx and pharynx. Pulmonary, cardiac, gouty, and rheumatic affections and anemia should be relieved by appropriate measures.

When due to faulty production or misuse of the voice, complete rest should be maintained for a considerable period of time, and followed by the adoption of a correct method of training, under the guidance of an experienced teacher.

The excessive use of alcohol and tobacco should be prohibited, and hazardous occupations should be changed to those with more wholesome surroundings.

If associated with evidences of tertiary syphilis or tuberculosis, these diseases should receive appropriate treatment (see Chapters XXIX and XXX). It is of the utmost importance that patients suffering from chronic laryngitis should have proper physical exercise, preferably in the open air, with fresh air even during sleep, and that they should avoid sedentary habits or occupations.

A full diet of plain foods minus spices and condiments should be given, the bowels to be properly regulated by morning doses of laxative salts for several days at a time, and if necessary an occasional active cathartic.

SIMPLE CHRONIC CATARRHAL (DIFFUSE) LARYNGITIS.

Pathology.—The pathological changes are varied, depending upon the primary cause of the affection. Hyperemia is constant, and is associated with variations in the thickening (hyperplasia) of the mucous membrane and submucosa. When the process is continuous and the inflammatory changes slow, there is a gradual proliferation of exudate into the submucosa and involvement of the glandular and connective tissue. In other cases there is engorgement and final dilatation of the blood-vessels, which causes sufficient perivascular pressure to produce thickening in the mucosa. In many cases the thickening is slight, although it may be quite general throughout the larynx. Certain locations, chiefly the interarytenoid space and the vocal cords, are the seat of congestion and thickening. The cords lose their distinct outlines and lustre, and become thickened

and of pinkish or decidedly red color, traversed by a network of dilated superficial vessels (Fig. 505). The interarytenoid space, ventricular bands, and rarely the cords become the seat of extensive submucous infiltration, which gradually encroaches upon the epithelium, producing roughness and induration. In a limited proportion of cases the infiltration extends even beyond the submucosa into the muscles, causing loss of motion of one or both vocal cords.

Local Treatment.—The topical application of remedial agents is accomplished by means of sprays, injections (Fig. 500), inhalations (Fig. 504), direct applications with the cotton carrier (Fig. 438), and insufflations. With our modern armamentarium these are applied for cleansing, astringent, stimulating, sedative, and tonic purposes. Each treatment should be inaugurated by cleansing the membranes of all secretions. For this purpose a detergent spray solution consisting of sodium bicarbonate, potassium bicarbonate, each 10 grains to the ounce of water, or a normal salt solution, or the inhalations of steam, may be employed. The spray tip must

Fig. 505.—Inflamed and thickened vocal cords.

have a downward curve at right angles, and be carried well back behind the epiglottis before the pressure is applied.

It is true that the spray solution as ordinarily used is largely condensed upon the pharyngeal walls, but, when thrown directly into the larynx by drawing the tongue forward, a small portion of the solution enters.

Mild astringent solutions, like chlorid of zinc, 15 to 30 grs. to the ounce, sulphate of copper, 5 to 20 grs. to the ounce, perchlorid of iron, 30 to 90 grs. to the ounce, may be applied by cotton applicator. Nitrate of silver, 10 to 60 grs. to the ounce, may be used in the same manner. Perchlorid of iron and nitrate of silver often cause distressing laryngeal spasm. To relieve the spasm the patient should be instructed to give a succession of short coughs. To avoid laryngeal spasm a preliminary applicaton of a 4 per cent. solution of cocaine should be made and the surplus solution should be carefully squeezed out of the cotton before introducing it into the larynx. Laryngeal irritation and cough are greatly relieved by the intratracheal injections heretofore recommended for acute laryngitis (Chapter XLVIII).

Two or three treatments weekly by the surgeon are necessary for the purpose of inspection and the application of suitable local measures of treatment. Ichthyol locally applied in the following formula, after thorough cleansing, has given excellent results on account of its stimulating and somewhat astringent qualities:—

℞ Ichthyol,
Glycerini .....āā ʒij.
Aquæ .....q. s. ad ℥j.

The author's laryngeal applicator (Fig. 438) is made of silver, the distal end being sufficiently flexible to admit of being shaped to suit the individual case. It is important to wet the tip and to wind the cotton well up from the tip in order to prevent slipping, while at the distal end it should be loose and brush-shaped. In case the trachea also is involved the method of treatment by intratracheal injections is most efficacious.

It is sometimes necessary to train patients to submit to this treatment, and for two or three times a previous application of cocaine may be necessary. The more slowly the solution is injected and the deeper the inhalations, with wide-open cords, the more thorough the application will be. Some burning and cough immediately follow, but the ultimate relief is often magical.

In cases of paralysis of the muscles resulting from deep-seated infiltration the faradic or high-frequency current may be employed with benefit.

CHRONIC SUBGLOTTIC LARYNGITIS.

In this variety there is infiltration in the subglottic tissues, often accompanied by hoarseness and dyspnea. The swelling undoubtedly results from simple chronic inflammation, which should not be confounded with rhinoscleroma, tuberculosis, syphilis or malignancy.

Pathology.—The pathological changes consist of inflammatory hyperplastic thickening in the subglottic mucosa. The infiltration is usually deep-seated, and the affection often occurs as a complication of chronic hyperplastic laryngitis.

Symptoms.—The ordinary symptoms of chronic laryngitis are supplemented by serious dyspnea and marked impairment of the voice. The latter becomes muffled and aphonic. Effort to dislodge the secretion is best described as a single, short, barking, metallic cough, similar to that observed in aneurism or tumor compression upon the trachea. The dyspnea is often sufficiently profound to induce all the phenomena of impending suffocation.

Examination of the larynx reveals the oval masses below the cords, which encroach upon the lumen of the glottis. During phonation the cords do not fully respond, either in motion, vibration or approximation. The infiltration is softer than in rhinoscleroma (Chapter XXXII), a rare disease which usually affects the nasal cavities as well as the larynx. The exact nature of the swelling may remain indeterminable until a microscopic examination has been made.

Prognosis.—The prognosis is more grave than in other forms of diffuse laryngitis. The hoarseness remains permanent, even though the swellings partially subside or are removed, and the alarming dyspnea may necessitate tracheotomy at any moment.

Treatment.—Authors very generally recommend the liberal administration of iodid of potassium, in doses of from 10 to 20

grains, three times a day, as the most effective absorbent. The dosage should depend upon the patient's ability to take this drug. If a tonic is required the syrup of the iodid of iron freshly made, in doses of from 10 to 30 minims, thrice daily, is beneficial. Caustics are of doubtful benefit, but applications of a 50 per cent. solution of lactic acid, of trichloracetic acid, or of nitrate of silver, 30 to 60 grs. to the ounce, when carefully made, may reduce the area of swelling. Great caution should be exercised, when applying caustics or the galvanocautery, not to touch the surrounding tissues, and it should be remembered that their use may be followed by reactionary swelling and edema sufficient to cause suffocation. It is usually necessary to train the larynx at repeated sittings by introducing various instruments, in order to accustom this sensitive organ to manipulation, and always under cocaine anesthesia. Tuerck's concealed applicator for applying caustics is the safer method. Crystals of nitrate of silver or chromic acid fused upon this applicator are among the safest cauterants to be applied, the caustic being concealed until the growth has been reached.

In case of impending suffocation, or when permanent stenosis has taken place, intubation or tracheotomy becomes imperative. Of these the intubation tube is more comfortable and less conspicuous. Furthermore, in rare instances, the pressure exerted by the tube produces permanent recession and absorption of the growth. As a rule, however, a tracheotomy tube or intubation tube, when once introduced, must be worn for life.

PACHYDERMIA LARYNGIS.

Advanced cases of chronic laryngitis sometimes undergo peculiar pathological changes in certain limited areas of the laryngeal mucosa, which give rise to a condition known as *pachydermia laryngis*. The special characteristics of pachydermia laryngis consist of changes in the epithelium from the normal to the stratified variety. During this process the superficial epithelial cells become the seat of keratinous deposits. The excrescences thus formed are indurated and nodular, and they appear upon the vocal cords or interarytenoid spaces. It is more common in males, and occurs in middle adult life. It is commonly found in chronic alcoholics, smokers, hucksters, and sometimes in those who strain the voice or speak for long periods in a vitiated atmosphere, or who are obliged to inhale irritating gases or dust for long periods.

Symptoms.—The chief symptom is hoarseness. Dyspnea is never severe. On the vocal cords the small nodules appear as indurated conical excrescences, and there is usually a corresponding depression upon the opposite cord. In the interarytenoid space the excrescence is more variable in size, shape and thickness.

The disease should be differentiated from singers' nodes (Fig. 506), which are softer, more superficial and unaccompanied by induration of the deeper structures. The crust formations of laryngitis sicca are darker colored and easily removed.

Treatment.—Faulty habits must be abandoned, the chronic laryngitis must receive due attention (see Treatment of Simple Acute Laryngitis), and the hygienic surroundings must be improved. Removal of the growths may be attempted whenever they are accessible. Likewise, cauterants (chromic acid, trichloracetic acid, etc.) may be employed.

Unfortunately, recurrence is common. Complete rest of the voice for a long period is most beneficial.

CHORDITIS NODOSA.

Synonyms.—Singers' nodules; trachoma of the vocal cords; chorditis tuberosa.

Chorditis nodosa, or singers' nodules, is a form of chronic laryngitis which is characterized by the formation of one or more new epithelial growths (nodules) upon the free border of the vocal cord. The favorite location for these growths is at the junc-

Fig. 506.—Singers' nodules upon the vocal cords.

tion of the middle and anterior thirds. The nodules are small, oval-shaped, and occur either singly or multiple.

Etiology.—It is generally conceded that nodules occur in individuals who are victims of long-continued laryngitis, and who at the same time have used faulty methods of voice production. Hence, singers and public speakers, hucksters, etc., are peculiarly liable to this affection. Miller claims that the majority of singers' nodes are due to chronic lacunar tonsillitis.

Pathology.—The nodes are composed of stratified epithelium. They generally appear upon the free edge of the cord (Fig. 506), and are rarely larger than a small bead. They are pinkish white in color. The surrounding superficial area of mucosa is usually the seat of congestion.

Symptoms.—The characteristic symptom of this affection is impairment of voice and especially a loss of voice control. This is illustrated by inability to "strike" certain notes and to sustain tones. There is also a tendency for the voice to "crack" or "break" during sustained vocalization.

Upon examination with the laryngeal mirror (Fig. 23) or the pharyngoscope (Fig. 501) the small characteristic pinkish nodules projecting from the free border of the vocal cord are observed (Fig. 506). When two or more nodes are present the mobility of the cords may be slightly impaired.

Prognosis.—In patients who are willing to submit to a prolonged rest of the voice and then to acquire correct methods of voice production the prognosis is favorable.

Treatment.—The treatment described above for simple chronic laryngitis should be adopted. When the nodules are of small size and recent development they usually disappear in response to a prolonged period of complete rest of the voice. Nodules of larger size should be surgically removed. They are removed intralaryngeally under cocaine anesthesia. The laryngeal forceps (Fig. 507) is an ideal instrument for the removal of singers' nodules. Grant's laryngeal forceps (Fig. 508) also are useful and safe for this purpose.

The nodules are prone to reappear after removal, particularly if the patient persists in the misuse of his voice. The denuded

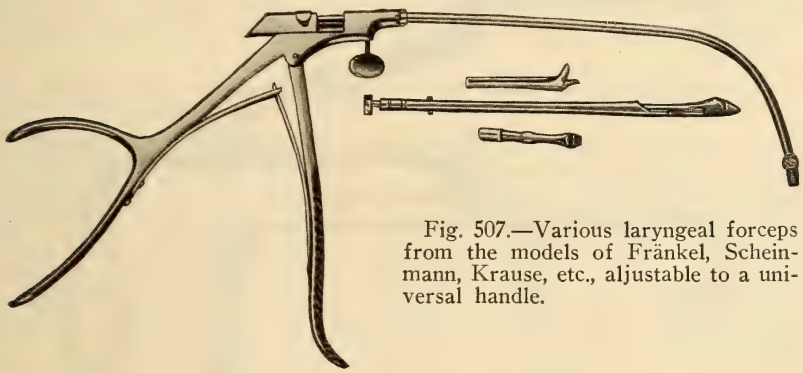

Fig. 507.—Various laryngeal forceps from the models of Fränkel, Scheinmann, Krause, etc., aljustable to a universal handle.

surface should be treated daily with a 25 per cent. solution of argyrol or a 3 per cent. solution of chlorid of zinc until healed.

The vocal exercises devised by Curtis and the manipulations recommended by Miller produce excellent results.

2. CHRONIC ATROPHIC LARYNGITIS.

Synonyms.—Laryngitis sicca; dry laryngitis; ozæna laryngis.

The term *laryngitis sicca* signifies a symptom, the characteristic feature of which is the accumulation and retention of inspissated secretions in the larynx.

Etiology and Pathology.—The etiology and pathology are precisely the same as in atrophic rhinitis (Chapter XXXIV), of which it is usually a secondary development. The affection is less common in the larynx than in the nasal cavities. The fetid form is invariably secondary to that of fetid rhinitis. This affection is aggravated by enforced mouth-breathing, and anemia is a common and persistent accompanying condition.

Symptoms.—The chief symptom is the accumulation of masses of inspissated crusts within the larynx. Hoarseness and even aphonia are present, especially in the morning, persisting until the

crusts are expelled. There is an irritating sensation of dryness in the larynx, which the patient endeavors to relieve by violent hawking efforts, which often induce strangling and slight hemorrhage. The discomfort is aggravated by public speaking or singing. In the fetid variety there is a carrion-like stench to the breath. In all cases there is diminished secretion. Similar crusty formations are usually found in the pharynx, nose and trachea. Pain is absent except during attacks of acute inflammation.

Diagnosis.—The diagnosis is never difficult, and is based upon the characteristic accumulation and retention of inspissated secretion.

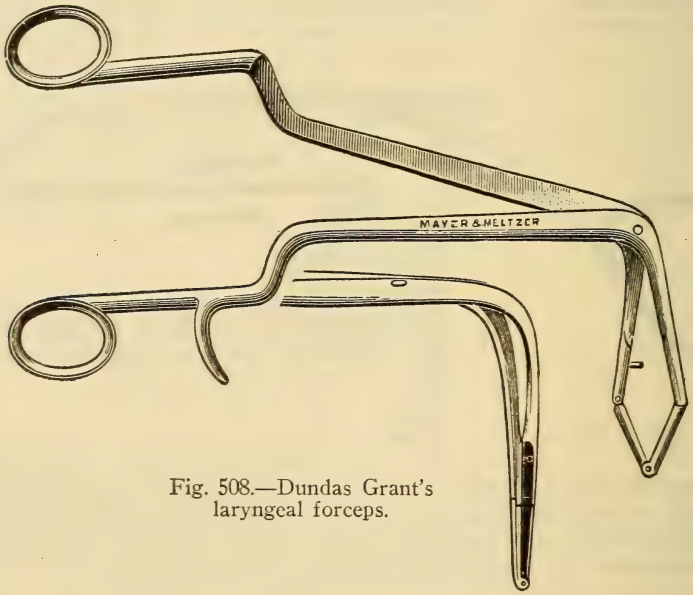

Fig. 508.—Dundas Grant's laryngeal forceps.

Prognosis.—The disease is very chronic, but when correctly treated for long periods of time the persistent accumulation of crusts may be arrested, especially when the atrophy and glandular destruction is limited.

Treatment.—Attention should first be directed to the treatment of the nose and nasopharynx already described, and especially to that of chronic purulent affections of the nasal accessory sinuses, together with such general treatment as the individual case may require. The anemia is indicative of impoverished blood resulting from some systemic infection or lack of proper oxygenation. Proper hygienic measures, therefore, should be inaugurated. Outdoor exercise, full but simple diet, and tonics are essential. The disease, except in advanced cases, is usually less marked in the larynx than in the nose and pharynx. Proper treatment of the latter favorably influences the laryngeal condition. In the simple form there is usually considerable inflammation of the mucosa and the disease occurs in

those who use alcohol or tobacco to excess, or who live in dust- and smoke-laden atmospheres. Obviously, these pernicious habits should be abandoned, and if possible the occupation changed.

Removal of the crusts is hastened by sprays of non-irritating alkaline solutions. It is often necessary to make use of the cotton-tipped probe in dislodging crusts, a procedure which many patients tolerate after a period of training. After removal of the crusts the membrane should be thoroughly swabbed with ichthyol, 25 per cent., or Mandl's solution No. 2 (page 518). The intratracheal injections of the medicated oily solutions described above are ideal applications for this affection. Steam inhalations impregnated with camphomenthol, 2 per cent., when the membranes are inflamed and engorged, are soothing. In the fetid variety the cleansed intralaryngeal surfaces should be swabbed daily with the ichthyol solution. It is important to remove all the crusts at least once a day for a prolonged period, especially in the fetid variety, and only by so doing is it possible to insure success.

3. CHRONIC PERICHONDRITIS AND CHONDRITIS.

Etiology.—Inflammation of the cartilages of the larynx does not occur as a primary affection. The disease is induced by infection from stab wounds or other traumatisms of the larynx, from tuberculosis, syphilis or cancer, from the pressure of intubation tubes, and occasionally as a sequela of typhoid fever and diphtheria. The superficial swelling and edema often obscure the deep-seated inflammation until ulceration takes place, at which time the probe will reveal exposed cartilage. In the milder forms no ulceration takes place, but instead there is an unusual development of new connective tissue which gives rise to much thickening.

Symptoms.—The symptoms are ushered in by gradually increasing swelling, pain and tenderness about the larynx, with dyspnea which is proportionate to the amount of infiltration, and obstruction to respiration. In case abscess forms there will be no relief until the cavity has been evacuated. Large abscesses are liable to encroach both upon the larynx and esophagus, thereby inducing dyspnea and dysphagia. The temperature is dependent upon the gravity of the infection. When the abscess empties into the larynx it is followed by a profuse expectoration of pus, which is sometimes tinged with blood. Burrowing abscesses may point at some adjacent area of the neck.

Diagnosis.—Examination under cocaine anesthesia is necessary, and during the early stages it is often impossible to make an accurate diagnosis. The history of syphilis or tuberculosis is confirmatory evidence. When a foreign body is suspected a radiograph should be made. There is usually some displacement of the laryngeal structures.

Prognosis.—The prognosis depends upon the underlying cause. In cancer and tuberculosis it is always grave and a fatal issue may be expected.

Treatment.—The treatment depends upon the cause of the disease. When due to syphilis, iodid of potash and mercurial

inunctions must be vigorously employed. When due to cancer or tuberculosis the etiology of the disease must be considered. Surgical removal of cancer is the only hope, and this is slight in extrinsic cases with lymphatic involvement. When of tuberculous origin both local and general measures (see Chapter XXIX) are to be employed. Foreign bodies should invariably be removed, the method of operating to depend upon the location and size of the impacted object. Direct laryngoscopy (Chapter LIII) is an effective method for removing foreign bodies from the larynx.

In suppurative cases the pus should be relieved by incision. If the abscess points outward external incision may be made. The danger of suffocation from the sudden flow of pus into the larynx following intralaryngeal incision may be obviated by immediately bending the patient's head and body forward and downward so that the pus will flow freely from the mouth. Alarming dyspnea at any time during the course of the disease may require immediate tracheotomy.

4. CHRONIC ANKYLOSIS OF THE CRICOARYTENOID JOINT.

In this affection the fixation of the cricoarytenoid joint may be partial or complete. It occurs as a result of purulent inflammation of the perichondrium of the cartilages, from tertiary syphilis, tuberculous and malignant affections, and from the deposits of gout and rheumatism.

Aphonia is the chief symptom and the diagnosis is not difficult except when the condition is accompanied with marked temporary swelling or edema. Partial or complete fixation of the cartilage is the basis for diagnosis.

The affection is not dangerous to life except when bilateral fixation in the median line occurs. This requires the permanent wearing of a tracheotomy or intubation tube.

Treatment. — Local treatment is of no avail except as a preventive measure. The voice impairment remains permanent. Cicatricial bands may be cut away, and if stenosis ensues intubation or tracheotomy may become necessary.

5. LARYNGEAL STENOSIS.

The treatment of laryngeal stenosis has been fully described under the various headings of acute septic perichondritis, chronic perichondritis, ankylosis of the cricoarytenoid joint, acute edematous laryngitis, membranous laryngitis, and enlarged upon in the general chapter on syphilis (Chapter XXX). A few additional statements are necessary to complete the subject.

Stenosis is sometimes congenital in the form of webs which extend from one vocal cord to the other (Fig. 286), generally in the posterior portion. It is also observed as a result of bilateral abductor paralysis when complete (Fig. 514), inasmuch as this unfortunate condition shuts off the lumen of the larynx. All other

forms are due to cicatricial contractions, adhesions, acute edematous inflammation, or new growths within or without the larynx. Constrictions due to webs may be relieved by cutting or dilating. Permanent relief is sometimes obtained by intubation.

6. FOREIGN BODIES IN THE LARYNX.

Small substances of various kinds may enter the larynx. Many objects become impacted in the recesses of the larynx, while others pass on into the trachea or bronchi.

They consist of fishbones, bone splinters, nutshells, needles, splinters of wood, corns, fruit pits, dental plates, pins (Fig. 566), tacks, collar buttons and other metallic objects. As a rule the accidental entrance of a foreign body into the larynx results from the pernicious habit of holding things in the mouth. The sudden inspiration which is the forerunner of a sneeze or paroxysm of coughing or laughing draws the object directly into the lumen of the larynx.

Treatment.—Fortunately, in the majority of cases, the patient, by means of a sudden and forcible cough, succeeds in ejecting the substance from the larynx. In a small percentage of cases, especially children, by holding the patient head downward and administering a sharp slap upon the back, the foreign body is dislodged and ejected.

Two surgical methods are employed for removing foreign bodies from the larynx, viz., the indirect and the direct.

The indirect method requires suitable laryngeal grasping forceps (Fig. 507) and excellent reflected light. Complete cocaine anesthesia is necessary. This method is applicable to adults and older children who are tractable.

The direct method is fully described in the chapter on direct laryngoscopy, etc. (Chapter LIII).

7. PROLAPSE OF THE VENTRICLE.

Prolapse of the ventricle of Morgagni, otherwise known as the saculus laryngis, into the lumen of the larynx is a rare affection. Kyle describes it as a separation of the membranous covering of the ventricle from its attachment, as a result of which it protrudes into the lumen of the larynx.

Watson Williams has advanced the more probable theory that prolapse of the membrane alone never occurs, but that a true infiltration of the underlying tissues forces the membrane from its normal position.

This affection is caused by tumors of various kinds, but more especially syphilis, tuberculosis and malignant growths. The prolapse may also be caused by pressure from abscesses or aneurisms. Aside from the symptoms which characterize the particular underlying disease the patient complains of aphonia and dyspnea. The treatment should be directed to the primary lesion.

Tuberculosis of the larynx, lupus of the larynx and syphilis of the larynx are respectively discussed in Chapters XXIX and XXX.

CHAPTER L.

NEOPLASMS OF THE LARYNX.

THE larynx may be the seat of both benign and malignant neoplasms.

1. BENIGN NEOPLASMS.

The following benign tumors may appear in the larynx, viz., papillomata, fibromata, cystomata, angiomata, lipomata, myxomata, singers' nodules (see page 774) and chondromata. Of these the papillomata, fibromata and cystomata are of the most frequent occurrence.

Etiology.—The exciting cause of benign neoplasms of the larynx is not definitely known, but authorities generally agree that long-continued laryngeal irritation and inflammation are potent predisposing causes. According to Semon, they are more common in Germany and France than in England and the United States. They are more common in males than in females, and, with the exception of multiple papillomata, which often occur in young children, they develop in adult life. Benign neoplasms are comparatively common in hucksters, "barkers," singers and public speakers. Moritz Schmidt[1] furnishes the following statistics regarding the frequency of laryngeal neoplasms, the cases tabulated being taken from a series of 32,997 patients treated in his clinic and covering a period of ten years:—

	MEN.	WOMEN.	CASES.
Fibroma	178	78	256
Papilloma	31	15	46
Singers' nodules	56	53	109
Lipoma	1	0	1
Myxoma	3	0	3
Fibromyxoma	1	0	1
Tuberculous tumors	14	22	36
Cysts	2	6	8
Sarcoma	3	0	3
Carcinoma	61	15	76
Tracheal carcinoma	1	1	2

Pathology. *Papillomata.*—These warty growths are of various size and extent, and are pedunculated, sessile or diffuse. They are usually attached to the vocal cords, occasionally to the ventricular bands, and rarely to other portions of the larynx. They are made up of connective tissue interspersed with round cells and covered with a massed layer of stratified epithelium. The color is pale pink with rough and uneven surfaces (Fig. 509).

Fibromata.—Fibromata usually occur singly. The form is oval, the surface even and the color pink. They are made up of rather

[1] New Growths of the Upper Air Passages.

dense connective tissue covered by a thin epithelial layer. They are attached to the vocal cords by a broad base, being rarely pedunculated.

Cystomata.—Cysts usually result from the retention of mucus in mucus-secreting glands the mouths of which have become sealed. They vary in size and on puncture are found to contain fluid mucus. They are attached about the epiglottis, aryepiglottic folds, or protrude from the ventricles. Tubercle bacilli and giant cells have been found in the cyst contents.

Angiomata.—Angiomata are vascular tumors with a broad base. They are usually located about the epiglottis or the ventricular bands.

Lipomata.—These are lobulated, fatty tumors, yellowish in color, with broad bases, usually arising from the aryepiglottic folds.

Myxomata.—These are smooth, bulbous, semitranslucent masses springing singly from the vocal cords. Structurally they are similar to nasal polypi, although somewhat denser.

Chondromata.—Chondromata are irregular, broad-based masses, largely made up of hyaline cartilage cells, and are usually attached to the cricoid cartilage, but in rare instances they spring from the thyroid, the epiglottis or the arytenoid cartilages.

Symptoms.—Impairment of voice, laryngeal irritation and dyspnea are the chief symptoms induced by benign growths in the larynx. Small tumors give rise merely to slight irritation and hoarseness. As they increase in size aphonia may develop, and when the growth encroaches upon the lumen of the larynx respiration becomes impeded, until, finally, alarming dyspnea may necessitate the removal by operation or relief by resort to intubation or tracheotomy.

Young children with multiple papillomata, and adults with either large papillomata or chondromata are especially liable to experience serious dyspnea. Pain is rare. Hemorrhage may be expected in angiomata. Cough is neither constant nor severe except in young children with multiple papillomata. Hemorrhage, dysphagia and pain are remote symptoms.

Diagnosis.—Remembering the clinical picture described in the pathology, the laryngoscopic examination (Figs. 22 and 501) will usually establish a clinical diagnosis. Some difficulty occasionally is experienced in differentiating fibromata, myxomata and lipomata. Malignant growths during the incipient stage are sometimes mistaken for those of benign nature. Benign growths are usually painless, non-ulcerating, and are unaccompanied by swelling, infiltration or fixation of the cartilages. The converse obtains in malignancy, and lymphatic gland enlargement develops early. Microscopic examination may become necessary to establish a definite diagnosis.

Prognosis.—The prognosis is good so far as life is concerned, except in children with multiple papillomata, which renders them susceptible to fatal dyspnea and pulmonary complications. The voice may recover whenever it is possible to remove the growth without injury to the vocal cords. Recurrent multiple papillomata, even though finally cured, usually result in permanent impairment of the voice. In young children and sometimes in adults multiple

papillomata persist indefinitely, and eventuate in contractions and permanent stenosis.

Treatment.—The employment of caustics, the galvanocautery, or rough rubbing with harsh substances, such as dry sponges, is open to the criticism that their use is attended with danger of serious injury to the surrounding tissues and of severe inflammatory reaction; moreover, these measures rarely succeed in destroying the tumor. Spraying the larynx with absolute alcohol five or six times a day has been advocated for the destruction of small papillomatous growths.

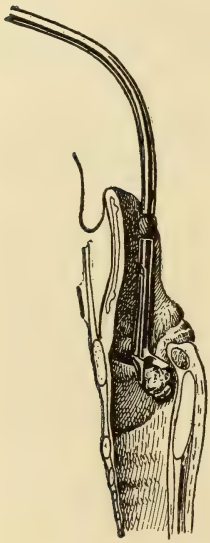

Fig. 509.—The laryngeal forceps in position for severing a papilloma from the vocal cord.

Benign tumors within the larynx, even though of small size, and apparently stationary, should always be removed, inasmuch as sooner or later they become sufficiently enlarged to interfere with phonation.

There are three general methods for the removal of benign growths: 1. By means of forceps or snare through the mouth. This requires the use of the laryngeal mirror, with reflected illumination. This method has already been described as the intralaryngeal operation, or indirect laryngoscopy. 2. By direct laryngoscopy by means of the Jackson or Killian tubular speculum (Chapter LIII). 3. By the extralaryngeal method (thyrotomy or tracheotomy).

The first method (indirect laryngoscopy), long in use, in favorable cases possesses many advantages. The patient or an assistant is instructed to grasp the protruded tongue with a napkin, holding it firmly between the thumb and the index finger. The operator should hold the laryngeal mirror in place with the left hand, thus bringing the laryngeal picture well into view (Fig. 22). He now is able to guide a suitable instrument, preferably a curved laryngeal forceps (Fig. 507), into the larynx and to grasp the growth (Fig. 509).

Local anesthesia, both of the pharynx and the larynx, should be complete. In the pharynx a 4 per cent. solution of cocaine sprayed or swabbed over the mucosa will suffice, but a 10 to 20 per cent. solution of cocaine is usually required in order to overcome the spasm of the larynx which is induced by instrumentation. Nervous patients often require considerable training of the larynx at repeated sittings before submitting to the operation.

The difficulties and dangers are: 1, lack of self-control and adaptability on the part of the patient; 2, the wounding or tearing of surrounding tissues by the operator.

Direct Laryngoscopy.—This method is fully described in Chapter LIII. It is comparatively a simple and effective procedure.

In adults the removal of benign growths from the larynx can usually be accomplished under local anesthesia, with the patient in the sitting posture. In young children or in adults who are unable to flex the head backward on account of excessive fat, rheumatism, gout or some other affection of the neck, the recumbent position is necessary.

Whichever position is used, the tubular speculum (Fig. 553) should be used and the entire larynx, including the vocal cords, brought into view. It is then a simple procedure to introduce the forceps (Fig. 556) and grasp the tumor.

Tracheotomy.—Of the endolaryngeal operations tracheotomy (see Chapter XXXI) is usually performed for the relief of dyspnea. High tracheotomy, however, enables the operator to remove small subglottic growths through the tracheal opening.

Thyrotomy.—Thyrotomy, hereinafter described, is the method most commonly employed. This procedure completely exposes the growths and permits the requisite surgical measures.

Subhyoid Pharyngotomy.—Subhyoid pharyngotomy is less effective. All extralaryngeal operations subject the patient to considerable danger of pulmonary complications. Until the advent of direct laryngoscopy, extralaryngeal operations have been necessary in adults for the removal of multiple papillomata, and in young children for the removal of large subglottic growths, especially when sessile.

In the removal of angiomata there is considerable danger of hemorrhage, and, unless so located that continuous pressure may be applied for some time, the growth should be destroyed either by repeated cauterizations with the electrocautery, or by electrolysis.

The removal of chondromata usually requires a thyrotomy and the complete removal not only of the tumor, but also of the cartilage from which it arises.

In the removal of cysts it is necessary to destroy or cut away a large proportion of the walls; otherwise there will be a reaccumulation of the fluid.

After-treatment.—Whether the entire tumor or a portion only is removed, the base or attachment should be rubbed with a 50 per cent. solution of lactic acid, and subsequently the larynx should be sprayed daily with the medicated oily solutions, or intralaryngeal injections (see Chapter XLVIII). Finally, the larynx should be inspected at intervals until complete healing has taken place.

2. MALIGNANT NEOPLASMS.

Carcinomata, usually of the epithelial type, and sarcomata occur primarily in the larynx. The former is far more common. In Zeimssen's report of 68 cases of malignant neoplasms of the larynx, 57 were carcinomata. Sarcoma is more likely to occur in younger subjects, while carcinoma of the larynx rarely occurs under 40 years of age.

Pathology.—Malignant laryngeal growths are defined as intrinsic when the tumor has remained entirely within the laryngeal box, and extrinsic in cases wherein the growth has extended beyond the confines of the larynx. The vulnerable avenues of extension are backward toward the esophagus and less commonly upwards toward the epiglottis and lateral hypopharynx. The disease rarely tends to extend primarily through the cartilaginous walls into the tissues of the neck. Carcinoma occurs in the following order of frequency: 1, vocal cords; 2, ventricular bands; 3, posterior laryngeal walls; and 4, ventricles. The disease develops slowly and secondary glandular involvement appears late. Carcinoma of the larynx is primarily unilateral, the first appearance being a congested or slightly nodulated area with slight thickening, followed by a real elevation of fibromatous appearance which in turn ulcerates. Infiltration and thickening of the surrounding tissues follow and the typical appearance of malignancy—the infiltrated areas, ulcerated center and cauliflower excrescence—completes the clinical picture. When the growth has become extrinsic, particularly if the glands of the neck have become involved, the subsequent development is extremely rapid to a fatal termination.

Symptoms.—The one outstanding initial symptom is hoarseness, mild at the commencement but steadily progressive until the voice becomes aphonic. Continuous hoarseness appearing in individuals after the fortieth year should invariably be regarded with suspicion and a careful visual inspection of the larynx should be repeatedly insisted on until a diagnosis is reached.

As a rule the location of the tumor, even though extremely small, can be seen with the laryngeal mirror. Loss of motility of the affected cord is almost a pathognomonic symptom of cancer. This is due to fixation of the musculature by infiltration. No case of primary involvement of the interarytenoid space has been reported. Twice in the author's experience he has been able to make a diagnosis of epithelioma of the vocal cord so early that less than one-third of its length had become involved. The hoarseness is peculiar and unlike that of ordinary laryngitis. Soon after the development of ulceration more or less tenderness on pressure appears over the larynx. Dyspnea is a late symptom and is a result of edema or of the encroachment of the growth upon the lumen of the larynx. Ulceration marks the appearance of secretion, to dislodge which the patient is obliged to cough and hawk. These efforts produce more or less pain which radiates to the tonsil and to the ear. The secretions are usually offensive and the breath odorous. In the later stages the expectoration becomes muco-purulent and often hemorrhagic. Dysphagia is a late symptom and extension of the growth to the laryngeal cartilages results in necrosis and severe pain. Cachexia develops late and after secondary involvement has appeared. Occasionally an epithelioma which has arisen outside the larynx invades this space, in which event extension and ulceration rapidly ensue. During the

final stages portions of necrosed cartilage may become detached and expectorated. At this time tracheotomy may become necessary in order to relieve an alarming dyspnea.

Diagnosis.—Early diagnosis is of the utmost importance and is often attended with much difficulty. In intrinsic cases, particularly those of limited area, it is possible to effect a complete and permanent cure by means of radical surgical removal, as hereinafter described. In 1896 the author reported a case of primary epithelioma of the left vocal cord, in a clergyman 66 years of age, in whom the clinical diagnosis was fibroma. The mass was removed with Schrötter's tube forceps under cocaine anesthesia. The entire diseased area covered less than one-half of the entire

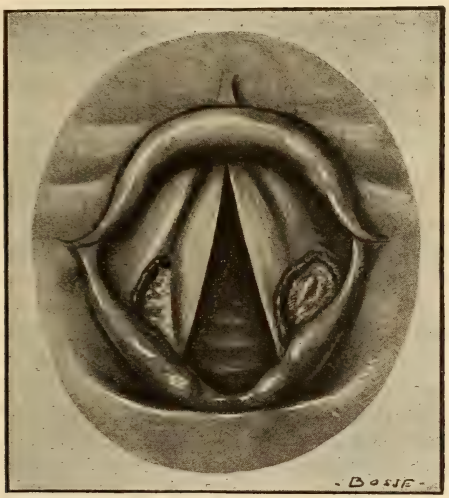

Fig. 510.—Tuberculous ulceration of the larynx.

vocal cord. The tumor was examined microscopically and was found to be an epithelioma. A hemilaryngectomy was immediately performed and the patient recovered with sufficient voice to enable him to fulfill the duties of his pastorate for fourteen years. In this case the early diagnosis and prompt operation rendered it possible to greatly prolong the patient's life. Laboratory examination of all growths removed from the larynx, even when considered benign, is a wise precaution. Intrinsic cancer during the early stages is not readily differentiated from innocent growths, syphilis, or tuberculosis. Suspension laryngoscopy and the bronchoscope (see Chapters LII and LIII) are of extreme value as aids to diagnosis in that they enable the examiner more fully to outline the location, size and extent of the growth. Barring the rare fulminating malignancies which sometimes invade these areas, all laryngeal cancers are entirely local in character.

Tuberculous ulceration (Fig. 510) is usually a late complication of a general tuberculosis and the tubercle bacilli are always

present. The differentiation of syphilis is more difficult and a Wassermann test or a short course of mixed treatment may be required. Antisyphilitic treatment has no effect on malignancy. Aside from these diseases the clinical history, the visual examination of the larynx and the microscope usually furnish sufficient data to establish a diagnosis. If possible, the diagnosis should be based on the history and appearance of the growth and by excluding syphilis and laryngeal tuberculosis. In no instance should a section of a malignant growth of the larynx be removed for pathological confirmation unless all arrangements have been previously made for immediate radical operative procedure.

The author would emphasize two definite conclusions: 1, that early diagnosis and complete surgical removal, as hereinafter described, will effect a permanent cure in practically every case of early intrinsic cancer; 2, that in extrinsic cancer of the larynx no permanent results may be expected from any operative interference.

Prognosis.—During recent years a more hopeful outlook has arisen regarding operations for intrinsic cancer of the larynx. With improved technique and a more careful selection of cases results have been attained which compare more than favorably with similar procedures in other parts of the body. The primary difficulties arise from slowness in rendering a diagnosis. This tardiness is due chiefly to the hidden position of the interior of the larynx. Inexperience on the part of the general profession and the fact that a large proportion of general practitioners of medicine never employ the laryngeal mirror, together with a lack of knowledge of the early manifestations of cancer of the larynx, are the chief obstacles to the early diagnosis which is so important from the standpoint of cure. In former days the extremely high operative mortality, over 30 per cent., and a corresponding high percentage of recurrence tended to discourage all operative procedure. Likewise, inexcusable pessimism on the part of many laryngologists, probably from the same reasons, has tended to retard progress. The attendant loss of voice incident to the removal of the larynx has remained a discouraging feature even though a more complete loss of voice is bound to result during the progress of unoperated cases. Emphasis is again placed upon the most common manifestation of laryngeal cancer, namely, hoarseness coming on after the middle period of life.

The prognosis is also influenced by the fact that the interior of the larynx is to a considerable degree unassociated with the lymph channels of the neck on account of the cartilaginous walls which tend to act as barriers to the extension of the disease. An involvement of the arytenoid cartilage is an evidence of extension closely reaching the border line of the extrinsic class. Likewise it lessens the hope of permanent cure. Experience has shown that in only the most incipient and localized intrinsic cancer of the larynx should any treatment be adopted other than radical and complete laryngectomy. Both experience and statistics bear out

the assertion that secondary operations for cancer of the larynx are almost invariably fatal.

It cannot be denied that the condition of the laryngectomized patient is attended with many difficulties and discouraging features. On the other hand, however, their lives have been saved, and they are able to attend to business and social obligations with considerable cheerfulness and to manifest gratitude for deliverance from certain death. MacKenty's statistics, carefully worked out, indicate that total laryngectomy gives the greatest promise of permanent cure in intrinsic laryngeal cancer. Prior to 1916-17, out of six hemilaryngectomies performed by him, two are

Fig. 511.—The primary T-incision. (*MacKenty* operation.)

still living and four died of recurrence in from two to three years after the onset of the disease. The two surviving cases were operated upon extremely early. Out of 13 total laryngectomies performed prior to 1916-17, two diabetic patients succumbed to the operation, six were advanced intrinsic cases with involvement of one or both arytenoids, and four of the six died of recurrence, and two are still living; three were intrinsic cases without involvement of the arytenoids, and one of these cases died from recurrence, one from nephritis a year after the operation and one is still living. Out of twenty thyrotomies, eight had the growth removed leaving the cartilaginous wall; seven of these died of recurrence and one is still living; twelve were operated upon by the window resection; eight of these had recurrence and died, and four are still living. Out of 143 cases of laryngeal cancer examined since 1916, 46 cases had remained intrinsic, in that the disease was still confined to the laryngeal box. Three of these cases

were truly incipient but in 97 the disease had extended beyond the larynx, often involving the glands of the neck. Thirty-one of the 48 intrinsic cases came to operation by total laryngectomy and two by thyrotomy. On account of the improved operative technique, as hereinafter described, in these 33 cases there were no surgical mortalities. Twenty-nine were done by means of the one-stage operation and two by the two-stage method. The ages varied from 41 to 80 years and there were but two females. Primary union was secured in but five. A large defect occurred in two, requiring a subsequent plastic closing. Twenty-six of the 33 cases are still alive, with no evidence of recurrence. The oldest case

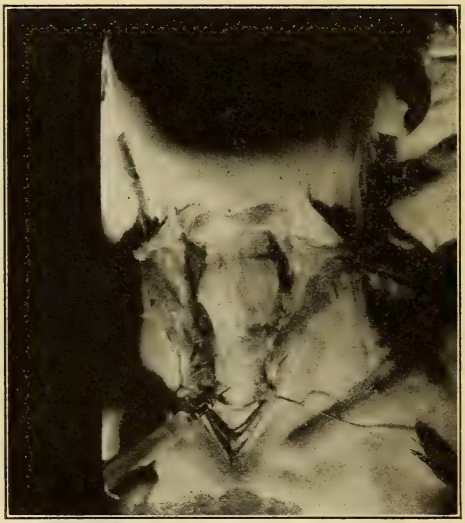

Fig. 512.—The skeletonized larynx. Also showing point for injecting the cocain solution previous to the tracheal incision. (*MacKenty* operation.)

died four years later of pneumonia; one died two years after operation from cerebral hemorrhage; one of the most hopeful died from recurrence three years after operation, and four in which the disease had extended well back toward the arytenoids succumbed to recurrence within two and one-half years after the primary operation. Should five more of MacKenty's cases eventually succumb to recurrence, there would still remain 66 per cent. of cures. Twenty-five of the last named cases eventually entirely discarded the tracheal cannula. MacKenty emphasizes the factors tending toward a favorable outcome as follows: 1, slowness of growth; 2, freedom from involvement of the posterior part of the larynx; 3, superficial growth (cancer originating in the deeper layers of the larynx may not be more malignant but it often escapes detection until well developed); 4, extension forward and downward rather than upward and backward; 5, age of the patient (cancer

in the late thirties or early forties is more malignant than in later life).

Treatment.—Surgical removal constitutes the only method of treatment which offers the slightest hope of cure, it being assumed that in extrinsic cases even surgical interference is uneffective. In extrinsic cases it is the author's belief that life is further prolonged and with no greater suffering by the employment of cleansing and palliative local applications and sufficient morphine to control pain. A tracheotomy should be performed whenever laryngeal stenosis becomes distressing. Dysphagia may be relieved by spraying the entire throat and larynx with a 2 per cent. solution of cocaine

Fig. 513.—Divided trachea. (*MacKenty* operation.)

twenty minutes before meals. In advanced cases feeding through an esophageal tube or even gastrotomy may become necessary in order to sustain life.

Surgical Procedure.—Three methods of operation have been employed depending upon the extent of the disease. Thyrotomy, partial laryngectomy, and complete laryngectomy.

THYROTOMY (LARYNGO-FISSURE).—This is the simplest, the least dangerous and usually results in less impairment of voice. Unfortunately it can rarely be employed because it is applicable only to cases where the disease is limited to an extremely small area.

Technique.—According to Butlin the steps of the operation are as follows:—

The patient is placed upon his back with the shoulders and neck elevated sufficiently to produce some tension upon the soft tissues which cover the larynx.

A median incision should then be extended from the hyoid bone above to about one inch from the sternum. Having severed the soft tissues the hemorrhage should be controlled. The trachea is then opened for the purpose of inserting a Hahns tracheotomy tube. During the interval required for the sponge to swell and thereby block the intervening space in the lumen of the larynx, the artery clamps may be released by applying ligatures.

The thyroid cartilage is then divided exactly in the median line. Considerable care should here be exercised to prevent injury to the vocal cords. By cutting from below upward and precisely following in the median line, this danger is reduced to a minimum.

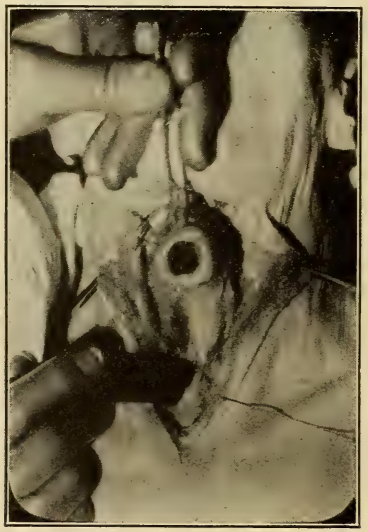

Fig. 514.—Divided trachea with large rubber tube inserted both for the purpose of preventing the entrance of blood and for the continued administration of the anesthetic. (*MacKenty* operation.)

The incision should now be extended through the cricothyroid membrane. The laryngeal incision is then spread wide open either by blunt retractors or preferably by traction from strong silk threads carried through each section of the divided cartilage. All oozing of blood should then be controlled by a temporary packing of the operating field with gauze soaked in a 1 : 2000 solution of adrenalin chloride. The growth should then be outlined and the incision extended around it at a distance of at least one-fifth of an inch from its free border.

Soft tissues included in the incision are then removed and the operation is completed by curetting the underlying cartilage and by cauterizing the area with nitric acid or the galvanocautery. The free borders of the cartilage are then coaptated and united by means of absorbable sutures and the external wound closed in

the usual manner except that the soft parts covering the tracheal wound are left open after withdrawing the Hahns tube for the purpose of quick drainage.

Partial Laryngectomy (Hemilaryngectomy).—Partial laryngectomy may be employed in the occasional early cases. MacKenty's statistics, however, show more favorable results from the more radical procedure. The initial steps in the technique are similar to those of thyrotomy. In the removal of the tumor the whole lateral half of the larynx is resected.

Complete Laryngectomy.—The technique of the complete laryngectomy as herein described follows the procedure which has

Fig. 515.—Cadaver representation of larynx divided both below and above and ready to be taken out. (*MacKenty* operation.)

proven so successful in the hands of MacKenty.[1] The surgical procedure may be divided into three stages: 1, the preparation; 2, the operation and its technique; and 3, the after-treatment.

Preparation.—The first step is to have a metabolist see that the patient is chemically balanced. If retention of sugar exists in the urine, treatment is instituted, and if unsuccessful the case is rejected for operation. Digitalization is very essential if the heart is weak. Special attention is paid to the colon; for one week preceding operation a weak carbonate of soda enema is given every other day followed by a saline colon irrigation. The diet in all cases for a week or two preceding operation must be of low protein content, excluding eggs, beef and sweet milk. Teeth that are carious and pyorrheal are extracted and the remainder cleaned by an expert dentist. Where all teeth are absent a primary union

[1] John Edmund MacKenty, New York State Medical Journal, October, 1922.

may be expected. If sinus disease exists every effort should be made to clean the nasal cavities by means of the suction douche twice daily during the period of preparation. Bicarbonate of soda should be given for a few days preceding operation.

The Operation and Its Technique.—The following surgical principles must be kept in mind: 1, anesthesia; 2, the prevention of the inhalation of blood; 3, cleansing and disinfection of the mouth, pharynx, nose, hypopharynx, and the prevention of their secretions from contaminating the wound; 4, the secure anchoring of the tracheal stump; 5, drainage; 6, method of closing the wound; 7, method of excluding the wound from the tracheal secretions; 8, the proper placing and securing of the feeding tube.

Fig. 516.—Sutured hypopharynx; also the anchoring of the tracheal stump below. (*MacKenty* operation.)

A combination of local and general anesthesia is better than either one alone; the larynx and upper two or three tracheal rings should be skeletonized under local anesthesia before the general anesthesia is given. One per cent. cocaine is used for the skin and one-fourth of 1 per cent. for the deeper structures. To this is added a very minute amount of adrenalin.

The T incision (Fig. 511) is used. The dissection is carried backward until the larynx and trachea are skeletonized (Fig. 512). When hemostasis is complete and all vessels tied the patient is given a general anesthetic. The trachea is now cut across just below the cricoid and minute care is taken that no blood enters the lumen of the tube. Before dividing the trachea a few drops of 10 per cent. cocaine solution should be injected between two rings (Fig. 512), to prevent coughing. The larynx is lifted for-

ward and the posterior wall of the trachea is incised down to the esophageal wall (Fig. 513). A rubber tube which fits snugly into the tracheal lumen is inserted into the trachea to a distance of about two inches (Fig. 514). This acts as a tracheal extension, turns back the blood, and enables the anesthetist to continue his anesthesia without being in the way.

The larynx is separated from the esophagus from below upwards to a point behind the arytenoids. It is then allowed to fall back into position (Fig. 515) and the thyro-hyoid membrane is divided opening the hypopharynx just below the attachment of the epiglottis. Before this opening is made the anesthetist or an

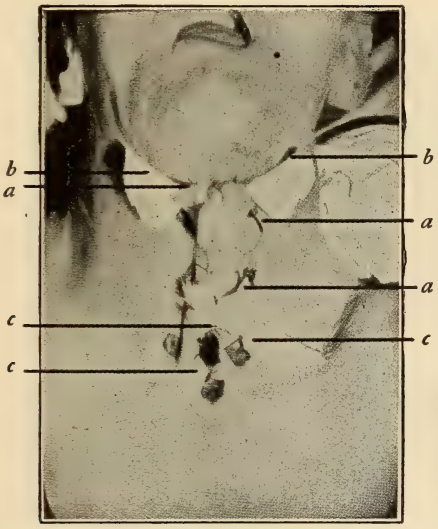

Fig. 517.—Closed external wound showing: *a*, loosely held stitches; *b*, wound freely packed at the ends of the bar of the T; *c*, small gauze drains around the anchored tracheal stump. (*MacKenty* operation.)

assistant opens the mouth wide, sucks out all secretion and paints the entire cavity, the pharynx, and the hypopharynx, with a 2 per cent. solution of mercurochrome. The nasal cavity is similarly treated. The edges of the opening through the thyro-hyoid membrane are grasped and held apart. A yard of gauze folded two inches wide is stuffed into the hypopharynx and crowded upwards until it fills the mouth and pharynx.

At this point a careful inspection is made of the growth. If it is found to be entirely intrinsic, the larynx is removed by cutting as close as possible to the superior border of the thyroid cartilage. If the disease has approached the top of the laryngeal box or has involved the arytenoid, then more tissue is sacrificed, even to the removal of the anterior esophageal wall adherent to the posterior surface of the larynx.

Just before the last stitch is tied in the closure of the hypopharynx (Fig. 516), the anesthetist removes through the mouth the gauze packing filling the mouth and pharynx. The mouth and pharynx are again cleansed by suction and again painted with a 2 per cent. solution of mercurochrome. A feeding tube (Fig. 518) of a size which will pass through the nose without undue pressure is passed through the more open side of the nose. When its point appears in the esophagus beneath the untied stitch the surgeon directs it into the esophagus to a depth of six inches. The point of exit from the nose is now carefully marked and the tube secured to the face by adhesive plaster.

Fig. 518.—Tracheal cannula and feeding tube adjusted and anchored. (*MacKenty* operation.)

The last stitch is now tied. If the redundancy of the tissues permits, a second layer of stitches is placed over the first in the hypopharyngeal closure. No. 1 plain gut is used. The trachea is anchored to the skin of the neck by two or three stay sutures, each passed around a ring and brought out about one inch from the edge of the wound. These are tied on small perforated lead discs (Fig. 516) which steadies the tracheal stump in the wound and relieves the strain upon the stitches which are to unite the skin edges with the mucous membrane of the trachea. To make this union more exact the fat along the wound edge on both sides is cut away, which allows the skin to fall more easily into relation with the edge of the tracheal stump. The skin strip and edge of the trachea are united by interrupted stitches, using fine silk—or better, fine equisitene. The external wound is loosely closed, no effort being made to bring the deeper parts into anatomical order.

It is essential to get primary union at one point and that is where the two lines of the T cross. If the integrity of this part of the wound can be maintained the subsequent healing is much more rapid and hypopharyngeal fistula does not occur. If this point breaks away, or has to be opened for the securing of better drainage, an effort should be made as early as seems prudent to again bring those angles of the T into place. Silver wire serves better here than any other suture material, since it may be left *in situ* for a long time, even in the presence of infection.

A tube and gauze drain are passed into the depth of the wound at the ends of the bar of the T (Fig. 518). Just above the point where the trachea is secured to the skin, two small gauze drains

Fig. 519.—Neck dressings protected by rubber drain. (*MacKenty* operation.)

are placed (Fig. 517), one on either side. This guards the direct route of the mediastinum. A large tracheal cannula (36) is wound with gauze impregnated with bismuth paste. The winding is so fashioned as to form a conical cork, and this is inserted into the trachea and should fit as a cork does a bottle (Fig. 518). The object of this corking the trachea is to prevent tracheal secretions from contaminating the wound from below and to turn back from the trachea any wound secretions from above. It also protects the tracheo-skin union.

The wound is dressed in the usual way (Fig. 517). A rubber apron (Fig. 519) is placed over the end of the cannula and catches all tracheal secretions. During the repair period of the operation the patient is given little or no anesthetic. Deep anesthesia is imperative only from the time the trachea is opened until the hypopharynx and esophagus are closed.

After-treatment.—The immediate treatment usual after any major operation is carried out. It is after this operation that the skill and experience of the surgeon are often taxed to and beyond their limit. Painstaking and constant care on his part personally is the only key to success. If infection occurs the surgeon must be at least one jump ahead of it; the reverse means almost certain death to the patient. Local reaction in the neck is extensive

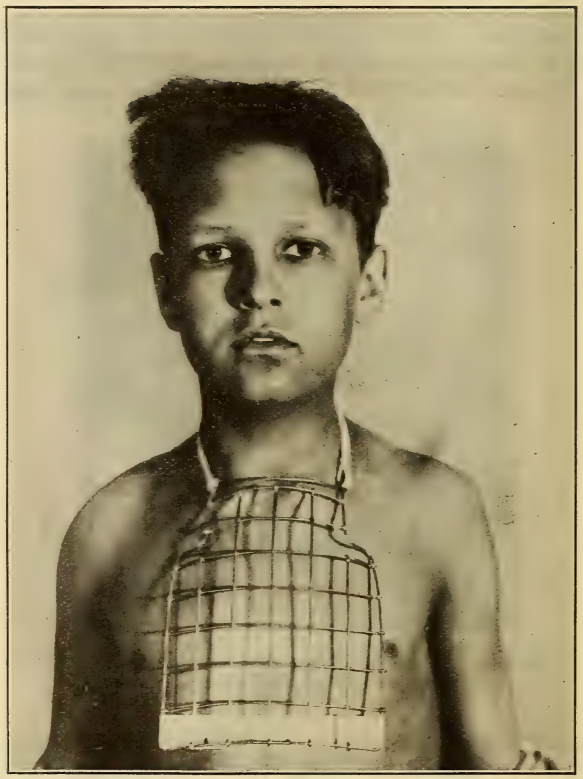

Fig. 520.—Device for breathing warm air from around the body. (*MacKenty* operation.)

and may simulate infection. If doubt exists the surgeon would do well to extend as widely as possible his drainage openings and watch for extension along the muscular planes of the neck, for if this occurs it must be followed and opened widely. Later, if pus becomes profuse and if a break takes place in the esophagus, suction to remove these secretions is of inestimable value. Tubes are placed at the bottom of the pockets and through the opening in the esophagus. These project through the dressing and the nurse applies suction to these tubes as frequently as is indicated. A 2 per cent. mercurochrome solution may be used sparingly. If

trachitis follows the operation, suction applied through a catheter unloads the trachea and prevents gravitation pneumonia. The lungs should be protected against cold dry air by a bulging wire screen worn over the tracheal opening and extending several inches down and across the chest (Fig. 520).

Dietary For Laryngeotomy Patient. Man, 150 lbs., 1900 Calories

	Grams		Carb. 115	Prot. 100	Fat 115	Vitamines	Bases	Acid Bases	NaCL
8a.m.	120	Orange Juice	12.0			(3)	4.5		.0203
	1	Egg		6.0	6.0	(1)		7.5	.302
	4 Oz.	Water				(2)			
10a.m	120	Oat Meal Gruel	7.6	1.5	.5			3.0	.114
	60	Cream, 40°/°	2.0	2.0	24.0	++(1)	.1		.0792
	120	Whole Milk	6.0	4.0	4.0	++(2) +(1) +(2)	2.0		.21
12 n.	120	Jellied Beef Soup	3.0	12.5	1.4			+	
		Butter			8.5	+++(1)			
		Gelatine, Granulated		14.1					
		(Heat and add water to make 8 oz.)							
2p.m.	120	Orange Juice	12.0			+++(3)	4.5		
	1	Egg		6.0	6.0	++(1) +++(2)		7.5	.0203
	4	Water							.302
4p.m.	120	Jellied Beef Soup	3.0	12.5	1.4			+	.0792
	60	Cream, 40°/°	2.0	2.0	24.0	++(1)			
	15	Gelatine, Granulated (Prepare as above)							
6p.m.	120	Oat Meal Gruel	7.6	1.5	.5	++(1) +(2)		3.0	.114
	120	Whole Milk	6.0	4.0	4.0	+(3)	2.6		.21
	30	Cream, 40°/°	1.0	1.0	12.0	++(1)	.1		.0396
8p.m	120	Prune Juice	20.0	1.0			25.0		.42
	2	Whites of Egg		(3.0		+		9.5	.30
		Water ad lib.		(3.0					
10p.m.	240	Whole Milk	12.0	8.0	8.0	++(1) +(2)	2.6		.42
	10	Cocoa	3.7	2.2	3.0	+(3)	.1		
2a.m.	90	Orange Juice	9.0			+++(3)	4.5		.0203
	1	White of Egg		3.0		+		9.5	.15
6a.m	120	Oat Meal Gruel	7.6	1.5	.5	++(1)		3.0	.114
	30	Cream, 40°/°	1.0	1.0	12.0		.1		.0396
		Water ad lib.							
			115.5	103.9	115.8		46.8	43.0	3.2768

IMPORTANT

That enough lean beef and bones be used in making the BEEF SOUP, so that when strained and set in the ice box, it will JELLY.

That all liquids, in the above Dietary, be carefully strained just before giving them to the patient.

---

30 grams equal 1 ounce
30 cc " " "
5 grams " 1 level teaspoonful.

For "Salt Free" Diet, use the above Dietary, omitting all salt from Soup and Gruel and using salt free Butter.

Prepared by - Ina J. Zimmer, 2/14/22

Fig. 521.—Dietary chart. (*MacKenty* operation.)

Feeding.—Much of the success to be obtained in piloting these cases across the post-operative period is due to the permanent feeding tube. Feeding to the point of toleration discourages septic infection. Feeding is begun just as soon as the anesthetic

period is over. For two days, from one-half to two-thirds the caloric requirements are given; then the amount is increased to tolerance. Any well balanced diet capable of being reduced to a fluid or semisolid may be used. (Figs. 521 and 522.) Fruit and vegetable juices are essential. Gravitation serves for ordinary liquids, and for thicker ones the piston syringe may be used. The food is very slowly introduced with the patient propped up in bed.

Feeding for Laryngectomy Patient

	Grams		Carb.	Prot.	Fats	Carb.	Prot.	Fats	Vitamines
8a.m.	120	Oat Meal Gruel	7.6	1.5	.5				++(1)
	15	Butter			12.8				++(1)
	60	Cream, 40°/°	2.0	2.0	24.0				
10a.m			9.6	3.5	37.3				
6.30 p.m		Repeated	3	3	3				
			28.8	10.5	111.9				
	1	Egg		6.0	6.0				++(1)
			28.8	16.5	117.9	28.8	16.5	117.9	++(2)
	15	Rice (Raw)	8.9	.12	.03				++(1)
12 n.	60	Cream. 40°/°	2.0	2.00	24.00				++(1)
	1	Egg		6.00	6.00				++(2)
			10.9	8.12	30.03	10.9	8.12	30.03	
2.30p.m									
4.30p.m	10	Ovaltine	6.8	1.4	.8				++(1)
	120	Whole Milk	6.0	4.0	4.0				+(2)
	60	Cream, 40°/°	2.0	2.0	24.0				+(3)
			14.8	7.4	28.8				++(1)
8.30p.m		Repeated	3	3	3				
			44.4	22.2	86.4	44.4	22.20	86.40	
10p.m.	10	Ovaltine	6.8	1.4	.8				++(1)
	120	Whole Milk	6.0	4.0	4.0				+(2)
			12.8	5.4	4.8				+(3)
2 a.m.		Repeated	2	2	2				
			25.6	10.8	9.6	25.6	10.80	9.60	
6a.m.	15	Malted Milk	9.5	2.3	1.2	9.5	2.30	1.20	
						119.2	59.92	245.13	Total
						4	4	9	Calories
						476.8	239.68	2206.68	"
								239.68	
								476.80	
								2922.65	Total Calories

Using 20°/° Cream instead of 40°/°, gives 161.13 Fats and 2,162.65 Calories.

Prepared by Ina J. Zimmer, 2/14/22

Fig. 522.—Dietary chart. (*MacKenty* operation.)

The feeding may be once in two and one-half to four hours and after each a few ounces of water are passed through the tube to cleanse it. Several times a day the pharynx is cleansed of mucus by suction and the mouth and teeth cleansed.

Dressings are changed as often as necessary to keep the wound free from secretions. In foul cases the wound packing may require several changes in twenty-four hours. The patient must be shifted from side to side and encouraged to sit propped up in bed.

Complications.—1. Pneumonia. The entrance of blood into the lungs during operation and prolonged deep anesthesia are the two most noteworthy causes of pneumonia.

2. Mediastinitis. Liberal drainage at the time of operation and free opening of the wound at the onset of infection will materially minimize this danger.

3. Extensive gangrenous sloughing of the wound. This may produce great debility but is not likely to cause death. It may perhaps save life by eradicating more efficiently than the knife any wandering cancer elements in the neck.

4. Hiccough. If this occurs, small doses of apomorphine will control it. It is probably due to irritation of the vagus nerve in the operated field.

5. Hemorrhage. Secondary hemorrhage immediately following operation is due to a defective technique on the part of the surgeon. All clamped points in operations in the neck should be tied. If a good pedicle cannot be secured for tying, then a transfixion stitch should be used. Secondary hemorrhage from sloughing, which may—though rarely—occur, may be controlled and is not serious unless prolonged. Secondary hemorrhage sometimes occurs in healing wounds just past the septic stage which is difficult to control. Septic absorption has so changed the chemistry of the blood as to convert the patient into a temporary bleeder. The blood becomes thin and clots poorly. In this state the granulating surface of the wound may bleed profusely. The granulations at the point of bleeding should be curetted away and the patient transfused. Repeated small transfusions act better than one large one.

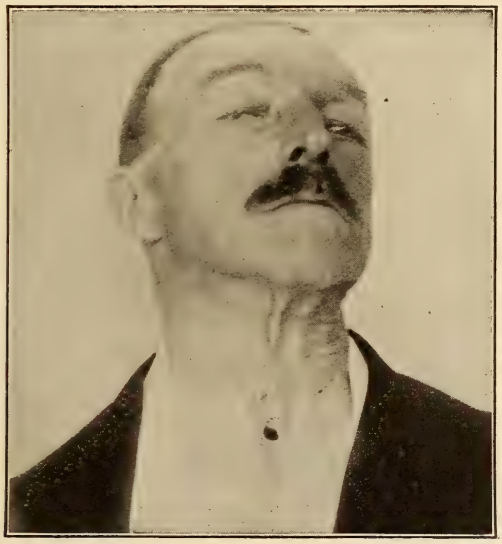

Fig. 523.—Tracheal wound after discarding cannula. (*MacKenty* operation.)

6. General sepsis. This may occur if the patient is a diabetic.

7. Trachitis. A mild degree of trachitis may be observed after laryngectomy; suction to clear the trachea and upper bronchial tree from secretion is of invaluable aid.

8. Finally it may be stated that a large majority of the cases eventually discard the cannula (Fig. 523).

CHAPTER LI.

NEUROSES OF THE LARYNX.

THE various neuroses of the larynx have to do either with the sensation or motion of this organ. Hence they are primarily classified as:—

1, sensory, and, 2, motor disturbances.

1. NEUROSES OF SENSATION.

Sensory neuroses are relatively rare and are chiefly confined to the terminal nerve filaments in the laryngeal mucosa. They are classified in conformity with their clinical manifestations into (*a*) anesthesia; (*b*) hyperesthesia and paresthesia; (*c*) hyperalgesia or laryngeal neuralgia.

(a) ANESTHESIA.

Etiology.—This affection is usually due to some form of neuritis of the terminal filaments of the superior laryngeal nerve, and is most commonly observed as a sequela of diphtheria and, rarely, of cholera. Hysteria is believed to be the cause in a limited proportion of cases. When of central origin it usually occurs as a symptom of bulbar paralysis or tabes.

Unilateral anesthesia is observed in cases of laryngeal paralysis from hemiplegia.

Symptoms.—The area of anesthesia may either be general or circumscribed. When general the entire laryngeal mucosa loses its normal irritability to touch and no cough or spasm is induced when a probe or applicator is passed into the larynx. Aside from the actual loss of sensation the most common symptom is the tendency for food and drink to pass into the larynx and trachea.

Diagnosis.—The diagnosis is based upon the loss of sensation to the touch of the probe.

Prognosis.—The prognosis depends upon the primary cause of the disease. It is grave in all cases of central origin, but when the affection results from diphtheria or hysteria the prognosis is good and recovery may be expected in a few weeks.

Treatment.—Except in cases of central origin the treatment should consist of general hygienic measures, principally out-of-door life in a bracing atmosphere, and the internal administration of suitable tonics in the form of iron and strychnia. When accompanied with paralysis of the laryngeal muscles it is important to adopt measures for preventing the entrance of food into the larynx. This is best accomplished by tubal feeding, or by having the patient assume the dorsal position while eating. Electricity in the form of the galvanic, faradic, or high-frequency current, applied locally, is of some benefit.

(b) HYPERESTHESIA AND PARESTHESIA.

Etiology.—Some increase in the sensibility of the larynx is common even among healthy individuals. The increased or hypersensitiveness is characterized by attacks of cough or even laryngospasm, upon the slightest touch or stimulus applied to the laryngeal mucosa. Such irritability, however, soon subsides and the patient becomes able to endure the stimuli without reflex symptoms. Persistent catarrhal inflammation of the upper air passages, particularly in those who indulge in tobacco or alcoholic excesses, is provocative of hyperesthesia of the laryngeal mucosa. The laryngeal mucosa of tuberculous and anemic persons is particularly susceptible to changes of temperature, smoke, dust or the slightest pressure upon the throat. The apprehension of impending cancer, tuberculosis or syphilis, which is aroused by nervous indigestion in neurasthenics, is a common cause of this affection.

Symptoms.—The milder symptoms consist of a disagreeable sensation of burning, pricking, dryness, constriction and rawness in the larynx. The phonophobia on the part of the tuberculous and of various reflex disorders is commonly due to a more or less abnormal sensitiveness in the mucous membrane of the larynx. The truly nervous laryngeal cough, however, according to Mackenzie "occurs without any altered sensibility of the larynx" at all. The mucosa is extremely irritable to the touch, and cough and "tired" voice is common. The mucous membrane is often congested, but may be anemic.

PARESTHESIA.

Paresthesia of the larynx is almost invariably associated with hysteria and is characterized by perverted sensations in the larynx. Persons who by occupation are obliged to use their voices much are frequently the sufferers from a morbid sensibility of the larynx which causes them to suspect the presence of a foreign body in the throat. More frequently the patient is apprehensive or even hysterical, and complains of a lump in the throat, violent pain or spasm.

Treatment.—The treatment of hyperesthesia and paresthesia in their simpler forms should aim to relieve the patient's baseless apprehensions regarding serious organic diseases, such as tuberculosis and cancer. The surgeon should, if possible, gain the patient's full confidence, meanwhile impressing upon him the fact that his affection is a simple matter which requires only the cooperation of both patient and physician in order to effect a cure.

As a rule it is unwise to recommend home treatment for the throat or to administer frequent office treatments unless it is thought wise to make use of a placebo for a time. In case the patient has a simple chronic laryngitis he should be subjected to the measures heretofore defined for that affection. When accompanied by faulty digestion he should be advised regarding his food, exercise and habits. Intratracheal injections of camphor and menthol, each 2

per cent. in benzoinol, afford much relief. Whenever anemia is present the administration of iron is beneficial.

(c) HYPERALGESIA OR LARYNGEAL NEURALGIA.

Laryngeal neuralgia is a comparatively rare affection, characterized by intermittent attacks of pain in the larynx. It is usually unilateral, intermittent, and is generally relieved by pressure. As a rule it is confined to the local area supplied by the superior laryngeal nerve. It is usually preceded by a history of a cold, but it may occur from the pressure of new growths. Avellis affirms that the spot where the superior laryngeal nerve penetrates the thyrohyoid membrane, between the hyoid bone and thyroid cartilage, is the pressure point of greatest pain. It is worthy of note that this is the precise spot that is complained of in the laryngeal crisis of locomotor ataxia. The affection may be due to rheumatism, gout or malaria.

Prognosis.—Usually the prognosis is favorable, although the course of the affection may be prolonged.

Treatment.—The treatment must be directed to the primary cause of the affection in each individual case. Apart from the neurasthenic element involved it is probable that a considerable proportion of these laryngeal dysesthesias are of rheumatic nature and as such are to be treated by potassium or the salicylates.

Whenever it can be determined that the affection is due to some constitutional dyscrasia, appropriate general treatment, adapted to the individual case, should be adopted. In gouty affections asperin (15 to 30 grs. a day) will afford relief. In case of malaria quinine is indicated. The intratracheal injections (see Chapter XLVIII) relieve the pain and irritation, while hot fomentations applied externally during the paroxysms afford relief.

2. NEUROSES OF MOTION.

The motor neuroses of the larynx are characterized either by loss or perversion of power or movement. When the affection is characterized by a loss of power it is known as paralysis; if due to perverted power it is known as spasm. To the one or other of these two primary classes all neuroses of motility belong. A further analysis determines whether the lack of motility lies in the tissues of the muscles or in disease of the nerves that control them. If found in the muscles it is termed myopathic. If it originates in the nerves it is classified as neuropathic. The muscles that may be involved are enumerated as follows:—

Group 1.	The lateral crico-arytenoids. The superior portions of the thyro-arytenoids. The arytenoids.	Adductors.
Group 2.	The internal thyro-arytenoids.	Internal tensors.
	The cricothyroids.	External tensors of the vocal cords.
Group 3.	The thyro-epiglottics. The aryteno-epiglottics All the adductor muscles.	Sphincters or constrictors.
Group 4.	The crico-arytenoids.	Abductors.

The chief function of groups 1 and 2 is that of phonation; of group 3, deglutition; of group 4, respiration.

The position of the vocal cords during forced inspiration is shown in Fig. 524; that of quiet inspiration in Fig. 525, and during phonation in Fig. 23. With the exception of the cricothyroids and a portion of the arytenoids the entire list of the above-mentioned muscles receive their nerve supply from the recurrent laryngeal nerves. The cricothyroids and the arytenoids, in part, are supplied by the superior laryngeal nerve.

It is obvious that an inflammatory process of sufficient severity to produce inflammatory changes in the mucous membrane and deeper tissues of the larynx is equally sufficient to induce disturbances of function of the type known as muscular paresis. The "tired" voice of the professional singer or orator, due to prolonged overstrain of voice or a too frequent use of unusual registers, called by Fränkel mogiphonia, may be regarded as paresis of this type.

Fig. 524.—Position of the vocal cords during forced inspiration.

Fig. 525.—The position of the vocal cords during ordinary inspiration.

While this is true, myopathic paralysis seldom exists without affecting its corresponding nerve. According to Ross, "we must assume that the inflammatory process, considering the intimate relation between a muscle and its nerve in the larynx, very easily spreads from the muscular tissue to the supplying nerve branches, and, again, a neuropathic paralysis, if existing for some while, may be accompanied by paresis of the corresponding muscle through what is called 'atrophy of inactivity.' Hence it follows that it will very frequently be impossible, or at least very difficult, to distinguish by means of the laryngoscopic image a myopathic from a neuropathic affection."

Furthermore, as the seat of the disease may be anywhere in the nerve from its root in the floor of the fourth ventricle to its termination in the larynx, we naturally divide them again into central or peripheral paralyses according as they have their origin in the central nervous system (Fig. 526) or in a disease of the nerve at its periphery in the larynx. It will thus be seen that the character of the paralysis of the laryngeal muscles depends upon whether the origin is to be sought in the nervous centres which govern their action, or in the endings of the nerves themselves.

1. CENTRAL PARALYSIS.

Fortunately, outside of the functional or hysterical paralyses of the larynx due to lesions in the central nervous system, cases of central origin are exceedingly rare and are seldom seen except in locomotor ataxia, multiple sclerosis and bulbar paralysis. And equally fortunate is the fact that their diagnosis is never difficult, for here the Semon-Rosenbach law is of great value, viz., "in all functional paralyses of the larynx the constrictors of the glottis (adductors) are almost always affected; in all the organic and progressive organic paralyses, whether central or peripheral in origin, the dilators of the glottis (abductors) are at first or exclusively affected."

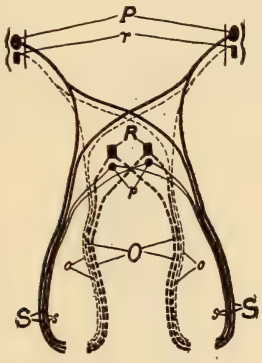

Fig. 526.—Diagrammatic representation of the centers of respiration and phonation in the brain and medulla oblongata and their tracts (after *Rethi).* The cortical center of phonation (*P*) is functionally more important, and, therefore, better developed, than the cortical center of respiration, *r;* on the other hand, the medullary (bulbar) center of respiration, *R,* is functionally of greater importance than the medullary center of phonation, *p.* The more important centers are thus marked with capital letters; the minor centers, with small letters; the black non-interrupted lines (*S,s*) show the course of the fibers for the narrowers; the lines *O,o,* those (dotted) for the dilators of the glottis. *(Ross,* with permission.)

And it may further be observed that the most marked characteristic of laryngeal paralysis of central origin is that other nerves become implicated. For instance central paralyses of the larynx, when due to organic disease, never appear alone, inasmuch as loss of power in some other muscle of the head, face, or extremity simultaneously occurs. Hence a history of a sudden loss of voice with an equally sudden return occurring in women at the period of puberty, pregnancy or the menopause, or among men hysterically inclined, or afflicted with nasal, pharyngeal, or laryngeal hypertrophies, and, especially when the image in the laryngoscope is that of paralysis of both adductors, it may be assumed that the affection is functional and not organic.

Prognosis.—The prognosis in these cases is generally good.

Treatment.—The surgeon should at the outset endeavor to gain the full confidence of the patient and meanwhile he should speak hopefully regarding the outcome. It is unwise to mention the word hysteria, but rather to assume that the affection is real but curable. If any pelvic disorders are discovered they should receive proper treatment. It is also important that any accompanying disease of the upper respiratory tract should be attended to and the general health and hygiene should, if possible, be improved by tonics, rest and proper exercise.

Full advantage should be taken of suggestions regarding the improvement of voice which may be expected to ensue, and even hypnotism may be resorted to with excellent results. A sudden shock from an electric current, or the passing of a probang into the larynx, has been known to restore the voice in patients who have been properly prepared by suggestion. The author has repeatedly succeeded in restoring the voice by direct application of weak silver or iron solutions to the larynx after having instructed the patient to say "John," "Mary," or some other word just at the instant when the probang is withdrawn.

2. PERIPHERAL PARALYSIS.

Our use of the word here covers the entire course of the nerve from the time it leaves the cranium to its termination in the larynx, and the symptoms are governed by the exact spot at which the nerve is affected. It is obvious that many factors may disturb or destroy the functions of the laryngeal nerves. According to Ross: "In lesions above the branching off of the superior laryngeal nerve all of the laryngeal muscles of the same side are paralyzed, and there is anesthesia of the corresponding half of the laryngeal mucous membrane, and the pulse rate is generally increased, even up to 160. In lesions between the origins of the two laryngeal nerves there is no anesthesia but only paralysis of the muscles. In lesions below the recurrent the larynx remains intact, while the cardiac symptoms may be alarming. If, in addition, the pharyngeal branches are paralyzed, we shall also find paralysis in the pharynx and anesthesia of the palate." For convenience of description peripheral paralyses are classified as follows:—

A, Paralysis induced by disease or traumatism of the recurrent (inferior) laryngeal nerve.

B, Paralysis induced by disease or traumatism of the superior laryngeal nerve.

A. PARALYSIS INDUCED BY DISEASE OR TRAUMATISM OF THE RECURRENT (INFERIOR) LARYNGEAL NERVE.

Owing to its exposed position, paralysis of this nerve is comparatively frequent, and its causes may be sought in: (*a*) Nearby diseases, such as aneurism of the aortic arch on the left, or the

innominate or subclavian arteries on the right, destructive processes at the apex of the lung, carcinoma of the esophagus, enlarged lymphatic glands, goitre, tumors of the mediastinum, pleurisy and, occasionally, pericarditis. (*b*) Traumatic injuries such as result from operations, stabbing and attempts at suicide. (*c*) Varied neuritic and perineuritic inflammatory processes due to such infectious diseases as diphtheria, influenza, typhoid fever, and, occasionally, rheumatic and scarlet fever; or the ingestion of large doses of such drugs as atropine, lead and arsenic. The various types of paralysis of the recurrent laryngeal nerve are defined in the following order:—

1. BILATERAL ABDUCTOR PARALYSIS.

Etiology.—As we have already observed, the act of abduction is performed by the posterior crico-arytenoid muscles. Paralysis of these muscles is of two general types, viz., neuropathic and myopathic. In the majority of all cases the lesion is central and arises

Fig. 527.—Bilateral abductor paralysis during inspiration.

Fig. 528.—Bilateral abductor paralysis during expiration.

Fig. 529.—Paralysis of the left abductor as seen during forced inspiration.

from degenerative changes which are induced by syphilis, tabes dorsalis and bulbar paralysis. In rare instances a bilateral involvement of the recurrent laryngeal nerves may arise from the pressure of mediastinal tumors, aneurism, goitre and cancer of the esophagus. This affection arises from peripheral causes (above defined) with extreme rarity.

Bilateral abductor paralysis is more common among men than women and is usually an affection of adult life, although a few cases have been reported among children. Whether myopathic or neuropathic in origin it is invariably a condition of grave import. A long-continued paralysis of the posterior cricoarytenoids should invariably lead to a suspicion of locomotor ataxia.

Symptoms.—Bilateral abductor paralysis is characterized by a gradually increasing inspiratory dyspnea which is aggravated by the least exertion. The dyspnea is accompanied by a marked stridor during sleep, and later on during the waking hours. The laryngoscopic picture (Figs. 527 and 528) is characteristic, inasmuch as the cords assume a fixed position in the median line and open but slightly during inspiration.

There are but two other conditions which are liable to be confounded with this affection, viz., bilateral ankylosis of the crico-

arytenoidal joint, and a perverted action of the vocal cords or spasm. But differentiation is never difficult. In ankylosis the cords are straight, tense and utterly without movement, while in paralysis they are flaccid and show a tendency to be sucked in toward the median line during inspiration (Fig. 527), and puffed upward and outward during expiration.

Equally sharp is the distinction between the so-called perverted action of the cords and true bilateral abductor paralysis, for in spasm the movement is intermittent in character and more or less short in duration. Furthermore, by adopting the simple expedient of inducing the patient to keep on repeating, *i.e.,* until the breath is exhausted, a perfectly normal abduction will take place with his next inspiration, showing that no real paralysis of the abductors has existed.

2. UNILATERAL ABDUCTOR PARALYSIS.

Etiology.—Unilateral abductor paralysis (Fig. 529) is rarely caused by a central lesion. It is usually induced by pressure upon the trunk of the recurrent nerve, by aneurisms, malignant growths, goitre, gummata, or enlarged glands. When of central origin it is due to tabes or syphilis and usually eventuates in the bilateral form. Cases have been reported wherein the affection has arisen from toxemic neuritis as a result of diphtheria, typhoid fever, or from lead poisoning. Finally, it may result from traumatism.

Symptoms.—The symptoms differ materially from those of the bilateral form. They are mild and are free from paroxysms of dyspnea. Aside from a slight loss of strength and flexibility of voice and a possible shortness of breath on exertion, no clinical symptoms may be detected except that the cord of the affected side remains practically stationary during respiration (Fig. 529). Whenever the affection is primarily due to a central lesion, it may be expected that sooner or later both sides will become involved.

Consideration of the prognosis and treatment for both these forms of paralysis is deferred until the end of the following section.

3. COMPLETE PARALYSIS OF THE RECURRENT NERVE.

Reference has already been made to the fact that all the adductor, abductor and tensor muscles of the larynx, with the single exception of the cricothyroids, are supplied by the inferior or recurrent laryngeal nerve; hence, by complete paralysis of the recurrent nerve we mean a paralysis of all the muscles involved or an advanced stage of abductor paralysis. According to Semon's law, the abductors are the first to succumb. This, if due to progressive central lesions, or continuous pressure upon the nerve trunks, will, sooner or later, be followed by paralysis of all the remaining muscles of the larynx, with the single exception of the cricothyroid, which is supplied by the superior laryngeal nerve. This condition marks the final stage of bilateral abductor paralysis.

Symptoms.—The symptoms depend upon whether one or both sides of the larynx are affected:—

(*a*) *Unilateral Paralysis of the Recurrent Laryngeal Nerve.*—A characteristic symptom is an alternation in the voice, due, no doubt, to the undue escape of air from failure of the glottis to close in response to the patient's efforts to produce tones (Fig. 530). The patient's ability to speak and breathe are still retained (Fig. 531) for the reason that, while the affected cord assumes and always

Fig. 530—Paralysis of the right recurrent laryngeal nerve during inspiration.

Fig. 531.—Paralysis of the right recurrent laryngeal nerve during phonation.

remains in the cadaveric position with its inner edge concave from paralysis of the tensor and the tip of the arytenoid cartilage unduly prominent, the healthy cord upon its opposite side will on phonation cross the median line (Fig. 532) and thus fall into apposition with the cord of the diseased side.

(*b*) *Bilateral Paralysis of the Recurrent Laryngeal Nerve.*—Here we reach the ultimate of all neuroses of the larynx (Fig. 533), inasmuch as nearly all the laryngeal muscles are paralyzed. With the

Fig. 532.—Paralysis of the right recurrent laryngeal nerve during phonation. The left vocal cord crosses the median line in order to compensate for the loss of motion in its opponent.

vocal cords, both in phonation (Fig. 534) and respiration, set in the "cadaveric position," dyspnea absent except on exertion, with extreme difficulty in coughing and speaking, and with no muscular power to clear the throat or to prevent the entrance of food and liquids into the larynx, a clinical picture of this hopeless malady is presented. In the majority of neuropathic cases of central origin the patient succumbs to the primary disease long before the laryngeal paralysis has completed its work. The following paragraphs are devoted to the prognosis and treatment of the three forms of abductor paralysis above described.

Prognosis.—The prognosis is governed by the underlying cause of the affection. In cases which are of central origin or are the result of prolonged and permanent pressure the paralysis will remain incurable. In bilateral abductor paralysis it is often necessary to resort to tracheotomy in order to prevent a sudden fatal issue from suffocation. The prognosis is more favorable in unilateral cases and in those neuropathic cases in which it is possible to remove the pressure upon the nerve trunks. It is still more favorable in recent cases which are due to toxic neuritis or to trauma.

Treatment.—Primarily the treatment must be directed to the underlying cause of the affection, and secondarily to the relief of the paralysis and its attendant symptoms. When the lesion is central, syphilis should be suspected regardless of whether the symptoms are those of tabes or bulbar paralysis. Hence iodid of potassium in full doses should be administered. When due to toxemia from lead or arsenic the same internal treatment is indicated, except that it be daily preceded by early morning doses of

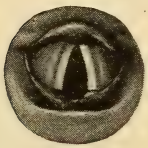

Fig. 533 —Cadaveric position of the cords in bilateral paralysis of the recurrent laryngeal nerve.

Fig. 534.—Bilateral paralysis of the recurrent laryngeal nerve during extreme effort to phonate.

Fig. 535.—Bilateral adductor paralysis of the larynx.

magnesium sulphate and sulphuric acid, while the evil effects of diphtheria, influenza, typhoid and other fevers should be met by good diet, change of air and free doses of strychnine and iron.

Myopathic cases when due to local syphilitic lesions in the muscles and other structures in the vicinity of the larynx call for the mercurial inunctions in addition to the iodid of potassium, while those of traumatic origin must be treated by absolute rest in bed, the prohibition of all efforts to talk and the employment of such surgical measures as the individual case may require.

The direct application of electricity is an entirely useless procedure in cases in which the paralysis has remained permanent for a long period, and especially so when the paralysis is bilateral and due to a central lesion or to pressure from aneurism or malignant growths. In recent cases which are due to toxemia or traumatism and in certain unilateral paralyses some benefit may be obtained from daily applications of the high-frequency current. Likewise in hopeful cases a systematic course of massage, careful hygiene, diet and exercise should be inaugurated.

In bilateral abductor paralysis when accompanied by paroxysms of dyspnea the treatment is entirely surgical and tracheotomy (see

Chapter XXXI) constitutes the only means of relief from the dyspnea and from the danger of sudden death from suffocation. The danger of delay should be fully explained to the patient, and, unless immediate relief should follow the adoption of local measures of treatment and the internal administration of the iodid of potash, there should be no delay in operating.

The author is in full accord with the recommendations of Semon that, unless objective widening of the glottis be obtained by treatment within a short time, tracheotomy ought to be performed without delay.

4. ADDUCTOR PARALYSIS OF THE LATERAL, CRICO-ARYTENOIDS AND THE ARYTENOIDS.

Unless preceded by paralysis of the abductor muscles the cause of adductor paralysis is either functional or myopathic.

When functional it is usually induced by exhaustion from disease, prolonged anxiety or nervous strain, anemia, hysteria and uterine disorders.

When of myopathic origin it is primarily due to acute or chronic laryngeal inflammation. It occurs chiefly among anemic, hysterical women and rarely in men or young children.

Symptoms.—Complete aphonia is the characteristic symptom of the functional type. The attack is sudden and terminates with equal suddenness. In rare instances the aphonia is confined to the speaking voice and the patient is able to indulge in coughing or laughter or sneezing. When of myopathic origin the aphonia is not complete, but the voice is hoarse; it tires easily and requires much strain in production. The laryngeal picture is either that of flabby, almost immovable cords occupying about the usual position of ordinary respiration (Fig. 535), or they may be made to partially or wholly approximate momentarily, only to resume the wide-open state.

Prognosis.—In the majority of cases the prognosis is good, and recovery, often after many relapses, is the rule. When the aphonia is due to long-continued chronic laryngitis or phthisis it usually remains permanent.

Treatment.—The underlying cause should be determined and if possible removed. Tonics, especially strychnia, out-of-door life in hygienic surroundings, cold sponges, massage and liberal diet are most beneficial. Complete rest of the voice often proves a curative measure. In hysterical women the measures advised for the treatment of hyperesthesia of the larynx are applicable.

In myopathic cases the treatment heretofore outlined for acute and chronic laryngitis is indicated. Daily applications of the faradic, high-frequency or galvanic current, both intralaryngeally and externally, to the affected muscles may prove of some benefit.

Treatment of a more general character calls for the ordinary antihysterical procedures, such as the use of the cold-water plunge, and the inhalation of chloroform in extreme cases.

5. PARALYSIS OF THE ARYTENOIDEUS.

This affection is caused by chronic inflammation of the laryngeal mucosa, incipient phthisis, hysteria, diphtheria, exhaustion from lingering diseases, and traumatism. It is frequently accompanied by paralysis of the lateral abductors.

Symptoms.—Feebleness, hoarseness, and, at times, loss of voice are the characteristic symptoms of this disease, the laryngoscope showing that, while the cords approximate well in the anterior three-fourths of the glottis, the posterior portion remains open (Fig. 536), thus leaving a triangular opening between the cords in that situation. The treatment is similar to that of adductor paralysis.

6. PARALYSIS OF INTERNAL TENSORS.

This type of paralysis is found largely among professional singers and speakers, and is due to an overstrain or overfatigue of the voice. This condition is generally ascribed to a paralysis of

Fig. 536.—Paralysis of the arytenoideus muscle.

Fig. 537.—Bilateral paralysis of the internal tensors during respiration.

Fig. 538.—Bilateral paralysis of the internal tensors during phonation.

the internal thyro-arytenoids, although many authors believe that some of the fibres of the lateral crico-arytenoid muscles may be involved. If due merely to fatigue it can easily be overcome, but if from actual strain months of complete rest may be necessary in order to effect a cure. In all other respects the causes are precisely the same as the preceding variety. It may either be bilateral or unilateral. In the laryngeal picture the cords appear concave (Fig. 537) so that when phonation is attempted an elliptical gap appears in the middle third (Fig. 538). The treatment is precisely similar to that of adductor paralysis above described.

B. PARALYSIS INDUCED BY DISEASE OR TRAUMATISM OF THE SUPERIOR LARYNGEAL NERVE.

Barring the sphincters or closers of the glottis, the only muscles supplied by the superior laryngeal nerves are the cricothyroids (external tensors). Furthermore this nerve supplies not only motion to the muscles but sensation to the laryngeal mucosa. Hence with the loss of motion there is a loss of sensation in this area.

1. Paralysis of the External Tensors.

This affection is extremely rare and seldom is seen except in the wake of diphtheria or from some pressure above the trunk of the nerve caused by a foreign body or enlarged gland. It may be bilateral or unilateral. When examined, the cords, though apparently in proximation, show a wave-like outline (Fig. 539).

The chief symptom is a hoarse and uneven voice, lacking power and modulation. In unilateral cases the affected cord will have the appearance of occupying a higher level than the one upon the opposite side.

Prognosis.—The prognosis is generally favorable. When both sensation and motion are impaired or lost there is an added danger of pneumonia from the entrance of fluids and solids into the lungs.

Treatment.—Full doses of strychnine and iron should be administered if due to diphtheria. Mercurials and iodid of potas-

Fig. 539.—Bilateral paralysis of the external tensors (cricothyroids).

Fig. 540.—Complete bilateral paralysis of the supralaryngeal nerve.

sium are indicated if syphilis be suspected. Complete rest of the vocal organs is of great benefit. Tubal feeding may be resorted to in cases wherein the food passes into the larynx.

2. Paralysis of the Sphincters of the Glottis.

Careful experiments have confirmed the commonly held view that sensation to the larynx above the level of the vocal cords and motion to the cricothyroid muscles are both supplied by the superior laryngeal nerve and that the closers of the glottis receive their motor supply from the same source. When, therefore, these muscles are paralyzed, closure of the glottis during deglutition cannot take place (Fig. 540); consequently, a continuous passage of portions of the matter swallowed, principally fluids, into the laryngeal orifice, takes place. Inasmuch as the reflex act of coughing cannot take place until these foreign substances reach below the level of the cords, on account of the anesthesia above them, some of these foods enter the trachea, where they are prone to induce pneumonia.

Treatment.—The treatment is similar to that advised for paralysis of the external tensors.

PERVERTED POWER OR SPASMS OF THE LARYNX.

1. Spasm of the Glottis (Laryngismus Stridulus).

Etiology.—This affection is largely confined to childhood, being more frequent between the ages of three months and two years, but the attacks may continue up to the ninth year. It is more prevalent among males than females. Opinions differ regarding the primary source of the affection as to whether it is central or purely reflex, but it is generally agreed that it is found principally among poorly nourished, rachitic children. Among the exciting causes are intestinal disorders, teething, intestinal worms, adenoids, undue emotional excitement and sudden exposure to cold. In short, malnutrition in some form is invariably at fault.

Symptoms.—The symptoms are characteristic and peculiar. Absolutely without warning and with no sign of any local disturbance in the larynx, a child otherwise free from evidences of disease of the larynx will suddenly awaken from sleep, sit up in bed and manifest all the symptoms of alarming dyspnea of an inspiratory character, struggling for breath, sonorous inspiration, and rapidly becoming cyanotic. Air will finally enter the lungs and the paroxysm terminates in from a few seconds to two minutes. Recovery is usually spontaneous, but fatal asphyxia may ensue. The attacks are prone to recur and even to increase.

Diagnosis.—The diagnosis as a rule is not difficult. Apart from spasmodic croup, catarrhal laryngitis and an occasional severe attack of whooping-cough, all of which are accompanied by cough, fever, expectoration and loss of voice, the only disease that simulates laryngismus stridulus is bilateral abductor paralysis. But the paralysis is easily distinguished from spasm, inasmuch as the closure of the glottis is constant and incomplete, while in spasm the closure is complete but not constant.

Prognosis.—The prognosis varies in proportion to the gravity of the underlying cause. In children who are fairly well nourished and who possess a good degree of resistance, in whom the attacks are infrequent and show a tendency to diminish in severity, the prognosis is good, and it may be expected that the paroxysms will finally disappear.

Treatment.—It is seldom that the surgeon has an opportunity to witness a paroxysm of laryngismus stridulus, on account of its brevity and irregularity. Hence the mother or nurse should be instructed to place the child in the sitting posture at the very commencement, to loosen the neckbands and to administer a sharp slap upon the patient's back. Ammonia may be held to the nose and cold water applied to the face and neck. A rapid tracheotomy should be performed in cases of threatened asphyxia, providing a surgeon can be procured. Mackenzie advocated the administration of musk, providing the child is able to swallow, in the following formula:—

℞ Musk ..... gr. iss.
White sugar,
Powdered acacia .....āā gr. ij.
Syr. orange flowers..... ♏ xx.
Water .....q. s. ad ℥j.
Sig.: Take at one dose.

The treatment between the attacks must vary in accordance with the primary cause and the exciting factors. When the paroxysms are frequent it becomes necessary to administer sedatives continuously in order to control them. Bromids, morphia and chloral may be administered under proper supervision. The mixed bromids are effective.

℞ Bromid of sodium,
Bromid of potassium.....āā gr. xx.
Bromid of ammonium..... gr. x.
Syr. simplex ..... ℥ij.
Aquæ .....q. s. ad ℥j.
Sig.: ℥j three times a day for a child 1 year old.

It is important that a healthy state of the upper respiratory tract should be maintained.

The general treatment should be directed to the underlying cause or causes of this affection, and usually it involves the administration of remedies for rachitis, viz., cod-liver oil, preparations of iron, the hypophosphites and liberal diet, combined with a carefully regulated hygiene, clothing and diet.

2. Spasm of the Glottis in Adults.

Etiology.—The clinical history of this affection in adults presents an altogether different picture than when occurring in childhood. For, apart from such attacks as occur as the result of a foreign body being impacted in the larynx or the spasms which arise from laryngeal edema or new growths, spasm of the glottis in adults is seldom dangerous as to life, and is more prevalent among females than males. It appears to be purely reflex in its nature, although an abnormal excitability of the nervous system must be regarded as a predisposing cause. As in childhood, the attack generally occurs at night, frequently during sleep, and the patient awakens suddenly, seized with a paroxysm of dyspnea, and manifests all the symptoms common to spasm of the glottis. Such attacks may be repeated, but the regular periodicity so characteristic of those occurring in childhood is absent. It is occasionally caused by tabes dorsalis, tetanus and hydrophobia.

Treatment.—The attacks are usually recovered from before any remedial measures have been applied. Inhalations of chloroform, nitrate of amyl, and ammonia have been recommended. Semon has secured good results by advising the patient to hold the breath for two seconds and then to draw two quick inspirations through the nose, with the mouth closed.

When the disease is caused by new growths and foreign bodies in the larynx, the treatment should consist of the surgical removal of the obstruction, whenever feasible.

In case the lesion is central, and in tetanus and hydrophobia, local measures are of but little avail, and the treatment should be directed to the specific affection in each individual case. Here again it is important to maintain a healthy state of the upper respiratory tract. This may require operations for the removal of adenoids, hypertrophied tonsils, or for the correction of intranasal deformities and diseases.

When the attacks are functional and therefore of reflex origin it is important to institute proper remedial measures, and to sustain the patient's general health by proper hygiene, clothing, habits, diet, etc.

3. Spasms of Co-ordination (Phonatory Spasms).

In addition to spasms of the glottis which invariably occur in the act of inspiration there is a class of these perversions that only occurs in the act of expiration; they are sometimes called expiratory spasms. They consist of a loss of power in the co-ordinate control of the laryngeal muscles and lead to a spasmodic contraction of the glottis in the act of expiration. It is the tensor muscles that are primarily at fault, although the adductor muscles are also involved in the act. Among these may be mentioned:—

4. Chorea of the Larynx (Spasmodic Laryngeal Cough).

The distinguishing feature of this form of spasm is a persistent, extremely loud, bark-like cough, so resembling that of the dog that children suffering from it are spoken of as "barking children." It has also been termed the "barking cough of puberty," and the "laryngeal cry." So persistent is this that apart from intervals of sometimes only a few minutes, during which the child may act perfectly natural, the cough will continue during all waking hours, sleep alone affording relief. Between these attacks the voice tone remains entirely unchanged, but during the attacks it becomes jerky and intermittent. This disease is found principally among girls, generally around the years of puberty, and is induced by spasm of the adductors, associated with a forcible expiratory movement.

Treatment.—There is no specific treatment for this affection. It is a neurosis, hence the bromids, arsenic, hyoscyamus or cannabis indica may afford relief. It is unwise to give undue importance to these patients, for they usually court the notoriety which is incited by the peculiar cough. A change of scene in the form of a sea voyage, according to Semon, is most effective in terminating the attacks.

5. Dysphonia Spastica.

This form of spasm differs from "chorea" only in that the spasm occurs in an attempt at phonation. For this reason it is sometimes called "stammering of the cords." Its prominent charac-

teristic therefore is first an impairment and then a complete loss of voice. This is explainable upon the theory that the moment the patient attempts to speak the cords come into such absolute apposition that the glottis is completely closed and all exit of air for phonetic purposes is absolutely cut off. The closure, however, will immediately cease the moment the patient ceases his attempts to speak, but it recurs just as quickly at every effort to phonate. The laryngoscope reveals a healthy appearing larynx in every way, but, the moment the cords are brought into approximation and an attempt at phonation is made, a spasmodic contraction takes place and the glottis closes. Pain has sometimes been complained of and is probably due to constriction or cramp. This symptom has given rise to the suggestion that the spasm arises from an over or strained use of the muscles of phonation, even as writers' cramp is caused by an overuse of the muscles of the lower arm.

Treatment.—There is no specific treatment for this affection. Usually the attacks are mild in character and cease after a few days of absolute rest of the voice. Whenever the attacks recur the patient should be required to take a prolonged rest and if possible a sea voyage, to build up his overtaxed and debilitated condition. These measures have already been outlined in the previous paragraphs. Likewise, attention has been called to the importance of maintaining a healthy state of the upper air tract. In some instances it is necessary for the patient to adopt a different method of voice production under competent instruction.

6. Laryngeal Vertigo.

This affection is characterized by a sudden paroxysm of cough, which terminates in a loss of consciousness of short duration, during which the patient usually falls. It occurs only in adults, usually in males and without premonition, leaving the patient as well as before the attack and without stupor. Its exact pathology is unknown. A case reported by the author[1] gave the following history:—

W. J. R., aged 50 years, an Englishman, manufacturer of confectioners' supplies; has resided in America ten years. His family history is good; his father and mother are still living and free from neuroses, and five brothers are all in good health. His complexion is florid and his appearance robust. He has never had venereal disease. He is of nervous temperament, but has never developed any neurotic characteristics, but says his friends call him excitable. For ten years he has been under severe mental strain from business cares. One year ago he had articular rheumatism for four days. He has never had muscular rheumatism or gout. He never has used tobacco or snuff in any form, but takes ale or beer in moderation with his meals.

In July, 1891, on entering a shop he stepped into an open trapdoorway and struck on his hip. He was badly stunned, but did not lose consciousness. He was in bed eight days, but refers all his suffering to the hip, and says that, although he was very nervous, he had no disturbance referable to the head and spine during that time. Aside from this he has never had any fright or sudden shock of any kind; neither has he had convulsions or fits. He has never had vertigo in any form, but has had what he calls bronchial

[1] Medical News, March 19, 1892.

catarrh for several winters. He has had headaches quite frequently during his life, but less so now than formerly, and has never been annoyed by hebetude or mental confusion. His attacks of coughing have always been accompanied by a profuse discharge of frothy mucus, which was, on one occasion, tinged with blood. Physical examination reveals very little except coarse râles, but his heart is slightly hypertrophied and its action weak.

He first came under my notice December 20, 1891. Three weeks previously he had taken a cold that had followed about the course of those of previous years, until one week ago, when the cough became more violent and paroxysmal. He remarked to me that "it was like whooping-cough because it was so strangling." Two days before I saw him, during a paroxysm of coughing, without premonition of any kind, he fell suddenly to the floor upon his back, entirely losing consciousness. The attack lasted but a few seconds and he arose from the floor feeling perfectly well, with no pain or unpleasant feeling of any kind, and with no vertigo either before or following the attack. The sensation was exceedingly pleasurable, and, upon being asked how he felt after an attack, exclaimed "I feel as though I had been in heaven."

Following the first attack he had one nearly every day for four days; they sometimes occurred while he was in bed. As a rule, he stood up when coughing and leaned forward with his hands upon a chair or some other object for support, but he invariably fell upon his back during the attack. On one occasion he fell upon the street, but was up again before any one reached him. In every instance the loss of consciousness came on during a paroxysm of coughing, but he had many paroxysms of cough which were not followed by loss of consciousness. He had had four when I first saw him, and loss of consciousness was complete in all. He did not bite his tongue, foam at the mouth, or groan or shriek; but on several occasions his mouth twitched convulsively during the attack and his eyes remained open. He had, in all, twenty attacks and on one day he had five paroxysms between 3 and 9 P.M. In every instance there was complete loss of consciousness. I instructed his wife to watch him carefully during the attacks; she reported that his face became very blue, and that his attacks terminated in from five to fifteen seconds, after which he would arise and walk as steadily as before. On two occasions he complained of a sensation of pressure in the arms and in the region of the deltoid muscle, and, again, of what he termed "smarting of the brain." The patellar reflexes were normal.

Examination of the upper air passages revealed a general hyperemic condition with no specially sensitive areas. There is polypoid degeneration of the middle turbinal bones, an exostosis on the septum, on the right side, with a posterior hypertrophy on the right inferior turbinal. There is no varix at the base of the tongue and only slight hypertrophies. His uvula was amputated thirteen years ago on account of its relaxed condition, which caused cough. The larynx, aside from a subacute inflammation, is normal in appearance. The vocal cords are congested at the edges, but approximate perfectly. There are no signs of paralysis.

After about ten days' treatment the attacks disappeared entirely and have not recurred up to this time (February 18, 1892). His diet was carefully regulated, his bowels opened with a brisk cathartic, and he was given 15 grains of bromid of sodium three times a day, in conjunction with 5-minim capsules of eucalyptol, four times a day.

Treatment.—Aside from the correction of diseases and abnormalities in the upper air tract, and attention to the general health, the internal administration of the bromids in large doses is sufficient to effect a cure in the majority of cases. Antipyrin in doses of 20 to 40 grains has been recommended.

CHAPTER LII.

SUSPENSION LARYNGOSCOPY.

Suspension laryngoscopy is a procedure by means of which the curved road from the teeth to the vocal cords can be converted

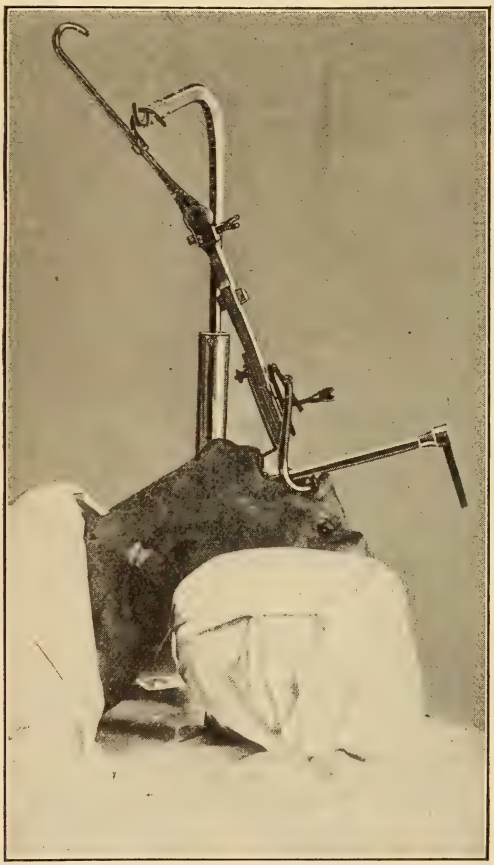

Fig. 541.—Introduction of bronchoscope under direct view, protecting all parts from traumatism.

into a straight one, so that through the wide open mouth a direct view of the larynx can be obtained while the operator is left with both hands free for manipulation as the occasion may require.

The method is not one to be used in routine office work, as a means of diagnosis, to supplant indirect laryngoscopy, neither is it recommended for every case in which operative or other treatment

in the region of the larynx is required. Only a well constructed instrument should be used, one made of steel and of sufficient strength to withstand any strain to which it may be subjected. The defects which were present in the earlier models have been largely overcome, and while to Killian we owe the discovery of suspension laryngoscopy, it is chiefly to Lynch, of New Orleans, that we are indebted for the perfected instrument of today.

The apparatus as modified by Lynch includes the traveling crane (Fig. 541) which may be lowered, or raised, or moved in a horizontal direction, and the horizontal bar having notches to sup-

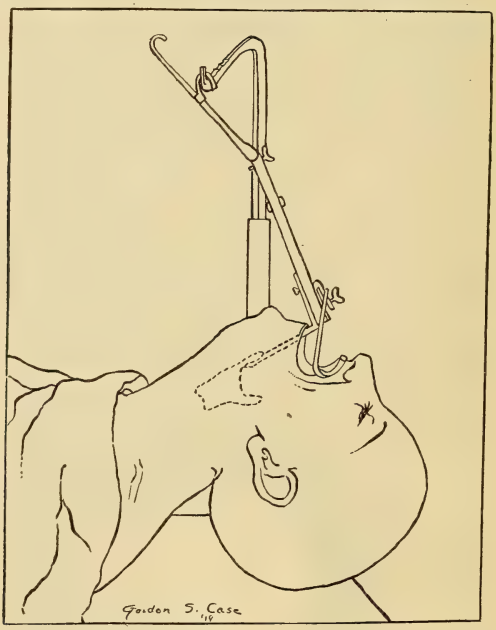

Fig. 542.—Showing new position of head and position of spatula as related to epiglottis and larynx.

port the handle of the spatula. The handle is provided with more than one hook to give additional latitude in vertical movement.

The base to which the tongue spatulæ (Fig. 542) are attached is made especially strong and the body is necessarily heavy to secure the large screw for the movement of the mouth-gag in the vertical direction.

The mouth-gag, which in the original model could not be opened more than an inch in the vertical direction, will now open as much as two inches or more, and this amount has so far been found by Lynch to be in excess of the widest mouth.

The ring is pear-shaped and attached at the small end to the body, and movement is controlled by a large screw which converts the ring into a powerful lever. By turning the screw the spatula

can be driven to any part of the laryngeal face of the epiglottis and by its action tends to elevate the epiglottis, giving a more extensive view of the interior of the larynx.

To prevent possible injury to the teeth sheet lead is used. (See Technique.)

TECHNIQUE OF THE PROCEDURE.

The technique of the procedure as outlined by Lynch[1] is about as follows and is based on the supposition that the instruments and particularly the hook and spatula have become standardized: The patient is prepared in accordance with accepted aseptic surgical procedures—two sterile pillow cases are slipped under the head, one to be wrapped about the patient's head and the other to furnish a sterile surface for the head of the table; the eyes and ears being at the same time covered.

Regarding anesthesia, whether general or local, the operator must use his best judgment and select his cases in accordance therewith. The temperament of the patient, his anatomical development about the neck and his probable self-control are features to be well considered. Thin, long necks with poor muscular development in patients who seem willing to co-operate and who possess some degree of stoicism best represent the type for local anesthesia work. In the majority of cases the procedure, under local anesthesia, is entirely feasible. When general anesthesia is employed the gas oxygen ether sequence combination is preferable for the reason that it lessens the amount of ether and reduces the shock from the anesthetic. In extremely robust individuals it may be found necessary to employ more or less chloroform in order to produce complete relaxation. There is some doubt whether the preliminary employment of morphine and atropin may not possess elements of danger in this particular procedure. When local anesthesia is employed the post-pharyngeal wall is first painted with a 20 per cent. solution of cocaine; after two minutes five drops of the 20 per cent. solution of cocaine is dropped over the epiglottis and is coughed out under instruction. After two minutes have elapsed a cotton-tipped applicator soaked in 1 : 1000 adrenalin solution and saturated with cocaine crystals is thoroughly applied to the base of the tongue and pyriform sinuses on both sides. If necessary this latter procedure may be repeated and finally two drops of the 20 per cent. solution are dropped onto the vocal cords. The operator should carefully avoid any excess of this strong cocaine solution. A preliminary morphine, atropin or scopolamin administration may be employed in cases where the operator has reason to believe that early nausea and vomiting will not occur.

Instead of dental spoons and long tooth plates it has been found that sufficient protection is secured by using only small pieces of lead plate about two millimetres thick, sufficiently long to extend to the first bicuspid on either side, bent so as to protect

[1] The Laryngoscope, July, 1921.

the biting edge of the teeth and sufficiently wide to extend on the lingual aspect of the teeth, far enough so that the tips of the tooth plates will not make pressure upon the membrane.

It is no longer necessary to employ a special table for this procedure, providing arrangements are devised where the crane can be securely fixed to the table-top in a manner that will permit its easy changes into its various positions.

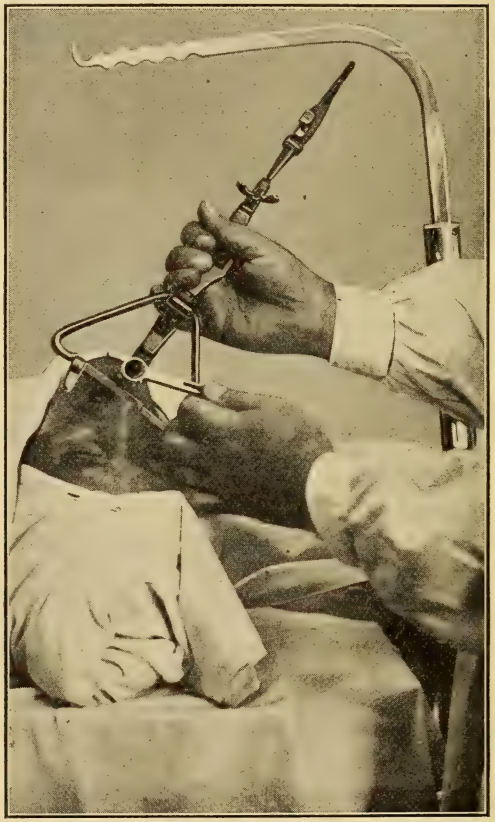

Fig. 543.—Demonstrating hook, latter tilted to patient's right to remove left tooth-plate.

By the more modern technique it is no longer necessary to drop the head of the patient over the table-top; but the head should be held in rather extreme extension by an assistant standing on the right side of the table facing the head of the patient. He then places both hands over the forehead, pulls the head back until the occiput is as near the nape of the neck as possible and raising the chin to its highest level. The mouth is opened wide and held so by a tight fitting gag. In patients with short rigid necks and marked muscular development it is sometimes difficult to obtain

the view of the anterior commissure. It is often necessary to produce a subluxation of the lower jaw by widely opening the gag and at the same time making upward pressure on the lower jaw. This will give the operator about one-quarter inch more view of the cords and will facilitate the suspension. At the same time no unfavorable results ensue from the subluxation. The operator holds the hook in the right hand and with the mouth gag of the hook closed, passes the spatula down along the dorsum of the tongue for the two following reasons:—

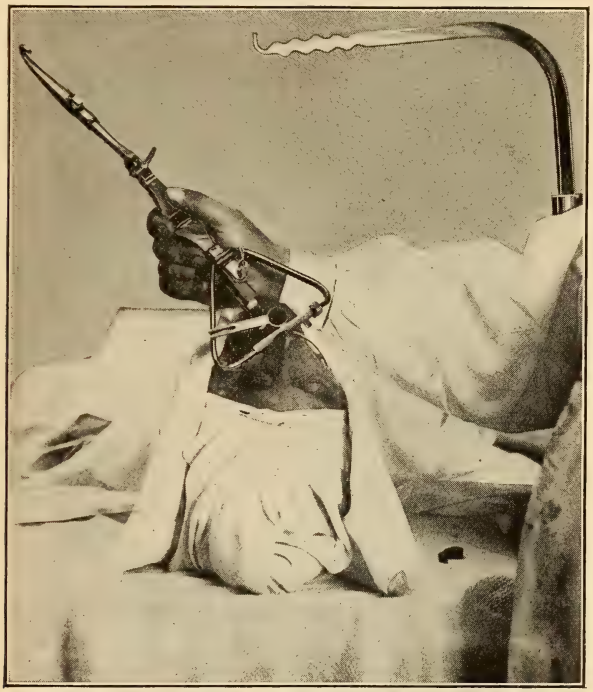

Fig. 544.—Hook tilted to left to remove right tooth-plate.

First.—The rough convex surface of the spatula will cause the tongue to be pushed into the mouth and thus prevent its being pinched by the teeth of the lower jaw.

Second.—The tip of the spatula can be guided in such manner as to prevent injury of the posterior wall of the pharynx; when the hypopharynx comes into view the tip of the spatula can be used to lift the tongue and see the epiglottis, and when this point is reached it is easier to actually place the tip of the spatula under the laryngeal face of the epiglottis than by the old method of following along the post pharyngeal wall. When the tip of the spatula has reached the laryngeal face of the epiglottis, if the proper length spatula has been selected, the tooth plates should be

ready to drop behind the teeth of the upper jaw. If all is in the middle line, the tongue should be in the center of the mouth and not in contact with the lower teeth. It may be best now to change hands, holding the hook in the left hand, and turning the screw, which opens the mouth gag of the hook, with the right hand. As the mouth gag opens, if the operator now sits upon a stool, by

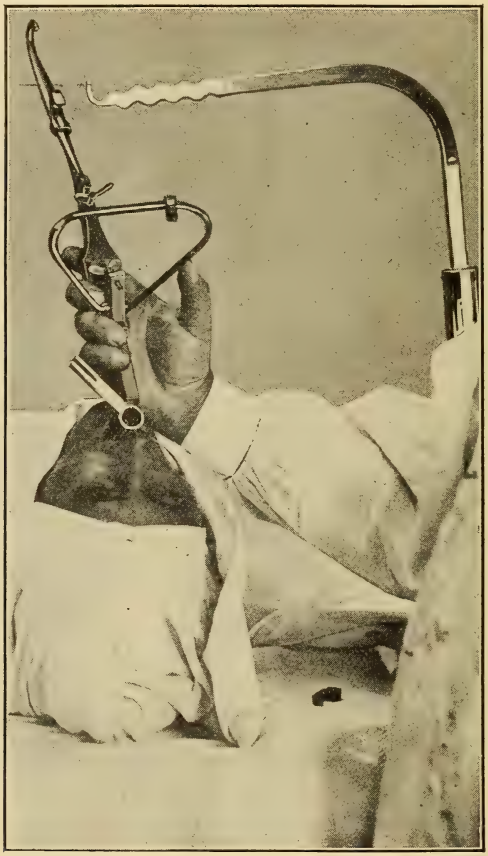

Fig. 545.—Elevation of ring, out of way of bronchoscope.

lifting the handle of the hook, or drawing it toward the head of the table or towards the operator, the larynx will frequently come into view. When the gag is opened to the full width through which it is intended to operate, the handle of the hook is placed upon the crane, and by gently elevating the crane and moving it gradually toward the head of the table, a clear view of the entire hypopharynx, mouth of esophagus and interior of the larynx can be seen. The assistant will now release the head, as the crane will maintain the position and serve its purpose. The mouth gag used

to open the mouth is removed and it will most often be found that the head, instead of swinging free of the table or actually being suspended, is resting firmly on the table, which means the tension is greatly reduced.

The relative position of the crane to head is somewhat different now to that which was at first employed; usually the crane

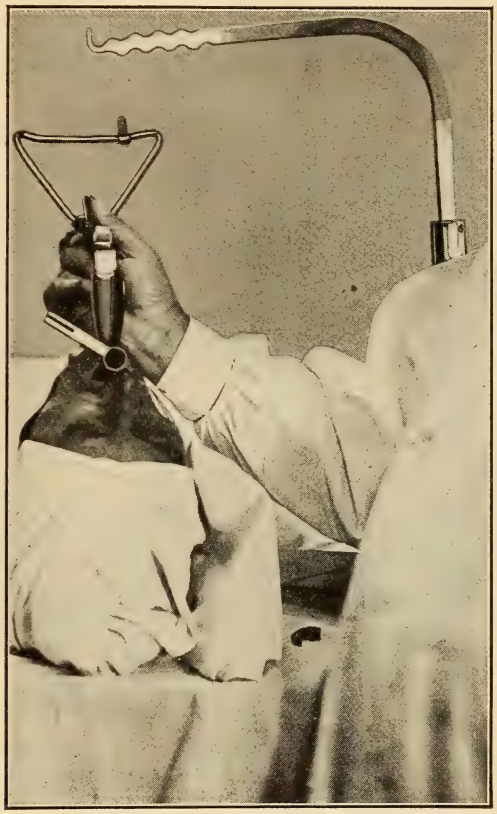

Fig. 546.—Removal of spatula.

will move from one-third to one-half its distance toward the head of the table, and will be found to be about on a level with the ear of the patient. Therefore, no extension of the table-top is needed.

By lifting the crane vertically the road to the larynx flattens or straightens out, and by moving the crane horizontally toward the head of the table the anterior commissure comes into view, and turning the screw of the pear-shaped ring forces the spatula deeper into the mouth, and turning the worm-gear joint on the handle of the hook, not only lifts the spatula, but elevates its tip. These movements form the necessary details in acquiring a proper view of the larynx.

Among the difficulties to overcome are the following: Occasionally the epiglottis will slip from underneath the spatula tip, particularly in children. This can be overcome either by turning the screw of the pear-shaped ring, thus lengthening the spatula, or by the employment of a longer spatula. Finally the epiglottis will be kinked or folded in front of the spatula, in which event its free edge will be crowded down into the cavity of the glottis; seriously interfering with the view and greatly disturbing the respiratory function. In order to correct this the operator must take the hook off the crane, close the mouth gag and tilt the handle of the hook

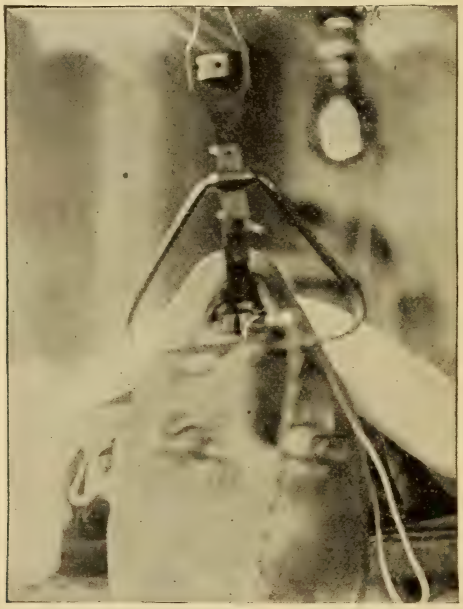

Fig. 547.—Interior of larynx, showing vocal cords in direct view.

toward the foot of the table, thus relieving all pressure of the spatula from the epiglottis, which will then return to its normal position. The gag is then reopened and the handle tilted toward the head of the table.

The most formidable difficulty, especially with beginners, is to keep the tongue in the median line. Whenever this occurs the operator should repeat the procedure about as follows: Close the gag, tilt its handle toward the foot of the table and then take the pear-shaped ring and with it move the spatula from side to side until the tongue is forced into the middle line, after which the gag is reopened rapidly and the tongue is held in the desired position. The operator is also cautioned not to permit laceration of the tongue by allowing it to become engaged between the spatula and the teeth of the lower jaw. The reason for insistence that the

tongue be maintained in the middle line is that otherwise prolonged tension is liable to produce tearing of the anterior pillar of the tonsil or submucous hemorrhage.

Fracture of the teeth or of the alveolus no longer occurs since the adoption of the plan now permitting the head to rest upon the operating table. This relieves practically all of the tension and pressure upon the upper teeth. When properly employed suspension laryngoscopy should never induce edema of the epiglottis or of the glottis. It occasionally happens that the spatula selected is too long, in which event it is liable to pass down behind the larynx and come into contact with the esophageal surface of the cricoid

a *b*

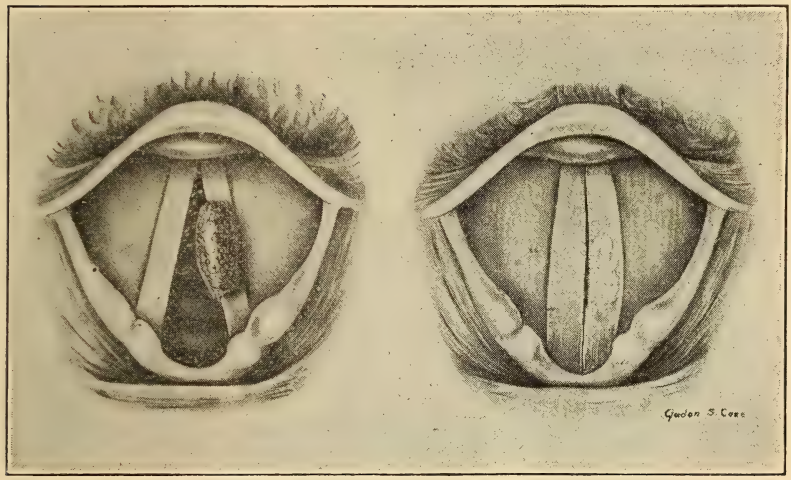

Fig. 548.—*a*, Papilloma of vocal cord; *b*, complete removal by dissection.

cartilage. At this point when a handle of the hook is pulled toward the operator the patient will probably stop breathing for the reason that this particular procedure closes the larynx tightly. Whenever this occurs the spatula should be speedily removed and respiration re-established before repeating the suspension procedure. Respiration is naturally choked off as a result of pushing of a mass of mucous membrane over the cricoid cartilage.

Another danger arises from any collection of fluid in the nasopharynx or larynx during the procedure, whether vomited material or merely an accumulation of mucous secretion. In order to avoid this danger a suction apparatus should be constantly at hand and all secretions removed; more particularly these secretions should be thoroughly pumped out just before the patient is taken down or the hook removed. Even after the hook is removed from the mouth a gag should be kept in and all secretion removed from the mouth and pharynx until the pharyngeal reflexes have returned.

Suspension laryngoscopy is inapplicable only in cases where it is found impossible to convert the spaces from the upper teeth to the base of the epiglottis into a straight line. As a matter of fact, such a possibility is a rare occurrence.

THE VALUE OF SUSPENSION LARYNGOSCOPY, ITS USES AND LIMITATIONS.

The diagnostic value of suspension laryngoscopy,[1] on account of the direct view thus obtained and the consequent direct approach to the operative field, establishes its usefulness beyond all

a *b*

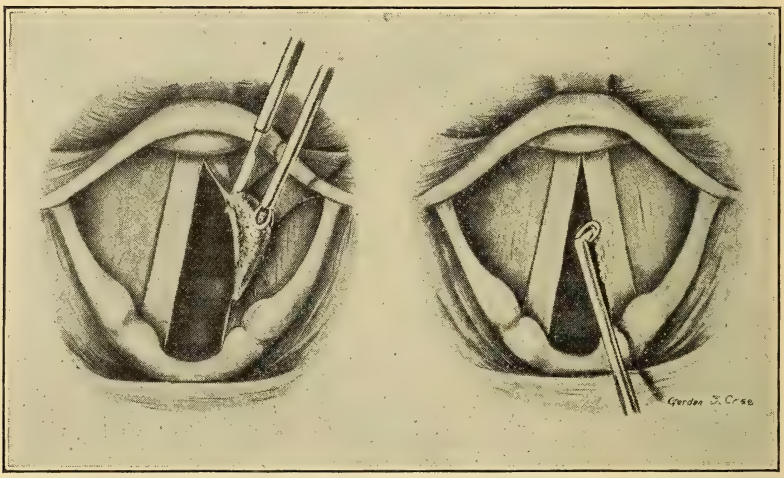

Fig. 549.—*a,* Technique of dissection; *b,* nodule forceps in place for vocal nodule removal.

doubt. Aside from the direct view and direct access to the operating field, the fact that it permits the operator the use of both hands is of extreme value. For instance, in the diagnosis of tumors, suspension permits the two-handed palpation carried out in a delicate and accurate manner. At the same time the color, vascularity and probable point of attachment of all tumors, together with their size, consistency and actual point of origin are easily obtainable. Furthermore, the extent of involvement and amount of induration can be determined under two-handed manipulation. These facts are of vital interest to the surgeon in determining the type of operative procedure best suited to the individual case. Suspension affords such a wide field of direct observation that it is often possible to differentiate types of the various growths which appear upon the vocal cords and subglottic regions. In this manner the various benign neoplasms like fibroma (Fig. 550), papilloma (Fig. 548),

[1] Annals of Otology, Rhinology and Laryngology, June, 1920.

singers' nodules (Fig. 549), lipoma, myxoma or retension cysts may be differentiated. In like manner ulcerations of the larynx, whether tuberculous, syphilitic or malignant, can be plainly seen and often differentiated.

Suspension is especially valuable in outlining and determining the extent of infiltration and involvement of malignant growths. Lynch affirms his belief that in cases where a malignant growth affects only the anterior two-thirds of one vocal cord, without involvement of the perichondrium of the thyroid cartilage, such

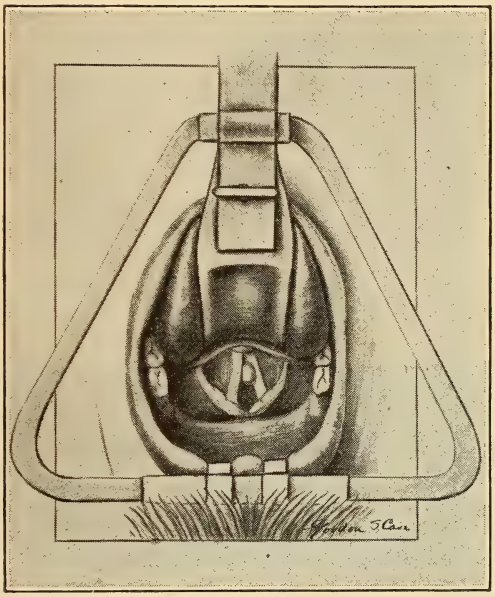

Fig. 550.—Angiofibroma of vocal cord as seen through suspension laryngoscopy.

cases are suitable for removal by suspension. He reports nine such cases, without recurrence.

Suspension also furnishes the simple means of viewing the larynx in acute conditions, particularly in children. For instance, the differential diagnosis of subglottic laryngitis and laryngeal diphtheria is feasible by this method, with the additional advantage that if intubation is necessary it can be accomplished accurately under suspension.

The diagnosis and treatment of vocal nodules is entirely feasible by means of suspension. Ulcers, polypi, pedunculated tumors, webs, tags, and the lodgment of foreign bodies are brought into view through suspension. Meanwhile, under suspension the entire pharynx, larynx and upper end of the esophagus are not only under direct view but permit two-handed deliberate palpation.

The development of suspension laryngoscopy by making possible the two-handed surgery of these regions has aided materially the skillful surgery of these parts as compared with the more difficult one-handed procedure by means of reflected light.

Fig. 551.—*A,* Section of vocal cord showing papilloma. *B,* Showing papilloma dissected from underside of cord.

In short, it is applicable to all benign pedunculated tumors to which the larynx is liable at any age. All foreign bodies lodging

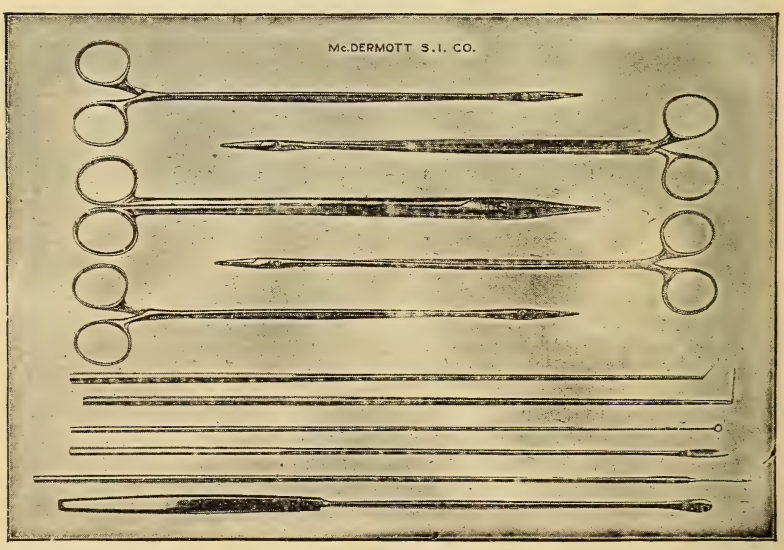

Fig. 552.

within view are easily removed, even though more or less impacted. The cautery can likewise be applied to any necessary extent and in special conditions stitches can even be taken and plastic flaps constructed and sutured.

Suspension laryngoscopy furnishes an ideal method for direct intubation and the spatula is quite essential in the passage of bronchoscopes in infants and young children. Suspension is the most feasible of all methods in the work on stenotic larynx and trachea cases, in that it permits of accurate dilatation, cauterization, incision of webs and when dilating from below upwards it holds the parts well in view and enables the operator to make sure that no false passage is made. Finally, it furnishes an adaptable method for the employment of radium in esophageal and laryngeal malignancy.

CHAPTER LIII.

DIRECT LARYNGOSCOPY, BRONCHOSCOPY AND ESOPHAGOSCOPY.[1]

History.—As early as 1807 attempts were made to examine the esophagus endoscopically. The early attempts were not successful, and it was not until 1896 that Mikulicz reported that he had successfully explored the esophagus by means of straight tubes. In 1897 both Kirstein and Killian succeeded in examining the larynx and trachea, and the latter succeeded in removing a foreign body from a bronchus. Killian then turned his attention to bronchoscopy and was finally able to perfect the technique of the direct examination of the air passages. In 1902 Einhorn devised an instrument for the direct examination of the esophagus, having an auxiliary tube in the wall of the main tube for the purpose of carrying a light carrier, which places the lamp at the end of the tube. In 1904 Ingals, of Chicago, used a separate light carrier in the Killian tube, and in this way successfully removed a pin from the bronchus of a woman. In 1905 Dr. Chevalier Jackson, of Pittsburg, perfected an instrument for the purpose of examining the trachea and bronchi, in which he embodied the straight tube of Killian, together with the light carrier used by Einhorn. It is this instrument, with slight modification, which he uses today, and which will be referred to in the balance of this chapter.

During the past seventeen years the direct examination of the air passages has made rapid strides throughout America and other countries, and many laryngologists are using these tubes with success. For this reason it is fitting that a chapter of this book should be devoted to a more or less detailed description of the instruments and the technique employed.

DIRECT LARYNGOSCOPY AND BRONCHOSCOPY.

By *direct laryngoscopy* is meant the inspection of the larynx through a straight tube, in contradistinction to examination by the reflected image on a mirror held in the pharynx. The same definition applies to *direct tracheoscopy* and *tracheobronchoscopy.* Tracheoscopy and tracheobronchoscopy may be divided into two classes, upper and lower. By upper bronchoscopy and tracheoscopy is meant the inspection of these structures through a tube inserted by way of the natural passages. By lower bronchoscopy is meant an inspection carried on through tubes inserted into a tracheotomy wound.

---

[1] The author is indebted to Dr. Chevalier Jackson for his coöperation in the revision of chapters liii and liv.

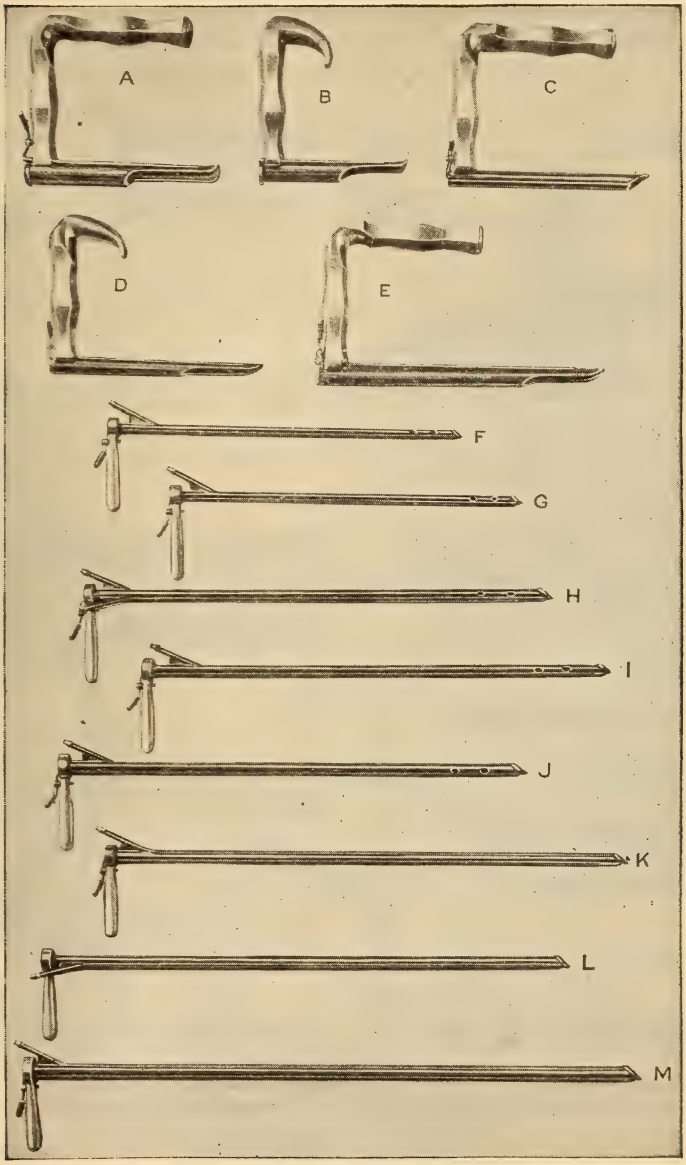

Fig. 553.—Chevalier Jackson's laryngoscopes, esophagoscopes and bronchoscopes. This illustration includes the essentials for an ordinary working set of endoscopic instruments. All the tubes are furnished with an extra light carrier and two extra lamps. The instruments are illuminated from a special triple circuit dry cell battery. None other should be used. These instruments are made by Charles Pilling and Sons.

The instruments used at the present time may be divided into two classes, according to whether the light is reflected from a source without the tube, or whether it is carried by means of light carriers to the distal end of the tube. As a type of the former

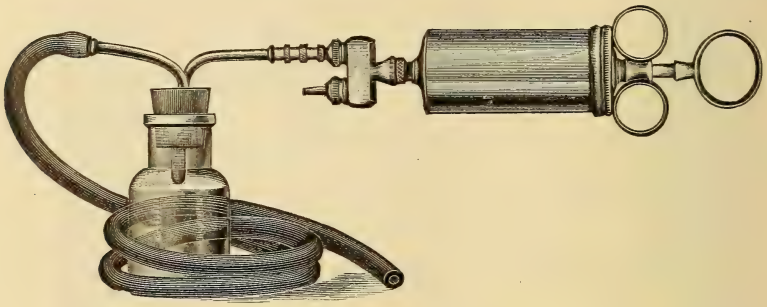

Fig. 554.—Jackson's secretion aspirator with plus pressure for cleansing clogged aspirating canals. Where portability is not required, the Robertson motor aspirator is better.

class may be taken the tubes devised by Killian, which consist primarily of a heavy handle carrying a lamp and a tube spatula through which secondary tubes are telescoped. Of the tubes in

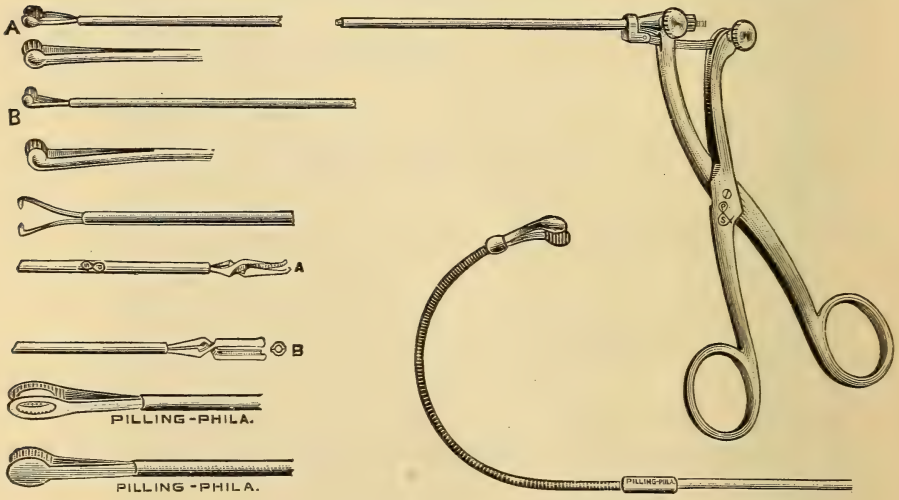

Fig. 555.—Jackson's foreign body forceps and other instruments for the removal of foreign bodies.

which a light is carried to the distal end by means of a light carrier, Jackson's are the most perfect type, and will hereafter be referred to in these descriptions.

They are made of various sizes. An ordinary working set is shown in the illustration on preceding page (Fig. 553).

The bronchoscopic tubes are made in two styles, one of which carries, in addition to the light carrier, a secondary drainage tube to which an aspirator may be attached for the purpose of removing excessive secretion, pus, or blood, from the field of examination. The aspirator consists of an aspirating syringe and bottle connected with the drainage tube by means of rubber tubing (Fig. 554).

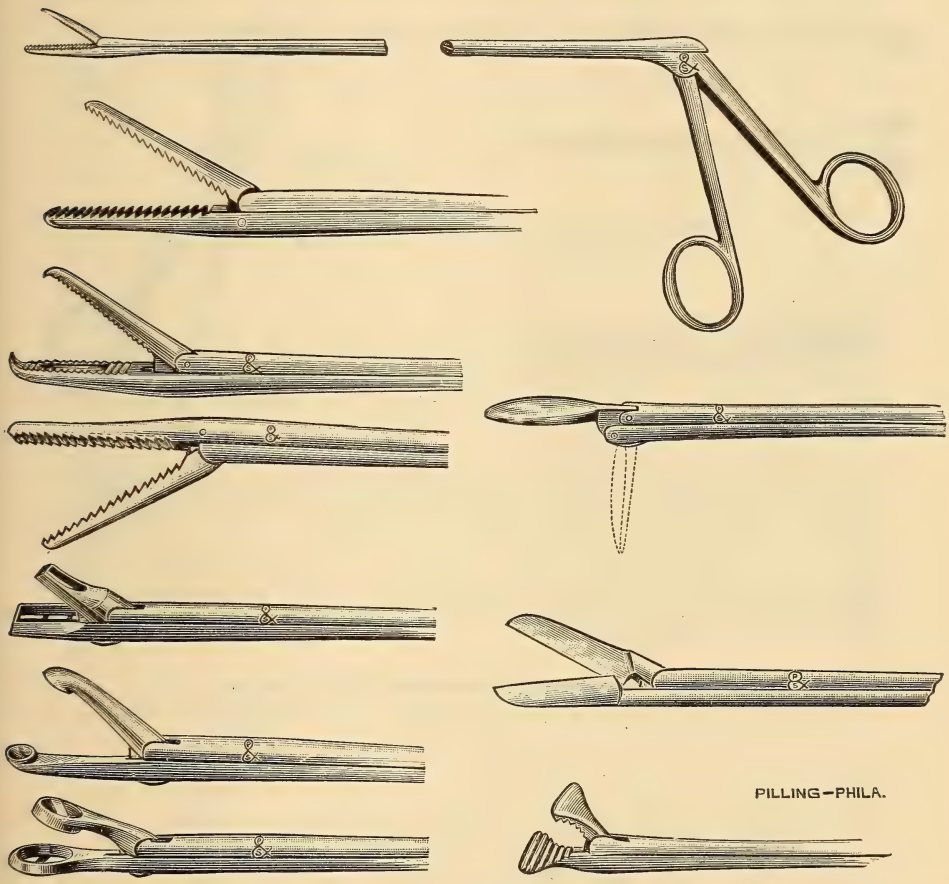

Fig. 556.—Chevalier Jackson's laryngeal operating instruments. The illustrations are enlarged about 4 diameters.

In addition to these tubes one must have various forms of forceps for the removal of foreign bodies. Those of Jackson (Fig. 555), Tucker (Fig. 557), and Mosher (Fig. 558), are admirably adapted for the removal of foreign bodies. One must also be equipped with various hooks, a safety-pin closer (Fig. 559), eyeglasses for the protection of the operator's eyes, and about a dozen sponge holders (Fig. 560).

One never should attempt to do bronchoscopy without having at hand a tracheotomy set, for the reason that it may become necessary at any time to perform a rapid tracheotomy, not because of the bronchoscopy but because of the conditions for which it is done.

Extra lamps are also essential. For the purpose of supplying light a triple circuit dry cell battery is necessary, and commercial

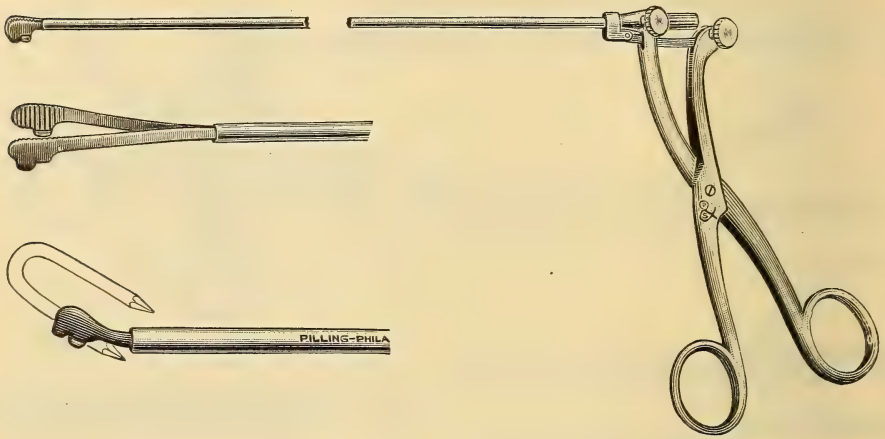

Fig. 557.—Gabriel Tucker's tack and pin forceps. The little lugs prevent loss of the pin and help bring it in line with the tube-mouth. The lower illustration shows the Tucker staple forceps.

lighting circuits should not be employed for light supply. The batteries are equipped with three cords, one of which can be attached to the laryngoscope while another is attached to the bron-

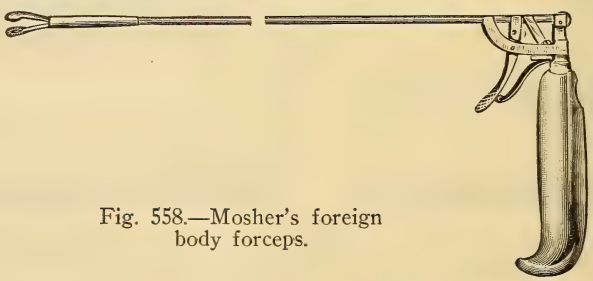

Fig. 558.—Mosher's foreign body forceps.

choscope, the third cord and its batteries constituting a reserve circuit.

Technique.—The first essential in the technique of bronchoscopy, as in most modern surgical procedures, is a rigid maintenance of asepsis. If time will permit the patient should be prepared by gentle catharsis, the mouth should be carefully cleansed and no food should be given for six or eight hours prior to the

introduction of the tubes, in order to prevent vomiting. The patient, the operator and all assistants should wear sterile caps and gowns, whether the operation be performed in the sitting posture or in dorsal decubitus. With the exception of batteries, light carriers, cords and the rubber portion of the apparatus, the instruments may be boiled. The lamps, rubber tubing and light carriers may be immersed in alcohol.

Anesthesia.—For direct laryngoscopy in children, from a newborn infant to a child of ten years, no anesthetic, general or local, is required; and every laryngologist should be able thus to examine the larynx of children. For bronchoscopy in children, no

Fig. 559.—Mosher's safety-pin closer.

anesthetic, general or local is required by many operators; but in children entirely free from obstructive laryngeal dyspnea there is no objection to ether if the operator prefers to use a general anesthetic. Chloroform is dangerous. When no anesthetic is used a sedative, such as bromide of sodium, may be given three hours before the endoscopy; or, better, a full dose of morphine guarded with atropin may be given an hour and a half before. "The cough reflex is the watch-dog of the lungs" (Jackson), therefore excessive dosage should be avoided. Morphine is less objectionable in this respect than ether. For direct laryngoscopy and bronchoscopy in adults the local application of cocaine, preceded by morphine hypodermatically, is sufficient for all purposes. The

Fig. 560.—Coolidge's sponge holder. (Modified by *Jackson.*)

morphine should be guarded with atropin and should be given at least an hour and a half before the laryngoscopy is to be done. A 4 per cent. solution should first be applied to the pharynx and larynx, and 20 per cent. to the trachea and bronchi. The application of cocaine to the pharynx and larynx is made before the insertion of the laryngoscope, preferably by means of tiny folded gauze sponges held in the Sajous cotton-holding forceps (Fig. 561,) which prevents the possibility of the sponges becoming detached in the larynx. If care is taken to apply the swabs to the region of the superior laryngeal nerves, no endolaryngeal application will be necessary.

After the thorough cocainization of the larynx the laryngoscope (Fig. 553) is introduced, and the further cocainization of the trachea and bronchi is carried out by means of small pledgets

of gauze passed through the laryngoscope and bronchoscope, on sponge carriers. These gauze sponges are made for the trade by Messrs. Johnston and Johnston, of New Brunswick, N. J.

DIRECT LARYNGOSCOPY AND BRONCHOSCOPY WITH THE PATIENT IN THE SITTING POSITION.

The sitting position is objectionable because of the lessened control of the patient and the opposition of gravity in the removal of secretions and foreign bodies. Before proceeding to the description of the technique of the procedure itself, too much stress cannot be laid on the necessity of adhering to every detail of the position of the patient and assistants, and to the arrangement of instruments. Care should be taken to see that the lamps are in perfect working order, and that the batteries and cords are properly adjusted. The patient is seated on a low stool, the second assistant being seated on a higher stool directly behind the patient. The instrument table should be to the patient's left, and the operator should stand in front. The first assistant stands to the right of the operator in order to be convenient to hand the operator

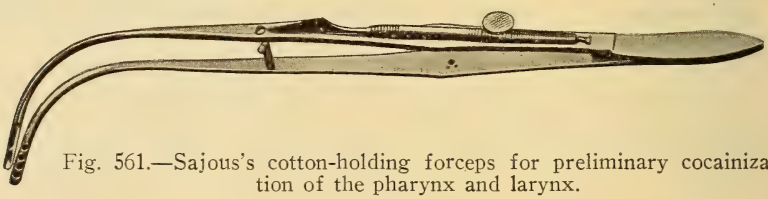

Fig. 561.—Sajous's cotton-holding forceps for preliminary cocainization of the pharynx and larynx.

the instruments required, always in a position for insertion. The nurse should be stationed behind the instrument table, and it is her duty to change the sponges and keep the instruments properly arranged so that the first assistant shall have no difficulty in rapidly picking them up. The batteries should be placed to the patient's right on a stool of convenient height. The duties of the second assistant are extremely important. He must hold the patient's head bent backward, with the trunk, and especially the neck, pushed forward, the extension being as much as possible in the region of the occipito-atloid joint. At the same time he holds the mouth widely open with the bite-block.

The lights having been adjusted to the proper brilliancy, and the field having been anesthetized, the laryngoscope is inserted until the epiglottis appears. In doing this it is necessary to hold the patient's upper lip out of the way to avoid pinching it between the instrument and the upper teeth. After the epiglottis comes into view, the flat end of the speculum is passed beyond it about one centimetre. And now comes the only point where difficulty in manipulation is encountered. Care must be taken not to pass the speculum too deeply, otherwise it will pass beyond the larynx into the esophagus. When traction is then made forward the patient's respiration will be stopped by occlusion of the orifice of

the larynx. Having passed the flat end of the speculum one centimetre over the upper end of the epiglottis, this structure and the hyoid bone must be drawn forward strongly out of the line of vision. This pressure is made by the end of the speculum and in doing so care must be taken not to use the upper teeth as a fulcrum. A beginner is very liable to pass the speculum into the esophageal orifice instead of into the larynx, and the bronchoscope may even be passed far into the esophagus. This is very frequently followed by a gush of fluid, even if nothing has been taken into the stomach for many hours. After a little experience one can readily tell by the respiratory sounds whether the spec-

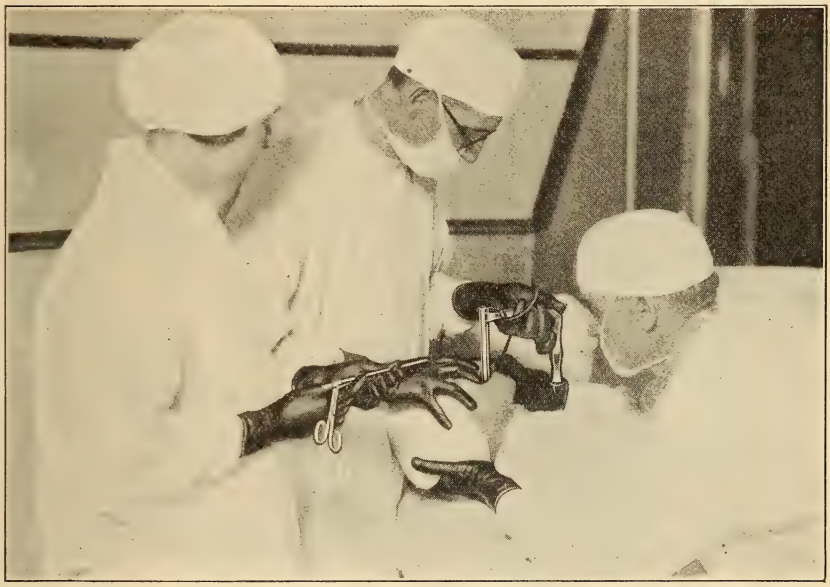

Fig. 562.—Direct laryngoscopy, recumbent patient. The laryngoscope is held in the *left* hand. The first, second and third fingers of the *right* hand are used to pull down the upper lip of the patient so as to avoid pinching it between the instrument and the upper teeth. The forceps are being held in proper presentation by the nurse. If bronchoscopy were contemplated, she would be thus holding the bronchoscope (with handle to the right and cord attached) instead of the forceps.

ulum is in the esophagus or in the larynx. When the speculum is properly placed in the laryngeal orifice the operator can usually feel the impact of the patient's breath against his face. Coughing is frequently a troublesome complication at this time, and unless the operator wears glasses to protect his eyes he is liable to have considerable difficulty. A very clear view of the vocal cords and larynx can now be obtained, but the appearance is very different from the mirror image. The cords show thick and red. Their recognition requires much practice, because they appear so different from the false appearance in the mirror.

If it is desired to explore the tracheobronchial tree the bronchoscope, with a second cord from the battery attached, is now passed through the slide laryngoscope beyond the cords and into the trachea. The sliding portion of the laryngoscope is then removed and the handle readily comes away, leaving the light, delicate bronchoscope in position.

DIRECT LARYNGOSCOPY AND TRACHEOBRONCHOSCOPY, DORSAL DECUBITUS.

This is the position of choice. In performing these procedures in the dorsal position the arrangement of the assistants and

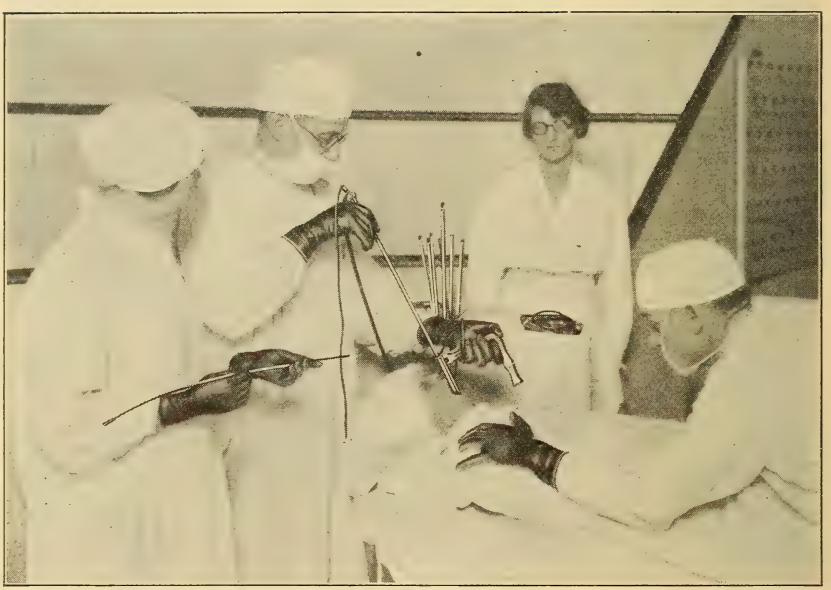

Fig. 563.—Insertion of the bronchoscope. Note direction of the trachea as indicated by the bronchoscope Note that the patient's head is held above the level of the table. The assistant's *left* hand should be at the patient's mouth holding the bite-block. This is removed and the assistant is on the wrong side of the table in the illustration in order not to hide the position of the operator's hands. Note the handle of the bronchoscope is to the right. (In the correct position the bite-block is held on the assistant's *right* index finger as shown in Fig. 568.)

instruments is somewhat different (Fig. 568). The second assistant sits on a high stool at the head of the table, with his right arm back of the patient's neck, and with his right hand he maintains the bite-block within the patient's mouth. His left hand supports and controls the patient's head from underneath, the hand resting upon his own knee, which is elevated to the proper height by a footstool the height of which depends upon the height of the table. In this position the second assistant can do his duty with-

out undue fatigue during a prolonged search or operation. It is absolutely essential that the second assistant shall make himself comfortable, as his work is extremely fatiguing.

The process of anesthesia, if local anesthesia is used, is precisely that described under bronchoscopy in the sitting position. General anesthesia, if used, is administered by insufflation through the auxiliary tube of the bronchoscope, or is applied intermittently on a gauze pad held over the proximal tube mouth. The laryngoscope is passed at the side of the tongue and the epiglottis is

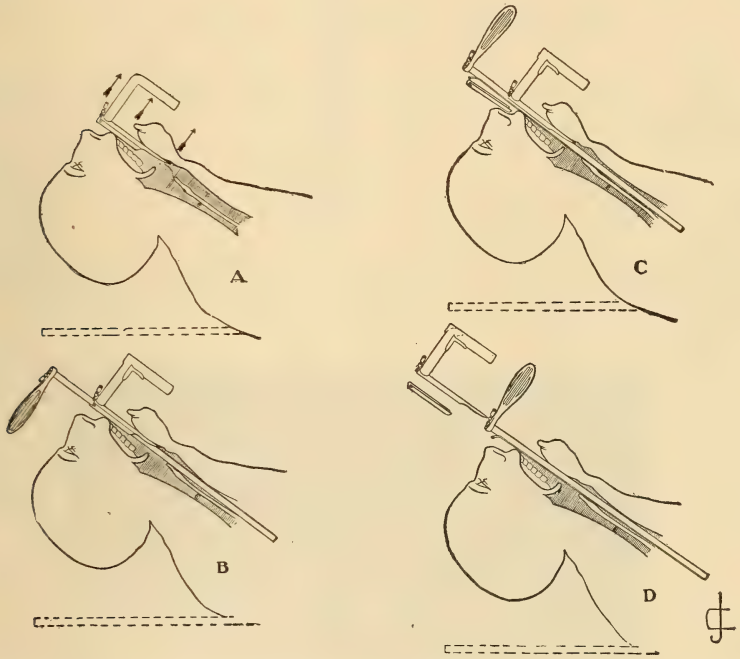

Fig. 564.—Schema illustrating oral bronchoscopy. The portion of the table here shown under the head is, in actual work, dropped all the way down perpendicularly. It appears in these drawings as a dotted line to emphasize the fact that the head must be above the level of the table during introduction of the bronchoscope into the trachea. *A,* exposure of larynx. *B,* bronchoscope introduced. *C,* slide removed. *D,* laryngoscope removed leaving bronchoscope alone in position. The handle of the bronchoscope should be out toward the observer, that is out horizontally to the right of the patient.

brought into view. The lip of the laryngoscope is passed one centimetre deeper and posterior to the tip of the epiglottis. Then the head of the patient is lifted on the tip of the laryngoscope, as shown at *A,* Fig. 564. After the glottic aperture is in view the operator waits until the patient takes a deep inspiration, when the cords will be seen to separate, and if it is desired to pass the bronchoscope this may be readily inserted between them. For

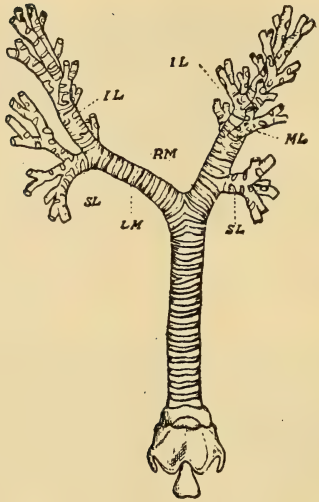

Fig. 565.—Tracheobronchial tree. *LM,* Left main bronchus. *SL,* Superior lobe bronchus. *ML,* Middle lobe bronchus. *IL,* Inferior lobe bronchus. (*Jackson,* with permission.)

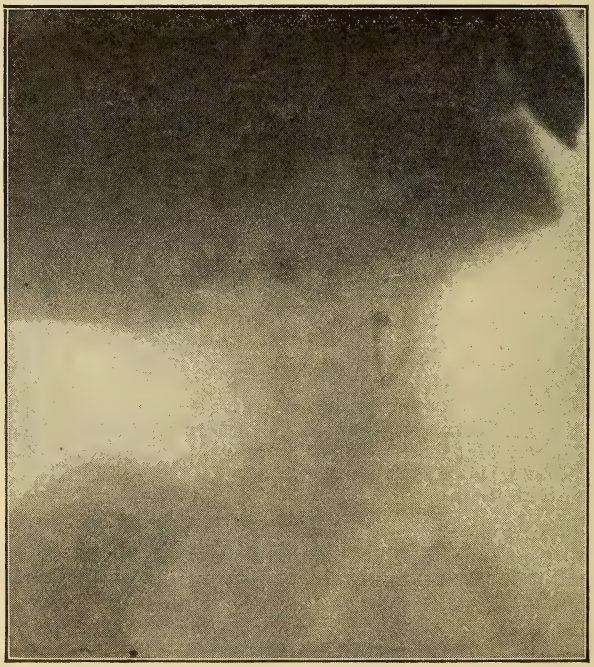

Fig. 566.—Skiagraph of a safety pin embedded in the larynx. (Author's collection.)

operative work upon the larynx the anterior commissure laryngoscope is best adapted.

In inserting the bronchoscope through the laryngoscope both lights should be on and the bronchoscope passed between the cords under the direct inspection of the eye. In case a foreign body obstructs one bronchus care must be taken, in passing the bronchoscope into the obstructed bronchus, not to shut off the supply of air to the other bronchi. This is usually taken care of automatically by the lateral apertures in the wall of the bronchoscope.

LOWER TRACHEOBRONCHOSCOPY.

Lower tracheobronchoscopy is now rarely used except for exploration of the conditions present in cases already tracheotomized for diseased conditions. All bronchoscopic manipulations are more easily carried out through the mouth than through the neck with the chin in the way. If it is desired to do a tracheotomic bronchoscopy a *low* tracheotomy is performed in the ordinary way (Chapter XXXI), and before attempting to pass any tubes all bleeding must be stopped and the trachea thoroughly cocainized, if the patient is an adult.

In doing this operation it is essential that strict asepsis should be carefully observed. If the operation of lower tracheobronchoscopy is satisfactorily accomplished, and there is no further use for the tracheotomy wound, it should not be stitched completely, but the central portion should be packed with gauze to insure perfect and permanent healing by granulation from below. During convalescence the wound in the trachea should occasionally be inspected by means of upper tracheoscopy.

A semidiagrammatic illustration of the subdivisions of the bronchi is shown in Fig. 565.

The skiagraph furnishes invaluable information regarding the location, size and shape of the foreign bodies lodged in the upper respiratory tract and the esophagus and even non-opaque foreign bodies can be localized by the obstructive emphysema or other pathologic changes they produce. The appearance of a safety-pin imbedded in the larynx is shown in Fig. 566.

CHAPTER LIV.

ESOPHAGOSCOPY.

For the details regarding the gross anatomy of the esophagus the reader is referred to treatises on anatomy. For our purpose it is necessary to give only such points as must particularly be borne in mind regarding the introduction of rigid, straight tubes into and throughout its lumen.

The variations both in length and the diameter of the lumen of the esophagus are so great not only in different individuals, but in the same individuals at different times, that it is impractical to enter into a detailed discussion of them. It is, however, important in this connection to bear in mind the four points of constriction in the lumen.

The most important constrictions, named in the order of importance, are: 1, cricoid (the first from above downward at the introitus, opposite the intervertebral disk between the fifth and sixth cervical vertebræ); 2, diaphragm (the fourth from above downward, the hiatus, at the exit of the esophagus through the diaphragm); 3, aortic (the second from above downward, corresponding to the arch of the aorta, opposite the fourth thoracic vertebra, back of the manubrium of the sternum), and 4, left bronchus (the third from above downward, corresponding to the left bronchus in front of the esophagus, at the level of the fifth thoracic vertebra).

All of these constrictions are more or less distensible, the first, or cricoidal, being the least so. While the extreme elasticity of the walls of the esophagus in the normal adult permits of stretching to over two centimetres without rupture, it is sufficient to bear in mind that rigid tubes and bougies of the following sizes should pass freely, and that failure to pass such instruments should direct the attention to the fact that if the instrument is properly directed and the patient is in proper position a stricture, spasmodic or anatomic, exists:—

Rigid tubes	Adults	9 mm.
	Infants and children up to ten	7 mm.

Esophagoscopy signifies the direct examination of the esophagus by means of tubes introduced through the mouth. The operation should be preceded by a thorough and careful examination of the larynx and pyriform sinuses with the mirror.

Position of the Patient.—This is of the utmost importance. A faulty position may render esophagoscopy impossible. The sitting position has many disadvantages. The Boyce position shown in Fig. 568 is the ideal one. It is essential to remember the high-

DESCRIPTION OF FIGURE 567.

A. Influenzal tracheobronchitis simulating diphtheria in a child aged two years. Antitoxin had been given because of the erroneous diagnosis. The direct laryngoscope reveals the swollen subglottic tissue that produces the croupy cough and the stenosis in laryngeal diphtheria; but there is no membrane or erosions on the intensely inflamed, slightly cyanotic mucosa.

B. Cancer of the esophagus as seen through the esophagoscope in a man aged fifty-five years, referred to the Bronchoscopic Clinic by Dr. Stengel. The fungations were nipped off, and, on histologic examination, confirmed Dr. Stengel's clinical diagnosis of cancer.

C. A typical endoscopic picture of chronic bronchitis after removal of collected secretions. The patient is recumbent. The upper orifice is that of the middle-lobe bronchus. The lower two-thirds of the drawing represents the view into the lower-lobe bronchus with subdivisions deep in the lower lobe. The branch-bronchi give off dorsal and ventral branches below the orifices shown. The thickening of the dividing spurs usually accompanies chronic bronchitis.

D. Papillomata on the left side of the fauces of a child aged two years. These faucial growths appeared after the removal of the recurrent multiple laryngeal papillomata from the larynx shown in illustration *E*. The appearance of new growths at so remote a location indicates the sad mistake of ruining a child's larynx in the attempt to prevent laryngeal recurrence by radical removal of the normal tissue underlying the base of the growths in the larynx.

E. Direct laryngoscopic view of a mass of laryngeal papillomata overhanging the glottis of a child aged two years. The dropping of the mass into the larynx on inspiration caused the cyanosis of the mucosa. The croupy cough and the dyspnea led to an erroneous diagnosis of diphtheria, for which antitoxin had been given. Removal of papillomata from the larynx is followed for a time by local repullulations and new growths at new locations (see illustration *D*); but repeated superficial removals will result in a cure with perfect voice. Radical local removal will not hasten the cure and will ruin the voice.

F. An aspirated piece of bone wedged in the right bronchus of a woman aged forty-four years. The bone produced the diagnostic asthmatoid wheeze. Bronchoscopic removal of the bone required thirty-five seconds and was immediately followed by disappearance of the asthmatoid wheeze.

G. Bronchoscopic view of a fistula leading to an old pulmonary abscess, not of foreign body origin, in a man aged fifty years. Bubbles of pus were coughed out of the orifice of the fistula just before the image here shown was mentally recorded by the bronchoscopist. The granulations here seen lined the fistula leading to the abscess, the "cavity" of which was filled completely, not simply lined, with mushy granulation tissue.

H. Bronchoscopic view at the bifurcation of the trachea in a case of pulmonary tuberculosis. Pus is blown out of the right upper-lobe bronchus by cough. The thickened broad carina, the pale, anemic, cyanotic mucosa, and the visibility and dark color of the mucosal vessels are all characteristic of advanced pulmonary tuberculosis.

I. Esophagoscopic view of a blackened, corroded, open safety-pin in the esophagus of a child aged seventeen months. Had removal or pushing down been attempted by any blind method, such as with the Graefe basket, bristle probang, sound, or stomach-tube, the point of the pin would have produced a fatal perforation of the esophageal wall. With the esophagoscope approach under guidance of the eye insures safety, provided the utmost care is taken not to touch or override the pin with the tube mouth. Removed esophagoscopically without anesthesia, general or local, in one minute and fifteen seconds.

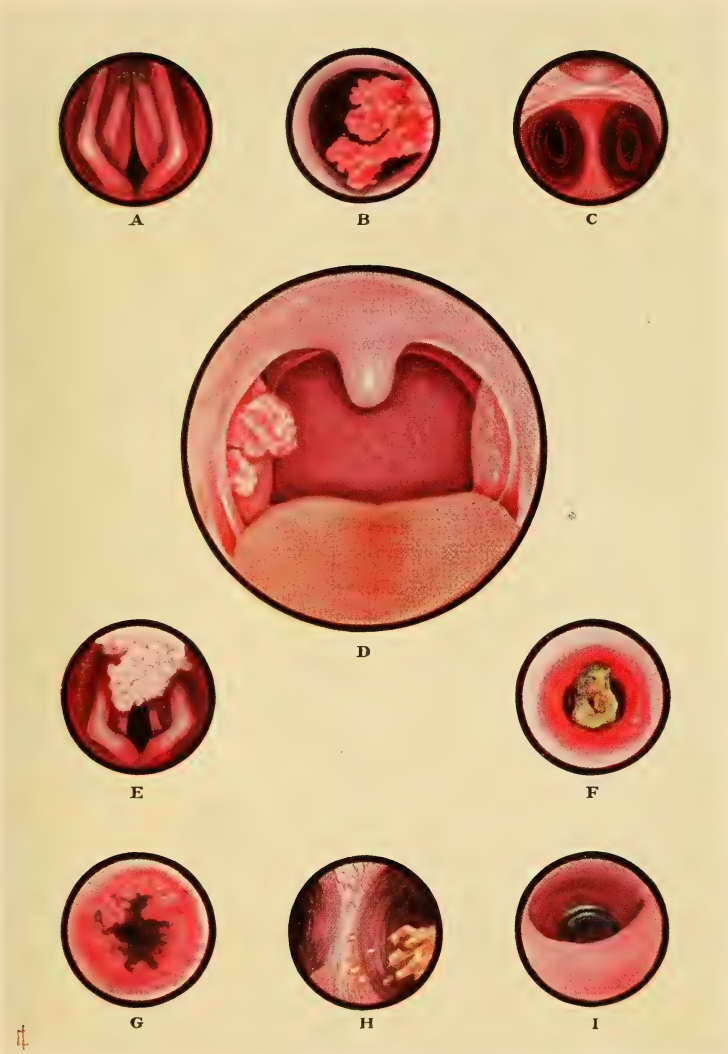

Fig. 567.—Photoprocess reproduction of a painting by Chevalier Jackson for Saunders' Clinics of North America. For description, see facing page.

low sequence[1] upon which successful esophagoscopy depends. The head must be out in the air beyond the table and supported in the hands of an assistant trained to the work.

Anesthesia.—For esophagoscopy in children no anesthetic, general or local is needed. General anesthesia introduces great danger in esophagoscopy unless the utmost care is taken not to block the air-way by compressing the trachea with the esophagoscope, or by displacement forward of the overridden foreign body. If the patient's head is held high above the level of the table, as it always should be during the passage of the retrotracheal esopha-

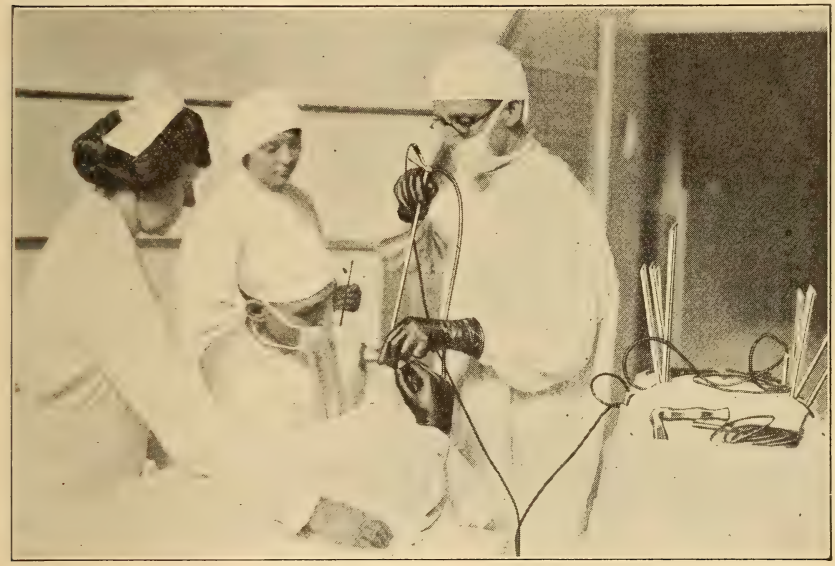

Fig. 568.—Esophagoscopy, "high-low" method, recumbent patient. The second assistant is sitting holding the head, his *left* forearm on his *left* thigh, his *left* foot on a stool whose top is 65 cm. lower than the table-top. His *left* hand is on the patient's sterile-covered scalp, the thumb on the forehead, the fingers under the occiput, making forced extension. The *right* forearm passes under the neck of the patient, so that the index finger of the *right* hand holds the bite-block in the *left* corner of the patient's mouth. The operator is using his left thumb to hold the patient's lip out of the way, while his second finger is inside the patient's teeth. The patient's head is 10 cm. above the table.

gus this accident will be avoided. In adults the application of a local anesthetic is more annoying to the patient than the passage of the esophagoscope without the local anesthesia. General anesthesia is not necessary for esophagoscopy in either adults or

[1] For the anatomical considerations on which this is based the reader is referred to Peroral Endoscopy and Laryngeal Surgery, by Chevalier Jackson. Textbook, 1914.

children, after skill is acquired; but the less experienced will find it a great help in passing the cricopharyngeal constriction.

Introduction of the Esophagoscope.—The easiest procedure is by Jackson's high-low method. The introduction may be divided into four stages, namely:—

1. Entering the right pyriform sinus.
2. Passing the cricopharyngeus.
3. Passing through the thoracic esophagus.
4. Passing the hiatus.

During the entire procedure the patient and second assistant are in the Boyce position (Fig. 568), the second assistant holding the bite-block. During the first and second and third stages the head is held high, in the fourth stage it is dropped until the occiput is slightly below the level of the table. Hence, the author has for convenience formed the habit of calling his method the "high-low" method of esophagoscopy.

Stage 1. Entering the pyriform sinus is readily understood by looking at the schema, Fig. 569. The collar of the tube is held

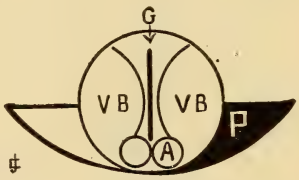

Fig. 569.—Schema for finding the pyriform sinus in the author's method of esophagoscopy. The large circle represents the cricoid cartilage. *G,* glottic chink, spasmodically closed. *VB,* ventricular band. *A,* right arytenoid eminence. *P,* right pyriform sinus, through which the tube is passed in the recumbent posture. The pyriform sinuses are the normal food passages. (From Jackson's "Bronchoscopy and Esophagoscopy," W. B. Saunders Co.)

lightly between the right thumb and fingers, and the tube-mouth, guided by the left hand, is inserted posterior to the dorsum of the tongue and with the proximal end high (Fig. 568). In passing the esophagoscope in the recumbent patient, the handle of the esophagoscope must always point toward the ceiling, in order to bring the lip of the esophagoscopic tube-mouth anteriorly, so as to ride over the cricopharyngeal fold. If the lip is posteriorward, perforation is possible if violence be used. The operator standing, his eye at the proximal tube-mouth seeks the right pyriform sinus (*P,* Fig. 569). The landmark is the right arytenoid eminence, which shows as a rounded mass rather larger than when seen by the indirect method. Great care must be taken to identify this arytenoid and to avoid hooking the tube-mouth over it or its fellow. This would prevent further insertion and if force were used the arytenoid mobility might be seriously injured. Having found the right pyriform sinus the tube glides in readily for two or three centimetres, when it comes to a full stop and the lumen disap-

pears. This is the spasmodically closed cricopharyngeal constriction. *During stage 1, or any of the other stages, the fingers are not inserted in the mouth, except so far as necessary for the "hooking" of the phalanges over the upper alveolus for fixation of the instrument.*

Stage 2. Passing the cricopharyngeus is, with the beginner, the most difficult part of esophagoscopy, especially if the patient is unanesthetized. Local anesthesia does not help much, if any. The cricopharyngeus as seen through the esophagoscope does not resemble the image seen in the speculum. It is simply a lost lumen. Only a solid wall of mucosa is seen. Force must not be used but a steady, firm pressure is made on the esophagoscope

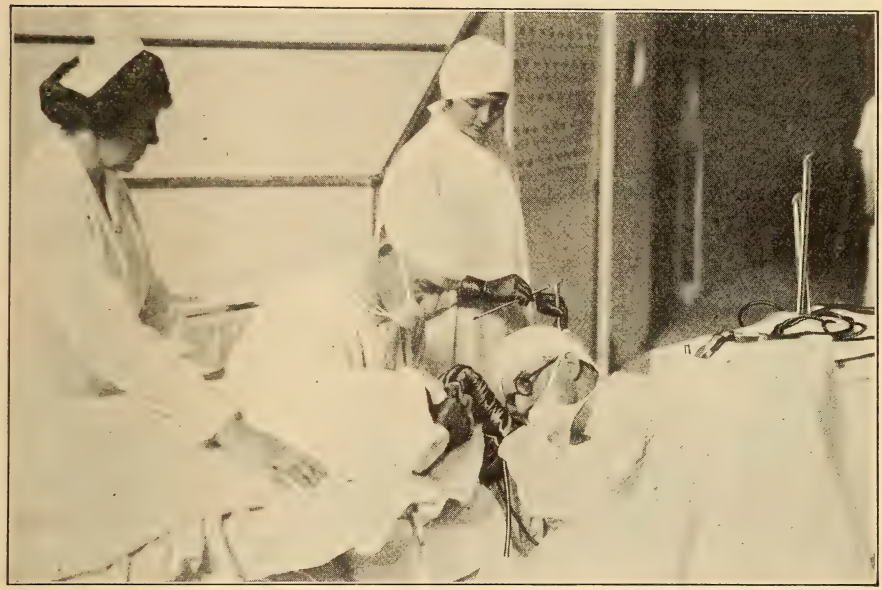

Fig. 570.—Esophagoscopy by the Jackson's "high-low" method. *Stage* 4. Passing the hiatus. The patient's vertex is about 5 cm. below the top of the table.

while a strongly anterior (lifting in the recumbent position) movement is imparted to the distal end of the esophagoscope by the left thumb. At the same time the lifting motion is imparted, the distal end should be guided slightly toward the middle line of the body. If the lumen is not seen, the patient should be told to take a deep breath when the lumen will usually appear. In an unanesthetized child the deep inspiration will soon be made involuntarily. A little patience here will always succeed; haste and force may be fatal. The author's slanted-end esophagoscope executes this second stage with the minimum of difficulty, the lip being insinuated upward and forward, and the handle being held sagittally and anteriorly. The lumen is a mere slit. The folds at the sides of the slit may seem to bulge toward the operator. In many instances

it is rosette-like in form with radial folds; and it varies with the instrument used. There is usually from 1 to 3 centimetres of this constricted lumen at the level of the cricopharyngeus and the subjacent orbicular esophageal fibres, after which the esophagoscope glides into the few centimetres of partially open cervical esophagus.

Stage 3. The esophagoscope usually glides easily through the normal thoracic esophagus. If it does not, the patient's position is faulty or the esophagoscope is rubbing on the upper teeth. The levels of the aorta and left bronchus are readily recognized by the impressions they make in the esophageal wall. After passing them the lumen of the esophagus seems to have more and more of a tendency to disappear anteriorly. This is the signal for lowering the head, which has till now been kept high, for the next stage.

Stage 4. Passing the hiatus is very easy after a little practice, if the directions here given are followed. It will be remembered

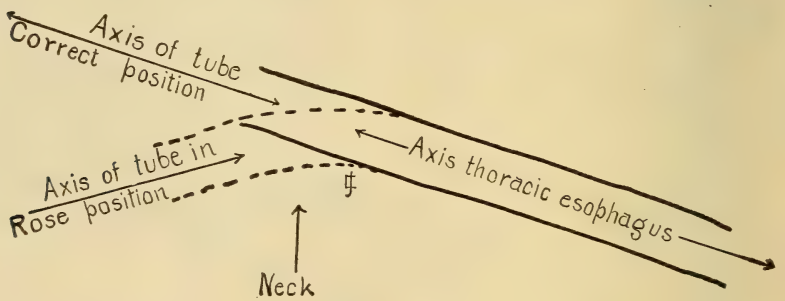

Fig. 571.—Schematic illustration of Jackson's "high-low" method of esophagoscopy. In the first and second stages the patient's head fully extended is held high so as to bring it in line with the thoracic esophagus, as shown above. The Rose position is shown by way of accentuation. (From Jackson's "Bronchoscopy and Esophagoscopy," W. B. Saunders Co.)

that the direction of the lower esophagus is anteriorly and to the left. To obtain this in the recumbent patient the head is dropped as shown in Fig. 570.

When the head is dropped it must at the same time be horizontally moved to the right (without rotation) in order that the axis of the esophagoscope shall correspond to the axis of the lower third of the esophagus which deviates to the left. The shoulders should also participate slightly in this movement. The hiatal constriction may assume the form of a slit or more commonly a rosette, and in its rosette form has often been mistaken by esophagoscopists for the cardia, leading to the erroneous idea of a sphincter at the cardia. If the rosette or slit cannot be promptly found, as may be the case in various degrees of diffuse dilatation, the tube-mouth must be shifted farther to the left, and also anteriorly. If the tube-mouth is centered over the hiatal constriction, moderately firm pressure continued for a short time will cause it to yield. Then the tube, maintaining its same direction will, without further trouble, glide into and through the abdominal esophagus.

The cardia will not be noticed as a constriction, but its appearance will be announced by the rolling in of reddish gastric, mucosal folds, and by a gush of fluid from the stomach.

The esophagoscope is extremely useful in skilled hands for the detection of disease and subsequent treatment. Stenotic conditions, whether due to spasm, cicatricial contractions, new growths in the esophagus or mediastinum or other causes, may be diagnosticated and surgical or therapeutic measures instituted for their relief, through the esophagoscope.

Diverticula are readily discovered and ulcers located and treated.

The diseases of the esophagus were little known and rarely successfully treated until esophagoscopy opened up this extensive field for clinical work.

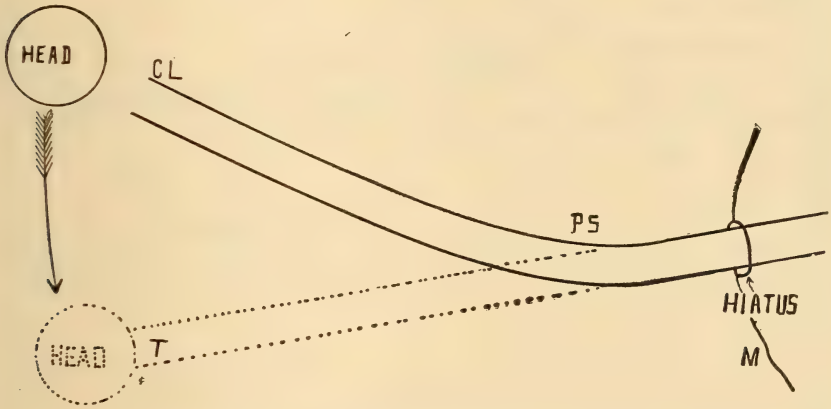

Fig. 572.—Schematic illustration of Jackson's "high-low" method of esophagoscopy, *fourth stage*. Passing the hiatus. The head is dropped from the position of the first and second stages, *CL*, to the position *T*, and at the same time the head and shoulders are moved to the right (without rotation) which gives the necessary direction for passing the hiatus. (From Jackson's "Bronchoscopy and Esophagoscopy," W. B. Saunders Co.)

Foreign bodies in the esophagus can be removed with the esophagoscope in close to 100 per cent. of the cases. External esophagotomy for foreign body is rarely, if ever, justifiable. A foreign body should not be seized and torn out at all hazards. Very careful examination and manipulation are necessary to avoid serious and fatal trauma. Often there is a complicated series of movements necessary for the disentangling, disimpaction, rotation or version of a foreign body before it can be safely withdrawn. The mechanical problems of removal, in a case such as a safety-pin, should be studied and worked out on the rubber tube, the cadaver and the dog, with a duplicate of the foreign body in the case, before removal from the patient is attempted. This is particularly true of infants and very young children in whom fatal trauma is readily inflicted.

EAR DEPARTMENT, MANHATTAN EYE AND EAR HOSPITAL.

101
℞
Dropper

102
℞
Acid. Boric.....ʒij

103
℞
Hydrogen. Perox.....ʒj
℞
Medicine Dropper
℞
Ear Syringe

104
℞
Enzymol.....ʒj

105
℞
Emuls. Codliver Oil

106
℞
Ol. Ricini.....ʒij

107
℞
Acid. Boric.....Gr. xx
Sol. Hydrarg. Bichl., $\frac{1}{1000}$...ʒj
Sp. Vini Rect.....q. s. ad ʒj
℞
Medicine Dropper

108
℞
Tab. Hydrarg. Bichl....Gr. j
No. 20
℞
Ear Syringe

109
℞
Hydrarg. Chlor. Corros.
Tablets.....Gr. j
No. 30

110
℞
Pulv. Ac. Boric.....ʒiv

111
℞
Ac. Boric.....Gr. xx
Alcohol (95%).....ʒj
Sig.: Ear Drops

112
℞
Alcohol (95%).....ʒj

113
℞
Sat. Sol. Ac. Boric. in
Spts. Vini Rect.....ʒj

121
℞
Nasal Tab., Seiler's.....xxx

122
℞
Dobell.....ʒiv

123
℞
Hydrarg. Oleat.....ʒj

124
℞
Ung. Hydrarg.....ʒj

126
℞
Tabl. Sod. Salicyl.....Gr. v
No. 20

127
℞
Hydrogen. Peroxidi.....ʒj

129
℞
Hydrarg. Bichlor.....Gr. j
Tr. Gent. Comp.,
Aquæ.....āā ʒij

130
℞
Hydrarg. Bichlor.....Gr. j
Potassii Iodidi.....ʒij
Tr. Gent. Comp.,
Aquæ.....āā ʒij

131
℞
Sat. Sol. Potass. Iodide....ʒj

132
℞
Mist. Rhei et Sodii.....ʒiv

133
℞
Tr. Nuc. Vom.....ʒiij
Mist. Rhei et Sodii.....ʒiv

EAR DEPARTMENT, MANHATTAN EYE AND EAR HOSPITAL.

134 ℞ Syr. Ferri Iodidi.....3j	143 ℞ Tinct. Iodine	152 ℞ Ammonii Mur.....Gr. xx Aquæ Dest.....ʒiv
135 ℞ Ferri et Quin. Cit.....ʒiss Tr. Nuc. Vom.....ʒj Syr. Simp.....ʒj Aquæ.....q. s. ad ʒiv	144 ℞ Balsam Peru	153 ℞ Sol. Argenti Nitras...Gr. v-ʒj
136 ℞ Hydrarg. Bichl.....Gr. j Tr. Ferri Chlor.....ʒj Aquæ.....q. s. ad ʒiv	145 ℞ Balsam Peru, Ol. Ricini.....āā ʒj	154 ℞ Sol. Argenti Nitras...Gr. x-ʒj
137 ℞ Pil. Blaud.....Gr. iij	146 ℞ Orthochlorophenol	155 ℞ Sol. Argenti Nitras..Gr. 60-ʒj
138 ℞ Pil. Blaud.....Gr. v	147 ℞ Ac. Chromic.	156 ℞ Sol. Argenti Nitras..Gr. 480-ʒj
139 ℞ Adrenalin.....ʒj Aquæ.....q. s. ad ʒj	148 ℞ Formalin	157 ℞ Sol. Adrenalin Chlor...1-5000
141 ℞ Alcohol (95%)	149 ℞ Camphophénique	
142 ℞ Ichthyol	151 ℞ Menth. Cryst., Ac. Carbolic. Cryst., Cocainæ Cryst.....āā ʒj	

THROAT DEPARTMENT, MANHATTAN EYE AND EAR HOSPITAL.

201
℞
Zinci Oleo-Stearatis.....ʒj

202
℞
Acetanilidi.....Gr. x
Zinci Oleo-Stearatis,
q. s. ad ʒj

203
℞
Antipyrini.....Gr. x
Zinci Oleo-Stearatis,
q. s. ad ʒj

204
℞
Bals. Peruviani.....♏ x
Zinci Oleo-Stearatis,
q. s. ad ʒj

205
℞
Emuls. Codliver Oil

206
℞
Ol. Ricini.....ʒij

207
℞
Acidi Carbolici.....♏ j
Acidi Borici.....Gr. x
Zinci Oleo-Stearatis,
q. s. ad ʒj
M.

208
℞
Gum Camphor.....Gr. iv
Menthol.....Gr. iv
Zinci Oleo-Stearatis,
q. s. ad ʒj
M.

209
℞
Iodi.....Gr. iij
Zinci Oleo-Stearatis,
q. s. ad ʒj

210
℞
Liq. Plumb. Subacet.....♏ x
Zinci Oleo-Stearatis,
q. s. ad ʒj

211
℞
Ol. Pini Pumillonis.....♏ x
Zinci Oleo-Stearatis,
q. s. ad ʒj
M.

212
℞
Ol. Pini Pumilionis,
Eucalyptol.....āā ♏ v
Zinci Oleo-Stearatis,
q. s. ad ʒj

213
℞
Orthochlorophenol.....♏ iv
Zinci Oleo-Stearatis,
q. s. ad ʒj

214
℞
Acidi Tannici.....Gr. x
Zinci Oleo-Stearatis,
q. s. ad ʒj

215
℞
Ung. Hydrarg. Am....Gr. xv
Bism. Subnit.....ʒj
Ung. Aq. Rosæ...q. s. ad ℥ss

216
℞
Ol. Sinipis Essent.....♏ vj
Menthol,
Camphor.... .....āā ℥ss

217
℞
Acid. Boric.....1
Lanolin.....20

218
℞
Syr. H. I.....ʒiv

219
℞
Ung. Hydrarg. Am.....ʒj
Ung. Zinci Oxid.....ʒij
M.

220
℞
Creosote +
Ol. Gaulther.....āā ʒij
Ol. Hydrocarbon.....ʒj
Ol. Ricini.....q. s. ad ʒj

221
℞
Nasal Tab., Seller's xxx

222
℞
Dobell.....ʒiv

223
℞
Hydrarg. Oleat.....ʒj

224
℞
Ung. Hydrarg..... .. ʒj

THROAT DEPARTMENT, MANHATTAN EYE AND EAR HOSPITAL.

225
℞
Alumnol.....ʒj
Aquæ .....ʒiij
M.

226
℞
Tabl. Sod. Salicyl.....Gr. v
No. 20

227
℞
Hydrogen Peroxide.....ʒj

228
℞
Aquæ Marina .....ʒiij

229
℞
Hydrarg. Bichlor.....Gr. j
Tr. Gent. Comp.,
Aquæ.....āā ʒij

230
℞
Hydrarg. Bichlor.....Gr. j
Potass. Iod.....ʒij
Tr. Gent. Comp.,
Aquæ.....āā ʒij

231
℞
Sat. Sol. Pot. Iod.....ʒj

232
℞
Mist. Rhei et Sodii.....ʒiv

233
℞
Tr. Nuc. Vom.....ʒiij
Mist. Rhei et Sodii.... ...ʒiv

234
℞
Syr. Ferri Iodidi .....ʒj

235
℞
Ferri et Quin. Cit.....ʒiss
Tr. Nuc. Vom.....ʒj
Syr. Simp.....ʒj
Aquæ.....q. s. ad ʒiv

236
℞
Hydrarg. Bichl.....Gr. j
Tr. Ferri Chlor.....ʒj
Aquæ .....q. s. ad ʒiv

237
℞
Pil. Blaud.....Gr. iij

238
℞
Pil. Blaud .....Gr. v

239
℞
Adrenalin.....ʒj
Aquæ.....q. s. ad ʒj

240
℞
Ichthyol.....Gr. xx
Menthol .....Gr. iij
Petrolati.....ʒj
M.

241
℞
Ichthyol.....Gr. xl
Menthol.....Gr. iij
Petrolati .....ʒj

242
℞
Menthol.....Gr. v
Eucalyptol.....♏ xv
Petrolati .....ʒj

243
℞
Tr. Iodine

244
℞
Aluminum Aceto Tart....ʒss
Acid. Boric. Pulv. .....ʒiv

245
℞
Alumin. Aceto Tart...Gr. xx
Aquæ Dest.....ʒj

246
℞
Menthol.....Gr. iss
Eucalyptol.....Gr. viij
Vaselin.....ʒss

247
℞
10% Argyrol.....ʒiij

248
℞
20% Argyrol.....ʒiij

THROAT DEPARTMENT, MANHATTAN EYE AND EAR HOSPITAL.

249
℞
Acid. Carbol.....Gr. v
Acid. Tannic.....Gr. x
Glycerini.....ʒiv
Aquæ.....q. s. ad ℥j

250
℞
Bororenal.....ʒj

251
℞
Ung. Zinci Oxidi.....ʒj
Ung. Hydrargyri
Ammoniati.... .....ʒss
Petrolati.....ʒj

252
℞
Ammonii Mur.....Gr. xx
Aquæ Dest.....ʒiv

253
℞
Menthol.....Gr. vj
Camph. Pulv..... ...Gr. xx
Vaselini.....ʒss

254
℞
Camph.....Gr. xij
Menthol..... Gr. x
Adrenal Inhal.....ʒiij
Benzoinol .....ʒij

255
℞
Acid. Carbol.....gtt. iv
Aquæ Marina.....ʒiv
M. Sig.: ʒij in nasal douche.

256
℞
Douglas Spray..... .....ʒij

257
℞
Pulv. Carbo. Ligni.....Gr. v
Kali Bromidi.....Gr. ij
Pepsini Puri.....Gr. j
Aquæ Menth. Pip.....ʒj

258
℞
Menthol.....Gr. xxx
Tr. Benz. Co.....ʒiv

259
℞
Menthol. .....Gr. v
Ol. Pini Pulm.....ʒj
Milk of Magnesia..q. s. ad ʒij

260
℞
Tr. Ferri Chlor .....ʒj
Glycerini.....ʒij

261
℞
Ichthyol.....25%
Glycerini .....q. s. ad ℥j

262
℞
Acid. Boric.....Gr. x
Adr. Chlor.....(1-1000) ʒj
Aquæ Rosæ.....q. s. ad ℥j

263
℞
Sol. Cocaine Mur.....5%

264
℞
Sol. Cocaine Mur 10%

265
℞
Sol. Cocaine Mur.....20%

266
℞
Mandell Sol.....no. 1

267
℞
Mandell Sol.....no. 2

268
℞
Sol. Argenti Nitras ..Gr. v-ʒj

269
℞
Sol. Argenti Nitras...Gr. x-ʒj

270
℞
Sol, Argenti Nit...Gr. xxx-ʒj

271
℞
Sol. Argyrol.....25%

272
℞
Tannin Glyceride,
Succus Limonis,
Adrenalin Chlor.,
Normal Saline Sol.....āā ʒij
To be kept on ice.

INDEX.

Abbe, Robert, 160
Abscess, brain, of otitic origin, 375-385
  cerebellar. See Brain abscess.
  cerebral. See Brain abscess.
  epidural, 365
  extradural, 366
  laryngeal, 761
  of auricle, 120
  of middle turbinals, 549
  of septum, 545
  perisinus, 352, 358
  peritonsillar, 708, 712
  retropharyngeal, 697
Acoumeter, 37, 38
Acousma, 58
Acoustic neuritis, 392
  nerve, primary atrophy of, 393
Actinomycosis, 482
Adams septum forceps, 528
Adductor paralysis of lateral crico-arytenoids and arytenoids, 811
Adenoids, 671
  alterations of voice in, 674, 675
  anosmia in, 675
  aprosexia in, 675, 677
  aural complications in, 676
  bones and, 674, 675
  clinical picture of, 673
  colds, recurrent, and, 676
  deaf-mutism and, 676
  diagnosis of, 677
    by anterior rhinoscopy, 677
    by digital examination, 677
    by posterior rhinoscopy, 677
  differential diagnosis, 678
  disorders of digestion from, 675
  etiologic significance in ear disease, 52
  etiology, 671
  facial deformity in, 675
  forceps, Brandegee, 679, 680, 683
    Hooper, 689
  hearing in, 676
  heredity and, 671
  inflammatory symptoms and complications of, 676
  intranasal inflammations and, 676
  lymphatic glands and, 673
  mentality in, 674, 677
  middle-ear complications of, 676
  mouth-breathing and, 674
  nasal obstruction and, 672
  neuroses, reflex, induced by, 677
Adenoids, operation, 679
    after treatment, 685
    hemorrhage after, 685
    position of patient in, 681
    preparation of patient for, 679
    with curet, 682
    with forceps, 683
  pathology of, 672
  postnasal, obstructive lesion in nasopharynx, 52
  prognosis of, 678
  recurrence after removal, 686
  respiration in, 674
  symptomatology, 673
  treatment, 679
Adenomata of pharynx, 743
Adenotome, La Force, 681, 682, 683
Adhesions, intratympanic, 180, 196, 197, 778
  in nasopharynx, 685, 686
  of nasal septum, 545
  ossiculectomy for, 197
  prevention of, by pneumomassage, 91
Aditus ad antrum, anatomy of, 174, 175
Adult tonsil, 724
Air heater, electric, 91
Air pressure, negative, in external auditory canal, 91
Air pump, 92
Air, superheated, 91
Air-douche bag, Politzer, 21
Air-douche therapy, 89
Alcohol, effect upon hearing, 53
  tinnitus from, 53
Alexander, 391
Allen-Heffermann's submucous speculum, 534
Allergic asthma, 486
Allergy in hay fever, 650
Allport's mastoid drills, 286
Alveolus, fracture of, during laryngoscopy, 827
Anatomical constrictions of esophagus, 844
Anders, 474
Anemia, 489
Anesthesia, cocaine, in submucous resection, 530, 531
  in direct laryngoscopy, 837, 841
  in esophagoscopy, 845
  in radical mastoid operation, 94

Anesthesia, in suspension laryngoscopy, 821
local, in aural surgery, 94
of pharynx, 748
of larynx, 801
Anesthetic, nitrous oxid, ideal for paracentesis, 96
Aneurism, cirsoid, of external ear, 155
in thorax and laryngeal paralysis, 488
of arch of aorta and left recurrent laryngeal nerve, 489
of ascending portion of aorta and right recurrent laryngeal nerve, 489
of subclavian artery and laryngeal paralysis, 489
Angina epiglottidea anterior, 751
Ludovici's, 760
Vincent's, 710, 714
Angiofibromata of vocal cord, 829
Angiomata of auricle, 154
of external auditory meatus, 165
of larynx, 780, 781
of nose, 660
of pharynx, 742
Angioneurotic edema, 488
Ankylosis of cricoarytenoid joint, 778. See also Adhesions, intratympanic
Annulus tympanicus, 176
Anosmia, etiology, 648
following influenza, 478
in adenoids, 675
in chronic hyperplastic rhinitis, 508
in frontal sinus disease, 591
in maxillary sinus disease, 574
obstructive lesions and, 648
prognosis of, 648
treatment of, 648
Anthelix, malformations of, 143, 145
Antitoxin, diphtheria, 450, 452, 454, 457, 458
dose of, 458
syringe, 458
Antrum forceps, forward cutting, Ostrum's 582
Wagener's, 581
irrigation tube, Myles's, 579
mastoid, anatomy of, 17, 174
mastoideum, 174
of Highmore. See Maxillary sinus.
Aortic constriction of esophagus, 844
Aphonia, 489
Applicator, angular flat, 552
concealed, Tuerck's, 772
laryngeal, Phillips's, 669, 772
platinum, 14
Aprosexia in adenoids, 675, 677
in frontal sinus disease, 591
in maxillary sinus disease, 574
Arrowsmith, concerning Vincent's angina, 714, 715
Arteriosclerosis, effects of high blood-pressure in, 489
Asch operation for deformity of septum, 529
Aspirator, Jackson's secretion, 834, 835
Robertson motor, 834
Asthma, 486
allergic, 486
bacterial infective, 486
combined allergic and infective, 486, 487
infective bronchial, 487
treatment, 487
vaccines in, 487
Asymmetry of pharynx, 692, 693
Atheromata of external ear, 153
Atresia of external auditory canal, 140
Atrophic laryngitis, 775
pharyngitis, 723
rhinitis, 440, 512
Attic, 174
Audiograph, 44
Audiometer, Fowler, 43
test, 42
Auditory canal, external, 28
hallucinations. See Acousma.
Auer, 487
Aural discharge. See Otorrhea.
as a symptom of diseases and injuries of external auditory meatus, 63
from tympanic cavity, 63
from walls of external auditory canal, 63
speculum, how to introduce, 10. See also Speculum.
Auricle, angiomata of, 154.
anomalies of, 144
cystomata of, 154
cysts of, sebaceous, 153
epitheliomata of, 156
fibromata of, 152
function of, 27
horny growths of, 152
keloid of, 152
landmarks of, 105
lupus of, 413
malformations of, 144
papillomata of, 152
perichondritis of, 121
sarcomata of, 160
supernumerary, 143, 147
surgical anatomy of, 104
variations in, 104
Auscultation of middle ear, 71
Autogenous vaccines in nasal furunculosis, 647
Autoinsufflation, Leduc, 431

Autophony, 57, 188, 202
Autumnal catarrh, 649. See Hay Fever.
Avellis, 805

Bacon, 436
Bacteremia, 45, 78
Bacteria, in middle-ear discharge, 45
  mode of entrance into tympanic cavity, 46, 47
Bacterial infective asthma, 486
Bacteriology of acute mastoiditis, 49
Bainbridge's test of enzyme treatment for cancer, 663
Ballance flap, 299
Ballenger, 136, 309, 415
  forceps, bone-cutting, 532
  mucosa knife, 528
  perichondrium elevator, 530
  swivel knife, 531, 534
Bárány noise producer, 340
  tests, 32
Bárány-Jones revolving chair, 318
Baratoux, 436
Barie, 491
Barker, life insurance statistics, 399
Barnhill, 114, 373
Barnick, 47
Basserau, 437
Battery, dry cell for bronchoscopy, 836
Bayer, 574, 714
Beck, 94, 100, 482
Beckman-Rienecke, 79
Belocq sound for treating epistaxis, 645
Benzoinol, O. B. Douglass formula for, 499
Berens' spokeshave, 563
Berkley, 433
Bernay's sponge, 645
Bettmann, 492
Bezold, 38, 39, 131, 168, 171, 182, 215, 219, 222, 223, 271, 290, 331, 338, 339, 340, 387, 410, 420, 469
Bezold's theory of etiology of middle-ear catarrh, 182
Bezold-Edelmann, 39
Bib for patients, 6, 8
Bier, 99, 100
  method of inducing hyperemia, 100
Billroth, 369
Bing's hearing test, 42
Birkner, life insurance statistics, 399
Bistoury for incising peritonsillar abscess, 712
Blackley, 650
Blake, 251, 274
Blau, 518
Blennorrhea, chronic, See Rhinitis, simple chronic.
Blood-clot method of closing mastoid wound, 250
Blood-count, 79
  differential, 80
Blood-cultures, 80
  significance of, positive, 81
Blood examinations, value of, in otology, 78-83
Blood-pressure, influence of, on diseases of ear, nose and throat, 489
  in suspected intracranial complications of suppurative ear diseases, 103
Bloodletting, local, 99
  in acute infectious laryngitis, 762
  in acute inflammation of ethmoidal sinuses, 612
  in acute peritonsillitis, 713
Bodies, foreign. See Foreign bodies.
Boenhaupt, 661
Boenninghaus, 182, 185, 216, 257, 261, 264, 272, 333, 334, 337, 344, 348, 351, 352, 356, 368, 369, 375, 377, 378, 387, 389, 391
Boisseau, 404
Bone conduction test, 40
  temporal, frontispiece, 1
    fracture of, 49
    section through, 174
Bordes, A., 410
Bosworth, 514, 519, 520
  formula for codeine, 759
  nasal saw, 541
    speculum, 13
Bougie, Duel electric, 196
  Eustachian, 23, 24
    dangers of, 24
    method of passing, 23
Bowman's eye probe in mastoid operation, 239
Boyce position of patient for esophagoscopy, 844, 846
Brain abscess of otitic origin, 375-385
  after-treatment, 384
  course, 377
  duration, 380
  etiology, 375
  pathology, 376
  prognosis, 380
  symptoms, 377
  treatment, operative, 381
    results, 385
    technique, 384
Brandegee adenoid forceps, 679, 680 683
Braunstein, 75
Bricy, 74
Brieger, 183
Briezer, 369
Broeckart, 519
Bronchial asthma (infective), 487

Bronchial tree, 842
Bronchitis, chronic, 844 (plate)
Bronchoscope, 819 *et seq.*
  insertion of, 840
  Jackson's, 832, 833, 835
  Lynch's, 820
Bronchoscopy, direct, 832. See Laryngoscopy.
Bronchus, constriction of esophagus by left, 844
Bruce, H. W., 710
Brühl, 256
Brüning's forceps, 553, 616, 623
Bryant, 309
Bulkley, 437
Bulla ethmoidalis, 567, 587
  frontalis, 587
Burckhardt, 469
Burkner, 347
Butlin's technique for thyrotomy, 789

Cabinet for electric switchboard, 7
  for instruments, 4
Caboche, 415, 416, 418
Caiger, 469
Caisson workers' disease, 392
Calcareous deposits in membrana tympani, 70, 190, 191
Calculi of tonsils, 739
  diagnosis, 739
  etiology, 739
  symptoms, 739
  treatment, 739
Caldwell, 583, 592
Caldwell-Luc operation for maxillary sinus disease, 583
Calmette ophthalmic reaction in tuberculosis of ear, nose, and throat, 409, 410
Campbell, 116
Canine fossa, operation through, 581
Cannula, intratracheal, 757
  Myles's irrigation tube and, 579
Carcinomata of larynx, 783
  of nose, 663
  of pharynx, 745
Card, history, 11, 12
Caries of external auditory canal, 141
  etiology of, 141
  in chronic purulent otitis media, 258
  treatment, 142
Carotid artery, injury to, in radical mastoid operation, 292
Carter's bridge and intranasal splint, 640
  nasal speculum, 533
  paraffin injection, 639, 642
Casselberry method of feeding after intubation, 466
Castaignes, 74
Catarrh, acute middle-ear, 182
    course, 184
Catarrh, acute middle ear, diagnosis, 185
    etiology, 182
    life insurance and, 401
    pathology, 182
    prognosis, 186
    treatment, 186
  autumnal, 649. See Hay Fever.
  chronic middle-ear, 187
    diagnosis, 193
      differential, 194
    etiology, 187
    functional tests for hearing in, 192
    life insurance and, 401
    otomassage in, 196
    otoscopic picture in, 189
    pathology of, 187
    prognosis of, 194
    symptomatology of, 188
    treatment of, 189
  chronic nasal. See Rhinitis, simple chronic.
  nasopharyngeal. See Nasopharyngitis.
  postnasal, chronic. See Nasopharyngitis.
  purulent nasal. See Rhinitis, purulent, chronic.
Catarrhal laryngitis. See Laryngitis, simple.
  pharyngitis. See Pharyngitis, simple.
Catheter, Eustachian, 18-23
    diagnostic value of, 19
    faulty position of, 22
    intratympanic medication by means of, 89
    methods of passing, 18-21
Catheterization, Eustachian, 18-24
    method of, 21
    obstacles to, 22
    position of patient during, 20
"Cauliflower ear," 60
Cautery, use of, in suspension laryngoscopy, 830
Cerebellar abscess. See Brain abscess.
Cerebral abscess. See Brain abscess.
Cerebrospinal fluid, bacteriological findings in, 73
    color of, 73
    cytodiagnosis of, 74
    differential diagnosis and, 75
    examination of, 73
    pressure of, 73
    significance of pathological findings in, 74
Cerumen, impacted, 131
  diagnosis of, 133
  etiology of, 132
  hearing tests before removal of, 134
  legal aspects of, 134
  pathology, 132
  prognosis, 133

Cerumen removal by douching, 84
symptomatology of, 132
treatment for, 134
Chair, revolving, 1, 318
Chancre, of larynx, 437
of mouth, 437
of nose, 436
of pharynx, 437
Chapin's tongue depressor, 15, 679
Charcot, 57
Charts, MacKenty's dietary, 797, 798
Chavasse, 74
Cheatle, 477
Chimani, 155, 404
Chimani-Moos test in simulated deafness, 403
Chisel, ethmoidal, 618, 619, 620
Hajek crotch, 535, 537
septal, 537
Killan's V-shaped, 602, 603
Chisels, for mastoid operation, 238
Choanæ, 665, 666
Cholesteatomata, in acute purulent otitis media, 248
in chronic purulent otitis media, 257
of temporal bone, 167
Chondritis of larynx, 777
Chondromata of larynx, 780, 781
Chorditis nodosa, 774
etiology, 774
pathology, 774
prognosis, 775
symptoms, 774
treatment, 775
tuberosa, 774
Chorea, of larynx, 816
pharyngeal, 747
Circulatory system, influence of diseases of, on ear, nose and throat, 488
Cirsoid aneurysm of external ear, 155
Citelli, 391
Clergyman's sore throat, 720. See Pharyngitis, chronic granular.
Closer, safety-pin, 835
Coakley, 445, 525, 592
transillumination lamp, 575, 576
Cocaine in aural surgery, 94, 95
in radical mastoid operation, 94
Cochlea, 31, 32
Cocoa, 650
Coffin ethmoidal forceps, 613
ethmoidal operation, 617
ring adenoid curet, 680, 681
suction apparatus, 577, 578
Cold, influence of, in aural inflammation, 51
rose, 649. See Hay Fever.
Coley, 663
Community centers for the deaf, 399
Compressed-air apparatus, 7
Cooke, 650
Coolidge's sponge holder, 837
Jackson's modification of, 837
Corbett, 472
Cords, vocal. See Vocal Cords.
Corning, on lumbar puncture, 73
Corti, cells of 32
organ of, 33
Coryza, vasomotor, 649. See Hay Fever.
Cotton applicator, Phillips's, 669
holder, Phillips's, 7
holding forceps, Sajous's, 837, 838
Cough in tuberculosis of larynx, 425
Coyon, 480
Craiger, 478
Crane, travelling, for bronchoscope, 820, 822, 824, 825
Cricoid constriction of esophagus, 844
Crista acoustica, 33, 34
Crotch chisel, Hajek, 535, 537
Croup kettle, 766
membranous, 764. See Laryngitis, membranous.
spasmodic, 753. See Laryngitis, simple acute.
Croupous laryngitis. See Membranous laryngitis
Curet, adenoid, Coffin, 680, 681
protector for, Thomson, 682
Stubbs, 680
angular, 279
ethmoid, Masher's, 622
Eustachian, Neumann, 286
pharyngeal, Myles's, 722
Richards, 285
ring, 279
septal, Yankauer, 530, 534
Curtis, 775
Cuspidor, fountain, 4
Cystomata of external ear, 154
of larynx, 780, 781
of middle turbinals, 549, 550
Cysts, retention, of larynx, 829
sebaceous, of external ear, 153

Da Costa, 80
Dann's nasal speculum, 533
Day, 94, 474
Deaf, community centers for, 399
social service for, 399
Deaf-mutism, 54, 396
acute infectious diseases and, 396
adenoids and, 396, 676
consanguinity and, 396
diagnosis of, 397
etiology of, 396
from chronic purulent otitis media, 262
from scarlatina, 469
heredity and, 396

Deaf-mutism, intracranial inflammations and, 396
lip-reading in, 397
otologists and, 399
prognosis of, 397
schools for, 397
treatment, 397
Deafness, acoustic neuritis and, 392
boilermakers', 57, 188
causes of, 53
hysterical, 406
idiopathic total, 54
intermittent, 56
from adenoids, 396, 676
in leukemia, 490
in tabes dorsalis, 490
labyrinthine, from caisson work, 52
partial, 55
postprandial, 56
psychical, 397
scarlatinal, 469
senile, 55
simulated, 403
symptomatic total, 54
Deaver, 667, 751, 752, 756
Deflections of septum, 524
Deformities, external nasal, 633
correction of, 635
Delstanche masseur, 389
pneumatic speculum, 25
rarefactor, 91
Dench, 46, 78, 98, 273, 302, 309, 347, 477
life-insurance statistics, 399
middle-ear vaporizer, 20, 22, 90
Denhart's mouth-gag, with ether tubes, 678
Denker, 386
Desault, 581
Desensitization in hay fever, 651
De Simoni, 482
Deviations of nasal septum, 524
De Vilbiss hand atomizer, 6
spray, 499, 500
Diagrams illustrating: direct laryngoscopy, 841
"high-low" esophagoscopy, 848, 849
Diameters of normal esophagus, 844
Diaphragmatic constriction of esophagus, 844
Dieffenbach's operation for sarcoma of nose, 662
Dietary charts, MacKenty's, 797, 798
Dietl, 369
Digestive system and diseases of upper respiratory tract, 484-486
Dilatation of pharynx, 692
Diphtheria, 449
antitoxin in, 450, 452, 454, 457, 458
etiology of, 449
extubation in, 467
intubation in, 462
Diphtheria, laryngeal, 829
middle-ear suppuration in, 451
mode of infection, 449
of ear, 451
of larynx, 453
of nose, 452
of pharynx, 453
pathology,450
prognosis, 454
Schick test, 454
sequelæ, 469
symptoms, 451, 452
toxin-antitoxin, 454
tracheotomy in, 467
treatment of, 454
antitoxin, 450, 454, 457, 458
constitutional, 457
dietetic, 456
hygienic, 456
local, 459
prophylactic, 454
types of, 450
illustrations of, 452
Diplacusis, 57
in syphilis of internal ear, 436
Direct bronchoscopy, 832
esophagoscopy, 832. See Laryngoscopy.
laryngoscopy, 16, 816, 819, 821, 832. See Laryngoscopy.
tracheobronchoscopy, 832
lower, 832
upper, 832
tracheoscopy, 832, 843
lower, 832
upper, 832
Dissector, Pierce's submucous, 536
Diverticula of esophagus, 849
of pharynx, 692
Dixon, 46
Domochowsky, 571, 572
Douche, ear, 84
Douglass, 100
douche-bag, 538
periosteal elevator, 232
Douglas, O. B., formula for benzoinol, 499
Downie, 335, 469, 471
Drainage tube, Ingals, 599
Drum, incision of, 97
membrane. See Membrana tympani.
Dry cell battery for bronchoscopy, 836
Duchenne, 491
Duel, 24, 82, 313, 451, 469
electric bougie, 196
operation for "lop-ear," 148
Dumond, 424
Dunbar's serum for hay fever, 488
Dunning, William M., 244, 332
Dunning's periosteal elevator, 531
Dura, injury to, in radical mastoid operation, 291

Dust, behavior of, in tonsillar crypts, Wright's experiments with, 706
Dwyer, 101, 121
Dysacoursia, 188
Dysphagia, in congenital tertiary syphilis, 447
in hydrophobia, 480
in tuberculosis, 425, 430
Dysphonia spastica, 816
Dyspnea in syphilis of larynx, 424, 431
in tuberculosis of larynx, 443, 447

Ear, anatomy of, 104, 174
cough, 64
drum. See Membrana tympani.
examination of, functional, 10
physical, 36
external, 104
life insurance and diseases of, 399
middle, 174
speculum, 25, 26, 96
Earache, in acute purulent otitis media, 202
Eardrops, purposes of, 93
Eburnation. See Sclerosis.
Eczema of external ear, 109
radium in, 115
x-ray in, 115
acute, 110
chronic, 111
intertrigo, 109
Edema, angioneurotic, 488
in tertiary syphilis of larynx, 446, 447
in tuberculosis of larynx, 424
of epiglottis in laryngoscopy, 827
of glottis in laryngoscopy, 827
of larynx of cardiac origin, 488
subglottic, 424
Eggston, 653
Einhorn, 832
Electric air heater, 91
bougie, Duel, 24
ear speculum, 96
motor, 8
Electromotor air-pump, 92
Elevator, Dunning's periosteal, 531
Emboli in brain following thrombi in carotids, 394
Empyema of antrum of Highmore, 572
of ethmoidal sinuses, 612
of frontal sinus, 589, 596
of sphenoidal sinuses, 628
suction treatment in chronic, 577
Encephalitis lethargica, 478
Enchondromata of external auditory meatus, 162
of nose, 660
Environment, influence of, on auditory apparatus, 51, 52
Enzyme treatment, Bainbridge's test of, in cancer, 663
Epiglottis, edema of, during laryngoscopy, 827
Epiglottitis, acute infectious, 751
Epilepsy improved by removal of nasal polypi, 654, 656
of nasal origin, 654
spasms of pharynx in, 747
Epistaxis, 643
diagnosis of, 644
etiology of, 643
sound for, Belocq, 645
treatment of, general, 645
local, 644
Epitheliomata of external auditory meatus, 166
of external ear, 156
Epitympanic space, 71, 174
Equilibrium, disturbances of, 314
Erb, 448
Erhard's test in simulated deafness, 404
Erickson sterilizer, 13
Erysipelas, from otological standpoint, 120
of ear, 479
of larynx, 479
of nose, 479
of pharynx, 479
special treatment, 121
Escat, concerning lupoid character of tuberculosis, 415
Esophagoscope. See Laryngoscope.
Jackson's, 833
Esophagus, anatomical constrictions of, 844
cancer of, 844 (plate)
diverticula of, 849
foreign bodies in, 844 (plate), 849
normal diameter of, 844
stenosis of, 849
Ether tubes and Denhart's mouth-gag, 678
Esophagoscopy, 832, 844
anesthesia for, 845
definition, 844
diagnostic value of, 849
direct, 832
"high-low" method, 845-849
diagrams of, 848, 849
Jackson's high-low method, 845-849
diagrams of, 848, 849
position of patient for, 844-846
stages of, 846-848
technique, 846
Ethmoidal chisel, 618, 619, 620
curet, Mosher's, 622
forceps, 618
sinuses, anatomy of, 609
inflammation of, acute, 610
diagnosis, 611

Ethmoidal sinuses, etiology, 610
pathology, 610
symptoms, 611
treatment, 611
Ethmoiditis, chronic purulent, 612
course, 613
diagnosis, 615
etiology, 612
pathology, 612
prognosis, 615
symptoms, 613
treatment, 577, 616
after-treatment, 624
complete removal of cells by intranasal route, 616
complications of, 621
technique, 617, 619
complete removal by external route, 616, 621
partial excavation by intranasal route, 616
Ethyl chlorid as local anesthetic in aural surgery, 95
Eustachian bougie, 23, 24
catheter, 18-23
curet, 286
tube, anatomy of, 174, 177
catheterization of, 18-24
foreign bodies in, 139
function of, 29, 177
new growths in, 166
obstruction of, 71
ossification of membranous portion of, 178
pharyngeal opening of, 193
Ewald's experiment, 317
Examination of patients, 9-25
Exostoses of external auditory meatus, 162
causes of, 162, 163
diagnosis, 163
prognosis, 163
treatment, 164
External auditory meatus, anatomy of, 65, 105
atresia of, 140
blood-supply of, 108
caries of, 141
development of, 106, 107
diseases of, 125
foreign bodies in, 135
hemorrhage of, 142
in children, 65
integument of, 108
lymph supply of, 108
negative air-pressure in, 91, 92
nerve supply of, 108
pain in, 60
peculiarities in, 65
plastic surgery of, 293
relation of, to mastoid antrum, 108
External auditory meatus, sterilization of, 86
tumors of, benign, 162
malignant, 141, 156
External ear, anatomy of, 104-108
anomalies of, 143
diseases of, 109-167
malformations of, 143
wounds of, 120
Extrinsic malignant neoplasms of larynx, 784
Extubation in diphtheria, 456-467

Facial deformity, in adenoids, 671
in labyrinthine disease, 340
nerve, injury to, in mastoid operation, 287
paralysis, of otitic origin, 311, 340
False nose, 640
Fauces, anatomy of, 690
examination of, 16
tearing of, during laryngoscopy, 827
Faucial tonsils, removal of, 727. See Tonsillectomy.
Faught, blood-pressure apparatus, 489
Feeding after laryngectomy, 797
Fenestra ovalis, 175
rotunda, 175
Fibrolysin in chronic middle-ear catarrh, 196
Fibromata of auricle, 152
of larynx, 780, 828
of nasopharynx, 687
of nose, 669
Fibromyomata of larynx, 780
Finkelstein, 478
Finlayson, 469
Fischer, 76, 469
method of extubation illustrated, 465, 466
method of intubation illustrated, 459, 461, 462, 463
Fistula congenita auris, 146, 150
test in purulent labyrinthitis, 327
Fistulous abscess of lung, 844 (plate)
Flaps, plastic, by suspension laryngoscopy, 830
Fleiss, 492
Floyd, 102
Fluids in larynx and nasopharynx during laryngoscopy, 827
Follicular tonsillitis, chronic, 736. See Tonsillitis.
Forceps, adenoid, Brandegee, 679, 680, 683
Hooper, 689
antrum, Ostrum's forward-cutting, 582
Wagner's forward-cutting, 581
bone-cutting, 535

Forceps Brüning's, 553, 604, 616, 623
chisel, Kerrison, 280
cotton-holding, Sajous's, 837, 838
ethmoidal, 618
foreign-body, Jackson, 834, 835
Mosher, 835, 836
Tucker, 835
hemostatic, Rosenheim, 733, 736
Killian, 429, 599
laryngeal, Frankel, 775
Grant, 775
Krause, 775
Krause-Herzog, 428
Scheinmann, 775
McCoy's septal, 432
punch, Grünwald's 551, 552
rongeur, 242, 243
Schrötter's tube, 785
septum, Adams, 528
sinus, Lester's, 713
sphenoidal, Grünwald, 631
tack and pin, Tucker's, 836
tenaculum, Thomson, 728
Fordyce, John A., 412, 416, 418, 423, 437
Foreign bodies, in ear, 135
diagnosis, 136
etiology, 135
symptoms, 136
treatment, 136
inanimate objects, 137
insects, 136
in esophagus, 849
in Eustachian tube, 139
in larynx, 779, 829
in middle ear, 139
in nose, 646
diagnosis, 646
symptoms, 646
treatment, 646
in right bronchus, 844 (plate)
Foreign body forceps, Jackson's, 834, 835
Mosher, 835, 836
Tucker, 835
Formulary, 850-854. (Manhattan Eye, Ear, and Throat Hospital.)
Fornix, 665
Fossa of Rosenmüller, 665
Foster, 647
Fournier, 437
Fowler's audiometer, 43
experiment, 30
hearing test, 42
infection apparatus, 31
nasal douche, 516
resonator apparatus, 42
suction apparatus, 84, 85
Fox, 418
Fracture of alveolus during laryngoscopy, 827
of teeth during laryngoscopy, 827
Fränkel, 574
laryngeal forceps, 775
Frankenberger, 676
Frazier, 311, 313
Freer's modification of submucous resection, 532, 533
incision for, 529, 532
perichondrium elevator, 530
Freudenthal, 492
Friederich, 77, 331, 336, 339, 340, 393
Frigario, 144
Frontal sinus, 587
anatomy of, 587
diseases of, 588
inflammation of, purulent, 589
diagnosis, 591
etiology, 589
pathology, 590
symptoms, 590
transillumination in, 592
treatment, 595
by external (radical) operation, 598
intranasal, 597
simple catarrhal, 588
diagnosis, 589
etiology, 588
prognosis, 589
treatment, 589
necrosis of, 595
diagnosis, 595
prognosis, 595
treatment, 595
operations upon, in chronic empyema, 596
Killian, 601
Kuhnt, 600
Luc, 600
Ogston-Luc, 600
radical, 598, 606
difficulties and dangers of, 607
periostitis of, 595
diagnosis, 595
prognosis, 595
treatment, 595
Frostbite of auricle, 52
Fungi in nose, 646
Funk, 47
Furunculosis of external auditory meatus, 125
of nose, 647

Gallagher, 429
Galton whistle, 39, 40
Galvanocautery, for destruction of turbinal hyperplasia, 560
for removal of neoplasms of pharynx, 743
knife, Phillips, 687
Gangrene following laryngectomy, 799
of external ear, 119
Gaucher, 446

Gauze sponges, Johnson and Johnson's, 838
Gellet's hearing test, 42
Genital system, disturbances of, in relation to diseases of ear, nose and throat, 491
Gerber, 287, 339, 481
Gerlach, 178
Gersuny, paraffin injection method, 636
Glanders, 482
Gleason operation for deformity of nasal septum, 529
Glénard's disease and nasopharyngitis, 485
Glenoid fossa, injury to, in radical mastoid operation, 292
Globus hystericus, 747
Glossitis, interstitial, 440
Glottis, edema of, during laryngoscopy, 827
  spasm of, in adults, 814
    in children, 815
Goldstein 144, 145, 146, 149, 151, 647
  operation for "lop-ear," 148
    for macrotia, 148, 149
  plastic flap, for perforation of nasal septum, 543
Goodale, 650, 705, 706
Gottheil, 481
Gottleib, 650
Gottstein, 476
Gout, 484
Gradenigo, 202, 340, 413, 434
Grant's laryngeal forceps, 775, 776
Granulomata in mastoid cells and antrum, 166
Grayson, 548
Green, 491
Grey, 94
Griesinger sign, 352
Groeber, 79
Grossman, 242, 309
Gruber, 117, 274, 347
  life-insurance statistics, 399
Gruening, 82
Grünert, 309, 366
Grünwald, 408, 419, 632
  punch forceps, 551, 552, 614
Gummata, 439
  of ear, 434
  of larynx, 439, 442, 445
  of mouth, 439
  of nose, 440, 444
  of pharynx, 439, 441, 445
  of tongue, 440
Gums, tuberculous ulceration of, 420
Güntzer, 481
Gurich, 480

Haberman, 336, 337, 391
Hajek, 414, 528, 566, 568, 570, 572, 590, 601, 613, 616, 625, 627, 751
Hajek crotch chisel, 535, 537
  septal chisel, 537
Halle's frontal sinus burrs, 597, 598
Harris, 356
Hartman silver probe, 71
Hartmann probe for exploring tympanum, 265
  tonsil punch, 734
  tuning forks, 39
Hartz, H. J., 387
Hasslauer, 371
Hassler, 347
Hay fever, 649
  allergy and pollen therapy in, 650
  desensitization, 651
  diagnosis, 651
  etiology, 649
  immunization, 651
  inoculation in, 651
  pathology, 649
  perennial, 652
  pollen extracts in, 652
  prognosis, 650
  symptoms, 649
  synonyms, 649
  treatment, 651
Hays laryngoscope, 760
  pharyngoscope, 17, 668, 760, 761
Hayem, 79
Head, 116
Headlight, 5
  Kierstein's, 16
  Phillips's, 5
Head mirror, 5
Hearing, disturbances of, of intracranial origin, 396
    in malaria, 480
    in Ménière's symptom-complex in otitis media, chronic purulent, 268
  influence of drugs and narcotics on, 53
  influence of radical mastoid operation on, 308
  physiology of, 26-35
  requirements of army and navy regarding, 405
  schools for children with defective, 398
  tests for, acoumeter, 37
    Bing, 42
    Fowler, 42
    Rinné, 41
    Schwabach, 40
    tuning-fork, 38
    voice, 36
    watch, 36
    Weber, 41
Heath, 309
  frontal sinus probe, 591
Heine, 287, 341, 351, 370
Heinrich, 482

Heinze, 423
Held, 349, 371, 710
Helix, malformations of, 143, 145
Helmholtz, 28, 29, 31, 33, 34
  theory of sound, 32
Hematoma of septum, 544
Hemilaryngectomy, 789, 791
Hemorrhage, following laryngectomy, 799
  in congenital nevus, 155
  laryngeal, 430
  submucous, during laryngoscopy, 827
Hemostat, Hurd's tonsil, 737
  Miculicz-Stoerck, 735, 738
  Rosenheim's, 733, 736
Henle, spine of, 232, 233
Henrici, 482
Heredity, influence of, on auditory apparatus, 52
Herpes zoster of external ear, 115-117
Heryng, 575
Herzog, 427
Hess, 369
Heterotophy, 144
Heyman, 430
Heysinger, 147
Hiatus semilunaris, 567, 587, 588
Hiccough following laryngectomy, 799
"High-low" method of esophagoscopy, 845-9
  diagrams of, 848, 849
Hinsberg, 331, 340, 342
Hiss, 101, 121
  leucocyte extract, 101
History card, Phillips's, 11, 12
  of patient, 9
Hodgkin's disease, 490
Hoegye's law, 317
Hofman, 508
Holders, sponge, 835
Hollander, 418
Holmes's middle turbinal scissors, 553, 554
  nasopharyngoscope, 193
  study of hysteria of ear, 406
Hooper, adenoid forceps, 689
Horne, 408
Howell, 39
Hubby, 103
Huber, Francis, 78
Hull, 650
Hunt, Ramsey, 62, 115, 116
Hunter sponge-holder, 684
Hurd, tonsil hemostat, 737
  tonsil separator, 731, 732
  tonsil suction tube, 732
Hutchinson, 436
Hutchinson's teeth in congenital syphilis, 447
Hydropathic applications, 89
Hydrophobia, 480
  aural symptoms in, 480
  laryngeal symptoms in, 480
Hydrorrhea, nasal, 653
Hydrotherapy, 84
Hyperalgesia of larynx, 803
Hyperemia, artificially induced, 99, 100
Hyperesthesia acoustica, 56
  of larynx, 802
  of pharynx, 574
Hyperesthetic rhinitis, 649. See Hay Fever.
Hyperkeratosis. See Keratosis.
Hyperosmia, 648
Hyperplasia of lymphoid tissue in nasopharynx, 671
Hyperplastic laryngitis, 768
  pharyngitis, 718
  tonsillitis, 724
Hypertrophic nasopharyngitis. See Nasopharyngitis.
Hypertrophy of Luschka's tonsil, 671
  of middle turbinals, 549, 550
Hysteria of ear, 406
  Holmes's study of, 406

Idiopathic rhinorrhea, 653
Illumination, 5
Immunization in hay fever, 651
Impacted cerumen, 131
Incision of ear drum, 97
Incisuræ Rivini, 176
  Santorini, 105
Incus, ligaments of, 179
Indirect bronchoscopy, 9
  laryngoscopy, 16
Infective bronchial asthma, 487
Inflammation of membrana tympani, 168. See also Myringitis.
Inflation of tympanic cavity, 18
Influenza, 477
  ear and, 477
  larynx and, 478
  mouth and throat and, 478
  statistics concerning the recent epidemic, 477
Influenzal tracheobronchitis, 844 (plate)
Infundibulum of frontal sinus, 587
Ingals, 832
Ingals's frontal sinus drainage tube, 599
  nasal speculum, 14
  pilot burr, 598
Ingersoll's tonsillar hemorrhage needle, 735
Instillation, intralaryngeal, 757, 762
Instruments, sterilization and care of, 8
Insufflation, 93

Intracranial complications of purulent otitis media, 346-385
Intralaryngeal instillation, 757, 762
Intratracheal cannula, 757
Intratympanic muscles, 180
Intrinsic malignant neoplasms of larynx, 784
Intubation, 462
  by suspension laryngoscopy, 830
  feeding after, Casselberry method of, 466
  in chronic stenosis of larynx, 465
  mummy bandage for, 461
  set, O'Dwyer, 460, 461, 462, 463, 465
Irrigation tube, antrum, 579
Isandert, 490

Jackson, 16, 436, 474, 548, 812
Jackson's aspirator, 834, 835
  bronchoscope, 832, 833, 835
  esophagoscopes, 833
  foreign-body forceps, 834, 835
  "high-low" esophagoscopy, 845-849
    diagrams of, 848, 849
  laryngoscopes, 832, 833
  secretion aspirator, 834, 835
  sponge holder, 837
  turbinectomy scissors, 559, 561
Jacobson, 491
Jansen, 294, 295, 340, 342, 600, 632
Jansen-Neumann operation for purulent labyrinthitis, 342, 343
Jansen's curved needle, 536
  fibrocartilaginous-wall retractor, 283
  mastoid-wound retractor, 234
  maxillary-sinus operation, 584
Jenning's mouth gag, 678
Johnson, 429
Johnson and Johnson's gauze sponges, 838
Jugular bulb, injury to, in radical mastoid operation, 291
    resection of, in sinus thrombosis, 362
      after-treatment, 363
      difficulties of, 363
      technique, 362
Junker, 155
Justrite receptacle, 3

Katz, L., 386
Kayser, 705
Keloid of auricle, 152
Keratosis of pharynx, 750
Kerley, 477, 485
Kerrison's chisel forceps, 280
Kershner, 167
Kessel, 28
Kidd, 423
Killian, 16, 592, 600, 604, 606, 623, 655, 666, 820, 832
Killian's crotch chisel, 337, 339
Killian's forceps, 429
  frontal sinus cannula, 595
  operation for frontal sinus disease, 601, 602
    after-treatment, 605
    technique, 601
  packing forceps, 599
  protector, 602
  submucous resection of nasal septum, 529
  submucous speculum, 534
  tube, 832, 834
  tubular speculum, 782
  V-shaped chisel, 602
Kirschner, 480
Kirstein, 832
Kirstein's headlight, 16
Knife, Ballenger mucosa, 528
    swivel, 531, 534
  Douglas tonsil, 529
Knight's angular scissors, 543
Koerner's flaps, 147, 296, 297
  theory of etiology of acute middle-ear catarrh, 182
Kopetzky, 71, 73, 74, 76, 371
Körner, 75, 182, 217, 223, 258, 282, 309, 347, 348, 349, 350, 353, 368, 371, 376, 378, 385, 394, 395
Krause, 427
  laryngeal forceps, 775
Krause-Heryng forceps, 429
Krause-Herzog laryngeal forceps, 428
Krelschmann, 435
Kroenig, 74
Kuhnt, 600
Kümmel, 158, 183, 352
Küster, 282, 581
Küttner, 492
Kyle, 516, 519, 520, 521, 751, 779

Labbi, 74
Labyrinth, emboli in, 391
  fistula in, 327, 328
  fractures through, 50
  function of, 31
  hemorrhage into, 391
  indications for opening, 341
  injury to, in radical mastoid operation, 291
  invasion of, mechanics and mode of, 333
  operations upon, 391
  otosclerosis of, 386
  spongification of capsule of, 386
  vulnerable points in wall of, 331
Labyrinthine involvement, disturbances of equilibrium in, 314, 340
  experimental evidence of, 316
  nystagmus in, 314, 315
  vertigo in, 314, 315
Labyrinithitis, purulent, 314-345

Labyrinthitis, purulent, clinical picture of, 338
course of, 337
indications for opening labyrinth in, 341
induced or experimental evidence of, 316
invasion of labyrinth in, mechanics and mode of, 333
from blood-vessels, 334
from meninges, 335
from tympanic cavity, 333
operations in, 342
Hinsberg, 342
illustrations of, 342
Jansen-Neumann, 343
Richards, 344
pathology, 336
prognosis, 340
sinusitis and, 339
symptoms, general, 338
fever, 338
nausea and vomiting, 338
pain, 338
referable to vestibular apparatus, 314
disturbances of equilibrium, 314, 340
nystagmus, 314, 315
vertigo, 314, 315
special, 339
disturbances of co-ordination, 340
facial paralysis, 340
impairment of hearing, 339
tinnitus aurium, 339
tests, experimental in, 316-318 *et seq.*
caloric, 318, 324
Ewald's, 317
fistula, 318, 327
galvanic, 318, 329
Hoegye's law, 317
rotation, 318
treatment, 341
Lack, 607, 609
Lacunar tonsillitis, chronic, 736. See Tonsillitis.
La Force adenotome, 681, 682, 683
Lake, 423, 431, 519, 563, 612
Lambert, Adrian, 102
Lamorier, 581
Langenbeck's cold-wire snare, 660
hoe periosteal elevator, 232
operation for sarcoma of nose, 662
Laryngeal abscess, 761
applicator, Phillip's, 669, 772
diphtheria, 829
forceps, 428, 775
mirror, 15, 16, 17
polypi, 829
stenosis, 778, 789
Laryngeal abscess, chronic, 465, 778
tags, 829
vertigo, 817
webs, 829
Larngectomy, complete, 789, 791
after-treatment, 796
anesthetic, 792
complications, 798
feeding after, 797
preparation of patient, 791
technique, 791, 792
partial, 789, 791
Laryngitis, acute edematous, 760
diagnosis, 760
etiology, 760
pathology, 760
prognosis, 762
symptoms, 761
treatment, 762
acute infectious, 759
due to general infections, 759
due to local infections, 760
chronic atrophic, 775. See also Rhinitis.
diagnosis, 776
etiology, 775
pathology, 775
prognosis, 776
symptoms, 775
treatment, 776
chronic catarrhal, 768, 770
pathology, 770
treatment, 771
chronic hyperplastic, 768
contributing causes, 768
diagnosis, 769
etiology, 768
prognosis, 769
symptoms, 769
treatment, 770
chronic subglottic, 772
pathology, 772
prognosis, 772
symptoms, 772
treatment, 772
membranous, 764
diagnosis, 765. See also Diphtheria.
etiology, 764
pathology, 765
prognosis, 766
symptoms, 765
treatment, 766
sicca. See Chronic atrophic.
simple acute, 753
as observed in adults, 753
etiology, 753
pathology, 753
prognosis, 755
symptoms, 754
treatment, 755
as observed in children, 758

Laryngitis, simple, acute, as observed in children, diagnosis, 758
symptoms, 758
treatment, 758
spasmodic. See Simple acute.
stridulosa. See Simple acute.
subglottic, 829
traumatic, 767
symptoms, 767
treatment, 767
Laryngofissure, 783, 789
Laryngorrhea. See Laryngitis, simple acute.
Laryngoscope, 819 *et seq.*
Jackson's, 832, 833
Hays, 760
Laryngoscopy, 16
direct, 832
anesthesia, 837, 841
definition, 832
diagrams illustrating, 841
history, 832
in malignant neoplasms of larynx, 782
insertion of bronchoscope, 840
technique, 836
in dorsal decubitus, 839, 840
in sitting position, 838
value of skiagraphy in, 843
illustration of conditions found by, 844 (plate)
suspension, 819
accidents occurring during, 826, 827
anesthesia, for, 821
conditions wherein it is inapplicable, 828
diagnostic value, 828
difficulties of, 826, 827
limitations, 828
Lynch's, 821
technic, 821
uses, 828-830
value of, 828
Larynx, acute inflammatory diseases of, 751
abscess of, 761
adhesions of, syphilitic, 442
anatomical points of, 751
ankylosis of cricoarytenoid joint, 778
carcinomata of, 783
chondritis, chronic, 777
cysts of, 829
deformities of, syphilitic, 442, 444
diphtheria of, 453
erysipelas of, 479
examination of, 13, 16
fibroma of, 780, 828
fluids in, during laryngoscopy, 827
foreign bodies in, 779, 829
gummata of, 439, 442, 445
influenza and, 477
Larynx, lupus of, 431
lipomata of, 780, 781, 829
myxomata of, 780, 781, 829
necrosis of, syphilitic, 442, 445
neoplasms of, 780, 783, 829
benign, 780
malignant, 783
diagnosis, 785
from syphilis, 786
from tuberculous ulceration, 785
extrinsic, 784
hemilaryngectomy for, 791
intrinsic, 784
laryngectomy for, 789, 791
laryngo-fissure for, 789
pathology, 784
prognosis, 786
symptoms, 784
tracheotomy for, 785, 789
thyrotomy for, 789
treatment, 789
neuroses of, 801
motor, 803
sensory, 801
papilloma of, 780, 828
pedunculated tumors of, 829
perichondritis of, acute infectious, 763
chronic, 777
syphilitic, 437, 445, 786
prolapse of ventricle of, 779
retention cysts of, 729
safety-pin in, skiagraph of, 842
sarcomata of, 783
scars of, syphilitic, 442
spasms of, 814
stenosis of, 778, 789, 831
syphilis of, 437, 445
differentiated from cancer, 786
tuberculosis of, 423
differentiated from cancer, 785
tumors of, 828, 829
ulcerations of, 442, 829
malignant, 829
syphilitic, 437, 442, 445, 786
tuberculous, 423, 785
Lateral sinus. See Sinus, lateral.
Lattrom, A., 420
Launois, 183
Lautmann, 492
Lead tooth plates, 821, 822, 823
Leduc autoinsufflator, 431
Leech, 99
artificial, 99
real, 99
Le Forte, 437
Left bronchus, constriction of esophagus by, 844
Leland tonsil separator, 729
Leprosy, 483
Leptomeningitis, otitic, 368

Leucoplakia oris, 448
etiology, 448
pathology, 448
treatment, 448
Leukemia, 490
Leutert, 74, 75, 365
Levy, 419, 429
Libman, 48, 80, 81, 82, 353
Life insurance in relation to ear diseases, 399
statistics of, Phillips's, 399
Ligation of jugular vein, 102
Light, Cooper-Hewitt, 431
Finsen, 418, 431
reflex, 66, 176, 177
Limbeck, 79
Lingual tonsil, 740
removal of, 741
Lipomata of larynx, 780, 781, 829
Lister's sinus forceps, 713
Lobule of ear, malformations of, 146
Lockard, 429
Locomotor ataxia. See Tabes dorsalis.
Loeb, 610, 616, 617, 625, 709
"Lop-ear," 144
Löri, 485
Lower tracheobronchoscopy, 832, 843
tracheoscopy, 832
Luc, 600, 601, 607
Lucae, douche, 84
pneumohydromassage, 389
pressure-sound, 390
tuning-forks, 39
Lucas, 102
Ludovici's angina, 760
Lumbar puncture, 73
as a therapeutic measure, 76
bacteriologic findings in, 73
dangers of, 78
diagnostic value of, 73
differential diagnosis by means of, 75
needle, 77
position of patient in, 77
pressure of fluid in, 73
syringe, 77
technique, 78
"Lumpy jaw." See Actinomycosis.
Lupus erythematosus, 414
exulcerans, 413
hypertrophicus, 413
of auricle, 413
of larynx, 431
of mouth and pharynx, 422
of nose, 415
Luschka's tonsil, 665
Lynch, 821, 829
Lynch's bronchoscope, 820
suspension laryngoscopy, 821

MacCallum, 469, 471
Mach, 28
MacKenty, 787, 788
case of status lymphaticus, 493
dietary chart, 797, 798
operation of complete laryngectomy, 791
operation for pinched nose, 641, 642, 643
Mackenzie, 136, 814
Mackenzie, G. W., 330
Mackenzie tonsillotome, 734
Macrotia, 144
Goldstein's operation for, 148
Macula acoustica, 33, 34
Maggots in nose, 646
Mahu, 74
Malaria, 480
Malassez, 79
Malignant neoplasms and life insurance, 402
Malingering and hemorrhage of external auditory canal, 142
simulated deafness and, 403
Chimani-Moos test in, 403
Erhard's test in, 404
Malleus, 66
ligaments of, 179
Manasee, 335
Mandl's solution, 518
Manubrium, landmark of membrana tympani, 68
Maragliano tuberculosis antitoxin, 409
Margo tympanicus, 176
Marina, 491
Marmorek tuberculosis antitoxin, 409
Martin, 491
Masher's ethmoid curet, 622
Massage of middle ear, 91, 92
vibratory, 92, 518
Masseur, Delstanche, 389
Mastoid antrum, new growths in, 166
burrs, Allport's, 286, 287
Mastoid operation in infants and young children, 245
radical, 281
Ballance flap in, 299
closure of persistent postauricular openings, 305
Mosetig-Moorhof method, 306
Passow-Trautmann method, 305
closure of postauricular wound, 303
contraindications for, 281
dangers and accidents in, 287
dislodgment of stapes 291
facial paralysis, 288
injury to carotid artery, 292
injury to dura, 291
injury to glenoid fossa, 292
injury to jugular bulb, 291
injury to labyrinth, 291
injury to lateral sinus, 291

Mastoid operation, radical, hearing and, 308
incisions in, 282
indications for, 281
in tuberculosis of aditus, antrum or cells, 413
Koerner flap, 296
life insurance and, 400, 401, 402
Panze flap, 294
postoperative treatment, 309
precautionary measures in, 300
preparation of patients for, 282
radiography, 222
results of, 307
Siebenmann flap, 298
Stacke meatal flap, in, 294
technique of, 301
Thiersch skin-grafts after, 298
simple, 225, 226, 228
after-treatment, 250, 251
bandage in, 249, 250
double, 250
blood-clot method of after-treatment, 247
complications of wounds, 252
instruments for, 230
landmarks in, 231
operative findings in, 246
Phillips's complete outfit for, 247
postoperative temperature, 252
preparation of patient, 228
results of, 226, 254
technique, 234
Mastoid process, 71
inflammation of. See Mastoiditis.
periostitis, 212
primary acute, 212
secondary, 212
surgical anatomy of, 231
X-ray of, 222
Mastoiditis, acute purulent, 215
atypical, 226
bacteriology, 49
cause, 217
cholesteatoma in, 248
diagnosis, 220
differential diagnosis, 222
etiology, 216
general pathology, 215
in influenza, 477
in measles, 471
in scarlatina, 469
treatment, 223
operative, 223
indications for, 223, 224, 225
results of, 226, 254
preventive, 222
Maxillary sinus, anatomy of, 566
cysts of, 585
diseases of, 570
empyema of, 572
Maxillary sinus, empyema of, acute, 572
chronic, 572
diagnosis, 573
prognosis, 577
skiagraphy in, 576
symptoms, 573
treatment, 577
irrigation, 579
operation, Caldwell-Luc, 583
radical, 580
through canine fossa, 581
after-treatment, 584
osteomata, 586
transillumination of, 574
Mayer's pharyngeal curet, 722
McBride, 672, 676
McCaw, 474
McCoy's septal forceps, 532
McEwen, 358, 371, 377, 385, 758
McKenzie uvulotome, 694
McKernon, 79, 82, 351
indications for exploration of cranial cavity in suspected otitic brain abscess, 381
Measles, ear complications of, 471
German, 473
Koplik's spots in, 472
laryngeal complications of, 472
mouth and pharynx complications of, 472
nose complications of, 471
treatment, local, 472
Mediastinitis following tracheotomy, 799
Medicine dropper, Yankauer, 430
Membrana basilaris, 31
tectoria, 33
tympani, 66, 175
anomalies of curvature, 67
cicatrization of, 69
diseases and injuries of, 168
ecchymosis of, 67
hyperemia of, 67
incisions of, 97
inflammation of, 168
landmarks of, 66, 176
neoplasms of, 166
normal, 174, 175, 176
paracentesis of, 95, 206
pars flaccida, 66, 176
tensa, 66, 176
pathological changes in, 67
perforations of, 69, 70
diagnostic significance of, in chronic purulent otitis media, 265
solution of continuity of, 68
traumatic lesions of, 171
from direct violence, 171
from indirect violence, 171, 172
treatment of, 172

Ménière, 491
Ménière's symptom-complex, 60
Meninges, hyperemia of, 394
otitic diseases of, 365-374
leptomeningitis, 368
meningitis purulenta, 368, 369
meningitis serosa benigna, 368, 369
serosa maligna, 368, 369
pachymeningitis externa, 365
interna, 367
Meningitis (otitic), Boenninghaus's classification, 368
course, 369
diagnosis, 370
operation on meninges in, 371
pathology, 368
prognosis, 371
symptoms, 370
treatment, 371
Meyer, Fritz, 480
Meyer, Wilhelm, researches of, 671
Meyjer, 753
Mial, turbinal snare, 561, 562
Michaels, 488
Michaels's postnasal mirror, 15, 16
Michel, 751
clamp sutures, 247, 250, 251, 304, 733
Microtia, 145, 147
Miculicz-Stoerck hemostat, 735, 738
Middle ear, 168
auscultation of, 71
blood-supply of, 180
discharges from, etiologic and diagnostic significance of, 45, 46, 47
diseases of, 168, 182
classification of, 182
foreign bodies in, 139
inflation of, 18
introduction of vapors into, 90
lymph supply of, 181
nerve supply of, 181
pneumomassage of, 91
surgical anatomy of, 174
traumatism of, 50
Mikulicz, 832
Miller, 775
Milligan, 607
Millord, 414
Mirva, 391
Monti, 450
Moore, 491
Moos, 436
Morepurgo, 491
Morf, 391
Morgagni, prolapse of ventricle of, 779
Morris, 588
Moseley tonsil snare, 731, 732
Mosher, 526, 617, 825
foreign-body forceps, 835, 836
safety-pin closer, 837
Motor aspirator, Robertson, 834
Moure, 437
Mouth, mucous patches in, 438
tuberculosis of. See Tuberculosis.
Mouth-breathing, adenoids and, 674
chronic atrophic laryngitis and, 775
chronic hyperplastic rhinitis and, 508
hypertrophied tonsils and, 725
Mouth-gag, Denhart's, with ether tubes, 678
for bronchoscope, 820
Jenning's, 678
Much, 366
Mucocele, of middle turbinal, 549
Mucosa knife, Ballenger, 528
Mucous patches, 438
Mummy bandage for intubation, 461
Mumps. See Parotitis.
Muscles, tympanic, 29
Mycelium leptothrix buccalis, 454
Mycosis, pharyngeal, differentiated from laryngeal diphtheria, 454
See also Keratosis.
Mygind, 416
Myles, 728
irrigation tube and cannula, 579
lingual tonsillotome, 740, 741
sphenoidal cannula, 630
tonsil punch, 732
Myringitis, acute, 168
diagnosis, 169
etiology, 168
treatment, 169
Myxomata of external auditory meatus, 165
of larynx, 780, 781, 829
of nose, 655

Nasal accessory sinuses, 566. See also Sinuses.
non-operative treatment, 577
Nasal deformities, (external), 633
broad-bridge nose, 634
crooked or twisted nose, 633
flat nose, 634
hooked nose, 633
partial or total absence of nose, 634
pinched nose, 634
"pound" nose, 634
"saddle" nose, 633
treatment, 635
external operation, 635
intranasal operation, 635, 642
paraffin injection, 634
douche, Fowler's, 516
hydrorrhea, 653
mucosa, acute inflammatory diseases of, 494
polypi, 655
septum, anatomy of, 518, 522, 544
abscess of, 545
adhesions of, 545

Nasal septum, deformities of, 523
deviations and deflections, 524
differential diagnosis, 527
etiology, 526
pathology, 526
perforations, 541
spurs or crests, 523
symptoms, 527
treatment, 528
hematoma of, 544
operations upon, 529
Asch, 529
comparative value of, 536
Gleason, 529
incisions, line of, 532
instruments, 528-543
removal of septal spurs, 537
Roe, 529
submucous resection of septum, 529
perforations of, 541
prognosis, 543
treatment, 543
ulcerations, 544
speculum, 14
Carter's, 533
Dann's, 533
Nasofrontal duct, 587
Ingals's method for enlarging, 598
Nasopharyngoscope, Holmes's, 193
Nasopharynx, anatomy of, 664
fluids in, during laryngoscopy, 827
foreign bodies in, 685
neoplasms of, 682
benign, 682
fibromata, 683
polypi, 683. See Nasal polypi.
malignant, 684
carcinomata, 684
lymphosarcomata, 684
sarcomata, 684
teratomata, 685
Nasopharyngitis, acute, 664
etiology, 664
symptomatology, 664
treatment, 664. See Rhinitis, acute
atrophic, 666
symptomatology, 666
treatment, 666
simple chronic, 664
etiology, 664
pathology, 665
treatment, 665. See Rhinitis, chronic.
Needle, Ingersoll's tonsillar hemorrhage, 735
spiral tonsil suture, 736
Yankauer's suture, 536
Neoplasms of larynx, 780, 783, 829 See Larynx.
Neosalvarsan, 433
Nephritis, chronic interstitial, 491
Neumann, 94, 298, 302, 314, 342
curet, 286
Neuralgia, laryngeal. See Hyperalgesia of larynx.
Neurasthenia, aural symptoms of, 402
Neuroses, nasal, 648
from adenoids, 677
reflex, 649
New growths and chronic purulent otitis media, 259
Nichols, 40
Nitrous oxid gas, ideal anesthetic for paracentesis, 96
Nodules, vocal cord, 828, 829
Noguchi test in labyrinthitis accompanying syphilis, 336, 347
in syphilis of middle ear, 435
Noise-producer, Bárány's, 340
Phillips's, 340
Noma of auricle in typhus fever, 475
Nose, deformities of, from syphilis, 444. See also Nasal deformities.
diphtheria of, 452
erysipelas of, 478
examination of, 13
false, 644
foreign bodies in, 646
furunculosis of, 655
neoplasms of, 655
benign, 655
angiomata, 660
enchondromata, 660
fibromata, 659
myxomata, 655
osteomata, 661
papillamata, 659
malignant, 661
carcinomata, 663
sarcomata, 661
neuroses of, 648
parasites in, 646
rhinoliths in, 647
Nystagmus, 59, 225, 315, 316, 341
in cerebellar abscess, 379
of vestibular origin, 315, 316

O'Dwyer intubation set, 460, 461, 462, 463, 465
Office equipment, 1-8
Ollier's operation for sarcoma of nose, 662
Onodi, 632
Oppenheimer, 650
Opsonic index, 100, 410
Opsonins, 100
Oropharynx, malformations and deformities of, 692
surgical anatomy of, 690
Osler, 423, 424
Ossicles, function of, 28
ligaments of, 179, 180

Ossicles, muscles of, 180
Ossiculectomy, 270, 274
  indications for, 275
  Kerrison chisel forceps in, 280
  ring curets in, 275
  results of, 279
Osteitis of middle turbinals, 549
Osteomata of external auditory meatus, 166
Ostium maxillare, 567, 568
Ostrum's forward-cutting forceps, 582
Otalgia, 60
  in diphtheria of ear, 451
  in rheumatic fever, 488
Othematomata, 122
Otitic vertigo, 58
Otitis, chronic purulent, 255-280
    course, 261, 263
    diagnosis, 264
      perforations of drum membrane an aid to, 265, 266, 267
    etiology, 260
    hearing in, 268
    intracranial complications, 346
    life insurance and, 401, 402
    new growths and, 259
    pathology, 255
      changes in bone, 258
      changes in mucous membrane, 255
    prognosis, 267
    symptoms, 261
    treatment, 269
      local therapy, 270
      ossiculectomy, 274
      radical mastoid operation, 270, 281
  circumscripta follicularis, 125
  externa diffusa, 129
    fungoides, 130
    keratosa, 131
    parasitica, 131
  media, acute purulent, 198-211
    bacteriology of, 199
    course, 202
    diagnosis, 204
    etiology, 199
    in epidemic cerebrospinal meningitis, 478
    in influenza, 477
    in lobar pneumonia, 478
    in measles, 471
    life insurance and, 401, 402
    pathology, 198
    prognosis, 205
    symptomatology, 202
    treatment, 205
      by incision of drum membrane, 206
  neonatorum, 200, 211
Otodynia, 62
Otomassage, 92, 196
Otomycosis, 130
Otopiesis, 57
Otorrhea, 260, 261
  influence of radical mastoid operation on, 308
Otosclerosis, 386
  cause, 387
  diagnosis, 388
  etiology, 386
  from gout, 484
  in syphilis, 434
  pathology, 386
  prognosis, 389
  treatment, 389
Otoscope, 20, 28
  Siegel, 69
Otoscopic examination, 9, 10, 65, 66
    obstacles to, 66
Oval window, 71
Ozena laryngis, 775
    of syphilitic origin, 440
  rhinitis, atrophic, and, 512, 514
  treatment of, Coffin's, 514

Pachyderma laryngis, 773
    symptoms, 773
    treatment, 774
Pachymeningitis externa, 365
  interna, 368
Packer, 480
Page, Lafayette, 331
Pain, as a general symptom, referable, to ear and surroundings, 60
  in Eustachian tube, 61
  in external auditory meatus, 60
  in head, 61
  in mastoid process, 61
  in neck, 61
  in pinna, 60
  in tympanic cavity, 61
  in tympanic membrane, 61
  inflammatory, 60
  neuralgic, 62
Palate retractor, 15
    White's, 16
  soft, paralysis of, 407
  tuberculous ulceration of, 420
Pansinusitis, 574
Panze flap, 147, 294
Papillomata of larynx, 780, 828, 844 (plate)
  of fauces, 844 (plate)
  of nose, 659
  of pharynx, 742
  of vocal cord, 827, 830
Paracentesis, 95, 206
  in acute purulent otitis media, 206
  indications for, 207
  instruments for, 96, 97
  preparation of patient for, 95, 96
Paracusis, 189
  loci, 56

Paracusis Willisii, 57, 188
Paraffin cup, 637
injection in atrophied turbinals, 518
in "saddle" nose, 636
Geruny method, 636
methods of injecting, 637
Paralysis, facial, of otitic origin, 311, 340
of larynx, 804
central, 805
peripheral, 806
Paralysis, adductor, 780
bilateral abductor, 807
complete, of recurrent laryngeal nerve, 808
induced by disease or injury of recurrent laryngeal, 806
induced by disease or injury of superior laryngeal, 812
of arytenoids, 812
of external tensors, 813
of internal tensors, 812
of pharynx, 747
of soft palate, 407
of sphincter of epiglottis, 813
of velum palati, 747, 748
Parasites in nose, 646
Paresthesia of larynx, 802
of pharynx, 749
Parker, 430, 495, 511, 524, 650, 722, 749, 758, 762, 764, 768
Parosmia following influenza, 478
Parotitis, epidemic, 476
Passow, 271
Passow-Trautmann method, 305
Payne nasal saw, 542
Pedunculated tumors of larynx, 829
Pemphigus of external ear, 119
Perceptive apparatus, disease of, 386, 406
Perennial hay fever, 652
Perforations of membrana tympani, 69, 70
in chronic purulent otitis media, 265, 266, 267
of nasal septum, 541
cause, 543
prognosis, 543
treatment, 543
Perichondritis, 121
of auricle, 121
of larynx, 763, 777
Periosteal elevators, Douglass, 232
Dunning's, 531
Langenbeck, 232
Periostitis of mastoid process, 212
Peritonsillar abscess, 708, 712
Peritonsillitis, 708, 712, 714
Perrin, 448
Pertussis, 476
Pharyngitis, acute infectious, 703
membranous, 704
Pharyngitis, parenchymatous, 703
chronic atrophic, 723
fetid, 724
simple 723
chronic hyperplastic, 718
granular, 720
simple, 718
simple acute, 699
toxic, 716
traumatic, 715
Pharyngocele, 692. See also Diverticula.
Pharyngomycosis. See Keratosis.
Pharyngoscope, Hays, 17, 18, 668
Holmes, 193
Pharyngotomy, subhyoid, 783
Pharynx, asymmetry of, 692, 693
dilatation of, 692
diverticula of, 692
erysipelas of, 479
examination of, 16
fungoid growths in, 749
in influenza, 478
in measles, 472
inflammations of, acute infectious, 702
inflammations of, chronic, 718
neoplasms of, 742
benign, 742
adenomata, 743
angiomata, 742
dermoid cysts, 743
fibromata, 742
papillomata, 742
ranula, 742, 743
malignant, 744
carcinomata, 745
sarcomata, 744
neuroses of, 746
motor, 746
sensory, 748
paralysis of. See Neuroses.
polypi of, 687, 829
spasmodic affections of. See Neuroses.
Phillips, 82
Phillips's complete mastoid outfit, 246
galvanocautery knife, 686
headlight, electric, 5
history card, 11, 12
laryngeal applicator, 669, 772
modification of Bosworth nasal speculum, 13
noise producer, 340
portable operating table, 245
tongue depressor, 728
treatment room, 1
waste-pail, 2, 4
Phillips-Friesner revolving chair, 318
Phlebitis in purulent otitis media, 346
Physical examination, 9-25
Physiology of hearing, 26-35

Pierce, 290
Pierce's submucous dissector, 536
Pillar, tearing of anterior, during laryngoscopy. 827
Pilz, 435
Pin forceps, Tucker's, 836
Pinna, pain in, 60
Pirquet, concerning vaccination in tuberculosis, 409
Pitt, 347
  life-insurance statistics of, 389
Pityriasis capitis extending to external ear, 118
Plastic flaps in suspension laryngoscopy, 830
Plates, lead tooth, 821, 822, 823
Pneumatic speculum, 24, 25
Pneumohydromassage, Lucæ, 389
Pneumomassage, 91, 92
Pneumonia, following laryngectomy, 798
  lobar, 478
Podagra. See Gout.
Politzer, 28, 56, 114, 168, 173, 215, 387, 397, 434, 435, 436, 491
  acoumeter, 37, 38
  air-douche bag, 21
  method of inflation, 18
Politzerization, 89, 90
Pollen extracts, 652
  therapy in hay fever, 650
Polyotia, 143, 147
  treatment, 150
Polypi, aural, 256, 257, 272
  in mastoid cells and antrum, 166
  laryngeal, 829
  nasal, 655
  pharyngeal, 687, 829
Position, Boyce, 844, 846
Postauricular openings, persistent, 305
Postnasal mirror, Michaels's, 15, 16
Poulson, life-insurance statistics, 400
Poyst, 437
Pregnancy, 492
Pressure-atrophy in chronic purulent otitis media, 258, 259
Preysing, 375
Processus uncinatus, 567, 587
Prolapse of ventricle of Morgagni, 779
Prussack's space, 177, 181
Pseudoacousma, 189
Psoriasis buccalis, 448
  of external ear, 118
Puberty, 492
Punch, Hartmann's tonsil, 734
Pyemia, otitic, 394
Pyriform sinuses, 846

Quincke, 73, 77
Quinsy, 707
Quire's foreign-body extractor, 139

Radiograph, of enlarged thymus, 492
  of frontal sinus, 594
  of lateral sinusitis, 350
  of mastoid, 222
  of nasal accessory sinuses, 592-4
  of purulent sinusitis, 594
  of status lymphaticus, 493
Radiotherapy, 431
Radium, application of, by suspension laryngoscopy, 830
  in eczema of ear, 115
  in tuberculosis of ear, nose, and throat, 409, 414
Rae, John B., 315
Randall, 399
  life-insurance statistics, 399
Ranula, 742, 743
Räpke, 385
Rarefaction of bone in chronic purulent otitis media, 258
Rasp, Weiner's, 578, 579
Reflected light, 5
Regnier, 697
Reid's base line, 373
Respiration, suspension of, during laryngoscopy, 827
Retention cysts of larynx, 829
Retractor, mastoid wound, 234
  submucous hand, 539
Retropharyngeal abscess, 697
Revolving chair, 1, 318
Revolving stool, 3, 5
Rheumatic fever, 479
Rheumatism and pharyngitis, 720
  and tonsillitis, 710
Rhinitis, 494
  acute, due to chemical and mechanical causes, 502
    due to local specific infections, 502
  atrophic, 512
    differential diagnosis, 515
    etiology, 512
    of syphilitic origin, 440
    ozena in, 514
    pathology, 513
    prognosis, 515
    symptoms, 513
    treatment, 516
  caseosa, 521
  diphtheritic, 501
  erysipelatous, 502
  general remarks on, 494
  gonorrheal, 502
  hyperesthetic, 649. See Hay Fever.
  hyperplastic, chronic, 507
  membranous, 501
  "occupation," 502
  of acute exanthemata, 501
  of influenza, 500
  of specific inflammations, 521
  purulent, chronic, 519
    diagnosis, 520

Rhinitis, purulent, etiology, 519
symptoms, 520
treatment, 520
simple acute, 495
complications, 496
etiology, 495
pathology, 496
treatment, 497
general local, 498
prophylactic, 498
simple chronic, 505
after-treatment, 507
diagnosis, 506
etiology, 505
pathology, 505
prognosis, 506
treatment, 506
Rhinoliths, 647
Rhinorrhea, cerebrospinal, 654
idiopathic, 653
Rhinoscleroma, 480
Rhinoscopy, anterior, 677
posterior, 14, 677
Richards's curet, 285
operation upon labyrinth, 344
Richardson, 217, 228, 230, 471, 715
headlight, 228
headrest for mastoid operation, 228
Ricord, 436
Rieder, 79
Rieman, 29
Ring, Waldeyer's, 739
Rinne's hearing test, 41, 192
Robertson's motor aspirator, 834
Roe, 634
operation for deformity of nose, 635
of septum, 529
Roosa, 436
Rose-cold, 649. See Hay Fever.
Rosenberg, 448
Rosenheim hemostatic forceps, 733, 736
Rosenmuller's fossa, 665
Ross, 804, 806
Rötheln, 472
Rouge, operation for sarcoma of nose, 662
Round window, 71
Rubella, 473
Rubeola, 473

Safety-pin closer, 835
Mosher, 837
in larynx, skiagraph of, 842
Sajous, 487
Sajous' cotton-holding forceps, 837, 838
Salvarsan, 433
silver, 433
Santi, 704
Sarcomata of external ear, 160
of larynx, 783
Sarcoma of nose, 661
serum therapy in, 663
Saw, nasal, Bosworth, 541
Payne, 542
Scarlatina, 469
of ear, 469
of larynx, 471
of nose, 470
of oropharynx, 470
Scheibe, 183
Scheinmann, laryngeal forceps, 775
Scheppegrell, 650
Schick test, 454
Schmidt, 485
Schmidt, Montz, statistics of neoplasms of larynx, 780
Schrotter's tube forceps, 785
Schulze, 370
Schwabach, 391, 436, 490
hearing test, 40
Schwartze, 71, 75, 207, 223, 272, 388, 399
Scissors, Holmes's middle turbinal, 552, 553
Jackson's turbinectomy, 559, 561
turbinal, 561
Sclerosis of bone in chronic purulent otitis media, 258
Screw-worms in nose, 646
Scurvy, 491
Sebaceous cysts of auricle, 153
Seborrhea of external ear, 118
Secretion aspirator, Jackson's, 834, 835
Selfridge, 650
Semicircular canals, 31, 32
Semon, 762, 811, 816
Semon-Rosenback law, 805, 808
Separator, Hurd tonsil, 731, 732
Septicemia, otitic, 395
Sepsis following laryngectomy, 800
Septal forceps, McCoy's, 532
Septum, nasal, 518, 522, 544. See Nasal septum.
Serum therapy of nose, 663
Shambaugh, 32, 34, 35, 386
Sharp's modification of Bosworth's nasal speculum, 14
Sheppard, 366
Shrapnell's membrane, 176
Sicord, 74
Siebenmann, 168, 171, 175, 387, 391, 451
flap, 298
Siegel otoscope, 69
pneumatic speculum, 24, 25
Silver salvarsan, 433
Simpson's sponge tampon, 542
Singers' nodules, 829
Sinus, accessory nasal, 566
skiagraphy of, 576, 592
anatomical classification, 566

Sinus, ethmoidal, 609. See Ethmoidal sinus.
frontal, 587. See Frontal sinus
anatomical illustration of, 586
radiograph of, 594
transillumination of, 592
lateral, anatomy of, 348
injury to, in radical mastoid operation, 290
maxillary, 566. See Maxillary sinus.
orifices of, 586
sphenoidal, 624. See Sphenoidal sinus.
thrombosis of, 346
anatomical consideration, 348
diagnosis, 353
etiology, 349
pathology, 351
prognosis, 357
relative frequency of intracranial complications of otitic origin, 347
skiagraph of, 350
symptoms, 351
treatment, 358
jugular resection, 362
after-treatment, 363
difficulties, 363
technique, 362
Sinuses, pyriform, 846
Sinusitis, frontal. See Frontal sinus.
radiagraph of purulent, 594
Skiagraph of safety-pin in larynx, 842
Skiagraphy, 576, 592, 615
value of, in laryngoscopy, 843
Skin-graft, Thiersch, 298
Sluder operation for removal of faucial tonsils, 733-4
Small-pox, 476
Smith, Ellery, 161
Harmon, 600, 601
paraffin syringe, 636
Snare, cold-wire, Langenbeck, 660
nasal, Krause, 553
tonsil, Moseley, 731, 732
turbinal, Mial, 561, 562
Social service for the deaf, 399
Solis-Cohen, 449
Somers, 488
Sound-conducting apparatus, 27
Sound-perceiving apparatus, 31
Spasmodic laryngeal cough. See Chorea of larynx.
Spasms of co-ordination, 816
of glottis, 814
of larynx, 814
Spatula of bronchoscope, 820, 823, 825
Speculum, aural, 10
Delstanche, 25
electric, 96
Siegel pneumatic, 24, 25
Speculum, nasal, 10, 13
Allen-Heffermann's, 534
Bosworth's, 13, 14
Carter's, 533
Dann's, 533
Ingalls's, 14
Killian's, 331
Phillips's, 13, 14
Sharp's, 13, 14
Sphenoidal sinus, 624
anatomy of, 624
diseases of, 627
empyema of, 628
prognosis, 629
symptoms, 628
treatment, 577, 629
surgical, 630
external operations, 632
perforation of anterior sphenoidal wall, 630
radical operation, 631
simple enlargement of osteum, 630
pathological anatomy, 625
surgical anatomy, 624
Sphygmomanometer, Faught, 489
Janeway, 103
Spine of Henle, 232, 233
Spira, 271
Spiral tonsil suture needle, 736
Spirocheta pallida, 433
Spokeshave, Berens, 563, 564
Sponge, Bernay's, 645
holder, 535
Coolidge's, 837
Hunter, 684
Jackson's modification of Coolidge's, 837
tampon, Simpson's, 542
Sponges, Johnson and Johnson's gauze, 838
"Spongy spot" in mastoiditis, 232, 246
Spray apparatus, 6
De Vilbiss, 6
Spray solutions, 6
Douglas's formula for, 499
Spray-tip, Thomson, 6
Spurs, septal, 523
Stacke, 282, 293, 309
meatal flap, 293, 294
operation for supernumerary auricle, 147
Stages, four, of esophagoscopy, 846-8
"Stammering of the cords," 816
Stapes, 31
dislodgment of, in radical mastoid operation, 231
ligaments of, 180
Status lymphaticus, 492
Steel, 647
Stein, 393, 485
Steinbrügge, 255, 436

Stenosis, congenital, of pharynx, 692
laryngeal, 778, 789, 831
chronic, 465, 778
of esophagus, 849
Sterilizers, 5
Sticker, 483
Stoerck, 427
Stöhr, 705
Stool, revolving, 3, 5
Stötzner, 391
Straussmann, 705
Stricture of external auditory canal, 140
Stubb's adenoid curet, 680
Subglottic laryngitis, 829
Subhyoid pharyngotomy, 783
Submucous dissector, Pierce's, 536
hemorrhage during laryngoscopy, 827
resection of nasal septum, 31, 529
after-treatment, 536
anesthesia, 530
Freer's incision, 529, 532
preparation of patient, 529
technique, 532
of inferior turbinal, 564
set, 539
Suction tube, Hurd's tonsil, 732
Suepfle, 48
Sugar, 391
Suspended respiration during laryngoscopy, 827
Suspension laryngoscopy, 819. See Laryngoscopy.
Suture, clamp, Michel's, 247, 250, 251, 304, 733
needle, Yankauer's, 536
Swivel knife, Ballenger's, 531, 534
Synechiæ in nares, 565
Syphilis, aural, and life insurance, 402
of external ear, 433, 434
of internal ear, 435
of larynx, 437, 442, 445, 786
of middle ear, 434
of mouth, 437
of pharynx, 437
salvarsan treatment of, 433
Syringe, antitoxin, 458
for removal of cerumen, 84
postnasal, 516, 517

Tabes dorsalis, 490
Table, Phillips's, 245
Tack forceps, Tucker's, 836
Tags, laryngeal, 829
Taylor, 311, 313
Teeth, fracture of, during laryngoscopy, 827
Tegmen tympani, 174
Temperature in aural diseases, 64
Temporal bone, frontispiece, 1
fracture of, 49
Temporal bone, section through, 174
Test, acoumeter, 37
audiometer, 42
bone conduction, 40
Schick, 454
Teutlevan, 178
Texier, 437
Thierfelder, 473
Thiersch skin-graft, 298
Thiesen, 751
Thiosinamin in chronic middle-ear catarrh, 196
Thoma, 79
Thomson, J. J., 6
protector for adenoid curet, 682
tenaculum forceps, 728
tongue depressor, 727
Thomson, St. Claire, 607, 654, 703
Thornwaldt's bursa, 666
Throat, examination of, 13
Thrombosis, lateral sinus, 346, 348
Thrush, 749
Thymus radiograph of, enlarged, 492
Thyrotomy, 783, 789
technic, 789
Tilley, 601, 607
Tinnitus aurium, high blood-pressure and, 489
in anemia, 489
in aural hysteria, 406
in chronic interstitial nephritis, 491
in chronic middle-ear catarrh, 189
in mumps, 476
in neurasthenia, 402
in purulent labyrinthitis, 339
in purulent otitis media, 262
in tabes dorsalis, vibratory massage for, 92
with nasal obstruction of septal origin, 527
Tobleitz, 471
Tobold, scarifier, 752, 761
Tod Hunter, 376, 379, 381
Tongue, 693
Tongue depressor, Chapin's, 15, 679
Phillips's, 728
Thomson's, 727
tuberculous ulceration of, 420
Tonsil, adult, 724
bacterial infection of, 704
calculi of, 739
diagnosis, 739
etiology, 739
symptoms, 739
treatment, 739
capsule of, 727
cysts of, 738
diagnosis, 738
symptoms, 738
treatment, 738
faucial, 690
function of, 705

Tonsil, gumma of, 440
hypertrophied, 724
indications for removal of, 727
knife, Douglas, 729
lingual, 671, 691, 739
Luschka's, 671
needle, Ingersoll's, for hemorrhage, 735
spiral suture, 736
portals of infection, 705
punch, Hartmann's, 734
Myles's, 732
removal of. See Tonsillectomy.
separator, Hurd, 731, 732
Leland's, 729
snare, Moseley, 731, 732
suction tube, Hurd, 732
tenaculum forceps (Thomson's), 728
tuberculous ulceration of, 420
Tonsillar hemorrhage needle, Ingersoll's, 735
Tonsillectomy, 727
advantages of hospital for, 729
after-treatment, 735
anesthetic, 729
dangers, 734
hemorrhage, 732, 734
control, 732, 733, 735
local anesthesia, 729
of lingual tonsil, 741
Sluder, 733
technique, 730
Tonsilliths, 739
diagnosis, 739
etiology, 739
symptoms, 739
treatment, 739
Tonsillitis, acute infectious, 705
complications, 710
diagnosis, 710
etiology, 707
pathology, 708
prognosis, 710
symptoms, 709
treatment, 711
after-treatment, 714
general, 711
local, 712
prophylactic, 711
varieties. See Pathology.
chronic follicular (lacunar), 736
diagnosis, 737
etiology, 736
pathology, 737
symptoms, 737
treatment, 737
chronic hyperplastic, 724
diagnosis, 726
etiology, 724
pathology, 725
prognosis, 726
symptoms, 725
Tonsillitis, chronic hyperplastic, treatment, 726
lacunar, 736. See Chronic follicular,
Tonsillotome, Myles's lingual, 740, 741
Mackenzie, 734
Tooth plates, lead, 821, 822, 823
Toxin-antitoxin, diphtheria, 454
Toynbee, 30, 274, 476
Trachea, bronchoscopic view at bifurcation, 844 (plate)
Tracheobronchial tree, 842
Tracheobronchitis, influenzal, 844 (plate)
Tracheobronchoscopy, direct. See Laryngoscopy.
lower, 843
Tracheoscopy, direct, 832, 843. See Laryngoscopy, 832
Tracheotomy, 783
for benign neoplasms of larynx, 783
for malignant neoplasms of larynx, 785, 789
in diphtheria, 467
set, 836
Trachitis following laryngectomy, 800
Trachoma of vocal cords. See Chorditis nodosa.
Tragus, malformations of, 146, 150
Transillumination of frontal sinus, 592
of maxillary sinus, 574
Coakley lamp for, 575
Trautmann, 309, 414
triangle, 342
Traveling crane for bronchoscope, 820, 822
Treatment room, 1-8
Tree, tracheobronchial, 842
Trelot, 420
Triboulet, 480
Tröltsch, 282
Tube, Eustachian. See Eustachian.
forceps, Schrötter's, 785
Killian, 832, 834
Tuberculosis, 408-432
antitoxins and, 409
Calmette ophthalmic reaction and, 409
of accessory sinuses, 418
of ear, 410
of gums, 420
of larynx, 423, 785
of mouth and pharynx, 418, 419
of nose, 414
of palate, 420
of tongue, 420
of tonsils, 420
opsonic index and, 409
radium and, 409
tuberculins and, 409
vaccination and, 409

Tuberculosis, X-ray and, 409
Tucker's foreign body forceps, 835
tack and pin forceps, 836
Tuerck's concealed applicator, 773
Tumas, 79
Tumors of larynx, diagnosis of, 828, 829
Tuning-forks, Bezold-Edelmann, 39
Hartmann's, 39
Lucae, 39
Turbinate bones, anatomy of, 546
function of, 547
synechiæ, 565
hypertrophy of, 507
inferior, 556
deformities of, 556, 559
diseases of, 556
acute inflammation, 556
atrophy, 558. See also Atrophic rhinitis.
dilatations, 559
hyperplasia, 557
synechiæ, 565
treatment of, 559
internal, 559
local, 559
surgical, 559
malformations, 556, 559
submucous resection of, 564
reduction of hyperplasia with galvanocautery, 559, 560
turbinectomy, 560, 563
turbinotomy, 560, 562
middle, 549
diseases of, 549
treatment of, 550
enlargement of, 550
surgical treatment, 550
anesthetic, 551
operation, 552
preparation of patient, 551
removal of entire middle, 553
results, 555
pathological anatomy of, 546
physiology of, 547
superior, 549
diseases of, 549
treatment of, 550
Turbinectomy, 552, 553, 560
Turbinotomy, 552, 560, 562
Turner, 607, 672, 676
Tympanic cavity, inflation of, 18
pain in, 61
Tympanic membrane, atrophy of, 71
Tympanophony. See Autophony.
Typhoid fever, 474
complications of, in ear, 474
in larynx, 474, 475
in mouth, 474
in nose, 474
in pharynx, 475
Typhoid fever, vaccine preventive treatment of, 475
Typhus fever, 475
Tyson, 753

Ulcerations of larynx, 442, 829
malignant, 829
of septum, 544
syphilitic, 442
tuberculosis, 423
Umbo, 66, 176, 177
Upper tracheobronchoscopy, 832
tracheoscopy, 832
Urbantschitsch, 89, 196, 367, 398, 476
Uremia, 491
Utricle, 32
Uvula, 690, 691
adhesions of, 696
elongation of, 694
malformations, 693
rudimentary, 693
surgical removal, 694
treatment, 694
ulcerations, 696
Uvulitis, acute, 695
Uvulotome, McKenzie, 694

Vaccine therapy, 100
Vaccines in asthma, 487
in nasal furunculosis, 647
Valsalva's method of inflating ear, 18, 19, 30, 72
Vaporizer, Dench middle-ear, 20, 22, 90
Vapors, introduction of, into middle ear, 90
Varix, lingual, 691, 740, 741
Vasomotor coryza, 649. See Hay Fever.
Velum palati, unilateral paralysis of, 747, 748
Vertigo, laryngeal, 817
otitic, 59
vestibular, 314
Vestibular apparatus, 314
Vestibule of labyrinth, 31, 32
Vibratory massage, 92
Vidal, 490
Vincent's angina, 710, 714
treatment, 714, 715
Virchow, 167
Vocal cords, angiofibromata of, 829
nodule of, 828, 829
papilloma of, 827, 830
tuberculosis of, 425, 426
Voice, changes in, in adenoids, 674, 675
in chronic hyperplastic laryngitis, 769
in tuberculosis of larynx, 424
tests for hearing, 36, 37
Voss bruit in sinus thrombosis, 353

Wade, 480
Wagener's adaptation of the Michel clamp suture for tonsillar hemorrhage, 730
forceps, 581
Waldeyer's ring, 671, 739
Walker, 487, 650
Walsham, 705
Wassermann test in labyrinthitis accompanying syphilis, 335
in lupus of nose, 417
in syphilis of middle ear, 435
Waste pail, Phillips's, 2, 4
Watch test for hearing, 36
Water, hot and cold applications, 89
Water massage of drum membrane, 87
Weber's hearing test, 41
Webs, laryngeal, 829
Weiner's rasp, 578, 579
Weiss, 471
Well, 650
Wertheimer, 77
Wet cups for local bloodletting, 99
White's palate retractor, 16
Whiting, 295
Whooping-cough. See Pertussis.
Wiese, 435
Wild's incision, 99, 165
Williams, Watson, 490, 706, 757, 779
Wittmaack, 392
Woakes, 655
Wolf, 37
Wolfenden, 430
Wood, 420, 423, 705, 750
Wright, Jonathan, 45, 82, 100, 160, 420, 433, 656, 705, 706, 707

X-ray in eczema of ear, 115
in epithelioma of auricle, 158
in rhinoscleroma, 481
in sarcoma, 572
in traumatic pharyngitis, 716
in tuberculosis, 409, 414, 418

Yankauer, incision for submucous resection, 528
medicine dropper, 430
periosteum elevator, 535
septal curet, 530, 534
suture needle, 536

Zarniko, 514
Zaufel, 137
Zeroni, 337, 366
Ziegler, 376
Ziem, 574
Ziemssen, 369, 778, 783
Zuckerkandl, 568, 570, 571, 572, 587, 626

H·31 83

THE LIBRARY OF CONGRESS

THE LIBRARY OF CONGRESS

N. MANCHESTER,
INDIANA 46962

LIBRARY OF CONGRESS
0 029 827 918 6